

# Endoscopically assisted nerve decompression of rare nerve compression syndromes at the upper extremity

Franck Marie P. Leclère · Dietmar Bignion ·  
Torsten Franz · Lukas Mathys · Esther Vögelin

Received: 27 September 2012 / Published online: 17 February 2013  
© Springer-Verlag Berlin Heidelberg 2013

## Abstract

**Background** Besides carpal tunnel and cubital tunnel syndrome, other nerve compression or constriction syndromes exist at the upper extremity. This study was performed to evaluate and summarize our initial experience with endoscopically assisted decompression.

**Materials and methods** Between January 2011 and March 2012, six patients were endoscopically operated for rare compression or hour-glass-like constriction syndrome. This included eight decompressions: four proximal radial nerve decompressions, and two combined proximal median nerve and anterior interosseus nerve decompressions. Surgical technique and functional outcomes are presented.

**Results** There were no intraoperative complications in the series. Endoscopy allowed both identifying and removing all the compressive structures. In one case, the proximal radial neuropathy developed for 10 years without therapy and a massive hour-glass nerve constriction was observed intraoperatively which led us to perform a concurrent complementary tendon transfer to improve fingers and thumb extension. Excellent results were achieved according to the modified Roles and Maudsley classification in five out of six cases. All but one patient considered the results excellent. The poorest responder developed a CRPS II and refused post-operative physiotherapy.

**Conclusion** Endoscopically assisted decompression in rare compression syndrome of the upper extremity is highly appreciated by patients and provides excellent

functional results. This minimally invasive surgical technique will likely be further described in future clinical studies.

**Keywords** Endoscopy · Pronator teres syndrome · Supinator syndrome · Kiloh–Nevin syndrome · Nerve compression · Nerve constrictions · Hourglass-like constrictions

## Introduction

Besides carpal tunnel (CTS) and cubital tunnel syndrome, other single rare nerve entrapments exist at the upper extremity. These include the compression of the proximal radial nerve (supinator syndrome), the proximal median nerve (pronator teres syndrome) and the anterior interosseus nerve (Kiloh–Nevin syndrome). Moreover, these nerves can also be constricted due to the compression sites or because of idiopathic etiologies. Non-operative management is always prescribed initially and consists of rest and a tapered course of oral corticosteroids. When symptoms persist, an open surgical treatment is necessary to release the nerve compression sites.

Since the first work of Tsai [1], endoscopically assisted decompression of the ulnar nerve has steadily developed and represents a reliable and reproducible alternative to conventional surgical techniques for cubital tunnel syndrome. In our experience [2–4], this technique allows for complete decompression of all compressive structures, without disturbing the vascularization of the nerve and leaving the nerve bed intact. This minimally invasive technique is highly appreciated by patients. In a previous article, we reported our experience with endoscopically assisted decompression of the ulnar nerve and raised the

F. M. P. Leclère (✉) · D. Bignion · T. Franz · L. Mathys ·  
E. Vögelin  
Department of Plastic and Hand Surgery, Inselspital Bern,  
University of Bern, Bern, Switzerland  
e-mail: [franckleclere@yahoo.fr](mailto:franckleclere@yahoo.fr); [franck.leclere@inserm.fr](mailto:franck.leclere@inserm.fr);  
[franck.leclere@insel.ch](mailto:franck.leclere@insel.ch)

possibility of applying this technique to other compression syndromes [3].

The purpose of this study was to evaluate our initial experience with endoscopically assisted decompression of rare nerve compression or constriction syndrome of the upper extremity. Particular attention is given to the technical steps of the surgical technique. We review the benefits of the endoscopic technique, the methodological limitations of the studies, and discuss possibilities of future development of endoscopy in peripheral nerve entrapment.

## Materials and methods

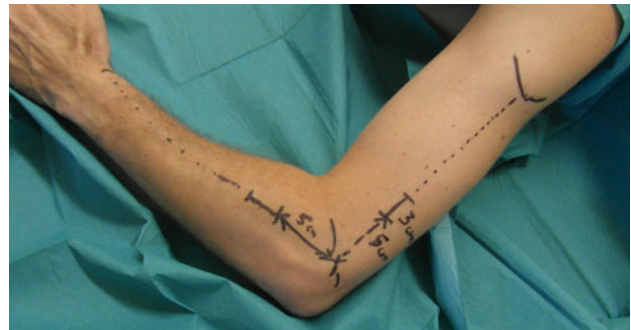### Patients

This retrospective study was performed following the ethical guidelines of the University of Bern. Inclusion criteria were patients with a rare single compression or constriction syndrome of the proximal radial or median nerve, of both sexes, that were operated upon between January 2011 and March 2012 in our department. Exclusion criteria were patients with the following: pregnancy, history of coagulation disorders or anticoagulants, diabetes, polyneuropathy, vasculitis and preoperative algodystrophy. Eight nerves were released with endoscopy in six patients during this period of time: four proximal radial nerve decompressions and two combined proximal median nerve and anterior interosseus nerve decompressions.

### Surgical technique

#### *Endoscopically assisted proximal radial nerve decompression*

A 2- to 3-cm incision was made 5 cm proximal to the elbow joint following the line from the insertion of the deltoid to the lateral epicondyle (Fig. 1). Under direct visualization, and then with an illuminated speculum, dissection was carried out through the subcutaneous layers to the level of upper arm fascia. The fascia was carefully opened allowing direct visualization of the radial nerve. After blunt tunneling with forceps, a 4 mm 30° endoscope (Karl Storz, Tuttlingen, Germany) was introduced in the superficial plane to complete the opening of the fascia, followed by opening of the intermuscular septum. The radial nerve was neurolyzed proximally and distally up 5 cm distal to the elbow joint with the elbow extended. A second 2- to 3-cm longitudinal incision was made distally where the light of the endoscope (introduced from proximally) could be seen 5 cm distal to the elbow joint. This was usually on the lateral surface of the proximal forearm overlying the interval between the brachioradialis (BR) and extensor carpi radialis longus (ECRL),



**Fig. 1** Drawing of the skin incision in endoscopically assisted proximal radial nerve decompression. The second incision is made distally where the light of the endoscope (introduced from proximally) can be seen 5 cm distal to the extended elbow joint. The incision point is usually between the BR and ECRL. In this figure the forearm is pronated which modifies the topography

beginning approximately 5 cm past the elbow flexion crease and extending distally. A different incision, medial to the BR, would have allowed good visualization of the superficial branch of the radial nerve but would have required a larger exposure to visualize the deep branch. Under direct visualization, dissection was performed through the subcutaneous layers to the level of the extensor muscles fascia. An illuminated speculum (blade length 9–11 cm) was inserted. The interval between the BR and the ERCL, or corresponding extensor muscles was opened and the posterior interosseous nerve exposed. It was previously identified using the first incision which had allowed a neurolysis 5 cm distal to the elbow joint. After blunt tunneling with forceps, the 4 mm 30° endoscope was introduced under the extensor muscles. The neurolysis was completed, first proximally, then distally. Known anatomical compression of the nerve (Arcade of Frohse, leash of Henry, fibrous edge of the ECRB) and the distal accessory bands, sequelae of traumatic injury and idiopathic constriction of the nerve, can be exposed and the nerve released from the pathologic structures.

#### *Endoscopically assisted proximal median nerve decompression*

A 3 cm straight longitudinal incision was made on the mid-volar surface of the forearm, 3 cm distal to the elbow flexion crease (Fig. 4). Under direct visualization, dissection was carried out through the subcutaneous layers to the level of the deep fascia. An illuminated speculum (blade length 9–11 cm) was inserted and the interval between the flexor carpi radialis (FCR) and the BR was opened that allowed for a direct visualization of the nerve. After blunt tunneling with forceps, a 4 mm 30° endoscope was introduced (Karl Storz, Tuttlingen, Germany). The opening of the fascia was completed. Afterwards, the endoscope was introduced in the deep dissection plane under the two

**Table 1** Our series of six patients who underwent endoscopically assisted nerve decompression of rare compression syndrome at the upper extremity

N	Age	Gender	Dominant side	Profession	Type of neuropathy	Side affected	Sites of compression	Nerve	Time before OP (months)	follow up (months)
1	38	M	R	Computer scientist	Constriction/compression	L	FI-BROUS BANDS	Prox. Radial N.	12	14
2	24	M	R	Student	Constriction/compression	R	RRFH AF	Prox. Radial N.	120	7
3	54	F	L	Worker	Compression	R	AF	Prox. Radial N.	4	6
4	52	M	R	Driver	Compression	R	CLT AF	Prox. Radial N.	3	6
5	21	F	L	Housewife	Compression	R	ECRB LF FDS	Prox. Median N. /AIN	13	8
6	65	M	R	Retired	Compression	L	FDS	Prox. Median N. /AIN	3	9

N	Age	Gender	Down-time (weeks)	Objective assessment	Subjective assessment	Preoperative dash	Postoperative dash	GRIP pinch pre/post (kg)	Wrist E/F preoperative postoperative	Wrist P/S preoperative postoperative
1	38	M	2	1	1	17	3	13/32	10-0-65	90-0-90
2	24	M	6	1	1	18	12	5/8 40/30	60-0-65	90-0-90
3	54	F	2	1	1	57	16	7/9 16/16	50-0-60	80-0-80
4	52	M	4	1	1	48	12	8/8 55/58	50-0-60	80-0-80
5	21	F	6	1	1	46	17	7.5/12 8/34	65-0-65	90-0-90
6	65	M	-	4	4	65	60	7/7 -/10 -/2	65-0-65	80-0-85
									70-0-70	90-0-90
									-	-
									30-0-30	70-0-90

RRFH radial recurrent fan of vessels described by Henry, AF arcade of Frohse, CLT triceps brachii muscle, lateral head, ECRB tendinous margin of the extensor carpi radialis brevis, LF lacertus fibrosus, FDS proximal fascial edge of the FDS arch

muscles. The neurolysis was performed first proximally; the bicipital aponeurosis and the fibrous bands of the pronator teres muscle were released. Distally, the median and anterior interosseus nerves were exposed after resection of the fibrous arch of the flexor digitorum superficialis (FDS) muscle and aberrant compressive bands.

#### Postoperative follow-up

An elastic elbow bandage was prescribed for 4 weeks. Patients were advised to avoid strenuous upper extremity activity and not allow these extremities to hang for too long as the effects of gravity might cause painful and uncomfortable oedema.

#### Rating of treatment results

A thorough examination of the affected limb was performed to assess sensitivity, strength, and motion. Objective results were assessed according to the modified Roles and Maudsley classification [5] (Table 1), in which an excellent result (scored 1) was defined as no pain, no altered sensibility, full movement and full activity; a good result was defined as occasional discomfort (pain and/or alteration of the sensibility), full movement, and full activity (scored 2); a fair result was defined as some continuous discomfort, but improved (scored 3); and a bad result was defined as no improvement of the symptoms. Using the list of pre-operative complaints as a guide, patients were questioned about their symptomatic relief and activity level. This subjective evaluation was assessed from excellent (scored 1) to bad (scored 4). It was always completed by comparing the DASH score pre- and postoperatively [6–8].

#### Measured parameters

Six patients were endoscopically operated on for rare compression or hourglass-like constriction syndrome. This included eight decompressions: four proximal radial nerve decompressions, and two combined proximal median nerve and anterior interosseus nerve decompressions. The timing of the evaluation ranged from 6 to 14 months postoperatively. Grip strength was assessed using a Jamar Dynamometer (Sammons Preston Inc., Illinois, USA). Pinch was assessed using a pinch dynamometer (Baseline hydraulic pinch gauge, Fabrication Enterprises Inc, New York, USA).

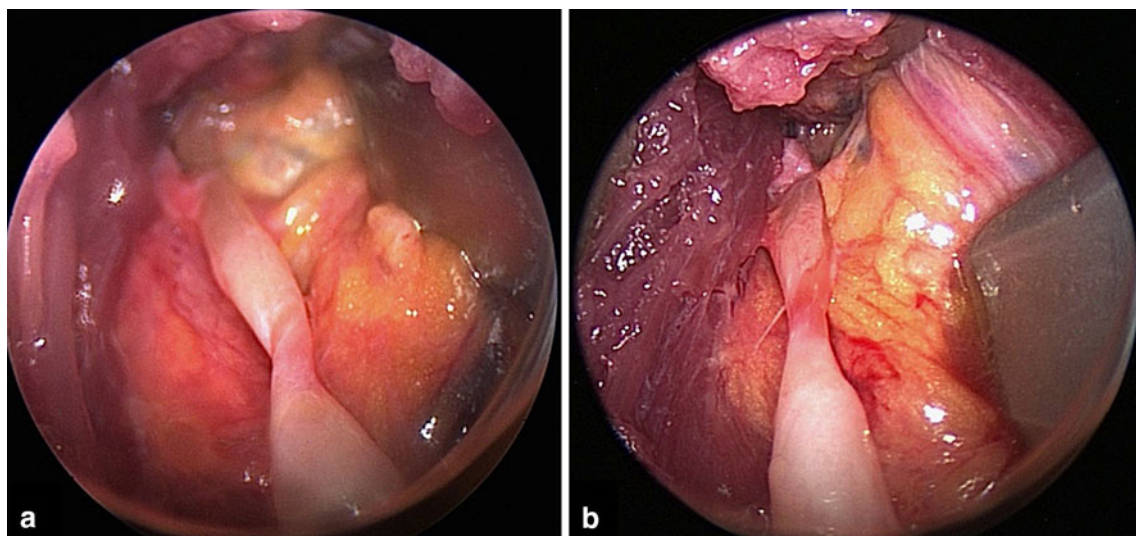
## Results

#### Complications

Between January 2011 and March 2012, six patients were endoscopically operated on for rare compression syndrome (Figs. 1, 2, 3, 4, 5, 6). Four were men and two were women. The mean age was  $42.3 \pm 17.6$  years. Pre-procedural onset of symptoms averaged  $28.3 \pm 45.3$  months (3–120 months). There were no intraoperative complications. Intraoperative findings and postoperative outcomes are reported separately for proximal radial and proximal median and anterior interosseus nerves (Table 1, 2, 3).

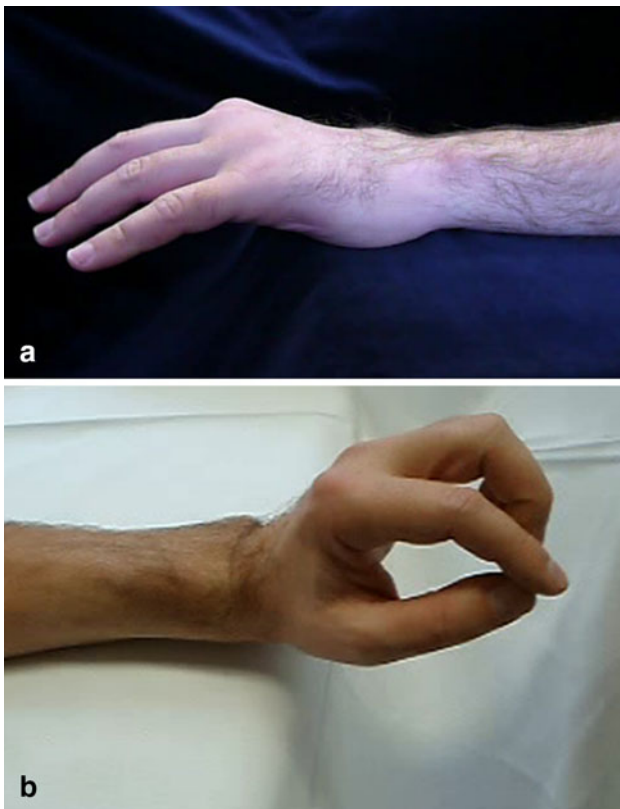
#### Proximal radial nerve decompression

Among the four patients operated on for supinator syndrome, intraoperative findings showed constriction-compression of the radial nerve in two patients and a simple

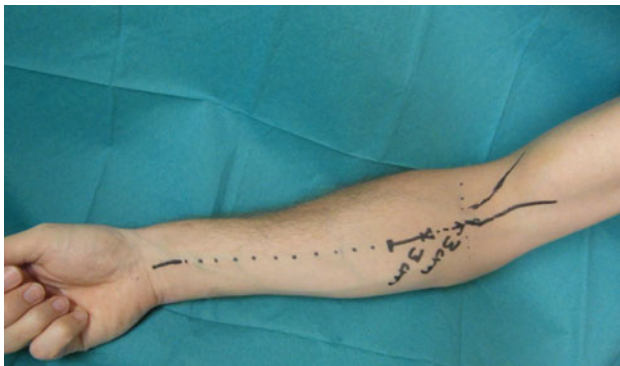

**Fig. 2** Combined compression/hour-glass constriction neuropathy of the radial nerve; **a** the lesion was observed beneath an aberrant compressive band 7–8 cm proximal to the lateral epicondyle (Patient 1 of the series). **b** Radial nerve after decompression





**Fig. 3** Patient 1 of the series before (a) and 4-months after endoscopic radial nerve decompression (b). In this case a compression/hour-glass-constriction neuropathy was observed beneath an aberrant compressive band 7–8 cm proximal to the lateral epicondyle. The wrist extension has improved from 10° to 60°



**Fig. 4** Drawing of the skin incision in endoscopically assisted proximal median nerve decompression

compression in two patients (Table 1). The two simple compressions were observed to be directly beneath the arcade of Frohse in one case (Table 1, Patient 3) and, the tendinous margin of the ECRB and the arcade of Frohse in the other case (Table 1, Patient 4). In the two cases of combined compression/hour-glass constriction neuropathies, the lesion was observed beneath an aberrant compressive band 7–8 cm proximal to the lateral epicondyle in

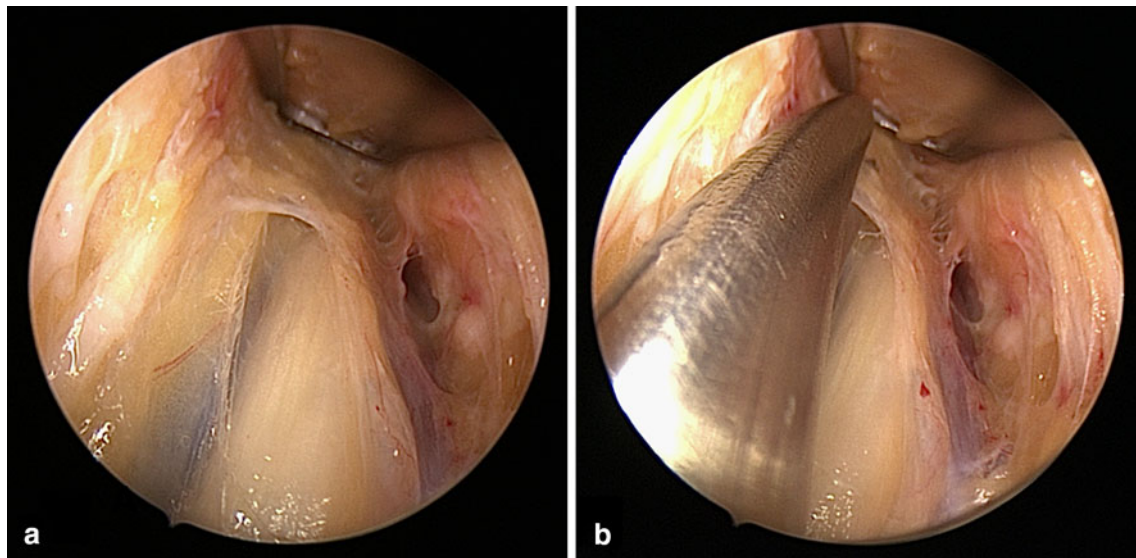
one case (Table 1, Patient 1, Figs. 1, 2, 3) and beneath the radial recurrent fan of vessels described by Henry and the arcade of Frohse in the other case (Table 1, Patient 2). In this last case (Patient 2), the neuropathy had developed for 10 years without therapy and was associated with loss of the following muscle function: extensor digitorum communis, extensor indicis proprius, extensor digitorum quinti, abductor pollicis longus, extensor pollicis brevis, and extensor pollicis longus. Moreover, a massive hour-glass constriction was observed intraoperatively, leading us to also perform a complementary tendon transfer (Palmaris longus to extensor pollicis longus and extensor carpi radialis longus to extensor digitorum communis) so as to improve the finger and thumb extension.

The deep aching pain in the proximal forearm resolved in three out of four cases. The pain radiation into the shoulder and neck, the sense of heaviness of the arm, and the inability to sleep on the affected side resolved respectively in one of two cases, two of three cases, and two of two cases. Weakness and fatigue sensation resolved respectively in three of four cases and two of two cases. The deficit of the wrist, thumb and finger extension resolved respectively in one of one case, two of two cases, and two of two cases (Table 2).

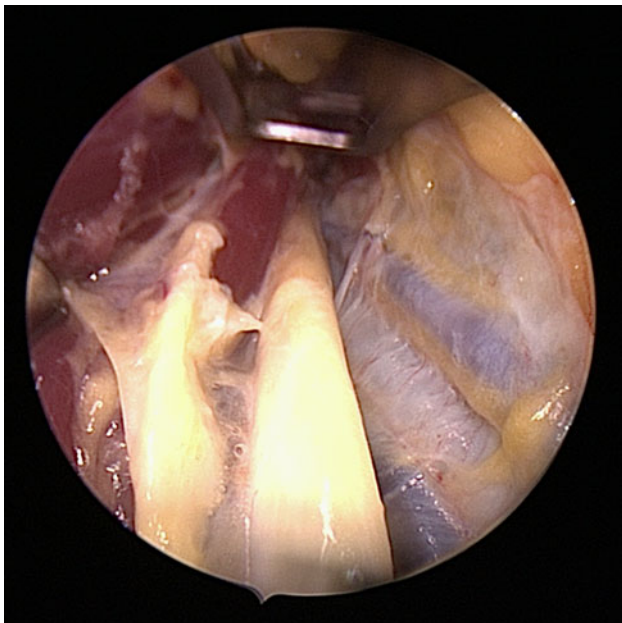
The most consistent pre-operative physical finding was localized and prominent tenderness over the radial nerve at the level of the proximal margin of the supinator muscle, with light digital pressure, accentuating the precise complaint. It resolved in all cases. Clinical examination is presented pre- and postoperatively in Table 3 for each case. For the patient who underwent a tendon transfer (Table 1, Patient 2), the finger and thumb extension could both reach a M5 on the British Medical Research Council (BMRC) scoring 7 months after the procedure (Table 2). Subjective and objective results, range of movement, pinch, and grip strength are reported in Table 1.

#### Proximal median nerve decompression

In the two cases operated with endoscopy for proximal median nerve decompression, the pre-operative complaints and examination (Table 2 and 3) could also underline involvement of the anterior interosseus nerve in the neuropathy. In one patient (Table 1, Patient 5, Figs. 4, 5, 6), compression was observed directly beneath the lacertus fibrosus and proximal fascial edge of the FDS arch. In the second case (Table 1, Patient 6), the compression was localized at the proximal fascial edge of the FDS arch. Complaints and clinical examination are presented pre- and postoperatively in Tables 2 and 3. Table 1 presents subjective and objective results, postoperative range of movement, pinch and grip strength. Patient 6 developed a CRPS II after operation and refused physiotherapy,



**Fig. 5** **a** Endoscopic nerve decompression in proximal median nerve neuropathy; **b** The endoscopically assisted technique using scissors is easy and safe to use in proximal median nerve neuropathy



**Fig. 6** Median nerve proximally to the incision after endoscopic decompression in proximal median nerve neuropathy (Patient 5 of the series)

accounting for the poor outcomes reported in Table 1 for this case.

## Discussion

In this series, six patients were endoscopically operated on for rare compression or hourglass-like constriction syndrome. This included eight decompressions: four proximal

**Table 2** Subjective results of the series

Complaints	Proximal radial nerve	
	Preoperative ( <i>N</i> = 4)	Postoperative ( <i>N</i> = 4)
Deep aching pain in forearm	4	1
Pain radiation to neck and shoulder	2	1
A “heavy” sensation in the arm	3	1
Cannot sleep on affected side	2	0
Weakness	4	1
Fatigues easily	2	0
Deficit of the wrist extension	1	0
Deficit of the thumb extension	2	0
Deficit of the finger extension	2	0
Complaints	Proximal median nerve	
	Preoperative ( <i>N</i> = 2)	Postoperative ( <i>N</i> = 2)
Aching pain in the proximal, volar forearm	2	1
Paresthesias radiating into the thumb, index finger, middle finger, and the radial half of the ring finger, similar to the sensory alterations of carpal tunnel syndrome	2	1
Pain radiation to neck and shoulder	1	1
A “heavy” sensation in the arm	2	1
Cannot sleep on affected side	2	1
Weakness	2	1
Fatigues easily	2	1

**Table 3** Functional results of the series

	Proximal radial nerve	
	Preoperative ( <i>N</i> = 4)	Postoperative ( <i>N</i> = 4)
Radial nerve tenderness at supinator	4	0
Pain on resisted supination	4	0
Tinel sign at proximal radial nerve in forearm	2	0
Altered sensibility over the first dorsal web space	1	1
Weakness of the wrist extension	1 <sup>*,a</sup> (Patient 1: M3)	0
Weakness of the thumb extension	2 (Patient 1: M3; Patient 2: M0)	0 <sup>*,b</sup>
Weakness of the finger extension	2 (Patient 1: M3; Patient 2: M0)	0 <sup>*,b</sup>
	Proximal median nerve	
	Preoperative ( <i>N</i> = 2)	Postoperative ( <i>N</i> = 2)
Resist the patient's pronation of his or her forearm in a neutral position. pain or paresthesias are reproduced during this maneuver (pronator teres syndrome suspected)	1	1
Resisted contraction of the FDS to the middle finger reproduces symptoms? (fibrous arch between the heads of the FDS suspected)	2	1
Symptoms are elicited by resisted flexion of the forearm in full supination, (compression at the more proximal level of the lacertus fibrosus suspected)	2	1
Median nerve tenderness at pronator, at FDS	2	1
Ok-sign not possible?	1	0
Tinel sign at proximal median nerve in forearm	2	0
Altered fingertip-2-point discrimination	2	0
FPL/FDP II weakness	2	0

<sup>\*,a</sup> Patient 2 had a M5 wrist extension on the British Medical Research Council (BMRC) scoring but a slight radial deviation of the extended wrist; this was corrected with the extensor carpi radialis longus to extensor digitorum communis transfer

<sup>\*,b</sup> In patient 2, the M0 finger and thumb extension was corrected with a tendon transfer (Palmaris longus to extensor pollicis longus and extensor carpi radialis longus to extensor digitorum communis

radial nerve decompressions, and two combined proximal median nerve and anterior interosseus nerve decompressions. Among the four patients operated on for supinator syndrome, intraoperative findings showed a constriction-compression of the radial nerve in two patients and a simple compression in two patients. There were no complications in the series. Endoscopy clearly helped to assess the localization of compression and hour-glass constriction. In one case, the proximal radial neuropathy had developed for 10 years without therapy and a massive hour-glass nerve constriction was observed intraoperatively, leading us to perform a concurrent complementary tendon transfer to improve the fingers and thumb extension. Our good functional results with this technique are corroborated by the high satisfaction of patients; they considered the results very good to excellent in all but one case. In the worst case, the patient developed a CRPS II and refused physiotherapy.

This study highlights the perfect adaptation of the endoscopically assisted technique to compression or constriction syndrome of the proximal radial nerve and median nerve. The technique presented here was adapted from one used previously for cubital tunnel syndrome. The latter was introduced in 1995 by Tsai et al. [1] and since this princeps (principle) publication, two types of surgical endoscopically assisted nerve decompression techniques have been used: Knives [9–12] and scissors [13–18] techniques. Despite the excellent results sometimes reported in the literature, endoscopically assisted knife techniques are in our opinion hazardous because of the discrepancy between the size of the instruments and that of the nerve, and the inherent resulting potential for intraoperative nerve injuries. Conversely, the technique using scissors described for the first time by Porcellini [13] and popularized by Hoffmann and Siemionow [14, 15] is much easier and safer to use in the compression or constriction nerve syndrome. Irrespective of the brand of instruments used, whether the one developed by Hoffmann [14, 15] or that reported in by Leclère et al. [2], the technique is standardized. It comes with excellent functional and subjective outcomes for the ulnar nerve. Our study demonstrates that this technique can be adapted with good results for the rarer syndromes of nerve compression or hour-glass constriction in the upper limb. These promising results can be explained by several factors. (1) The instrumentation used allows for a safe neurolysis unlike endoscopic techniques with knives. Kiloh–Nevin syndrome (compression of the anterior interosseous), pronator teres syndrome (compression of the median nerve at the elbow) and supinator syndrome (compression of the motor branch of the radial nerve) involve separate anatomical structures well described in the literature [19–23]. Endoscopy allows for both identifying



and removing all compressive structures. (2) It enables performing the neurolysis without compromising the blood supply of the nerve and reduces scar formation because of the limited opening of the skin and subcutaneous tissues. (3) Finally, the smaller scar is an additional advantage.

Despite the excellent functional and subjective outcomes presented in this series, our study has methodological limitations: First, the number of cases presented in this series is small. However, as it stressed in the introduction section, these syndromes are much rarer than the cubital tunnel syndrome. The majority of patients are first treated with conservative therapy which is usually enough to recover affected nerve function. Second, a control group is lacking. Due to the small number of patients with these conditions, a comparative study like this has not previously been feasible. Third, the mean follow-up is limited. However, this is the first study to describe the endoscopically assisted decompression of the proximal radial nerve. This study, which completes a previous study of Lee et al. [24], underlines the safety of the endoscopically assisted technique for rare compression syndrome at the upper extremity.

Besides the rarity of nerve compression syndromes, two aspects explain the limited development of the endoscopic technique for nerve entrapment or constriction. The price of the equipment can be initially prohibitive. The affordability of new instruments, their rapid amortization, and the aforementioned benefits should contribute to a wider use of this powerful tool. Some authors have previously highlighted the long learning curve of the endoscopic or arthroscopic techniques [25]. The simplicity and practicality of the material presented here illustrates the rapid and safe learning curve of this technique [3].

## Conclusion

Endoscopically assisted decompression in rare compression syndrome of the upper extremity is a procedure highly appreciated by patients and provides excellent functional results. This minimally invasive surgical technique will likely be further described in future clinical studies.

**Conflict of interest** There is no conflict of interest.

## References

1. Tsai TM, Chen IC, Majd ME, Lim BH (1999) Cubital tunnel release with endoscopic assistance: results of a new technique. *J Hand Surg [Am]* 24:21–29
2. Leclère FM, Manz S, Unglaub F, Cardenas E, Hahn P (2011) Endoscopic decompression of the ulnar nerve in the cubital tunnel syndrome: about 55 patients. *Neurochirurgie* 57:73–77
3. Leclère FM, Manz S, Unglaub F, Cardenas E, Hahn P (2012) Endoscopic decompression of the ulnar nerve in the cubital tunnel syndrome. Communication GEM Paris
4. Leclère FM (2012) Ergebnisse der endoskopisch assistierten Dekompression des N. ulnaris bei Sulcus nervi ulnaris-Syndrom: Eine retrospektive Studie über 55 Fälle. University of Heidelberg, Heidelberg, pp 1–111
5. Roles NC, Maudsley RH (1972) Radial tunnel syndrome: resistant tennis elbow as a nerve entrapment. *J Bone Joint Surg [Br]* 54:499–508
6. Jester A, Harth A, Wind G, Germann G (2003) The shoulder, arms and hand disability questionnaire as a scale for identification of the diagnosis-specific activity profile. *Unfallchirurg* 106:834–838
7. Jester A, Harth A, Germann G (2005) Measuring levels of upper-extremity disability in employed adults using the DASH Questionnaire. *J Hand Surg [Am]* 30:1074
8. Jester A, Harth A, Wind G, Germann G, Sauerbier M (2005) Disabilities of the arm, shoulder and hand (DASH) questionnaire: determining functional activity profiles in patients with upper extremity disorders. *J Hand Surg [Br]* 30:23–28
9. Carlier Y, Prové S, Desmoineaux P, Boisrenoult P, Beaufile P (2005) Décompression in situ du nerf ulnaire au coude par technique endoscopique: à propos de 22 cas. *Rev Chir Ortho Traumat* 2:91–96
10. Bain GI, Bajhou A (2005) Endoscopic release of the ulnar nerve at the elbow using the Agee device: a cadaveric study. *Arthroscopy* 21:691–695
11. Ahcan U, Zorman P (2007) Endoscopic decompression of the ulnar nerve at the elbow. *J Hand Surg [Am]* 32:1171–1176
12. Nakao Y, Takayama S, Toyama Y (2001) Cubital tunnel release with lift-type endoscopic surgery. *J Hand Surg [Am]* 6:199–203
13. Porcellini G, Paladini P, Campi F, Merolla G (2005) Arthroscopic neurolysis of the ulnar nerve at the elbow. *Chir Organi Mov* 90:191–200
14. Hoffmann R, Siemionow M (2006) The endoscopic management of cubital tunnel syndrome. *J Hand Surg [Eur]* 31:23–29
15. Hoffmann R, Meek MF (2008) Endoscopic decompression of the ulnar nerve at the elbow. *J Hand Surg [Am]* 33A:615–616
16. Bultmann C (2009) Ergebnisse der endoskopischen Dekompression des Nervus ulnaris bei Kubitaltunnelsyndrom. *Handchir Mikrochir Plast Chir* 41:28–34
17. Cobb T, Sterbank P (2007) Comparison of return to work: endoscopic versus open cubital tunnel release. Poster IFSSH, Sydney
18. Cobb TK, Sterbank PT, Lemke JH (2010) Endoscopic cubital tunnel recurrence rates. *Hand [NY]* 5:179–183
19. Dang AC, Rodner CM (2009) Unusual compression neuropathies of the forearm, part I: radial nerve. *J Hand Surg* 34A:1906–1914
20. Dang AC, Rodner CM (2009) Unusual compression neuropathies of the forearm, Part II: Median Nerve. *J Hand Surg* 34A:1915–1920
21. Zancolli ER 3rd, Zancolli EP 4th, Perrotto CJ (2012) New minimally-invasive decompression for pronator teres syndrome. *J Hand Surg [Am]* 37:1706–1710
22. Presciutti S, Rodner CM (2011) Pronator syndrome. *J Hand Surg [Am]* 36:907–909
23. Van den Ende KI, Steinmann SP (2010) Radial tunnel syndrome. *J Hand Surg [Am]* 35:1004–1006
24. Lee AK, Khorsandi M, Nurbhai N, Dang J, Fitzmaurice M, Herron KA (2012) Endoscopically assisted decompression for pronator syndrome. *J Hand Surg [Am]* 37:1173–1179
25. Falcone MO, Wavreille G, Limousin M, Chantelot Ch, Fontaine Ch (2009) Complications de l'arthroscopie de poignet en début d'expérience. Communication GEM Paris