

About the role of visual field defects in pure alexia

Tobias Pflugshaupt,^{1,2,3,4} Klemens Gutbrod,³ Pascal Wurtz,^{1,2} Roman von Wartburg,^{1,2}
Thomas Nyffeler,^{1,2,3} Bianca de Haan,⁴ Hans-Otto Karnath⁴ and René M. Mueri^{1,2,3}

- 1 Perception and Eye Movement Laboratory, Department of Neurology, Inselspital, Bern University Hospital and University of Bern, Switzerland
- 2 Perception and Eye Movement Laboratory, Department of Clinical Research, Inselspital, Bern University Hospital and University of Bern, Switzerland
- 3 Division of Cognitive and Restorative Neurology, Department of Neurology, Inselspital, Bern University Hospital and University of Bern, Switzerland
- 4 Section of Neuropsychology, Centre for Neurology, Hertie-Institute for Clinical Brain Research, Eberhard Karls University, Tübingen, Germany

Correspondence to: Prof. René M. Mueri, MD,
Perception and Eye Movement Laboratory,
Departments of Neurology and Clinical Research,
University Hospital, 3010 Bern,
Switzerland
E-mail: rene.muering@insel.ch

Pure alexia is an acquired reading disorder characterized by a disproportionate prolongation of reading time as a function of word length. Although the vast majority of cases reported in the literature show a right-sided visual defect, little is known about the contribution of this low-level visual impairment to their reading difficulties. The present study was aimed at investigating this issue by comparing eye movement patterns during text reading in six patients with pure alexia with those of six patients with hemianopic dyslexia showing similar right-sided visual field defects. We found that the role of the field defect in the reading difficulties of pure alexics was highly deficit-specific. While the amplitude of rightward saccades during text reading seems largely determined by the restricted visual field, other visuo-motor impairments—particularly the pronounced increases in fixation frequency and viewing time as a function of word length—may have little to do with their visual field defect. In addition, subtracting the lesions of the hemianopic dyslexics from those found in pure alexics revealed the largest group differences in posterior parts of the left fusiform gyrus, occipito-temporal sulcus and inferior temporal gyrus. These regions included the coordinate assigned to the centre of the visual word form area in healthy adults, which provides further evidence for a relation between pure alexia and a damaged visual word form area. Finally, we propose a list of three criteria that may improve the differential diagnosis of pure alexia and allow appropriate therapy recommendations.

Keywords: reading; eye movements; visual field defect; pure alexia; hemianopic dyslexia

Abbreviations: LBL = letter-by-letter; VWFA = visual word form area; WLE = word length effect; wpm = words per minute

Introduction

Patients with pure alexia suffer from severe reading problems while other language-related skills such as naming, oral repetition, auditory comprehension or writing are typically intact (Behrmann *et al.*, 2001). The disorder has also been labelled alexia without agraphia (Dejerine, 1892), letter-by-letter (LBL) dyslexia (Fiset *et al.*, 2005), spelling dyslexia (Warrington and Langdon, 1994),

word-blindness (Kusssmaul, 1877), or word-form dyslexia (Warrington and Shallice, 1980). It results from cerebral lesions in circumscribed brain regions and thus belongs to the group of acquired reading disorders (Coslett, 2000), as opposed to developmental reading disorders found in children who have difficulties in learning to read (Temple, 2006). Acquired reading disorders can further be divided into peripheral and central dyslexias (Shallice and Warrington, 1980), depending on whether the underlying

deficit predominantly affects—in a very broad sense—the visual analysis of written language or ‘higher’, more cognitive levels of the reading process. Within this dichotomy, pure alexia has been assigned to the group of peripheral dyslexias (Coslett, 2000).

Initially, pure alexics may show severe difficulties not only in word and sentence reading but also in identifying and discriminating single letters (Leff *et al.*, 2001), a condition known as global alexia (Binder and Mohr, 1992). In the course of recovery, they typically develop a LBL reading strategy, which is characterized by laborious, serial encoding of letters (Rayner and Johnson, 2005). The hallmark feature of pure alexia is the word length effect (WLE), i.e. a disproportionate prolongation of reading times when the number of letters per word is increased (e.g. Arguin and Bub, 1993; Hanley and Kay, 1996; Montant and Behrmann, 2000; Sakurai *et al.*, 2006). However, the magnitude of this effect seems quite variable between patients, as it can range, for example, from 97 ms (Behrmann *et al.*, 1998) to 2402 ms (Leff *et al.*, 2001) per additional letter.

Since the first scientific description of a patient with pure alexia in the 19th century (Dejerine, 1892), several theories about the pathological mechanism evoking the disorder have been proposed. In the traditional view (Dejerine, 1892; Geschwind and Fusillo, 1966), pure alexia results from a disconnection between early visual cortices and an assumed visual centre for words in the left angular gyrus (Catani and ffytche, 2005). More recent accounts can be grouped regarding the particular stage between low-level visual perception and word form recognition to which the core deficit is assigned. At the ‘visual end’ of this scale, pure alexia has been attributed to a perceptual impairment affecting linguistic and non-linguistic stimuli alike (Friedman and Alexander, 1984; Farah and Wallace, 1991; Rapp and Caramazza, 1991). A more linguistic theory states that the main deficit of patients concerns impaired encoding and processing of letters on a pre-lexical level (Arguin and Bub, 1993). Finally, the disorder has been explained in terms of a deficient system through which the whole word form is attained (Warrington and Shallice, 1980). Processing multiple letters in parallel (Levine and Calvanio, 1978; Rayner and Johnson, 2005) or mapping the percept of all the letters in a familiar letter string onto the mental representation of the whole word form (Leff *et al.*, 2001) may be specifically impaired.

Regarding the neuroanatomical correlate of pure alexia, the traditional disconnection approach postulates two critical lesions needed to isolate the visual centre for words in the left angular gyrus from visual input: one in the left occipital lobe and the other in the splenium of the corpus callosum (Dejerine, 1892). However, pure alexia has also been described after single lesions, which sometimes do not include the splenium (Behrmann *et al.*, 2001). In the vast majority of cases reported in the literature, the disorder occurred secondary to lesions in the left occipito-temporal region (Montant and Behrmann, 2000). More specifically, studies during which common lesion sites were investigated in groups of patients have related pure alexia to: (i) a lesion in the paraventricular white matter of the left occipital lobe (Damasio and Damasio, 1983); (ii) damaged cortex and white matter of the left ventral temporal lobe including the inferior temporal and anterior fusiform gyri (Binder and Mohr, 1992); (iii) an injury to the cortex in the left occipito-temporal sulcus (Cohen *et al.*, 2003); or (iv) a lesion in

the posterior part of the left fusiform gyrus and adjacent tissue (Leff *et al.*, 2006).

Of particular interest in the study of Leff *et al.* (2006) is the finding that in four of their six patients with pure alexia, brain damage included the coordinate assigned to the centre of the so-called visual word form area (VWFA) in the left fusiform gyrus of healthy adults (Jobard *et al.*, 2003). The other two patients had damage within 4 mm of this coordinate. Based on findings from functional imaging studies (e.g. Cohen *et al.*, 2000, 2002), the visual word form area has been described as a specialized brain region devoted to the identification of visual letter strings (Dehaene *et al.*, 2005) and abstract visual word form perception (McCandliss *et al.*, 2003). Despite an ongoing debate concerning the role of this area in reading (e.g. Price and Devlin, 2003; Cohen and Dehaene, 2004), several recent case studies in patients with pure alexia have explicitly related the disorder to a lesioned visual word form area (Cohen *et al.*, 2003; Henry *et al.*, 2005; Johnson and Rayner, 2007) or to deafferentation of the visual word form area from visual input (Cohen *et al.*, 2004). Specifically relevant is the case of an epileptic patient who showed a pronounced word length effect after focal corticectomy in the left occipito-temporal lobe: based on comparison of pre- with post-surgical reading performance as well as brain activations measured with fMRI and intracranial electrodes, a causal link between brain damage in the region of the visual word form area and pure alexia has been postulated (Gaillard *et al.*, 2006).

Concerning both the scientific and clinical investigation of pure alexia, it is challenging that most patients with this disorder show a right-sided visual field defect. Based on extensive literature research including 107 cases of pure alexia published over the preceding 40 years, Leff *et al.* (2001) found that 98 (92%) of these patients ‘had a right homonymous field defect of some sort’ (p. 516). On the one hand, it has been proposed that these field defects are not causally related to the severe word recognition impairment of pure alexics (Leff *et al.*, 2006). Support for this assumption comes from rare reports about pure alexia found in patients without visual field defects (e.g. Greenblatt, 1973; Henderson *et al.*, 1985). However, as already pointed out by others (Johnson and Rayner, 2007), right-sided field defects are likely to lower reading performance at least to some degree, given the defect affects the foveal and/or parafoveal visual field whose integrity is crucial for reading (Rayner and Bertera, 1979).

In this case, pure alexics actually suffer from a second peripheral dyslexia, which is called hemianopic dyslexia (Zihl, 1995) or hemianopic alexia (Leff *et al.*, 2000) and was first described by Mauthner (1881). Being regarded as the most elementary and most frequent of the peripheral dyslexias (Schuett *et al.*, 2008), hemianopic dyslexia is mainly characterized by slowed reading (Zihl, 1995) and inefficient eye movement strategies during reading (McDonald *et al.*, 2006). Although the label hemianopic dyslexia is collectively used for reading problems occurring due to different types of visual field defects (Schuett *et al.*, 2008), many studies have shown that right-sided field defects cause more severe reading problems than left-sided field defects (e.g. Zihl, 1995; Trauzettel-Klosinski and Brendler, 1998). This finding

concerns languages that are read from left to right, and it results from the asymmetry of the so-called perceptual span during reading: when we read from left to right, the region of effective processing in the visual field extends to 3–4 characters to the left of fixation, as opposed to 15 characters to the right of fixation (as reviewed in Rayner, 1998). In addition to this side-specificity, the severity of the reading impairment in hemianopic dyslexia crucially depends on the degree of macular sparing, with more sparing causing less impairment (Zihl, 1995).

As mentioned above, it is important to investigate the role of the visual field defect that accompanies pure alexia in most patients for both scientific and clinical reasons. When pure alexia is interpreted on the basis of a presumed key deficit such as deficient letter encoding (Arguin and Bub, 1993) or impaired processing of multiple letters in parallel (Rayner and Johnson, 2005), one should exclude—or at least minimize—the possibility that this deficit is merely a consequence of a right-sided field defect. From a clinical point of view, examining if and to what extent pure alexia and hemianopic dyslexia may be present in a given patient is essential, since specific rehabilitation techniques have been developed for both reading disorders (Leff *et al.*, 2001, 2006). While patients with hemianopic dyslexia mainly benefit from eye movement training (Zihl, 1995; Spitzyna *et al.*, 2007), treatment efforts in pure alexia have been focused, for example, on the improvement of word identification through kinaesthetic reading (Seki *et al.*, 1995; Nitzberg Lott and Friedman, 1999). The present study was aimed at disentangling the visual field defect from pure alexia by comparing the reading performance of pure alexics with that of hemianopic dyslexics. It goes without saying that this experimental design requires patients whose visual field defects are—with regard to side and degree of macular sparing—highly similar between groups.

From a methodological point of view, the two patient groups were compared with a text reading task during which we recorded their eye movements. In healthy adults, text reading evokes a rather stereotypical eye movement pattern (Land, 2006), characterized by a series of rightward saccades that connect successive fixations during which visual information is acquired (Rayner, 1998). Leftward saccades also occur during text reading: return sweeps move the eyes from the end of a line to the beginning of the next line (Trauzettel-Klosinski and Brendler, 1998), while occasional regressions are corrective saccades that move the eyes back to previous parts of the text (Reichle *et al.*, 2003). A wide range of variables such as fixation duration or the frequency of regressions can thus be extracted from eye movement recordings and used to investigate normal (as reviewed by Rayner, 1998; Reichle *et al.*, 2003) or pathological reading. In fact, eye movement analysis has already been applied to analyse reading performance in patients with pure alexia (Behrmann *et al.*, 2001; Rayner and Johnson, 2005; Johnson and Rayner, 2007) and patients with hemianopic dyslexia (e.g. Zihl, 1995; Trauzettel-Klosinski and Brendler, 1998; McDonald *et al.*, 2006). But none of these studies was aimed at examining the role of visual field defects in pure alexia.

Contrasting eye movement behaviour of pure alexics with that of hemianopic dyslexics allows investigation of this issue in both descriptive and quantitative terms. Descriptively, we were

interested in the identification of visuo-motor variables that potentially separate the two patient groups. For instance, if pathologically prolonged fixation durations were found in pure alexics—but not in hemianopic dyslexics—one could conclude that this deficit has little to do with the right-sided field defect. Quantitatively, central tendency measures from the two patient groups and from healthy participants were used to estimate the extent to which the right-sided field defect contributes to the reading impairment in pure alexia. Furthermore, correlational analyses within patient groups allowed examination of the relation between the reading-relevant degree of macular sparing and visuo-motor difficulties during reading. Finally, we also performed lesion analyses in both patient groups. Here the main goal was to investigate if damage in the area corresponding to the centre of the visual word form area in healthy adults (Jobard *et al.*, 2003) may be a useful indicator to separate pure alexics from hemianopic dyslexics.

Methods

Participants

Similar to previous studies investigating pure alexia in more than one or two patients (e.g. Binder and Mohr, 1992), our clinical sample was prospectively recruited over a relatively long time period. During the 5 years needed to assemble appropriate participants for the present study, six patients with pure alexia were identified from the population of in-patients at our unit of cognitive and restorative neurology. All of them fulfilled the following inclusion criteria: (i) severe reading difficulties (e.g. extremely slowed reading, clinically evident word length effect) in the absence of other aphasic symptoms during neuropsychological examination; (ii) ability to correctly identify all the letters of the alphabet at the time of the investigation, which is a critical criterion when text reading shall be examined in pure alexia (Behrmann *et al.*, 2001); and (iii) presence of a significant word length effect in a computer-assisted single word reading task as described below. In addition to fulfilling these criteria, patients underwent automated static perimetry (Octopus 101TM, Haag-Streit AG, Koeniz, Switzerland), which included a programme specifically designed to assess visual field function in the macula. Demographic and relevant clinical data of these six patients is listed in Table 1.

Two control groups were recruited for the present eye movement study. First, six patients with hemianopic dyslexia due to right-sided visual field loss participated as a clinical control group. Absence of aphasic symptoms, flawless letter identification ability and absence of a significant word length effect in the single word reading task described below were the inclusion criteria for this group. Furthermore, Table 1 shows that hemianopic dyslexics and pure alexics were matched with regard to gender and did not significantly differ from each other concerning age, education, duration since onset of brain damage, estimated lesion volume and—most importantly—degree of macular sparing. Visual field defects of all 12 patients are illustrated in Fig. 1. A second control group consisted of six healthy adults who were matched with the two patient groups regarding gender (two females, four males), age (median = 56 years, interquartile range/IQR = 26 years) and education (median = 15 years, IQR = 6 years). All 18 participants were right-handed, had uncorrected or corrected visual acuity of at least 0.63 and gave written informed consent prior to participation. Moreover, the study was carried out

Table 1 Demographic and clinical data of the two patient groups

Patient	Gender	Age in years	Education in years	Aetiology	Time post-onset in weeks	Lesion volume (ccm) ^a	Visual field defect	Macular sparing in degrees ^b	WLE in ms/letter ^c	WLE, <i>p</i> ^d
Pure alexia										
1	Male	42	20	Infarct	18	100	Right paracentral scotoma	3.5	287	<0.001
2	Male	43	15	Haemorrhage	7	20	Right upper quadrantanopia	7.5	933	<0.001
3	Female	18	12	Infarct	6	24	Right upper quadrantanopia	1	405	<0.001
4	Female	64	12	Haemorrhage	9	60	Right hemianopia	0.5	288	<0.001
5	Male	36	20	Infarct	8	50	Right hemianopia	1	430	<0.001
6	Male	63	13	Infarct	5	34	Right upper quadrantanopia	2	469	<0.001
Median (IQR)		43 (32)	14 (8)		8 (6)	42 (47)		1.50 (3.63)	418 (297)	
Hemianopic dyslexia										
1	Female	35	20	Haemorrhage	6	23	Right paracentral scotoma	2	31	0.381
2	Female	46	13	Trauma	19	11	Right hemianopia	4	33	0.327
3	Male	78	16	Infarct	1	19	Right upper quadrantanopia	0.5	50	0.052
4	Male	48	15	Haemorrhage	19	34	Right hemianopia	0.5	46	0.086
5	Male	70	15	Infarct	8	39	Right hemianopia	5	28	0.467
6	Male	59	13	Trauma	90	67	Right hemianopia	0.5	37	0.231
Median (IQR)		54 (29)	15 (4)		14 (32)	29 (29)		1.25 (3.75)	35 (17)	
Mann-Whitney Tests										
U		11.0	15.0		13.0	11.5		15.0	0.0	
<i>P</i>		0.310	0.699		0.485	0.310		0.699	0.002	

a As estimated with MRICro software (Rorden and Brett, 2000).

b Based on macula-specific, static automated perimetry (programme M2 of the Octopus 101TM, Haag-Streit AG, Koeniz, Switzerland); sparing was assessed along the horizontal meridian, by counting unaffected test points in the perimetry chart and converting the result into visual degrees, rounded to 0.5°.

c Word-length effect (WLE) in milliseconds per additional letter. Based on reading times from the single word reading task described in the Methods section.

d One-tailed error probability of a modified *t*-test specifically designed to compare the value of a single patient with those of a small control group (Crawford and Howell, 1998). Refers to the comparison between the WLE of a given patient with corresponding values from a control group of healthy adults (*n* = 20), as described in the Methods section.




Figure 1 Visual field defects of the two patient groups (PA = pure alexia; HD = hemianopic dyslexia). Individual plots are based on macula-specific, static automated perimetry (programme M2 of the Octopus 101TM, Haag-Streit AG, Koeniz, Switzerland) and show the central visual field (radius = 10°) of each patient. Absolute deficits are shown as black areas (0–5 dB), relative deficits as grey areas (5–20 dB) and unaffected regions as light grey or white areas (>20 dB). Visual fields were separately tested for both eyes. When interocular differences were revealed, the less affected eye—concerning macular sparing along the horizontal meridian—was chosen for both the quantification of macular sparing and the present illustration. Patient numbers correspond to those given in Table 1.

in accordance with the latest version of the Declaration of Helsinki and approved by the local ethics committee.

Single word reading task

As mentioned above, displaying a pathological word length effect when reading German single words was an inclusion criterion for the group of pure alexics and an exclusion criterion for the group of hemianopic dyslexics. During the word reading task used for the present study, patients silently read 40 four-letter and 40 six-letter nouns that centrally appeared on a computer screen, one-by-one, in a pseudo-randomized order. According to the CELEX database (Baayen *et al.*, 1993), the two groups of words did not significantly differ from each other with regard to word frequency. Patients were instructed to stop every word presentation with a keypress as soon as correct word identification was possible. Reading accuracy as tested by the experimenter after each trial was 95% or higher in all patients. Reading times were analysed by calculating the mean increase in milliseconds per additional letter, which is the standard measure for the word length effect (e.g. Behrmann *et al.*, 1998). Applying modified *t*-tests (Crawford and Howell, 1998), this increase was considered pathological when it significantly exceeded corresponding values from a control group of healthy adults ($n=20$; age: mean=44 years, SD=12 years; 6 males, all right-handed; WLE: mean=27 ms, SD=13 ms), who showed flawless reading accuracy. Table 1 lists absolute word length effects and *P*-values of each patient.

Lesion analysis

Using the freely available MRIcro software (<http://www.mricro.com>; Rorden and Brett, 2000), brain lesions were manually drawn from clinical MR or CT scans onto axial slices of the CH2 template brain. MRIcro allowed estimation of lesion volumes (Table 1) and labelling of shared lesion sites based on the Automated Anatomical Labelling map (Tzourio-Mazoyer *et al.*, 2002). Furthermore, the MRIcroN software (www.mricro.com/mricron; Rorden *et al.*, 2007) was applied to create group-specific lesion overlay plots and a subtraction plot displaying voxels more often affected in pure alexia than in hemianopic dyslexia and vice versa. These plots were created in correspondence with a recent study aimed at comparing neuroanatomical correlates in pure alexia and hemianopic dyslexia (Leff *et al.*, 2006). In order to increase comparability between this study and ours, we chose the same *z*-planes (−24, −20, −16, −12, −8 and −4) for the overlay and subtraction plots and the same coordinate ($x=-44$, $y=-58$, $z=-16$) to indicate the centre of the visual word form area in the healthy brain. This coordinate was obtained from a meta-analysis based on 27 functional imaging studies about word reading in healthy adults (Jobard *et al.*, 2003).

Eye tracking device

An infrared-based video tracking system (EyeLink™, SensoMotoric Instruments GmbH, Berlin, Germany) was used to measure eye movements at a sampling rate of 250 Hz and with a spatial resolution of 0.01°. Gaze-position accuracy relative to stimulus coordinates was 0.5–1.0°, depending on participants' fixation accuracy during the calibration procedure. The latter was performed before each text presentation by means of a 9-point target grid. A chin rest was used to ensure constant viewing distance and minimize head movements. In addition, head movement compensation was performed by the tracking system. Participants sat in a dimly lit room, 70 cm in front of a 19 inch CRT computer screen, resulting in a field of view

of $\sim 29 \times 22^\circ$. Concerning the identification of saccades and fixations from the raw data recorded by the eye tracking system, the EyeLink saccade detection algorithm was used and configured to the following thresholds: a saccade velocity threshold of 35° s^{-1} , a saccade acceleration threshold of $9500^\circ \text{ s}^{-1}$ and a saccade motion threshold of 0.1°. Moreover, a minimal fixation duration of 100 ms was applied.

Text reading task

Four articles taken from a local newspaper written in German were used as stimuli of the text reading task. They measured between 43 and 52 words in length, summing to 194 words overall. Each text was presented in seven left-justified lines. Approximately two character spaces corresponded to 1° of visual angle. Before the presentation of each article, a 'starting point' was shown in the left upper screen corner to indicate the position of the first letter in the subsequently appearing text. Participants were instructed to look at that point and initiate text presentation with a mouse click. Then they had to silently read the article before stopping its presentation with another mouse click. The experimenter thereafter descriptively tested global text comprehension by asking participants why they thought this story was printed in the newspaper, or what they considered most unusual about the story. Here it is important to note that all articles described a highly uncommon event. For instance, one text was about a woman who delivered a baby in a car while her husband was driving her to the hospital. When participants told us that it is unusual to deliver a baby in a car, global comprehension was assumed to be good for that particular text. Detailed text comprehension was not tested. Prior to the experiment, at least one practise trial was conducted in each participant.

The analysis of text reading performance was based on nine dependent variables overall: reading speed in words per minute (wpm), fixation frequency expressed as fixation-to-character ratio, average fixation duration, amplitude of rightward saccades, percentage of regressions, amplitude of regressions, amplitude of return sweeps and fixation frequency as well as cumulative fixation duration as a function of word length. For the latter two variables, three words for every length between two and six letters were selected from the four texts. Concerning word frequency (Baayen *et al.*, 1993), there was no significant overall difference between these five groups of words. The number of fixations and the cumulative fixation duration on the selected words was then analysed and averaged for each word length, allowing the calculation of average increases in fixation frequency and viewing time per additional letter.

At first sight, investigating the influence of word length on fixation patterns during text reading seems redundant, since patients were assigned to groups based on whether they show a significant word length effect during single word reading (pure alexia) or not (hemianopic dyslexia). However, it has been proposed that right-sided visual field defects impair text reading more than single word reading (Leff *et al.*, 2001), so that hemianopic dyslexics might yet display a significant word length effect during text reading. Finally, it should be mentioned that amplitudes of regressions and return sweeps were included as control variables—and expected to be normal in both patient groups—as reduced amplitudes of leftward saccades are characteristic of left-sided, but not right-sided visual field loss (Zihl, 1995).

Data analysis

Since Kolmogorov–Smirnov tests revealed that several of the dependent variables significantly deviated from normal distribution, group

comparisons were based on non-parametric statistical tests. For the same reason, medians and IQRs were used to describe group-specific central tendency and dispersion. As for group comparisons, we first performed Kruskal–Wallis tests to evaluate overall group differences. Here a P -value of <0.05 was considered statistically significant. Concerning those variables that yielded significant overall group differences, one-tailed Mann–Whitney U -tests were then performed for paired comparisons, applying a Bonferroni-corrected P -value threshold of 0.017 to control for type 1 error inflation.

Visuo-motor variables yielding significant deficits in pure alexics were further used to estimate the contribution of the right-sided field defect to their reading impairment, taking into account central tendency measures from all three groups of participants. For each of these variables, we first calculated (i) the absolute difference between the median of pure alexics and that of healthy participants; and (ii) the absolute difference between the median of hemianopic dyslexics and that of healthy participants. The latter difference was then expressed as a percentage of the former. For instance, if the median fixation duration was 200 ms in healthy participants, 300 ms in hemianopic dyslexics and 600 ms in pure alexics, applying this formula would result in a quantitative estimate of 25%. Finally, and aimed at complementing these estimates, we examined the relationship between the degree of macular sparing and visuo-motor behaviour within the two patient groups by means of non-parametric correlational analyses (i.e. Kendall's rank order correlation).

Results

Lesion analysis

Figure 2A illustrates conventional lesion density plots for the two groups of patients. The number of overlapping lesions is colour-coded, with increasing frequencies ranging from purple ($n=1$) to red ($n=6$). Figure 2B shows the results of the subtraction analysis during which the lesions of hemianopic dyslexia patients were subtracted from those of pure alexia patients. The most pronounced differences between groups were found in posterior parts of the left fusiform gyrus, occipito-temporal sulcus and inferior temporal gyrus. These brain areas also included the coordinate assigned to the centre of the visual word form area in healthy adults (Jobard *et al.*, 2003). In fact, the visual word form area coordinate (white crosshairs in Fig. 2) was affected in five of the six patients with pure alexia, but in none of the six patients with hemianopic dyslexia.

Text reading

Global text comprehension

Four of the six patients with pure alexia, all hemianopic dyslexics and all healthy participants showed unimpaired global text

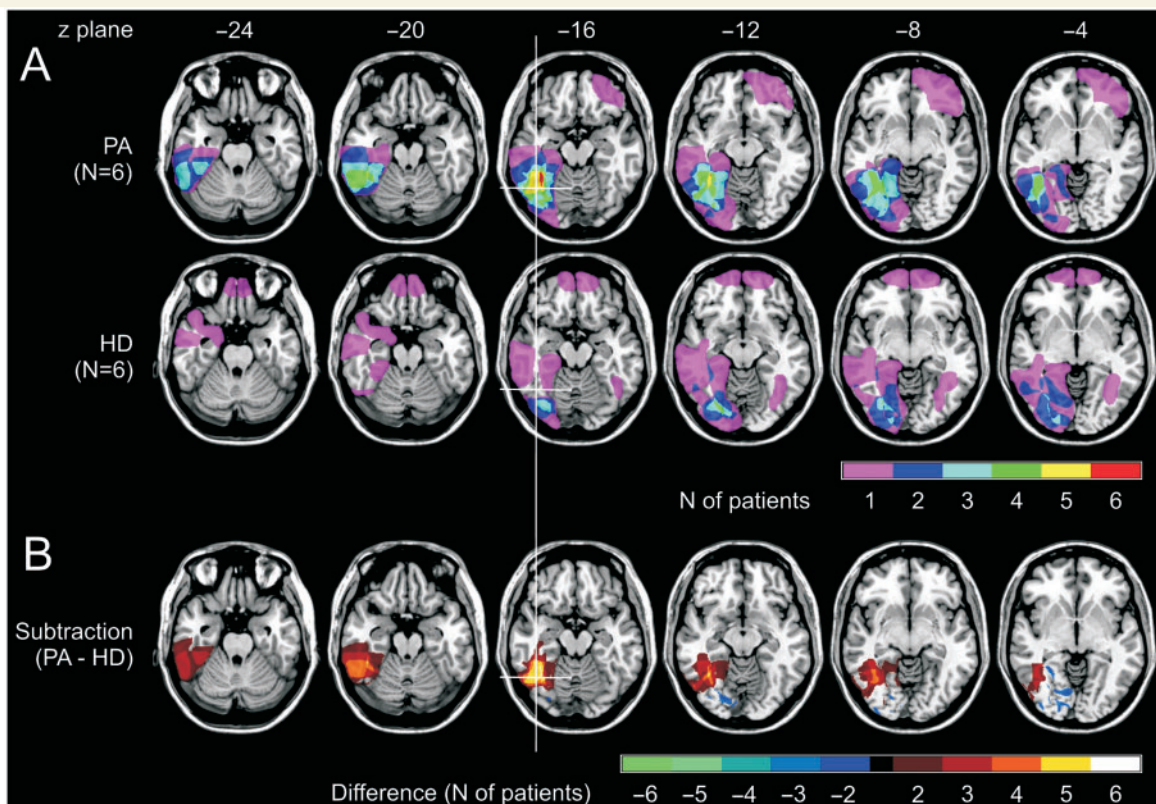


Figure 2 Analysis of brain lesions in the two patient groups. (A) Group-specific overlay plots (PA = pure alexia; HD = hemianopic dyslexia). (B) Subtraction analysis. Coloured voxels are those more often lesioned in pure alexics (warm colours) or in hemianopic dyslexics (cold colours), relative to the other patient group. White crosshairs show the coordinate assigned to the centre of the visual word form area in healthy adults, as obtained from the meta-analysis by Jobard *et al.* (2003).

comprehension. In other words, they correctly described each of the four unusual events. One patient with pure alexia apparently missed single words that are crucial for the overall context of a story (e.g. words indicating a negation) in two texts. The sixth patient with pure alexia had certain comprehension problems with all texts. For example, he reported that two men—instead of one—offered a kidney for sale on the internet, or that a window pane—instead of the backrest of the passenger seat—had been wound down before a woman gave birth to a child in a car.

Reading speed

With regard to reading speed in words per minute (wpm), significant overall differences between the three groups of participants were found (Kruskal–Wallis test: $\chi^2 = 15.158$, $df = 2$, $P = 0.001$). Mann–Whitney tests showed that healthy participants (median = 237 wpm, range: 230–256 wpm) read faster than both patient groups, and that hemianopic dyslexics (median = 75 wpm, range: 55–198 wpm) read faster than pure alexics (median = 24 wpm, range: 15–39 wpm). These central tendency measures were comparable to those found in previous studies. For example, Leff *et al.* (2001) reported an average reading speed of 68 words per minute for patients with hemianopic dyslexia—who suffered from a right-sided visual field defect—and

23 wpm for patients with pure alexia in another study (Leff *et al.*, 2006), while Radner *et al.* (2002) measured a mean reading speed of 230 words per minute in a group of 99 healthy university students. Figure 3A depicts group-specific medians, interquartile ranges and P -values of paired comparisons of the present study.

Visuo-motor variables

Significant overall differences between groups were found with regard to the fixation-to-character ratio (Kruskal–Wallis test: $\chi^2 = 14.749$, $df = 2$, $P = 0.001$), the average fixation duration (Kruskal–Wallis test: $\chi^2 = 12.772$, $df = 2$, $P = 0.002$), the amplitude of rightward saccades (Kruskal–Wallis test: $\chi^2 = 11.614$, $df = 2$, $P = 0.003$) and the percentage of regressions (Kruskal–Wallis test: $\chi^2 = 8.526$, $df = 2$, $P = 0.014$). As expected, the amplitude of regressions and that of return sweeps did not significantly differ between groups. Figure 3B–G depicts group-specific medians and interquartile ranges of these six visuo-motor variables.

Concerning the four variables that yielded significant overall differences, Fig. 3B–G also includes significant P -values of paired comparisons (Mann–Whitney tests). Relative to healthy participants, patients with pure alexia displayed a higher fixation-to-character ratio, longer fixation durations, shorter amplitudes of rightward saccades and an enhanced percentage of regressions. Except for the latter deficit, the same impairments were found in

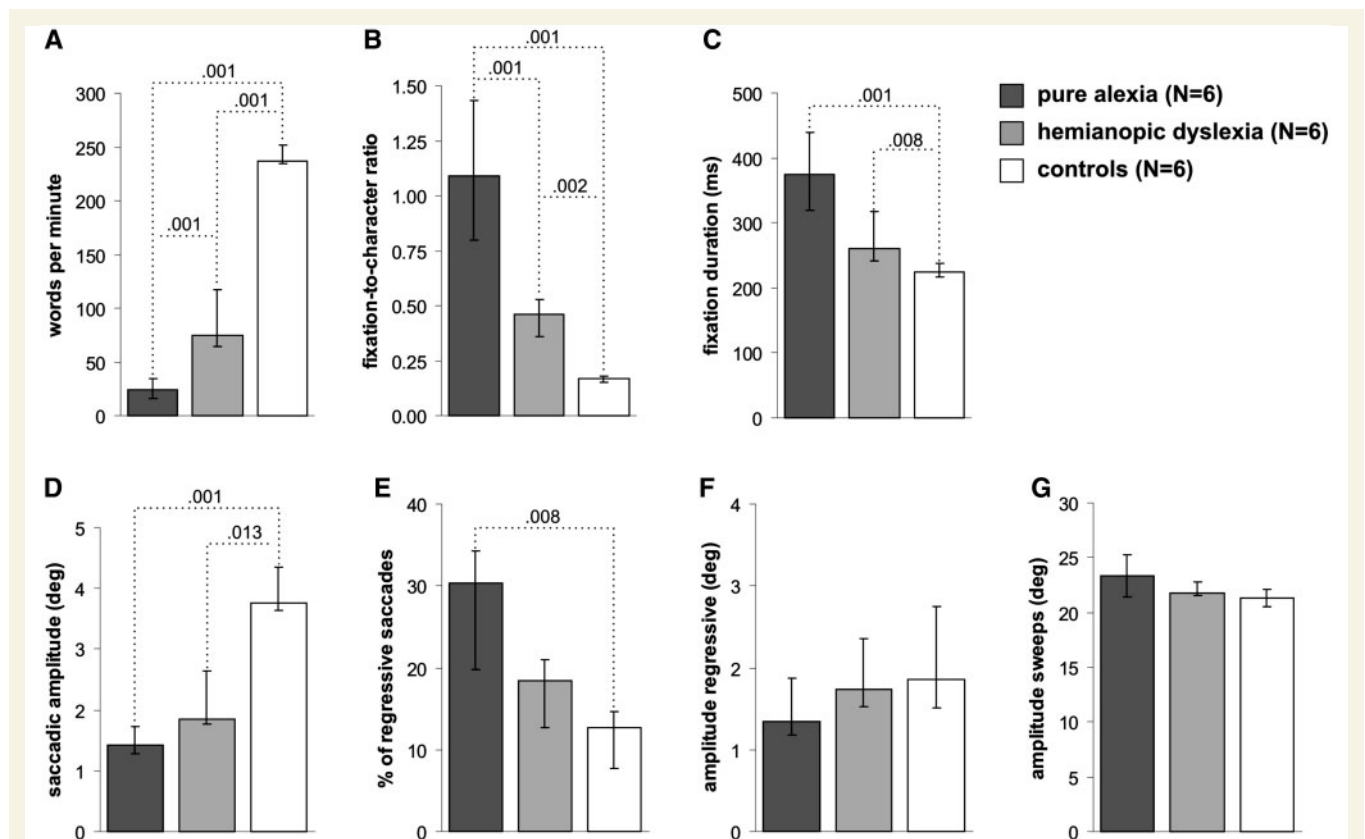


Figure 3 Reading speed and visuo-motor variables. Group-specific medians and interquartile ranges/IQRs are shown for: (A) reading speed; (B) fixation frequency; (C) average fixation duration; (D) amplitude of rightward saccades; (E) percentage of regressions; (F) amplitude of regressions; and (G) amplitude of return sweeps. (A–E) further show P -values for those paired comparisons (one-tailed Mann–Whitney tests) that reached the Bonferroni-corrected level of significance (0.017).

patients with hemianopic dyslexia. Paired comparisons between the two patient groups showed that pure alexics displayed a higher fixation-to-character ratio than hemianopic dyslexics. Illustrating these visuo-motor differences between groups, Fig. 4 shows typical scanning patterns.

Analysing the influence of word length on fixation frequency and viewing time revealed significant overall differences between groups with regard to the increase in the number of fixations per additional letter (Kruskal–Wallis test: $\chi^2 = 12.104$, $df = 2$, $P = 0.002$) and the increase in viewing time per additional letter (Kruskal–Wallis test: $\chi^2 = 11.789$, $df = 2$, $P = 0.003$). The two right panels in Fig. 5 depict group-specific medians, interquartile ranges and significant P -values of paired comparisons (Mann–Whitney tests) for these two variables. Patients with pure alexia displayed enhanced increases in fixation frequency and viewing time per additional letter, relative to both healthy participants and

patients with hemianopic dyslexia. No significant differences were found between the latter two groups.

As a next step, the quantitative contribution of the visual field defect to visuo-motor impairments in patients with pure alexia was estimated according to the formula described in the methods section. We found that their field defect accounts for 32% of the enhanced fixation-to-character ratio, 23% of the prolonged average fixation duration, 82% of the reduced amplitude of rightward saccades, 32% of the enhanced percentage of regressions, 25% of the enhanced increase in fixation frequency per additional letter and 10% of the enhanced increase in viewing time per additional letter. In line with the finding of a dominant involvement of the visual field defect in the reduced amplitude of rightward saccades in pure alexia, non-parametric correlational analyses within this patient group revealed that the amplitude of rightward saccades was the only visuo-motor variable that significantly



Figure 4 Typical scanning pattern examples from a patient with pure alexia (A), a patient with hemianopic dyslexia (B) and a healthy participant (C). Lines depict saccades, circles represent fixation locations and circle diameters are proportional to fixation duration.

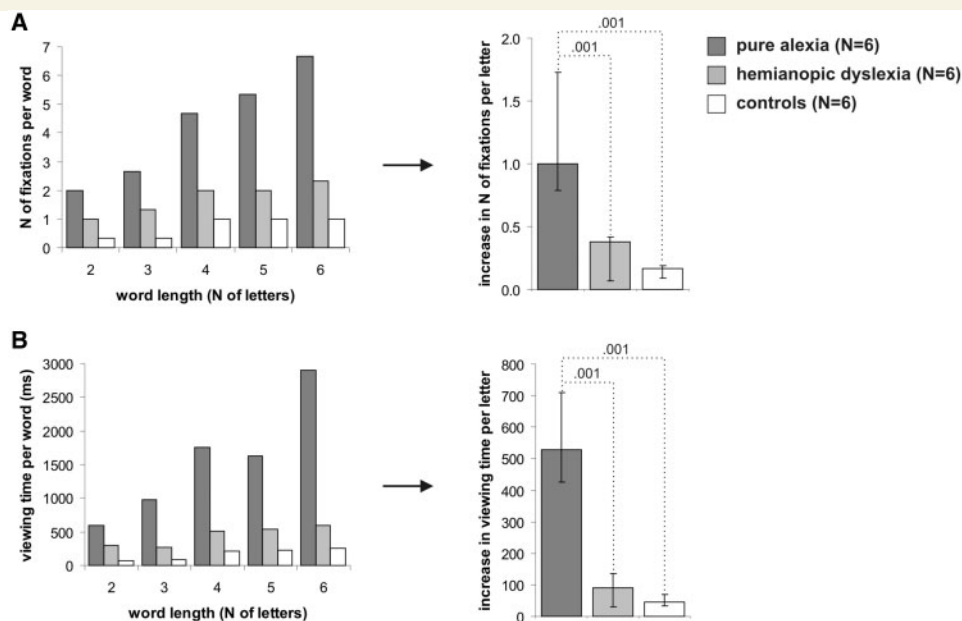


Figure 5 Visuo-motor word length effect (WLE). (A) Fixation frequency as a function of word length. (B) Viewing time as a function of word length. The panels on the left display group-specific medians for each word length that was analysed, while median increases per additional letter and corresponding interquartile ranges are shown in the panels on the right. The latter panels further include P -values for those paired comparisons (one-tailed Mann–Whitney tests) that reached the Bonferroni-corrected level of significance (0.017).

correlated with the degree of macular sparing. More precisely, patients with less macular sparing tended to make shorter rightward saccades ($r_{\text{Kendall-Tau-b}} = 0.828$, $P_{\text{two-tailed}} = 0.022$). Corresponding analyses within the group of patients with hemianopic dyslexia yielded two significant correlations, both of them concerned the influence of word length on visuo-motor variables: hemianopic dyslexics with less macular sparing tended to display more pronounced increases in fixation frequency ($r_{\text{Kendall-Tau-b}} = -1.000$, $P_{\text{two-tailed}} = 0.010$) and viewing time ($r_{\text{Kendall-Tau-b}} = -0.894$, $P_{\text{two-tailed}} = 0.016$) per additional letter.

Discussion

Although >90% of patients with pure alexia show a right-sided visual field defect (Leff *et al.*, 2001), little is known about the contribution of this defect to their reading difficulties, which are mainly characterized by a pronounced word length effect (WLE) and LBL reading (Montant and Behrmann, 2000). When their foveal or parafoveal visual field is affected, patients actually suffer from a combined reading disorder: pure alexia in terms of impaired letter (Arguin and Bub, 1993) and/or word form processing (Warrington and Shallice, 1980), and more elementary hemianopic dyslexia due to restricted visual input (Schuett *et al.*, 2008). From a methodological point of view, the role of the latter disorder in the reading difficulties of patients with pure alexia can be investigated in at least two ways: (i) comparison of the reading performance of pure alexics with that of hemianopic dyslexics showing similar visual field defects; or (ii) examination of the relation between the extent of the visual field defect and reading performance within a group of patients with pure alexia. Both approaches were applied in the present eye movement study.

Based on neuropsychological examination, macula-specific perimetry, and on whether individual patients showed a significant word length effect during single word reading (pure alexia) or not (hemianopic dyslexia), six pure alexics and six hemianopic dyslexics were identified and recruited. The two clinical samples did not differ from one another regarding several demographic and clinical variables such as the side of their visual field defect and the degree of macular sparing. These patients and a control group consisting of six healthy adults were confronted with a text reading task that required participants to silently read short newspaper articles while their eye movements were recorded. Reading speed was analysed as a first outcome variable. Confirming our hypotheses, healthy participants read significantly faster than both patient groups, and hemianopic dyslexics displayed a higher reading speed than pure alexics. Moreover, group-specific central tendency measures were comparable to those reported in previous studies for pure alexia (Leff *et al.*, 2006), hemianopic dyslexia (Leff *et al.*, 2001) and healthy adults (Radner *et al.*, 2002).

However, our main analyses concerned visuo-motor variables that can be regarded as the basic spatio-temporal units out of which total reading duration and thus reading speed is composed. These analyses revealed that the reading impairment of pure alexics was evident in all visuo-motor variables for which significant deficits were expected with reference to previous studies (Behrmann *et al.*, 2001; Johnson and Rayner, 2007). Relative to

healthy participants, they displayed higher fixation frequency, longer fixation durations, shorter amplitudes of rightward saccades, higher percentages of regressions and more pronounced effects of word length on fixation frequency and viewing time. On the other hand, patients with hemianopic dyslexia showed three of these six visuo-motor deficits—i.e. enhanced fixation frequency, prolonged fixation duration and shortened amplitudes of rightward saccades—which also corresponds well with previously described eye movement patterns found in patients with this disorder (Zihl, 1995; Trauzettel-Klosinski and Brendler, 1998; McDonald *et al.*, 2006). Descriptive comparison of visuo-motor deficits between patient groups thus suggests that enhanced percentages of regressions and pronounced effects of word length on fixation frequency and viewing time found in patients with pure alexia may have little to do with their right-sided field defect.

Yet, due to relatively small sample sizes and thus limited statistical power, these comparisons are likely to underestimate visuo-motor deficits in patients, which particularly concerns the less impaired hemianopic dyslexics. As a consequence, the contribution of the field defect to the reading impairment in pure alexia might also be underestimated. Based on central tendency measures from all three groups of participants, we therefore calculated quantitative estimates of this contribution for every visuo-motor variable that yielded significant deficits in patients with pure alexia. Our data indicate that the field defect may account for about one-third or less of most of their visuo-motor impairments during text reading. The notable exception concerned the reduced amplitude of rightward saccades. Here a contribution of 82% was found, suggesting that this deficit of pure alexics is predominantly attributable to their right-sided visual field defect. Consistently, further analyses revealed that the amplitude of rightward saccades was the only visuo-motor variable that significantly correlated with the reading-relevant degree of macular sparing in patients with pure alexia.

That their amplitude of rightward saccades was more strongly influenced by the field defect than other visuo-motor variables can be related to previous findings about eye-movement control during reading in healthy participants. As reviewed by Reichle *et al.* (2003), the decision about where to fixate next seems largely determined by visual features to the right of fixation (e.g. spaces between upcoming words). Since right-sided parafoveal field defects disturb or prevent the perception of such features, amplitudes of rightward saccades may considerably be affected by this visual impairment. In contrast, the decision about when to move the eyes seems primarily determined by linguistic properties of words (Reichle *et al.*, 2003). The degree of linguistic impairment in pure alexics—that is, their difficulties in processing letters (Arguin and Bub, 1993) and/or word forms (Warrington and Shallice, 1980)—is thus likely to have a stronger impact on fixation durations and total viewing times than their field defect. As a first major conclusion, we therefore postulate that the contribution of the right-sided visual defect to the reading impairment of pure alexia is deficit-specific, with amplitudes of rightward saccades being most affected.

Furthermore, the findings of the present study have implications for the differential diagnosis of pure alexia. Availability of sensitive

parameters to separate pure alexia from hemianopic dyslexia in individual patients is important since specific rehabilitation techniques have been developed for either disorder (e.g. Nitzberg Lott and Friedman, 1999; Spitzyna *et al.*, 2007). Leff *et al.* (2006) have recently proposed the combined use of simple reading tests, perimetry and lesion profiles for differential diagnosis. The authors particularly emphasized the role of lesion analysis. In four of their six patients with pure alexia, brain damage involved the coordinate identified as the centre of the visual word form area (VWFA) in healthy adults (Jobard *et al.*, 2003), a site that was spared in the group of hemianopic dyslexics. The results of the present lesion analysis were similar: brain damage included this coordinate in five of our six patients with pure alexia—but in none of the hemianopic dyslexics—and the largest differences between groups were found at and near the visual word form area coordinate. These findings thus provide further evidence for a relation between pure alexia and a lesioned visual word form area (Cohen *et al.*, 2003; Henry *et al.*, 2005), a brain region devoted to the identification of visual letter strings (Dehaene *et al.*, 2005) and abstract visual word form perception (McCandliss *et al.*, 2003) in the healthy brain. Moreover, our results suggest that lesion analysis may indeed be helpful when pure alexia has to be identified and separated from hemianopic dyslexia in clinical settings.

However, lesion analysis alone is certainly insufficient to solve the issue, as not all pure alexics display brain damage in left occipito-temporal brain regions. For instance, the disorder has also been associated with a left thalamic haemorrhage (Hanley and Kay, 1996) or even a right-hemispheric infarction (Tsapkini *et al.*, 2005). It thus seems reasonable to assume that differential diagnosis can be improved when adequate behavioural measures are applied. In this regard, the magnitude of the word length effect and reading speed may be promising candidates. Leff *et al.* (2006) chose an arbitrary word length effect cut-off score of 100 ms per additional letter during single word reading to separate the more impaired pure alexics from hemianopic dyslexics. Furthermore, and based on Fig. 1 in their article, applying a text reading speed cut-off score of ~50 wpm would have had the same effect. Interestingly, these two cut-off scores also distinguish the two patient samples of the present study.

In contrast, other results from patients with pure alexia or hemianopic dyslexics are at odds with the use of these two cut-off scores. For example, one of the six pure alexics described in the study of Behrmann *et al.* (1998) displayed a word length effect of only 97 ms per additional letter, while word length effects in hemianopic dyslexics can be as high as 162 ms per additional letter (Leff *et al.*, 2001). Moreover, text reading speed in one of the four hemianopic dyslexics examined by Leff *et al.* (2000) was only 32 wpm. It might thus be desirable if further sensitive parameters were available. Results from the present study indicate that eye movement analysis seems suitable to provide such parameters.

Analysing visuo-motor behaviour during text reading revealed three variables that significantly separated the more impaired pure alexics from hemianopic dyslexics, i.e. fixation frequency and effects of word length on both fixation frequency as well as viewing time. The first two of these variables may be specifically

helpful to differentiate between the two groups. Being regarded as one of the hallmark features of pure alexia (e.g. Rayner and Johnson, 2005), the characteristic LBL reading implies that patients with pure alexia fixate more or less every single letter during text reading, and that they show an increase of about one fixation for each additional letter when different word lengths are compared. In fact, this is exactly what we have found in the present dataset (Figs 3 and 5). From a methodological point of view, assessing reading impairments in pure alexia on the basis of eye movement data offers a crucial advantage, relative to simple measurements of reading times and reading speed. When the characteristic word length effect is elicited by reading tasks during which eye movements are not tracked, a patient under consideration might read words by making a single fixation at the centre of words, very similar to the visuo-motor reading strategy of healthy participants (Rayner, 1998). If the duration of this single fixation increases as a function of word length—due to, for example, enhanced visual or semantic complexity of long, relative to short words—the patient would display a word length effect although he does not apply the serial letter encoding strategy characteristic of pure alexia (Rayner and Johnson, 2005). In contrast, the visuo-motor finding of enhanced fixation frequency as a function of word length rules this possibility out.

As a second major conclusion, we thus propose that eye movement analysis improves the differential diagnosis of pure alexia. This particularly concerns brain-damaged patients who display a right-sided visual field defect and impaired reading, while other language skills are relatively intact. In such situations, clinicians need to decide whether a patient suffers from pure alexia, in addition to the hemianopic dyslexia that can be assumed when the field defect affects the foveal or parafoveal visual field. Together with findings from previous studies, the present results suggest that pure alexia is more likely the more of the following conditions are fulfilled: (i) damage to posterior parts of the left fusiform gyrus, occipito-temporal sulcus and inferior temporal gyrus; (ii) text reading speed of <50 wpm; and (iii) a fixation-to-character ratio as well as an increase in fixation frequency per additional letter during text reading of about one or higher.

Funding

Haag-Streit Foundation; Novartis Foundation.

References

- Arguin M, Bub DN. Single-character processing in a case of pure alexia. *Neuropsychologia* 1993; 31: 435–58.
- Baayen RH, Piepenbrock R, van Rijn H. The CELEX lexical data base [CD-ROM]. Philadelphia: Linguistic Data Consortium, University of Pennsylvania; 1993.
- Behrmann M, Nelson J, Sekuler E. Visual complexity in letter-by-letter reading: 'Pure' alexia is not so pure. *Neuropsychologia* 1998; 36: 1115–32.
- Behrmann M, Shomstein SS, Black SE, Barton JJ. The eye movements of pure alexic patients during reading and nonreading tasks. *Neuropsychologia* 2001; 39: 983–1002.

- Binder JR, Mohr JP. The topography of callosal reading pathways. A case-control analysis. *Brain* 1992; 115: 1807–26.
- Catani M, ffytche DH. The rises and falls of disconnection syndromes. *Brain* 2005; 128: 2224–39.
- Cohen L, Dehaene S. Specialization within the ventral stream: the case for the visual word form area. *Neuroimage* 2004; 22: 466–76.
- Cohen L, Dehaene S, Naccache L, Lehérycy S, Dehaene-Lambertz G, Hénaff MA, et al. The visual word form area: spatial and temporal characterization of an initial stage of reading in normal subjects and posterior split-brain patients. *Brain* 2000; 123: 291–307.
- Cohen L, Henry C, Dehaene S, Martinaud O, Lehérycy S, Lemer C, et al. The pathophysiology of letter-by-letter reading. *Neuropsychologia* 2004; 42: 1768–80.
- Cohen L, Lehérycy S, Chochon F, Lemer C, Rivaud S, Dehaene S. Language-specific tuning of visual cortex? Functional properties of the visual word form area. *Brain* 2002; 125: 1054–69.
- Cohen L, Martinaud O, Lemer C, Lehérycy S, Samson Y, Obadia M, et al. Visual word recognition in the left and right hemispheres: anatomical and functional correlates of peripheral alexias. *Cereb Cortex* 2003; 13: 1313–33.
- Coslett HB. Acquired dyslexia. *Semin Neurol* 2000; 20: 419–26.
- Crawford JR, Howell DC. Comparing an individual's test score against norms derived from small samples. *Clin Neuropsychol* 1998; 12: 482–6.
- Damasio AR, Damasio H. The anatomic basis of pure alexia. *Neurology* 1983; 33: 1573–83.
- Dehaene S, Cohen L, Sigman M, Vinckier F. The neural code for written words: a proposal. *Trends Cogn Sci* 2005; 9: 335–41.
- Dejerine J. Contribution à l'étude anatomo-pathologique et clinique des différentes variétés de cécité verbale. *Mém Soc Biol* 1892; 4: 61–90.
- Farah MJ, Wallace MA. Pure alexia as a visual impairment: a reconsideration. *Cogn Neuropsychol* 1991; 8: 313–34.
- Fiset D, Arguin M, Bub D, Humphreys GW, Riddoch MJ. How to make the word-length effect disappear in letter-by-letter dyslexia: implications for an account of the disorder. *Psychol Sci* 2005; 16: 535–41.
- Friedman RB, Alexander MP. Pictures, images, and pure alexia: a case study. *Cogn Neuropsychol* 1984; 1: 9–23.
- Gaillard R, Naccache L, Pinel P, Clémenceau S, Volle E, Hasboun D, et al. Direct intracranial, fMRI, and lesion evidence for the causal role of left inferotemporal cortex in reading. *Neuron* 2006; 50: 191–204.
- Geschwind N, Fusillo M. Color-naming defects in association with alexia. *Arch Neurol* 1966; 15: 137–46.
- Greenblatt SH. Alexia without agraphia or hemianopsia. Anatomical analysis of an autopsied case. *Brain* 1973; 96: 307–16.
- Hanley JR, Kay J. Reading speed in pure alexia. *Neuropsychologia* 1996; 34: 1165–74.
- Henderson VW, Friedman RB, Teng EL, Weiner JM. Left hemisphere pathways in reading: inferences from pure alexia without hemianopia. *Neurology* 1985; 35: 962–8.
- Henry C, Gaillard R, Volle E, Chiras J, Ferrieux S, Dehaene S, et al. Brain activations during letter-by-letter reading: a follow-up study. *Neuropsychologia* 2005; 43: 1983–9.
- Jobard G, Crivello F, Tzourio-Mazoyer N. Evaluation of the dual route theory of reading: a metanalysis of 35 neuroimaging studies. *Neuroimage* 2003; 20: 693–712.
- Johnson RL, Rayner K. Top-down and bottom-up effects in pure alexia: evidence from eye movements. *Neuropsychologia* 2007; 45: 2246–57.
- Kussmaul A. Die Störungen der Sprache. Leipzig: F.C.W. Vogel; 1877.
- Land MF. Eye movements and the control of actions in everyday life. *Prog Retin Eye Res* 2006; 25: 296–324.
- Leff AP, Crewes H, Plant GT, Scott SK, Kennard C, Wise RJ. The functional anatomy of single-word reading in patients with hemianopic and pure alexia. *Brain* 2001; 124: 510–21.
- Leff AP, Scott SK, Crewes H, Hodgson TL, Cowey A, Howard D, et al. Impaired reading in patients with right hemianopia. *Ann Neurol* 2000; 47: 171–8.
- Leff AP, Spitsyna G, Plant GT, Wise RJ. Structural anatomy of pure and hemianopic alexia. *J Neurol Neurosurg Psychiatry* 2006; 77: 1004–7.
- Levine DN, Calvanio R. A study of the visual defect in verbal alexia-simultanagnosia. *Brain* 1978; 101: 65–81.
- McCandliss BD, Cohen L, Dehaene S. The visual word form area: expertise for reading in the fusiform gyrus. *Trends Cogn Sci* 2003; 7: 293–9.
- McDonald SA, Spitsyna G, Shillcock RC, Wise RJ, Leff AP. Patients with hemianopic alexia adopt an inefficient eye movement strategy when reading text. *Brain* 2006; 129: 158–67.
- Mauthner L. *Gehirn und Auge*. Wiesbaden: Bergmann; 1881.
- Montant M, Behrmann M. Pure alexia. *Neurocase* 2000; 6: 265–94.
- Nitzberg Lott S, Friedman RB. Can treatment for pure alexia improve letter-by-letter reading speed without sacrificing accuracy? *Brain Lang* 1999; 67: 188–201.
- Price CJ, Devlin JT. The myth of the visual word form area. *Neuroimage* 2003; 19: 473–81.
- Radner W, Obermayer W, Richter-Mueksch S, Willinger U, Velikay-Parel M, Eisenwort B. The validity and reliability of short German sentences for measuring reading speed. *Graefes Arch Clin Exp Ophthalmol* 2002; 240: 461–7.
- Rapp B, Caramazza A. Spatially determined deficits in letter and word processing. *Cogn Neuropsychol* 1991; 8: 275–311.
- Rayner K. Eye movements in reading and information processing: 20 years of research. *Psychol Bull* 1998; 124: 372–422.
- Rayner K, Bertera JH. Reading without a fovea. *Science* 1979; 206: 468–9.
- Rayner K, Johnson RL. Letter-by-letter acquired dyslexia is due to the serial encoding of letters. *Psychol Sci* 2005; 16: 530–4.
- Reichle ED, Rayner K, Pollatsek A. The E-Z Reader model of eye movement control in reading: comparisons to other models. *Behav Brain Sci* 2003; 26: 445–526.
- Rorden C, Brett M. Stereotaxic display of brain lesions. *Behav Neurol* 2000; 12: 191–200.
- Rorden C, Karnath HO, Bonilha L. Improving lesion-symptom mapping. *J Cogn Neurosci* 2007; 19: 1081–8.
- Sakurai Y, Yagishita A, Goto Y, Ohtsu H, Mannen T. Fusiform type alexia: pure alexia for words in contrast to posterior occipital type pure alexia for letters. *J Neurol Sci* 2006; 247: 81–92.
- Schuett S, Heywood CA, Kentridge RW, Zihl J. The significance of visual information processing in reading: Insights from hemianopic dyslexia. *Neuropsychologia* 2008; 46: 2445–62.
- Seki K, Yajima M, Sugishita M. The efficacy of kinesthetic reading treatment for pure alexia. *Neuropsychologia* 1995; 33: 595–609.
- Shallice T, Warrington EK. Single and multiple component central dyslexic syndromes. In: Coltheart M, Patterson K, Marshall JC, editors. *Deep dyslexia*. Amsterdam: Elsevier; 1980. p. 119–48.
- Spitsyna GA, Wise RJ, McDonald SA, Plant GT, Kidd D, Crewes H, et al. Optokinetic therapy improves text reading in patients with hemianopic alexia: a controlled trial. *Neurology* 2007; 68: 1922–30.
- Temple CM. Developmental and acquired dyslexias. *Cortex* 2006; 42: 898–910.
- Trauzettel-Klosinski S, Brendler K. Eye movements in reading with hemianopic field defects: the significance of clinical parameters. *Graefes Arch Clin Exp Ophthalmol* 1998; 236: 91–102.
- Tsapkini K, Dimos O, Katsarou Z. Pure alexia without agraphia after a lesion at the right hemisphere: a case study. *Brain Lang* 2005; 95: 239–40.
- Tzourio-Mazoyer N, Landeau B, Papathanassiou D, Crivello F, Etard O, Delcroix N, et al. Automated anatomical labeling of activations in SPM using a macroscopic anatomical parcellation of the MNI MRI single-subject brain. *Neuroimage* 2002; 15: 273–89.
- Warrington EK, Langdon D. Spelling dyslexia: a deficit of the visual word-form. *J Neurol Neurosurg Psychiatry* 1994; 57: 211–6.
- Warrington EK, Shallice T. Word-form dyslexia. *Brain* 1980; 103: 99–112.
- Zihl J. Eye movement patterns in hemianopic dyslexia. *Brain* 1995; 118: 891–912.