

Zsolt Szucs-Farkas
Peter Vock

Image quality of supine chest radiographs: intra-individual comparison of computed radiography and low-dose linear-slit digital radiography

Received: 18 December 2008
Revised: 23 February 2009
Accepted: 13 March 2009
Published online: 5 May 2009
© European Society of Radiology 2009

Z. Szucs-Farkas (✉) · P. Vock
Department of Diagnostic,
Interventional and Paediatric Radiology,
Inselspital, Berne University Hospital
and University of Berne,
Freiburgstrasse 4,
Berne, 3010, Switzerland
e-mail: zsolt.szuecs@insel.ch
Fax: +41-31-6320570

Abstract The purpose of this retrospective study was to intra-individually compare the image quality of computed radiography (CR) and low-dose linear-slit digital radiography (LSDR) for supine chest radiographs. A total of 90 patients (28 female, 62 male; mean age, 55.1 years) imaged with CR and LSDR within a mean time interval of 2.8 days \pm 3.0 were included in this study. Two independent readers evaluated the image quality of CR and LSDR based on modified European Guidelines for Quality Criteria for chest X-ray. The Wilcoxon test was used to analyse differences between the techniques. The overall image quality of LSDR was significantly better than the

quality of CR (9.75 vs 8.16 of a maximum score of 10; $p < 0.001$). LSDR performed significantly better than CR for delineation of anatomical structures in the mediastinum and the retrocardiac lung ($p < 0.001$). CR was superior to LSDR for visually sharp delineation of the lung vessels and the thin linear structures in the lungs. We conclude that LSDR yields better image quality and may be more suitable for excluding significant pathological features of the chest in areas with high attenuation compared with CR.

Keywords Digital radiography · Computed radiography · Image quality · Chest X-ray

Introduction

Total-body digital radiography (DR) permits a comprehensive radiographic evaluation from the head to the lower extremities in about 13 s, without requiring the patient to be repeatedly moved and manipulated [1–3]. The method is based on enhanced linear-slit (or slot) scanning technology, which utilises solid-state X-ray detectors that nearly eliminate scattered radiation along the z-axis. This technology results in a high-quality two-dimensional radiographic image at substantially lower patient exposure relative to conventional radiography [4–8]. In this paper, the method will be referred to as linear-slit digital radiography (LSDR).

LSDR is most commonly used for rapid initial evaluation of trauma patients, such that instead of acquiring numerous conventional radiographs of various body parts, an anteroposterior (AP) and a lateral image of the whole

body is substituted [9]. This approach helps exclude major injuries or attracts attention to suspicious areas requiring more detailed imaging. Any part of the whole-body image can be enlarged and digitally enhanced for more accurate evaluation. For example, when analysing the chest, a common site for traumatic injuries, not only must fractures of the rib cage, thoracic spine and the shoulder girdle be excluded, but also the thoracic visceral organs have to be assessed. Important diagnoses that should be confidently identified or excluded are significant pleural effusion, pneumothorax, collection of gas in the soft tissues, consolidation and contusion of the lungs, and widening of the mediastinum.

Beyond trauma applications, there are further clinical areas in which LSDR, with its large field of view (FOV), may be beneficial. For example, patients with ventriculo-peritoneal shunts require repetitive imaging follow-ups to control the localisation and continuity of the shunt. In this

patient group, we routinely substitute four radiographs of the skull, the neck, the chest and the abdomen with a single LSDR procedure to reduce exposure. Other possible indications for LSDR are leg length measurements, assessment of the whole spine for deformities prior to orthopaedic surgery and evaluation the skeletal system in patients with diseases affecting several distant bones and joints, such as multiple cartilaginous exostosis.

The correct assessment of both trauma victims and patients with ventriculoperitoneal shunts requires chest images of high diagnostic quality. Until now, studies comparing quality of chest images with computed radiography (CR) and DR systems have analysed only erect images [10–12]. However, patients of both the groups described above often cannot stand, necessitating a supine radiograph. Supine chest X-rays often have limited quality because of difficulties with patient positioning, the lack of co-operation resulting in reduced lung volume and technical deficiencies caused by time pressure.

In this retrospective series, we used the European Guidelines on Quality Criteria [13], modified for supine radiographs, to intra-individually compare the quality of chest images extracted from magnified whole-body LSDR with CR of the chest.

Materials and methods

Patients

Our database was retrospectively searched for patients who had undergone both LSDR and supine chest CR within a 14-day time interval between July 2007 and June 2008. When more than one chest radiograph was acquired in the same patient within the 2-week period, the radiograph taken closest in time to the LSDR was used in the study. Erect chest radiographs were excluded from the investigation. The images of 90 patients (28 female, 62 male; mean age, 55.1 years; range, 17–88 years) were eligible for inclusion in the study. The mean time interval between LSDR and CR was 2.8 days \pm 3.0. The indication for LSDR was either suspected polytrauma (motor vehicle accident,

high-energy crash or fall in 69 patients) or follow-up of a ventriculoperitoneal shunt (21 patients). This retrospective study was performed according to the regulations of the institutional review board.

Imaging

The Lodox Statscan (Lodox Systems, North America, LLC, South Lyon, Mich.) Critical Imaging System was used to acquire supine AP images of the whole body in trauma patients and from the top of the skull to the symphysis in patients with ventriculoperitoneal shunts. This imaging unit contains a C-arm, which is moved in the longitudinal axis of the patient lying on the trolley. An X-ray tube emitting a low-dose, linearly collimated fan-beam is mounted at one end of the C-arm. Fixed at the other end of the C-arm is the X-ray detector, consisting of scintillator arrays measuring 60 μ m, optically linked to charge-coupled devices (CCDs). The variable spatial resolution can be selected at between 1.4 and 5.0 line pairs per millimetre (lp/mm). The achievable contrast resolution of 14 bits equals 16,000 grey levels in the image. The FOV can be selected up to a maximum of 180 \times 68 cm. Depending on the imaged body region, radiation exposure may be significantly smaller than from equivalent X-ray techniques [5, 14]. The patient size, ranging from paediatric to extra large, is selected by the technician on the user interface of the LSDR unit. All technical parameters, including tube energy and tube current time product, are adapted to the patient's body size using an algorithm designed by the manufacturer to keep patient exposure to a minimum and image quality at an optimum.

In our study, the tube voltage was typically between 100 and 120 kV with an automatically selected tube current of 125–200 mA. The C-arm velocity was set at 140 mm/s and the slit width at 0.4 mm, corresponding to a local exposure time of 2.86 ms. The spatial resolution chosen was 2.1 lp/mm with a corresponding pixel size of 240 μ m (Table 1).

The CR images were acquired with a Shimadzu MUX-100 H mobile X-ray unit (Shimadzu, Tokyo, Japan; focal

Table 1 Technical parameters used in typical patients for supine chest radiographs with CR and whole-body image with the LSDR unit. The mAs values for the LSDR system were calculated from the

tube current, the slot thickness (0.4 mm) and the table speed (140 mm/s) (*FDD* focus-detector distance)

	Conventional CR		LSDR			
	Medium	Large	Small/ paediatric	Medium	Large	Extra large
Patient size	Medium	Large	Small/ paediatric	Medium	Large	Extra large
Tube potential (kV)	80	85	80	100	110	120
mAs	2.0	3.2	0.457	0.357	0.457	0.571
(mA)			(160)	(125)	(160)	(200)
FDD (cm)	120	120	130	130	130	130
Resolution (lp/mm)	5	5	2.08	2.08	2.08	2.08

Table 2 European Guidelines on Quality Criteria for erect PA chest radiographs and the modified criteria used in the study for AP chest radiographs. Differences are highlighted in *bold* (*NA* not applicable)

European Guidelines on Quality Criteria for erect PA chest radiographs	Modified criteria for AP chest radiographs
Performed at full inspiration (as assessed by the position of the ribs above the diaphragm—either 6 anteriorly or 10 posteriorly) and with suspended respiration	NA
Symmetrical reproduction of the thorax as shown by the central position of the spinous process between the medial ends of the clavicles	Unchanged
Medial border of the scapulae to be outside the lung fields	NA
Reproduction of the whole rib cage above the diaphragm	Unchanged
Visually sharp reproduction of the vascular pattern in the whole lung, particularly the peripheral vessels	Unchanged
Visually sharp reproduction of the trachea and proximal bronchi	Unchanged
Visually sharp reproduction of the borders of the heart and aorta	Unchanged
Visually sharp reproduction of the diaphragm and lateral costophrenic angles	Unchanged
Visualisation of the retrocardiac lung and the mediastinum	Unchanged
Visualisation of the spine through the heart shadow	Unchanged
Small round details in the whole lung, including the retrocardiac areas: (1) high contrast: 0.7 mm diameter; (2) low contrast: 2 mm diameter	Round details in the whole lung, including the retrocardiac areas: (1) high contrast: 2 mm diameter; (2) low contrast: 6 mm diameter
Linear and reticular details out to the lung periphery: (1) high contrast: 0.3 mm in width; (2) low contrast: 2 mm in width	Unchanged

spot size, 0.7 mm; filtration, 2.5 mm Al) or with a stationary system containing a Philips Optimus 80 X-ray generator and an X-ray tube (Philips Medical Systems, Hamburg, Germany; focal spot size, 0.6 mm; filtration, 2 mm Al). The 35×43-cm storage phosphor cassettes, corresponding to 2,140×1,760 pixels, were placed posterior to the patient lying supine with no anti-scatter grid used during exposure. Tube energy for CR was selected according to the patient size and typically ranged between 80 and 85 kV. The tube current time product ranged between 2.0 and 3.2 mAs. Image information was extracted by a dedicated CR laser reader (Fuji FCR Profect CS Fujifilm Medical, Tokyo, Japan).

All images were stored in a picture archiving and communication system (PACS).

Image evaluation

For the purpose of this study, the European Guidelines for Quality Criteria [15], originally developed for erect postero-anterior (PA) chest radiography, were modified for supine AP chest radiography (Table 2). The criteria that analyse full inspiration and the position of the scapulae are specific for the erect position and thus were omitted. Furthermore, we assumed that the visualisation of small

structures in supine radiographs would be inferior to that of erect chest X-rays. Thus, according to Sandborg et al. [12], the size threshold for rounded structures that needed to be visualised in the lung periphery was elevated from 0.7–2 mm to 2–6 mm and the threshold for linear and reticular structures remained at 0.3–2 mm.

Two board-certified radiologists with professional experience of 32 and 13 years independently rated all criteria for both CR and LSDR images as fulfilled (score 1), partially fulfilled (score 0.5) or not fulfilled (score 0). The sum of the scores was calculated to obtain the overall image quality. Image analysis was performed in a side-by-side manner using two high-definition LCD monitors (ME355i2, Totoku Electric, Japan), which simultaneously displayed the CR and the magnified LSDR images of the same patient. The readers were aware of the techniques based on the image characteristics. Image post-processing, including magnification and adjustment of brightness and contrast, was allowed during the reading session.

Statistical analysis

Statistical analysis was performed with the Statistica 7 software package (StatSoft, Tulsa, Okla.) and MedCalc

software (MedCalc, Mariakerke, Belgium). A p value of less than 0.05 was considered significant. All quality criteria and the total quality score of LSDR and CR were compared using the Wilcoxon matched pairs test. Inter-observer agreement was assessed by computing the kappa value for overall image quality. Agreement between the readers was graded as follows: <0.20 poor, 0.21–0.40 fair, 0.41–0.60 moderate, 0.61–0.80 good, 0.81–1.00 very good.

Results

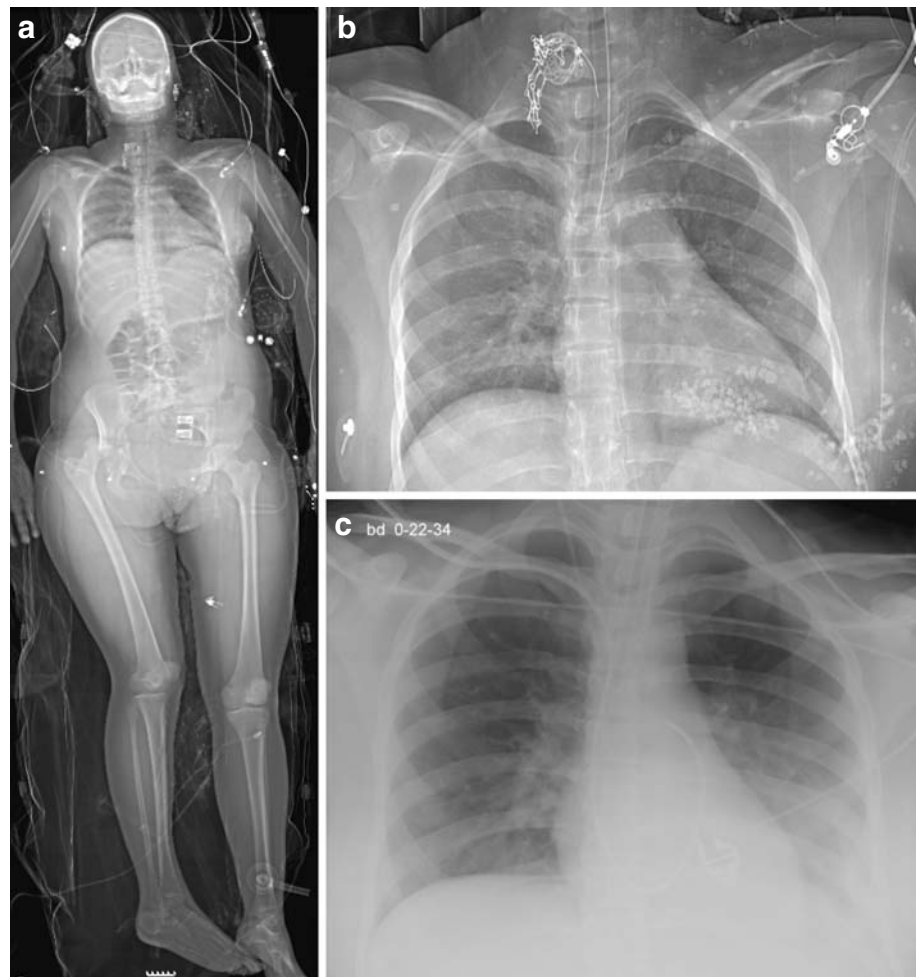
The overall image quality (i.e. total score) of LSDR was significantly better than CR ($p < 0.001$) (Table 3). Not only were the retrocardiac lung, the mediastinum and the thoracic spine better visualised by LSDR than CR, but also the heart, the aorta and the trachea with the main bronchi were more sharply depicted ($p < 0.001$ for all criteria) (Fig. 1). On the other hand, sharp visual reproduction of the lung vessels and the thin linear and reticular structures was rated higher in CR than LSDR (Fig. 2). There was no significant difference between

the techniques in respect to symmetrical reproduction of the chest and the delineation of small round details in the lungs ($p > 0.1$). The whole chest was more often reproduced and the diaphragm with the costophrenic angles was more often visualised by LSDR compared with CR (Fig. 3). The inter-observer agreement for overall image quality was good (kappa=0.63).

Discussion

Conventional supine chest radiography has played a very important part in the initial evaluation of trauma patients for decades. Even in the era of widely available CT systems, rapid initial exclusion of significant diseases requiring urgent intervention must be performed. Large-scale radiographs obtained by linear slit-scanning systems can substitute for multiple conventional X-ray images and have the potential to reduce both the overall imaging time and radiation exposure [16]. However, the quality and usability of those images must be proven in clinical studies. As for other body regions, good image quality is a

Fig. 1 **a** Whole-body LSDR of a 17-year-old female patient with symphysiolytosis, acetabular fracture and dislocation of the femur on the right side after motor vehicle accident. **b** Image retrieved by magnification of image **a**. Compared with the CR image (**c**) taken 8 h later, the visibility of the retrocardiac lung, the left hemidiaphragm and the thoracic spine is clearly better with LSDR. The patient's clothes contained glass splinters at the time of the LSDR, which are no longer visible on the CR image



prerequisite for the recognition or exclusion of diseases in the chest. We are not aware of any investigations into the quality of chest images acquired with linear slit digital radiographic systems. Furthermore, the image quality of supine chest radiographs with CR and DR systems has not been studied either. In the current retrospective series, we intra-individually compared the image quality of supine chest radiographs acquired by CR and LSDR.

As the population studied with erect chest radiographs is quite different from that undergoing a supine chest X-ray, we compared LSDR with supine CR images. We found a superior overall quality of LSDR compared with CR. The possible reasons for this finding are the different imaging methods and detector systems. It has been already reported that DR systems using flat-panel detectors obtain the same image quality at lower patient exposure compared with CR systems because of the higher detective quantum efficiency of the flat-panel detector [10, 11]. Those studies clearly demonstrated that anatomic structures in the high attenuation areas (i.e. mediastinum and retrocardiac areas) are significantly better delineated with DR compared with the CR technique. Furthermore, the X-ray source-detector

configuration used in linear slit technology is significantly different from that used in conventional DR systems [6, 7]. The linear detector of the LSDR unit virtually eliminates scattered X-ray photons in the z-axis, which results in images with higher contrast. This high contrast is particularly advantageous in high attenuation areas of the chest, which are hallmarked by the overlapping soft tissue structures and bones. Finally, the LSDR system uses a post-processing program that digitally enhances the raw images. These technical innovations result in superb soft tissue contrast and simultaneous good delineation of bony structures over a large FOV with low patient exposure.

Thus, it is not surprising that LSDR performed significantly better for all quality criteria analysing the soft tissue contrast on chest radiographs, such as the delineation of the air-filled trachea and the main bronchi in the mediastinum, the depiction of the descending aorta superimposed on the heart, and the visibility of the retrocardiac lung and mediastinum. Visualisation of the diaphragm and the costophrenic angles is significantly hampered in the presence of pleural effusion and lung

Fig. 2 A 12-year-old male patient after a motor-vehicle accident. **b** Image extracted from the magnified full-body LSDR (**a**). The CR image (**c**) was taken 6 h after image **b**. Although the thoracic spine and the retrocardiac lung are better visualised with LSDR, the hilar vessels and thin linear details in the lung parenchyma are more clearly delineated on the CR image

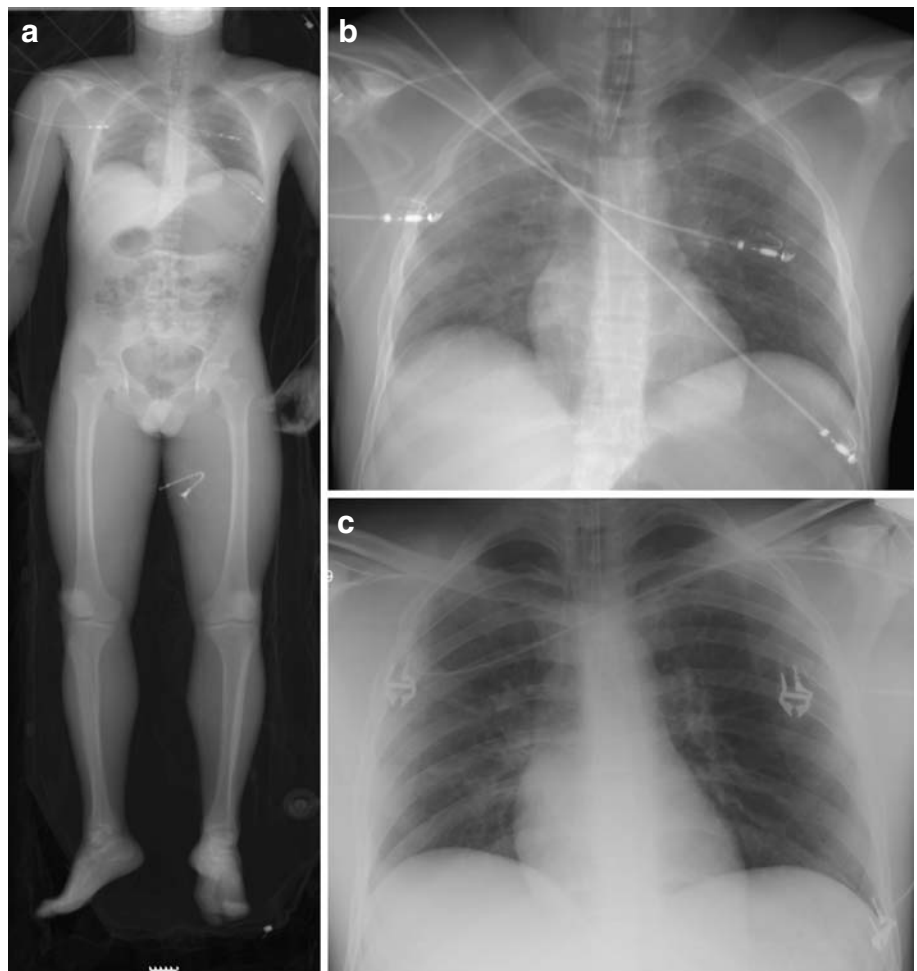
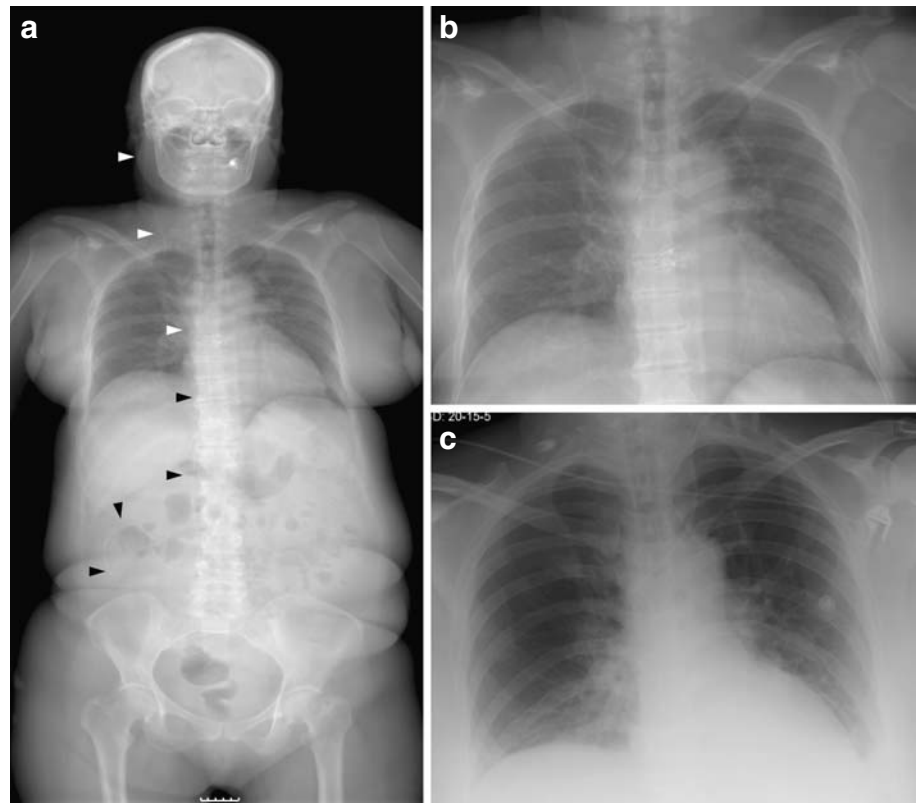


Fig. 3 **a** Follow-up LSDR of a 53-year-old female patient with subarachnoid haemorrhage treated by aneurysm clipping and ventriculoperitoneal shunt (*arrowheads*). The magnified LSDR image (**b**) allows a clear delineation of the spine and shows the retrocardiac lung and left hemidiaphragm better than the preoperative supine CR of the chest (**c**)



collapse, which are often seen after motor vehicle accidents. For these tasks, LSDR was also superior to CR.

The major drawback of the LSDR unit when used for whole body scanning is its lower spatial resolution, by a

factor of almost $\times 2.5$, compared with the CR system. Because of this difference, CR performed significantly better than LSDR with regard to the sharp delineation of the pulmonary vessels and details of small linear structures

Table 3 Summary of quality criteria assessed for supine chest radiographs using CR and a low-dose LSDR on 90 patients. All ratings were done by two independent readers as criteria fulfilled (score 1), partially fulfilled (score 0.5) or not fulfilled (score 0). The

right-most column contains the *p* values calculated by the Wilcoxon matched pairs test. For better visualisation, significantly higher means and medians along with the 95% confidence interval (CI) are highlighted in *italics* (NS non-significant)

Quality criteria	CR			LSDR			<i>p</i>
	Mean	Median	95% CI	Mean	Median	95% CI	
Symmetrical reproduction of the thorax	0.978	1.0	(0.75; 1.0)	0.958	1.0	(0.5; 1.0)	0.155; NS
Reproduction of the whole rib cage	0.950	1.0	(0.5; 1.0)	<i>0.997</i>	<i>1.0</i>	<i>(1.0; 1.0)</i>	0.018
Visually sharp reproduction of the lung vessels out to the lung periphery	<i>0.978</i>	<i>1.0</i>	<i>(0.75; 1.0)</i>	0.928	1.0	(0.5; 1.0)	0.002
Visually sharp reproduction of the trachea and proximal bronchi	0.567	0.50	(0.25; 1.0)	<i>0.950</i>	<i>1.0</i>	<i>(0.5; 1.0)</i>	<0.001
Visually sharp reproduction of the heart and aorta	0.797	0.88	(0.5; 1.0)	<i>0.931</i>	<i>1.0</i>	<i>(0.5; 1.0)</i>	<0.001
Visually sharp reproduction of the diaphragm and lateral costophrenic angles	0.928	1.0	(0.5; 1.0)	<i>1.0</i>	<i>1.0</i>	<i>(1.0; 1.0)</i>	<0.001
Visualisation of the retrocardiac lung and mediastinum	0.467	0.50	(0; 1.0)	<i>0.881</i>	<i>1.0</i>	<i>(0.5; 1.0)</i>	<0.001
Visualisation of the spine through the heart shadow	0.544	0.50	(0; 1.0)	<i>0.958</i>	<i>1.0</i>	<i>(0.75; 1.0)</i>	<0.001
Round details measuring 2–6 mm in the whole lung, including the retrocardiac areas	1.0	1.0	(1.0; 1.0)	0.992	1.0	(1.0; 1.0)	0.109; NS
Linear and reticular details 0.3–2 mm out to the lung periphery	<i>0.950</i>	<i>1.0</i>	<i>(0.75; 1.0)</i>	0.908	1.0	(0.75; 1.0)	0.010
Total score	8.158	8.25	(6.75; 9.25)	9.503	9.75	(8.5; 10.0)	<0.001

measuring 0.5–2 mm. The different pixel sizes of the two techniques did not influence the depiction of nodular structures measuring 2–6 mm. This finding corresponds to our experience that LSDR offers a superb depiction of ventriculoperitoneal shunts. Limited availability is a further drawback of the LSDR systems restricting their use mainly to large trauma centres.

There are some limitations of our study. First, we clearly focused on image quality criteria and not on the sensitivity or specificity of the techniques to detect thoracic diseases. Therefore, we did not correlate the LSDR and CR images with the result of CT examinations and clinical findings. A meticulous intra-individual analysis of the clinical value of LSDR compared with conventional radiography is required in future studies. Second, LSDR and CR images were not randomised for the evaluation, but simultaneously shown to the readers. This side-by-side comparison of the images allowed the readers to focus on important differences in quality criteria, which would not have been possible with a random reading order. Third, despite the short time interval between LSDR and CR in the same patient, chest diseases seen on the images were not identical in around one-third

of the cases. In some instances the pneumothorax or large pleural effusion detected on LSDR had been drained and was no longer visible on the follow-up CR image. Conversely, some patients developed lung atelectasis or pleural effusions after LSDR, which were depicted only on the CR image. However, LSDR and CR were affected by this phenomenon approximately at the same proportion. Fourth, a direct comparison of patient exposure with the two techniques was not possible, as the FOV of CR was confined solely to the chest, whereas LSDR comprised multiple body regions with various X-ray transmittances. Therefore, exposure for the chest cannot be simply calculated from the dose area product for the whole scan, as reported by the LSDR unit. The potential of LSDR for dose reduction compared with conventional techniques is especially striking for abdominal or whole-body applications [5, 8].

We conclude that LSDR yields better overall image quality and might be more capable of diagnosing significant chest diseases than supine CR radiographs in areas with high attenuation. We urge a randomised clinical study using CT as the “gold standard” to justify this assumption.

References

- Douglas TS, Sanders V, Pitcher R, van As AB (2008) Early detection of fractures with low-dose digital X-ray images in a pediatric trauma unit. *J Trauma* 65(1):E4–E7
- Lodox Homepage <http://www.lodox.com/html/specs.html> Last updated: November 27, 2007
- Mulligan ME, Flye CW (2006) Initial experience with Lodox Statscan imaging system for detecting injuries of the pelvis and appendicular skeleton. *Emerg Radiol* 13:129–133
- Pitcher RD, van As AB, Sanders V, Douglas TS, Wieselthaler N, Vlok A, Pavard S, Kilborn T, Rode H, Potgieter H, Beningfield SJ (2008) A pilot study evaluating the “STATSCAN” digital X-ray machine in paediatric polytrauma. *Emerg Radiol* 15:35–42
- Maree GJ, Irving BJ, Hering ER (2007) Paediatric dose measurement in a full-body digital radiography unit. *Pediatr Radiol* 37:990–997
- Samei E, Saunders RS, Lo JY, Dobbins JT 3rd, Jesneck JL, Floyd CE, Ravin CE (2004) Fundamental imaging characteristics of a slot-scan digital chest radiographic system. *Med Phys* 31:2687–2698
- McAdams HP, Samei E, Dobbins J 3rd, Tourassi GD, Ravin CE (2006) Recent advances in chest radiography. *Radiology* 241:663–683
- Irving BJ, Maree GJ, Hering ER, Douglas TS (2008) Radiation dose from a linear slit scanning X-ray machine with full-body imaging capabilities. *Radiat Prot Dosimetry* 130:482–489
- Boffard KD, Goosen J, Plani F, Degiannis E, Potgieter H (2006) The use of low dosage X-ray (Lodox/Statscan) in major trauma: comparison between low dose X-ray and conventional x-ray techniques. *J Trauma* 60:1175–1181 discussion 1181–1173
- Gruber M, Uffmann M, Weber M, Prokop M, Balassy C, Schaefer-Prokop C (2006) Direct detector radiography versus dual reading computed radiography: feasibility of dose reduction in chest radiography. *Eur Radiol* 16:1544–1550
- Bacher K, Smeets P, Bonnarens K, De Hauwere A, Verstraete K, Thierens H (2003) Dose reduction in patients undergoing chest imaging: digital amorphous silicon flat-panel detector radiography versus conventional film-screen radiography and phosphor-based computed radiography. *AJR Am J Roentgenol* 181:923–929
- Sandborg M, Tingberg A, Dance DR, Lanhede B, Almen A, McVey G, Sund P, Kheddache S, Besjakov J, Mattsson S, Mansson LG, Alm Carlsson G (2001) Demonstration of correlations between clinical and physical image quality measures in chest and lumbar spine screen-film radiography. *Br J Radiol* 74:520–528
- European guidelines on quality criteria for diagnostic radiographic images (1996). In: EUR 16260 EN. European Commission, Brussels
- Irving BJ, Maree GJ, Hering ER, Douglas TS (2007) Radiation dose from a linear slit scanning x-ray machine with full body imaging capabilities. *Radiat Prot Dosimetry* 0:1–5
- Quality Criteria for Diagnostic Radiographic Images (1990). In: Working Document XII/173/90. Commission of the European Communities (CEC), Brussels
- Exadaktylos AK, Benneker LM, Jeger V, Martinolli L, Bonel HM, Egli S, Potgieter H, Zimmermann H (2008) Total-body digital X-ray in trauma. An experience report on the first operational full body scanner in Europe and its possible role in ATLS. *Injury* 39:525–529