

Arch Orthop Trauma Surg (2009) 129:1691–1700
DOI 10.1007/s00402-009-0977-7

ORTHOPAEDIC OUTCOME ASSESSMENT

Second-generation uncemented stems: excellent 5–13-year results

Moritz Tannast · Timo M. Ecker · Stephen B. Murphy

Received: 13 November 2008 / Published online: 17 October 2009
© Springer-Verlag 2009

Abstract

Introduction The purpose of this study was to prospectively evaluate the 5–13-year results of a cementless total hip arthroplasty with a special focus on the survivorship, occurrence of osteolysis, incidence of intraoperative femoral fractures, thigh pain, and cortical hypertrophy of the femoral stem. The femoral component used in this study was titanium fluted, slotted, symmetrical component that was prepared with intraoperative machining. The proximal third of the stem had hydroxyl-apatite coating and horizontal steps.

Methods The clinical and radiographical results of a consecutive series of 157 total hip arthroplasties (124 patients) with this stem were investigated. Minimum follow-up was 5 years. The average age of the patients at the time of surgery was 47 years. Three patients died and ten patients were lost to follow-up, leaving 142 hips for evaluation. The clinical result was evaluated on the basis of the Merle d'Aubigné score, complications and thigh pain. A detailed radiographic analysis was performed at each follow-up visit. Kaplan–Meier survivorship analysis was performed to evaluate stem, cup, and bearing survivorship.

Results The mean follow-up was 8.5 years (range 5–13 years). The average Merle d'Aubigné score improved from

10.5 points preoperatively to 17.4 points postoperatively. The cumulative 10-year survival rate was 99% for the femoral component, 99% for the acetabular component, and 69% for the bearing. Thigh pain was identified in three patients (2%). There was no distal femoral osteolysis. Seventy-nine percent of all the hips had endosteal spot welds around the coated, proximal one-third of the prosthesis. 51% had radiodense lines around the distal tip of the prosthesis, and 3% had cortical hypertrophy. One undersized stem and one cup were revised for aseptic loosening, and 25 bearings were exchanged.

Conclusions Uncemented, machined, fluted titanium canal-filling femoral components achieve reliable fixation in this young patient population. They have a decreased incidence of activity-related thigh pain, lower rate of intraoperative femur fractures and cortical hypertrophy with comparable bone-ingrowth in comparison to other second-generation uncemented femoral components described in literature. Bearing wear and the need for bearing exchange was the only limitation of these constructs.

Keywords Total hip arthroplasty · Cementless · Stem · Long-term results

Electronic supplementary material The online version of this article (doi:10.1007/s00402-009-0977-7) contains supplementary material, which is available to authorized users.

M. Tannast · T. M. Ecker · S. B. Murphy
Center for Computer Assisted and Reconstructive Surgery,
New England Baptist Hospital,
Tufts University School of Medicine, Boston, MA, USA

M. Tannast (✉) · T. M. Ecker
Department of Orthopaedic Surgery, Inselspital,
University of Bern, Murtenstrasse, 3010 Bern, Switzerland
e-mail: moritz.tannast@insel.ch

Abbreviation

THA Total hip arthroplasty
HA Hydroxyl-apatite
PE Polyethylene

Introduction

Cementless fixation techniques in total hip arthroplasty (THA) are increasingly used worldwide, particularly in younger and more active patients [1, 19, 41]. Uncemented

femoral components were designed to decrease failure rates due to aseptic loosening, which were found to be the most common long-term complication of cemented stems [2, 24]. However, first generation of cementless femoral components fell short of expectations because they were associated with intraoperative femoral fractures, high incidence of postoperative thigh pain, stress shielding, subsidence, early loosening, and endosteolysis [4–6, 11, 14, 15, 21, 29, 32, 37, 47].

Based on these early experiences, an intraoperatively machined, proximally load bearing, coronally slotted, hydroxyl-apatite (HA)-coated titanium stem with horizontal metaphyseal steps was developed to address these problems. The HA coating is covering the stepped surface of the proximal sleeve. The combination of coating and textured surface is engineered to provide optimized fit and to enhance more natural compressive load bearing.

Preliminary results of an initial series of the first 64 operations with this stem were published in a previous report [40]. In contrast to other reports of so-called ‘second-generation’ stems impacted with a broach-only technique, no intraoperative femur fractures occurred. No cases of activity-related thigh pain were observed at 1 year, and all stems osseointegrated fully without signs of osteolysis in the distal part of the stem.

The purpose of this prospective study was to assess 10-year implant survival rates, clinical outcomes, and radiographic results in a consecutive series of patients treated with this second-generation stem. First, we hypothesized that the new design of the stem leads to a higher long-term survival rate in comparison to first-generation stems and to a comparable survivorship with other second-generation stems. The second hypothesis was that this particular stem has a decreased incidence of activity-related thigh pain, lower rate of intraoperative femur fractures and cortical hypertrophy with comparable bone-ingrowth in comparison to other second-generation uncemented femoral components described in the literature.

Materials and methods

Patient demographics

We prospectively followed 157 consecutive primary total hip arthroplasties with a second-generation cementless stem in 124 patients with a special focus on intraoperative complications, long-term clinical outcome with survivorship, and radiographic analysis. The results were compared with the results of other first- and second-generation cementless femoral components described in literature.

All procedures were performed by the senior author (SBM) between July 1992 and October 1999. The study

group included 59 men and 65 women. The average age (and SD) of the patients at the time of surgery was 46.9 ± 10.5 years (range 22.9–70.1). The mean height was 170 ± 9 cm (range 145–195), the mean weight was 82 ± 20 kg (range 45–134), and the mean body mass index was 27.9 ± 5.5 kg m⁻² (range 18.3–41.2). Eighty-three right hips and 74 left hips were involved. The preoperative diagnoses were typical for this age range (Table 1). Thirty-eight of the 157 hips (24%) had previous surgery (Table 2).

Operative technique

Total hip arthroplasty was performed through a modified direct lateral approach in 150 hips (95.5%), through a trochanteric slide exposure in 6 hips (3.8%) and through a vastus slide exposure in 1 patient (0.6%). The modified direct lateral approach is basically a classical transgluteal approach in lateral decubitus position. The modification consisted of the elevation of an additional thin bony wafer of the anterior part of the greater trochanter. The trochanteric slide exposure consists of a trochanteric osteotomy where the vastus lateralis fascia distally and the Mm. gluteus medius and minimus proximally are connected to the

Table 1 Preoperative diagnosis of the 157 hips included in the study

Underlying disease	Number of hips (%)
Osteoarthritis	60 (38)
Dysplasia	53 (34)
Avascular necrosis	14 (9)
Posttraumatic osteoarthritis	10 (6)
Slipped capital femoral epiphysis	5 (3)
Legg–Calvé–Perthes disease	5 (3)
Cerebral palsy	3 (2)
Spondyloarthropathy	2 (1)
Rheumatoid arthritis	2 (1)
Other	3 (2)

Table 2 Details of the 38 patients with previous surgical interventions

Previous surgical intervention	Hips (n)
Pelvic and/or femoral osteotomies	17
Open reduction and internal fixation	5
Hemiarthroplasties	3
Fibular allografts	3
Surgical hip dislocations	2
Arthroscopies	2
Excisions (synovial cyst, osteochondroma)	2
Pinning slipped capital femoral epiphysis	1
Arthrotomy	1
Multiple femoral/pelvic surgeries in childhood	2

trochanteric osteotomy. The vastus slide approach is a transgluteal exposure above the vastus tubercle and it becomes a lateral exposure of the femur below the vastus tubercle without trochanteric osteotomy. The quadriceps is then connected to the anterior part of the transgluteal approach.

The femoral component consisted of titanium, cylindrical, symmetric, slotted, fluted design with proximal HA coating (50 μm) (Stability femoral component, DePuy Orthopaedics, AJ&J Company, Warsaw, IN, USA) [40]. The stem is a further development of the S-ROM concept. It is prepared using a cylindrical diaphyseal reamer, a conical metaphyseal reamer, an angled drill for preparation of the calcar region, and a final broach.

The acetabular component consisted of a spherical titanium shell with porous coating of two manufacturers (Duraloc, DePuy, A J&J Company, Warsaw, IN, USA). 143 acetabular components had no screw holes (100 series), 11 had up to 3 screw holes (6 Bantam series, 5 Sector series), and 3 had 8–12 screw holes (1200 series). A polyethylene (PE) bearing surface was used for all hips. Early in the series, a Hylamer PE liner was used in 36 hips prior to December 1994; thereafter, an Enduron PE was implanted in 103. Beginning in December 1998, a highly cross-linked PE Marathon liner was implanted in 18 hips. Seventy-one hips had a Zirconia ceramic femoral head, 57 had an Alumina ceramic femoral head and 29 hips a cobalt–chrome femoral head. Implant information is summarized in Table 3.

Follow-up evaluation

Three patients (3 hips, 2%) had died from unrelated causes 2.1, 2.5 and 5.3 years postoperatively. Ten patients (12 hips, 8%) were lost to follow-up. Thus, the status of 142 of the original 157 hips (111 patients, 90%) was known at the last follow-up examination. The mean duration of follow-up was 8.5 years (range 5–13 years). Ninety-five patients (124 hips, 87%) were evaluated both clinically and radiographically. The remaining 16 patients (18 hips) were unable to return for a clinical evaluation for reasons not related to the result of the arthroplasty, and they were evaluated on the basis of a telephone interview only. In this interview, patients were asked predefined questions from a questionnaire described later to assess their hip function.

Patients were assessed preoperatively; at 6 and 12 weeks; and annually thereafter, if possible. The minimal follow-up was set at 5 years. At each visit, patients were asked to fill out a standardized and validated hip questionnaire [25, 28] including information about severity and location of pain, especially emphasizing occurrence of thigh pain, and their functional status. All the patients were clinically examined by the operating surgeon. Those who were unable to return were interviewed by telephone and

Table 3 Implant information

Implant information	Number used
Head size	
22	9
26	46
28	100
32	2
Cup size	
44	1
46	3
48	12
50	11
52	32
54	35
56	36
58	23
60	2
62	2
Head material	
Cobalt–chrome	29
Ceramic (Zirconia)	71
Ceramic (Alumina)	57
Liners	
Hylamer PE	36
Enduron PE	103
Cross-linked Marathon PE	18

Total number $n = 157$

PE polyethylene

asked to have radiographs taken locally and then sent to us. Members of the families of the patients who had died were interviewed to determine the function of the hip at the time of death. Clinical outcome was rated according to the Merle d'Aubigné Score [38]. Clinical results were then classified as excellent (18 points), very good (17 points), good (16 points), fair (15 points), and poor (14 points or less). All complications related to the hip arthroplasty were reported and divided into three categories (intraoperative, perioperative, and postoperative).

Radiographic evaluation

Serial anteroposterior, lateral, and false profile radiographs of the pelvis were analyzed by a second independent observer (MT) who was blinded to the clinical outcome of the corresponding patients. Prosthetic component orientation was measured with the use of a caliper for which a mean reliability and reproducibility of $<1^\circ$ for the acetabular component and could be found [26]. Because cup version cannot be reliably measured on anteroposterior pelvic radiographs, only cup abduction was measured with the

inter teardrop line as a horizontal reference [45]. Stem position (varus, valgus, or neutral alignment) was established as the angle formed by the intersection of a line drawn through the longitudinal axis of the proximal part of the femoral canal and a line drawn through the longitudinal axis of the stem [34].

The locations of the radiographic findings of the femur were recorded using of the Gruen zones (Fig. 1) and of the acetabulum using the DeLee and Charnley zones [12, 18]. The following standard set of radiographic parameters was assessed: femoral cancellous densification (so-called endosteal spots) was identified by a qualitative increase in bone density anywhere between the implant and the femoral cortex [15]. Radiodense lines were indicated by a thin radiopaque layer of bone seen parallel, and in close proximity to the implant and covering at least 50% of the zone length [8]. Cortical hypertrophy was defined as an increase in the outer diameter of the cortex [23, 34]. Radiolucency was defined as a radiolucent zone anywhere around the implant at least 2-mm-wide, and covering at least 30% of any zone [23]. Calcar re-modeling was classified as hypertrophy if there was a densification of the proximal femoral osteotomy side and as atrophy if there was a visible loss of trabecular bone density [22]. Heterotopic ossifications were graded with the Brooker classification [7]. Vertical subsidence was defined as a minimum 5 mm change of the distance from the superolateral edge of the stem to the tip of the greater trochanter between the immediately postoperative and the latest anteroposterior radiograph [44]. Osteolysis was defined as bone resorption, with a visible loss of trabecular bone density or cortical thinning. Peritrochanteric osteolysis was defined as osteolysis in the greater trochanteric region cranial to zone 1. Retroacetabular osteolysis was judged on the false profile view. Because it

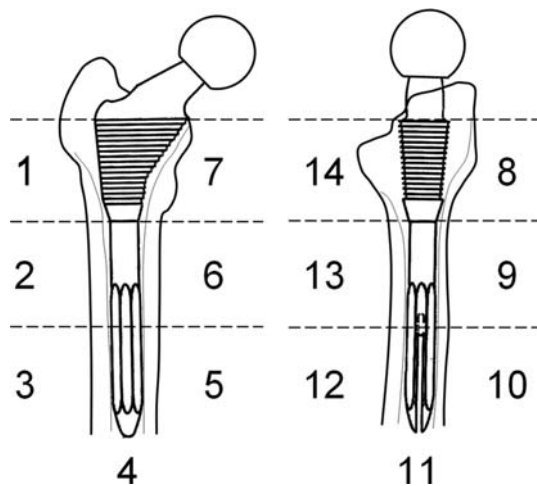


Fig. 1 The radiographic zones for the investigated stem according to Gruen are shown [18]

could be shown that the radiographic interpretation of femoral components can be made with substantial reliability and reproducibility [31], no such analysis was performed.

Statistical analysis

Kaplan–Meier survivorship analysis was performed to determine the cumulative survival rate for the each component with revision for each component as the end point [27]. Normal distribution was determined with the Kolmogorov–Smirnov test. Paired and unpaired student's *t* tests were used for comparison of normally distributed data. The Wilcoxon rank sum and the Mann–Whitney *U* tests were used when comparing paired and non-paired data without normal distribution. To assess associations between categorical variables, Fisher's exact test was performed. Significance was defined as a *p* value of <0.05.

Results

Clinical evaluation

Merle d'Aubigné score of the 115 non-revised hips improved from 10.5 preoperatively (range 5–14) to 17.4 (range 12–18) at the 5–12-year follow-up (Table 4, $p < 0.0001$). Among the seven patients with a poor result, three patients had persistent pain (one of them with Grade 3 heterotopic ossification), one patient had deficit in the range of motion and three other patients needed walking support at the time of latest follow-up.

Four of the 137 non-stem-revised hips (2.9%) were related with thigh pain. Two patients had mild thigh pain that occurred predominantly with prolonged activity and which required medication occasionally. One patient had moderate and another severe pain that occurred with all activities and required regular pain medication. None of these three patients had clinical or radiographic signs of stem loosening. We did not observe a specific time-dependent pattern for the occurrence of thigh pain.

Complications

Among the eight major complications (Table 5), there were one intraoperative, two perioperative, and five postoperative complications without a case of intraoperative femur fracture, deep infection, nerve palsy, or diagnosis of deep venous thrombosis. One of the postoperative dislocations occurred 4.7 years postoperatively and underwent closed reduction without further intervention. The other patient with postoperative dislocation, who had postoperatively lost 45 kg of weight after gastric bypass, sustained four dislocations beginning 35 months after surgery. This patient

Table 4 Summary of the clinical and radiographical results

Parameter	Number (%)
Postoperative Merle d'Aubigné score	
Excellent (%)	79 (69)
Very good (%)	22 (19)
Good (%)	4 (3)
Fair (%)	3 (3)
Poor (%)	7 (6)
Number of hips with thigh pain (%)	4 (2.9)
Mean cup abduction	41.5° ± 6.4° (28–64)
Stem alignment	
Neutral	105 (83)
Varus	7 (6)
Valgus	13 (10)
New cortical hypertrophy	3 (2)
Subsidence >5 mm	1 (1)
Heterotopic ossifications	
Grade 0	94 (76)
Grade 1	20 (16)
Grade 2	3 (2)
Grade 3	7 (6)
Grade 4	0 (0)
Calcar reaction	1
No changes (%)	103 (82)
Atrophy (%)	16 (13)
Hypertrophy (%)	5 (4)
Peritrochanteric osteolysis	25 (20)
Retroacetabular osteolysis	16 (13)

Table 5 List of complications

Category	Number
Intraoperative	
Iliac vein laceration	1
Perioperative	
Superficial wound infection	1
Seizure due to bupivacaine toxicity	1
Postoperative	
Dislocations	2
Greater trochanteric fracture	2
Periprosthetic fracture	1

required revision with a lipped liner 4.1 years after initial surgery and had remained stable. Among the two patients with postoperative greater trochanteric fractures, one occurred in the postoperative rehabilitation requiring internal fixation 3 weeks after the initial surgery. The second was an incomplete fracture of the greater trochanter after fall 1.9 years postoperatively and was successfully treated

conservatively. One patient had a periprosthetic diaphyseal fracture after trauma 9.2 years after THA and underwent internal fixation. The fracture healed uneventfully without revision of the femoral component.

Radiographic results

A characteristic pattern of bone-ingrowth of the femoral component was seen (Tables 6, 7); with 107 of the hips (86%) having endosteal spot welds in Gruen zones 1, 7, or 8. These circumscribed areas of stress transfer are typically located at the junction between the conical and the straight portion of the femoral component. Sixty-three hips (51%) had radiodense lines around the distal tip of the prosthesis (zones 3–5 or 10–12). There was no endosteolysis in any of the diaphyseal zones (zones 2–6, or zones 9–13). Radiolucent lines in zone 1 were only located around the stem shoulder and did not continue to the distal part of this zone. Cups with one single dome hole demonstrated lysis only in zone II. The incidence of femoral cortical hypertrophy was 6% (8 hips). Five of the eight patients had previous femoral osteotomies with pre-existing hypertrophic changes. Two femurs with correct alignment showed isolated hypertrophy in zones 5 and 2, respectively. One femur in varus orientation showed isolated hypertrophy in zone 5.

Revisions

There were 1 stem revision, 1 metal shell revision and 25 exchanges of the PE bearing. The bearing exchanges (15 Hylamer, 10 Enduron PE liners) were performed for polyethylene wear associated with progressive retroacetabular or peritrochanteric osteolysis. The number of bearing exchanges was significantly higher for the Hylamer PE liners (Table 8). One hip had a combined revision of the liner and the loosened metal shell. This hip had a broken locking mechanism and part of the broken locking ring migrated into the articulation. There was resulting wear and the cup was found to be loose at surgery. Mean time to revision was 7.9 ± 2.3 years (range 2.2–12.5). In all, 25 hips that had a revision of the acetabular component (polyethylene liner and metal shell), the stem was clinically, radiographically and intraoperatively fully stable. Revision of the polyethylene liner was correlated with increased head diameter, but not with younger age, abduction outliers, sex, side, height, weight, body mass index, stem alignment, cup diameter, or previous operations (Table 8).

One patient had an undersized femoral component that failed to osseointegrate. He had a painless fibrous interface, which became painful more than 2 years after the surgery and was revised 3.1 years postoperatively.

Table 6 Radiographic findings on the anteroposterior radiographs of 123 of the non-revised femora

Parameter	Number of hips (%)													
	Zone 1	Zone 2	Zone 3	Zone 4	Zone 5	Zone 6	Zone 7	Zone 8	Zone 9	Zone 10	Zone 11	Zone 12	Zone 13	Zone 14
Radiolucent lines	17 (14)	0 (0)	0 (0)	0 (0)	0 (0)	0 (0)	2 (2)	7 (6)	0 (0)	0 (0)	0 (0)	0 (0)	0 (0)	0 (0)
Radiodense lines	0 (0)	10 (8)	8 (6)	32 (26)	10 (8)	18 (14)	1 (1)	4 (3)	7 (6)	18 (14)	47 (38)	19 (15)	6 (5)	5 (4)
Endosteal spots	87 (70)	5 (4)	0 (0)	1 (1)	0 (0)	4 (3)	77 (62)	54 (43)	2 (2)	0 (0)	0 (0)	0 (0)	0 (0)	12 (10)
Cortical hypertrophy	1 (1)	6 (5)	1 (1)	0 (0)	3 (2)	1 (1)	0 (0)	0 (0)	1 (1)	0 (0)	0 (0)	0 (0)	1 (1)	0 (0)

Table 7 Radiographic findings of the 99 non-revised sockets

Parameter	Zone 1 (%)	Zone 2 (%)	Zone 3 (%)
Osteolysis/radiolucent lines	2 (1)	10 (10)	1 (1)
Radiodense lines	8 (8)	0 (0)	2 (2)

Survivorship

With the revision of the each component as the end point, the cumulative survival rate was 99% for the stem (95% confidence interval, 98–100%), 99% for the metal shell (97–100%), and 69% for the liner (57–82.0%) at 10 years (Fig. 2).

Discussion

To our knowledge, this is the first report on the intermediate to long-term results of this specific intraoperatively machined second-generation femoral component which had been designed to address the specific problems of first-

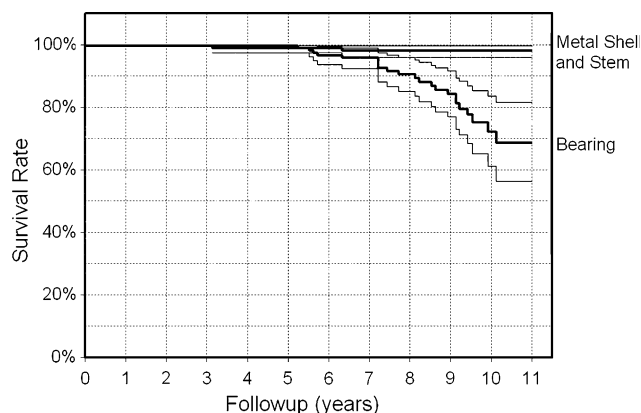


Fig. 2 A Kaplan–Meier survivorship analysis shows a 99% rate of cup and stem survival, and a 69% rate for bearings with revision of the components as endpoint

generation cementless femoral implants. As we first hypothesized in the introduction, the cumulative 10-year survivorship of the investigated femoral component exceeds the results of first-generation stems and compares favorably to the survivorship of other second-generation stems (Table 9). In addition, our results support the second

Table 8 Factors associated with accelerated polyethylene liner wear and bearing exchanges

Parameter	Bearing exchange (n = 25)	No bearing exchange (n = 117)	p value
Age at surgery (years)	44.4 ± 8.0 (30.4–61.6)	48 ± 10.6 (25.1–70.1)	0.121
Hips with previous operation (%)	3 (12)	33 (28)	0.069
Men patients (%)	14 (56)	52 (44)	0.202
Right side hips (%)	15 (60)	59 (50)	0.258
Abduction outliers (<30° or >50°) (%)	5 (20)	11 (9)	0.962
Height (cm)	172 ± 11 (147–195)	170 ± 9 (145–183)	0.302
Weight (kg)	85 ± 27 (51–134)	81 ± 17 (45–120)	0.413
Body mass index (kg m ⁻²)	28.1 ± 7.0 (18–41)	28.1 ± 5.0 (18–38)	0.994
Stem malalignment (% varus/valgus)	4 (16)	16 (16)	0.671
Head diameter ≥28 mm (%)	20 (80)	65 (52)	0.018
Cup diameter ≥54 mm (%)	15 (60)	63 (54)	0.368
Hips with Hylamer PE (%)	15 (60)	17 (15)	<0.0001
Hips with Enduron PE (%)	10 (40)	89 (76)	<0.0001

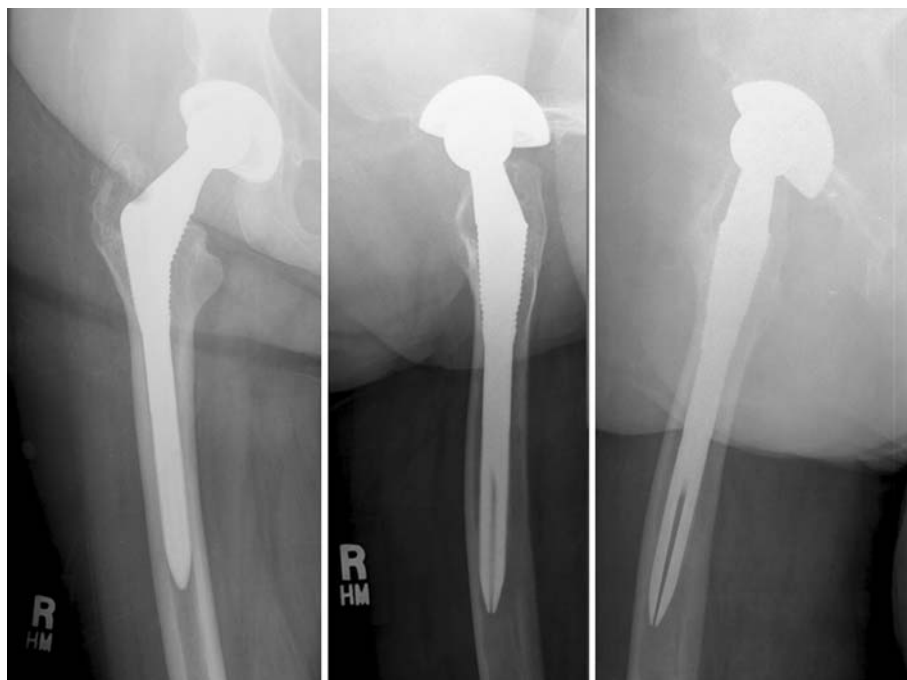PE polyethylene

Table 9 Comparison of outcome results of first- and second-generation cementless femoral components in total hip arthroplasty

References	No. of hips	Mean fu (years)	Lost to fu	Stem	Intraoperatively machined	Stem material	Intraoperative femur fracture	Thigh pain	Subsidence	Distal femoral osteolysis	Stem loosening	Cumulative 10-year survival rate (95% CI)	Calcar rounding	Cortical hypertrophy
First-generation stems														
Kim and Kim [30]	50	7 (7–7.4)	10%	Anatomic medullary locking (DePuy)	No	Cobalt–chrome	13%	21%	No data	58%	6%	No data	No data	No data
Duffy et al. [13]	82	10.3 (10–14)	0%	Porous coated anatomic (PCA); Harris Galante I porous, osteonics	No	No data	6%	No data	No data	No data	12%	84.9% (77–94)	No data	No data
Götze et al. [16]	137	12.8 (10.1–14.9)	15.4%	Lübeck prosthesis	No	Cobalt–chrome	2.9%	No data	30%	No data	5.1%	86.2% (14.9 years fu)	27%	Evident
Kim et al. [31]	65	12.5 (10–16)	5%	Harris Galante I	No	Titanium	No data	9%	No data	18%	13.8%	80% (74–86, 15 years)	No data	12.3%
Mallory et al. [33]	177	6.3 (0.6–8.5)	No data	Mallory–head porous femoral component (Biomet)	Yes	Titanium	No data	11%	<1 mm (0–2.2 mm)	No data	2.8%	94% (86–100, 8 years)	No data	11%
Grappiolo et al. [17]	300	12.6 (10–16)	1.6%	CLS prosthesis	No	Titanium	3.3%	No data	2.8%	Evident	1%	95.3 (92.8–97.8)	No data	No data
Siebold et al. [42]	298	11.7 (10.2–14)	10.8%	CLC prosthesis	No	Titanium	10.7%	0.3%	No data	No data	2.0%	93.7% (12.3 years)	No data	No data
Clobisny and Harris [10]	88	10.6 (7–12.9)	1.1%	Harris Galante I	No	Titanium	No data	No data	No data	52%	19%	82% (72–90)	No data	No data
Second-generation stems														
Sinha et al. [43]	123	6.5 (5–9.6)	0%	Harris Galante multilock (Zimmer)	No	Titanium	1.6%	11%	0.7 mm (–1.7–2.7)	No	0.8%	97% (94–100)	86%	29%
Kim et al. [30]	118	9.8 (8–11)	0%	Anatomic profile (DuPuy)	No	Titanium	8%	10%	No	No	No	100% (93–100)	Evident	25%
Archibeck et al. [3]	85	10 (8–11)	8.2%	Anatomic (Zimmer)	No	Titanium	4%	9%	No	No	No	100%	97%	74%
Meding et al. [36]	105	10.4	3.8	BiMetric (Biomet)	No	Titanium	No data	2%	1%	No	No	100%	No data	83%
Mont et al. [39]	109	6 (5–7)	0%	PCA-E stem (Howmedica)	No	Cobalt–chrome	5%	6%	No data	No	2%	No data	100%	No data
Christie et al. [9]	159	5.3 (4–7.8)	13.9%	Modular system (S-ROM, DePuy)	Yes	Titanium	1.8%	6%	1.8%	No	0.6%	No data	98%	31%
Harris et al. [20]	107	8.4 (5–10.5)	7%	APR-II (Zimmer)	No	Titanium	No data	No data	No data	No	No	100%	31%	No data
Mazoochian et al. [35]	10	7	0%	CR-stem (Implantcast)	No data	Titanium	0%	No data	2.23 mm (1–4.2)	No data	No data	No data	No data	No data
Van der Wal et al. [46]	64	6.3 (5–6.8)	0%	ABG II (Stryker)	No	Titanium	0%	15.6%	2%	No	No data	No data	34.4%	9.4%
Current study	157	8.6 (5–13)	8%	Stability (DePuy)	Yes	Titanium	0%	2.9%	0.6%	No	0.6%	99% (98–100)	82%	6%

fu followup

Fig. 3 The anteroposterior (a), lateral (b) and false profile (c) radiographs of 68-year-old patient 8 years after primary total hip prosthesis are shown. Although excessive polyethylene wear is visible, there is no evidence of osteolysis around the femoral or the acetabular component



hypothesis that states that the specific features of the described stem leads to an absence of intraoperative femoral fractures, a lower incidence of activity-related thigh pain and femoral hypertrophy in comparison to other second-generation stems (Table 9). The disadvantages of this second-generation hip prosthesis are the necessity of the additional machining of the metaphysis in comparison to the broaching-only technique. This requires further technical skills for the surgeon that can lead to an increased operation time.

There are several limitations to our study. All the patients have been clinically evaluated by the operating surgeon. This might have positively biased the results. However, important parameters assessed in this study such as the severity and location of pain (particularly thigh pain) were obtained directly from the patients' questionnaires. These were completed in the absence of the evaluating surgeon; also, the radiographic analysis was done by another observer independent from the surgeon which should minimize bias. Another weakness of this study is the mixture of acetabular shells, polyethylene liners, and femoral heads. The original study protocol did not include particular exclusion criteria concerning this. Therefore, the investigated stem was combined with different types of polyethylene bearings and/or femoral head materials according to the latest technical advancements in this area. Unexpectedly, a high rate of bearing exchanges due to accelerate wear was found for Hylamer PE. One reason for this might be that those patients had a higher follow-up. Therefore, this finding is not particularly significant. Nevertheless, after recognition of this fact, the utilization of this type of PE was

abandoned. From a theoretical point of view, the higher rate of wear could have negatively influenced the outcome of the investigated stem. However, no such difference could be observed in this series. The fact that this femoral component shows very reliable results despite being used with different bearing components rather reflects the quality of the investigated stem and does not jeopardize the results of our study. The stem survives with stability and can potentially serve as a barrier to PE debris and subsequent osteolysis (Fig. 3).

Our study documents that fluted titanium canal-filling femoral components routinely osseointegrate and can remain well fixed, even in a young patient population. Despite the significant wear of the retrieved polyethylene liners, none of the femoral components experienced distal osteolysis, suggesting that a circumferential seal between the implant and the femur might inhibit particulate debris migration (Table 6). This corresponds well with the long-term results of other proximally coated cementless stems (Table 9) and supports the conclusion that extensively coated femoral components are not necessary to achieve fixation or inhibit debris migration [3, 29, 33, 36, 40].

There are some technical differences between the investigated stem and the similar S-ROM design. The S-ROM stem is very smooth distally, polished really, and the tip of the stem is quite square, leading to more localized stress transfer at the tip. The evaluated stem has a chemically milled surface that facilitates osseointegration over a longer distance. Even if there is a proximal loading, there is osseointegration along the whole prosthesis. In addition, the stem tip of the investigated design is more bullet-shaped and this

tapered design leads to a better distribution of the stress transfer at the tip of the prosthesis. Besides, the slightly different definition of osseous hypertrophy and the older patient population for the S-ROM stem [9], this might explain the higher incidence of cortical hypertrophy and calcar rounding for the S-ROM prosthesis [9] (Table 9). Other parameters, such as thigh pain, the rate of intraoperative femur fractures and subsidence did not differ substantially (Table 9).

The one stem and one cup failure were clearly due to technical reasons. The one stem that failed to osseointegrate was undersized. The one cup that loosened occurred in association with a failed locking mechanism, hardware migrating to the articulation, and associated accelerated wear.

Being aware that other factors can influence the long-term survivorship in THA, the femoral stem evaluated in this study appears to offer a balance of proximal stability and reduction in distal bending stiffness which can be illustrated radiographically. Proximal stability could be visualized by the increase in bone density in the proximal Gruen zones (1, 7, 8, or 14) in 80% of all the cases as a sign for osseointegration. The distal radiodense lines around the tip of the prosthesis may be attributed to flexibility of the distal part of the prosthesis mainly due to the low modulus of elasticity of the titanium alloy and the coronal slot. Theoretically, a coronal slot should reduce the stem stiffness particularly with hip flexion which is confirmed by the fact that reactive radiodense lines were predominantly found on the lateral radiograph.

The 10-year cumulative survival rate compares favorably with the reports of so-called second-generation cementless femoral components in literature which rates from 97 to 100% [3, 29, 33, 36]. However, when comparing with these studies, the current study presents some additional findings. First, the absence of intraoperative femoral fractures in the present series is notable and may relate to careful preparation of the calcar region with the described intraoperative machining technique, eliminating the need for high-impact during preparation of the femur. In contrast, intraoperative femoral fractures associated with the broaching-only techniques were seen in up to 8% of recently published studies on cementless THA (Table 9). Second, the incidence of thigh pain of 2% is very low which may be explained by the combination of the slotted design in combination with titanium alloy. In other series with non-slotted stems, thigh pain was found up to 10% in cobalt–chromium and up to 11% in titanium stems [29, 40]. Third, cortical hypertrophy occurred only in three hips without previous femoral surgical intervention. This is considerably lower than the incidence of 29–83% of cortical hypertrophy in other studies [33, 40]. The low incidence of cortical hypertrophy suggests that the stresses are

transferred from the implant to the bone more proximally, eliminating high stress transfer in the diaphysis. This may be due to the metaphyseal geometry of the implant which also included horizontal steps which were designed to convert hip stresses to compressive stresses and confirms previous finite element analysis predictions [37].

In summary, uncemented intraoperatively machined fluted titanium canal-filling femoral components achieve reliable fixation. PE bearing wear and the need for bearing exchange was the only limitation of these constructs. Reduced wear with hard bearings or improved polyethylene bearings should be expected to further improve the results of total hip arthroplasty using these types of implants.

Acknowledgment One of the authors (MT) received personal funding from the Swiss National Science Foundation (SNSF).

References

- Allen AM, Ward WG, Haygood TM (1995) Imaging of the total hip arthroplasty. *J South Orthop Assoc* 4:96–123
- Anthony PP, Gie GA, Howie CR, Ling RS (1990) Localized endosteal bone lysis in relation to the femoral components of cemented total hip arthroplasties. *J Bone Joint Surg Br* 72:971–979
- Archibeck MJ, Berger RA, Jacobs JJ, Quigley LR, Gitelis S, Rosenberg A, Galante JO (2001) Second-generation cementless total hip arthroplasty. *J Bone Joint Surg Am* 83:1666–1673
- Barrack RL, Jasty M, Bragdon C, Haire T, Harris WH (1992) Thigh pain despite bone ingrowth into uncemented femoral stems. *J Bone Joint Surg Br* 74:507–510
- Bobyn JD, Mortimer ES, Glassmann AH, Engh CA, Miller JE, Brooks CE (1992) Producing and avoiding stress shielding: Laboratory and clinical observations of noncemented total hip arthroplasty. *Clin Orthop Relat Res* 274:79–96
- Bourne RB, Rorabeck CH, Ghazal ME, Lee MH (1994) Pain in the thigh following total hip replacement with a porous-coated anatomic prosthesis for osteoarthritis. A five-year follow-up study. *J Bone Joint Surg Am* 76:1464–1470
- Brooker AF, Bowerman JW, Robinson RA, Riley LH (1973) Ectopic ossification following total hip replacement. Incidence and a method of classification. *J Bone Joint Surg Am* 55:1629–1632
- Callaghan JJ, Dysart SH, Savory CG (1988) The uncemented porous-coated anatomic total hip prosthesis. Two-year results of a prospective component. *J Bone Joint Surg Am* 70:337–346
- Christie MJ, DeBoer DK, Trick LW, Brothers JC, Jones RE, Vise GT, Gruen TA (1999) Primary total hip arthroplasty with use of the modular S-ROM prosthesis. Four to seven-year clinical and radiographic results. *J Bone Joint Surg Am* 81:1707–1716
- Clohisy JC, Harris WH (1999) The Harris-Galante uncemented femoral component in primary total hip replacement at 10 years. *J Arthroplasty* 14:915–917
- D'Antonio JA, Capello WN, Jaffe WL (1992) Hydroxylapatite-coated hip implants. *Clin Orthop Relat Res* 285:102–115
- DeLee JG, Charnley J (1976) Radiological demarcation of cemented sockets in total hip replacement. *Clin Orthop Relat Res* 121:20–32
- Duffy GP, Berry DJ, Rowland C, Cabanela ME (2001) Primary uncemented total hip arthroplasty in patients <40 years old: 10- to 14-year results using first-generation proximally porous-coated implants. *J Arthroplasty* 16:140–144

14. Engh CA, Bobyn JD, Glassmann AH (1987) Porous-coated hip replacement: The factors governing bone ingrowth, stress shielding, and clinical results. *J Bone Joint Surg Br* 69:45–55
15. Fitzgerald RH Jr, Brindley GW, Kavanagh BF (1988) The uncemented total hip arthroplasty. Intraoperative femoral fractures. *Clin Orthop Relat Res* 235:61–66
16. Götze C, Tschugunow A, Götze HG, Bottner F, Potzl W, Gosheger G (2006) Long-term results of the metal-cancellous cementless Lubeck total hip arthroplasty: a critical review at 12.8 years. *Arch Orthop Trauma Surg* 126:28–35
17. Grappiolo G, Blaha JD, Gruen TA, Burastero G, Spotorno L (2002) Primary total hip arthroplasty using a grit-blasted, press-fit femoral prosthesis. Long term results with survivorship analysis. *Hip Intern* 12:55–72
18. Gruen TA, McNeice GM, Amstutz HC (1979) “Modes of failure” of cemented stem-type femoral components: a radiographic analysis of loosening. *Clin Orthop Relat Res* 141:17–27
19. Hardidge AJ, Hooper J, McMahon S (2003) Current attitudes to total hip replacement in younger patients: a comparison of two nations. *ANZ J Surg* 73:280–283
20. Harris M, Dorr LD, Wan Z, Sirianni L, Boutary M (2005) Total hip arthroplasty with the APR stem and cup follow-up of a previous report. *J Arthroplasty* 20:828–831
21. Havelin LI, Espehaug B, Vollset SE, Engesaeter LB (1995) Early aseptic loosening of uncemented femoral components in primary total hip replacement. A review based on the Norwegian Arthroplasty Register. *J Bone Joint Surg Br* 77:11–17
22. Hedley AK, Gruen TA, Borden LS, Hungerford DS, Habermann E, Kenna RV (1987) Two-year follow-up of the PCA noncemented total hip replacement. *Hip* 225–250
23. Herrera A, Canales V, Anderson J, Garcia-Araujo C, Murcia-Mazon A, Tonino AJ (2004) Seven to 10 years followup of an anatomic hip prosthesis: an international study. *Clin Orthop Relat Res* 423:129–137
24. Huddleston HD (1988) Femoral lysis after cemented hip arthroplasty. *J Arthroplasty* 3:285–297
25. Johnston RC, Fitzgerald RH, Harris WH, Poss R, Müller ME, Sledge CB (1990) Clinical and radiographic evaluation of total hip replacement. A standard system of terminology for reporting results. *J Bone Joint Surg Am* 72:161–168
26. Kalteis T, Handel M, Herold T, Perlick L, Paetzel C, Grifka J (2006) Position of the acetabular cup—accuracy of radiographic calculation compared to CT-based measurement. *Eur J Radiol* 58:294–300
27. Kaplan E, Meier P (1958) Nonparametric estimation from incomplete observations. *J Am Statist Assn* 53:457–481
28. Katz JN, Phillips CB, Poss R, Harrast JJ, Fossel AH, Liang MH, Sledge CB (1995) The validity and reliability of a total hip arthroplasty outcome evaluation questionnaire. *J Bone Joint Surg Am* 77:1528–1534
29. Kim YH, Kim VE (1993) Early migration of uncemented porous coated anatomic femoral component related to aseptic loosening. *Clin Orthop Relat Res* 295:146–155
30. Kim YH, Oh SH, Kim JS (2003) Primary total hip arthroplasty with a second-generation cementless total hip prosthesis in patients younger than fifty years of age. *J Bone Joint Surg Am* 85:109–114
31. Kim YG, Kim SY, Park BC, Kim PT, Ihn JC, Kim ID (2005) Uncemented Harris-Galante total hip arthroplasty in patients with osteonecrosis of the femoral head. A 10–16-year follow-up study. *Acta Orthop* 76:42–48
32. Kim YH, Kim VE (1994) Cementless porous-coated anatomic medullary locking total hip prostheses. *J Arthroplasty* 9:243–252
33. Mallory TH, Head WC, Lombardi AV, Emerson RH, Eberle RW, Mitchell MB (1996) Clinical and radiographic outcome of a cementless, titanium, plasma spray-coated total hip arthroplasty femoral component. Justification for continuance of use. *J Arthroplasty* 11:653–660
34. Martell JM, Pierson RH, Jacobs JJ, Rosenberg AG, Maley M, Galante JO (1993) Primary total hip reconstruction with a Titanium fiber-coated prosthesis inserted without cement. *J Bone Joint Surg Am* 75:554–571
35. Mazoochian F, Schrimpf FM, Kircher J, Mayer W, Hauptmann S, Fottner A, Müller PE, Pellengahr C, Jansson V (2007) Proximal loading of the femur leads to low subsidence rates: first clinical results of the CR-stem. *Arch Orthop Trauma Surg* 127:397–401
36. Meding JB, Keating EM, Ritter MA, Faris PM, Berend ME (2004) Minimum ten-year follow-up of a straight-stemmed, plasma-sprayed, titanium-alloy, uncemented femoral component in primary total hip arthroplasty. *J Bone Joint Surg Am* 86:92–97
37. Menon DK, McCreath SW (1999) 5- to 8-year results of the Freeman press-fit hip arthroplasty. *J Arthroplasty* 14:581–588
38. Merle d’Aubigné R, Postel M (1954) Functional results of hip arthroplasty with acrylic prosthesis. *J Bone Joint Surg Am* 36:451–475
39. Mont MA, Yoon TR, Krackow KA, Hungerford DS (1999) Clinical experience with a proximally porous-coated second-generation cementless total hip prosthesis. Minimum 5-year follow-up. *J Arthroplasty* 14:930–939
40. Murphy SB (1995) Design rationale for intraoperatively machined uncemented femoral components in total hip replacement. *Oper Techn Orthop* 5:331–335
41. Scheerlinck T, Druyts P, Casteleyn PP (2004) The use of primary total hip arthroplasty in university hospitals of the European Union. *Acta Orthop Belg* 70:231–239
42. Siebold R, Scheller G, Schreiner U, Jani L (2001) Long-term results with the cement-free Spotorno CLS shaft. *Orthopäde* 30:317–322 (In German)
43. Sinha RK, Dungy DS, Yeon HB (2004) Primary total hip arthroplasty with a proximally porous-coated femoral stem. *J Bone Joint Surg Am* 86:1254–1261
44. Sutherland CJ, Wilde AH, Borden LS, Marks KE (1982) A ten-year follow-up of one hundred consecutive Müller curved-stem total hip replacement arthroplasties. *J Bone Joint Surg Am* 64:970–982
45. Tannast M, Langlotz U, Siebenrock KA, Wiese M, Bernsmann K, Langlotz F (2005) Anatomic referencing of cup orientation in total hip arthroplasty. *Clin Orthop Relat Res* 436:144–150
46. Van der Wal BC, de Kramer BJ, Grimm B, Vencken W, Heyligers IC, Tonino AJ (2008) Femoral fit in ABG-II hip stems, influence on clinical outcome and bone remodeling: a radiographic study. *Arch Orthop Trauma Surg* 128:1065–1072
47. Xenos JS, Hopkinson WJ, Callaghan JJ, Heekin RD, Savory CG (1995) Osteolysis around an uncemented cobalt chrome total hip arthroplasty. *Clin Orthop Relat Res* 317:29