

Outcome analysis of breast reconstruction with free transverse rectus abdominis musculocutaneous (TRAM) flaps

Jacqueline Ziswiler-Gietz, Mary Makrodimou, Yves Harder, Andrej Banic, Dominique Erni

Department of Plastic and Hand Surgery, Inselspital, University of Berne, Switzerland

Summary

Questions under study: With the reduction in breast cancer mortality in recent years the aesthetic outcome after treatment has gained increasing attention. The aim of this study was to assess the outcome quality of our single institution concept of free TRAM flap breast reconstruction with the aim of providing data to assist the patient's decision-making when breast reconstruction is an option.

Principles/methods: Thirty-two consecutive patients receiving immediate (n = 14) or delayed (n = 18) breast reconstruction with free transverse rectus abdominis musculocutaneous (TRAM) flaps were included. The selection of patients was based on their own wish and the availability of abdominal tissue, without excluding patients at risk for wound healing complications. Patient data were assessed prospectively and the aesthetic outcome was rated after the final result had been achieved.

Results: Ten patients sustained wound healing complications (4 of 9 smokers, 8 of 16 patients with a BMI over 25 kg/m²), 8 of them requiring revisional surgery. An average of 1.06 corrective procedures were performed per patient. The aesthetic outcome was judged to be good by 20 patients, fair by 5 and poor by 1 patient who sustained severe tissue loss.

Conclusions: Our results revealed that a large measure of satisfaction is achievable from breast reconstruction with free TRAM flaps, in spite of the invasive nature of the procedure and the inclusion of patients at risk for wound healing complications. These data may be used in the decision-making process by patients eligible for breast reconstruction after mastectomy.

Key words: breast cancer; skin sparing mastectomy; autologous tissue; microsurgery; aesthetic outcome

Introduction

At present breast cancer accounts for the highest prevalence of malignant diseases in the female population of industrialised countries. In recent decades breast cancer mortality has been reduced thanks to advanced medical technologies, in particular sophisticated imaging techniques and refined therapeutic strategies. In line with this trend, increasing attention has been paid to the aesthetic outcome after treatment. Currently the primary goal is preservation of the affected breast, which can be offered to approximately 70% of patients [1, 2], whereas female integrity can be reestablished with breast reconstructive procedures if mastectomy is inevitable for medical reasons or if preferred by the patient. If metastatic disease has been ruled out immediate breast reconstruction at the time of the mastectomy is recommended, to avoid the psychological

trauma inflicted by the ablation [3, 4]. As much as possible of the skin envelope should be preserved, this being a prerequisite in obtaining the most natural shape and skin texture of the reconstructed breast [5]. Provided that proper surgical indications are respected, oncologic safety has been confirmed for both immediate breast reconstruction and skin sparing mastectomy [5-7].

Basically, the breast mound can be reconstructed with alloplastic (silicone) implants, the use of autologous flap tissue, or a combination of both. Most patients are reluctant to harbour foreign material in their bodies and thus opt for use of autologous tissue alone. Various parts of the body may serve as donor sites, such as the back [8, 9], the gluteal area [10, 11] and the abdominal wall [12]. Due to the general abundance of abdominal panniculus in the breast cancer popula-

tion, the quality and reliability of the anatomical blood supply and the aesthetic benefit at the donor site, the transverse rectus abdominis musculocutaneous (TRAM) flap has become the flap of choice for this purpose. The flap may be pedicled on the superior epigastric system, as first described by Hartrampf et al. in 1982 [12], or it may be raised as a free flap, pedicled on the inferior epigastric artery and vein, which are anastomosed to vessels at the recipient site to reestablish blood perfusion [13]. Because the flap tissue belongs to the vascular territory of the inferior epigastric system, the blood supply to the superiorly pedicled flap depends on the intramuscular arcading collaterals, whereas the free flap is perfused via its anatomical vascular axis. In addition, the resulting abdominal wall defect at the donor site is restricted to the infraumbilical area after free flap harvesting, whereas the entire rectus muscle serves as the flap pedicle if the flap is based superiorly.

For the above reasons, the free TRAM flap is the preferred method of breast reconstruction at our institution. Our concept consists in a two session approach, volume replacement being the goal of the first intervention and breast contouring that of the second, possibly combined with re-

construction of the nipple-areola complex (NAC). The drawback of this concept is its invasive nature, which may deter some patients from choosing it. Being faced with the diagnosis of breast cancer, selecting the therapeutic option that best fits the patient is overwhelming, particularly for immediate reconstruction. Besides the experienced plastic surgeon who should be involved in the primary planning of the therapeutic strategy, patients very often seek assistance in their decision-making process from their physicians and family doctors [1, 14]. It has been shown that long-term patient satisfaction depends largely on preoperative information on the upcoming procedure: a patient is much more ready to accept the burdens of surgery, with the attendant postoperative pain and discomfort, if she is aware of them beforehand [15]. On the other hand, many women regret the decision in the long run if reconstruction was refused [3].

The aim of this study was to assess the outcome quality of our single institution concept of free TRAM flap breast reconstruction, with the aim of providing data useful to the patient in her decision-making when breast reconstruction is an option.

Patients and methods

The study comprises a consecutive series of patients receiving a free TRAM flap for breast reconstruction at our institution between January 1998 and February 2003. The indication for mastectomy was set by the gynaecologist who transferred the patient to our department and was commonly based on the suggestions of a senology tumour board. The indication for breast reconstruction, both immediate and delayed, was determined by the patient's wish. Infiltration of the tumour into the skin or thoracic wall (pT4), palpable regional lymph nodes or systemic metastases were taken as exclusion criteria for immediate reconstruction, and the absence of any signs of recurrence documented in the routine staging procedure was required for delayed reconstruction. Prerequisites for selecting a TRAM flap included the availability of sufficient abdominal skin and fat tissue, the absence of median laparotomy scars and the patient's preference. There were no exclusion criteria with regard to risk factors.

All operations were performed in a two-team approach consisting of one surgical team working at the recipient site (mastectomy or resection of mastectomy scar, dissection of recipient vessels), and the other team dissecting the flap. In all immediate reconstructions, lymphadenectomy of level I and II was performed routinely. The skin envelope was left intact as far as possible, depending on where the tumour was located.

The flap design was marked on the upright patient on the preoperative day. The adipocutaneous part of the flap consisted of a horizontal spindle extended between the superior anterior iliac spines. The vertical amount of harvested skin and fat was determined by the amount of remaining skin allowing for direct closure after mobilisation of the cranial wound margin. The umbilicus was dissected free from the surrounding flap tissue and was reinserted into the mobilised cranial abdominal skin at its

original position. The flap was dissected free from the anterior rectus sheath by preserving the musculocutaneous perforator vessels nourishing the adipocutaneous flap components. The anterior rectus sheath was then sparingly incised around the perforator vessels. A cuff of rectus muscle surrounding the perforators was included in the flap, and the feeding deep epigastric artery and vein were dissected free until branching of the external iliac vessels, where they were transected. Approximately one third of the muscle circumference was always preserved. After harvesting of the flap, the anterior rectus sheath was duplicated and closed using two lines of nonabsorbable sutures and by avoiding the use of artificial meshes.

The flap was then brought to the recipient site, where it was revascularised by microsurgical arterial and venous anastomosis to the thoracodorsal vessels. Thereafter, the flap was shaped and adaptive reduction mammoplasty was performed according to patients' needs.

Postoperatively the flaps were monitored by clinical observation, temperature measurement and Doppler flowmetry, and 10% dextran 40 (B. Braun Medical AG, Emmenbrücke, Switzerland) was given at a rate of 50 ml per hour until postoperative day four to support microcirculatory blood flow in the flap. Ambulation and respiratory physiotherapy were initiated as soon as the patient was extubated. A tight bra and abdominal garment were prescribed in all patients for four and six weeks respectively.

The desired shape of the breast was commonly accomplished with a second procedure 6 to 9 months after flap surgery. In the immediate reconstruction cases the NAC was reconstituted by reimplanting the preserved original NAC a few days postoperatively, provided that no tumour infiltration was found in the histological sections

of the retroareolar tissue. In the other patients and in the secondary reconstructions the nipple was recreated using a local flap or by transplanting a part of the contralateral nipple or a piece of the labia minora, and the areola was tattooed.

The acquisition of data was in accordance with the guidelines of the Ethics Committee of the Canton of Berne and the informed consent of the patients. All patients were prospectively assessed for demographic data as well as preoperative surgical and medical interventions, including radiotherapy and chemotherapy. Postoperatively the patients were assessed for systemic complications, wound healing complications (total or partial flap failure, infections, haematoma, seroma) and patency of the abdominal wall at the donor site during the hospital stay and the regular follow-ups in the outpatient clinic.

Partial flap failure included skin and fat necrosis. The severity of the complication was validated according to the need and numbers of revisional surgery.

Final outcome was assessed at least six months after the last reconstructive step. The aesthetic result was evaluated by the patients themselves and by visual examination by two independent staff members whose scores were averaged. The aesthetic result was scored according to shape, symmetry, scars, NAC and overall impression, which were all checked for a possible relationship with primary/delayed reconstruction or contralateral breast reconstruction, smoking, overweight, wound healing complications and numbers of corrective procedures.

Comparative statistical analysis was not performed because randomisation was not given and the number of covariates was too large for the sample size.

Results

Patients' data: Thirty-two patients were included in this study. The patients' data are presented in table 1. The patients had a median age of 53 years and most were slightly overweight (median BMI of 26). Twenty-two patients (69%)

presented with one or more systemic risk factors (hypertension, diabetes mellitus, obesity, smoking), and 19 patients (59%) with a local risk factor (previous radiotherapy or abdominal surgery), whereas only 6 patients (19%) had no risk factor. Tumour size and stage were similar in both the immediate and delayed reconstruction group.

Surgery and hospitalisation: The reconstruction was unilateral in 29 patients and bilateral in 3 patients (table 2). One patient with large breasts received bilateral mastectomy and immediate reconstruction with a TRAM flap on one side and a musculocutaneous latissimus dorsi flap and a silicone prosthesis on the other. Fourteen patients received immediate reconstruction but reconstruction was delayed in the other 18. Ten patients underwent simultaneous reduction mammoplasty to achieve symmetrical breast size and ptosis, and in another 8 patients this was accomplished during a secondary adaptive procedure. The original NAC was reimplanted in 4 immediate reconstruction patients, the nipple alone in another 7 cases. Tattooing of the areola was performed in 23 patients, whereas 3 patients refused NAC reconstruction and the original NAC was preserved in the 2 subcutaneous mastectomy patients. One patient required revision of the arterial anastomosis intraoperatively while all other flaps healed without any thrombotic event at the site of the microsurgical anastomosis. The median operative time was 7 h and the median hospital stay 11 days. The duration of the hospital stay was not influenced by the length of the surgical procedure. There were no systemic complications such as thromboembolism, pneumonia, or acute cardiovascular events. An average of 1.06 procedures were performed per patient to correct the shape of the reconstructed breast with or without adaptive surgery on the contralateral healthy side at a later stage (33 operations).

Wound healing complications and donor site morbidity: Ten patients had wound healing complications in the reconstructed breast, out of whom

Table 1

Patients' data (n = 32 patients), range (median).

Age	35–68 (53)
BMI (kg/m ²)	20–39 (26)
Systemic risk factors	27
Arterial hypertension	1
Diabetes mellitus	1
Obesity (BMI >25)	16
Smoking	9
Local risk factors	19
Preoperative radiotherapy	2
Previous abdominal surgery	17
Indication for mastectomy	
Proliferative mastopathy	3
In situ carcinoma	2
Invasive carcinoma	27
T1	9
T2	13
T3	2
T4	1
Unknown	2

Table 2

Surgery and hospitalisation (n = 32 patients), range (median). The values for operative time are rounded to 2 significant digits.

	n	Operative time (min)	Hospitalisation (days)
Immediate unilateral reconstruction			
With contralateral mammoplasty	2	410–540 (470)	10–11 (11)
Without contralateral mammoplasty	11	300–610 (400)	7–14 (11)
Delayed unilateral reconstruction			
With contralateral mammoplasty	8	320–480 (430)	5–20 (11)
Without contralateral mammoplasty	8	260–540 (390)	7–13 (10)
Bilateral reconstruction	3	500–660 (520)	10–14 (11)

Table 3

Complications in reconstructed breast (recipient site, flap) and at abdominal donor site (n = 32 patients). The wound healing complications healed spontaneously (n = 2) or required surgical revision (n = 8).

	Total	Spontaneous healing	Surgical revision
Recipient site			
Skin necrosis	2	1	1
Infection	1	0	1
Seroma	1	0	1
Flap			
Total flap loss	0		
Partial tissue loss	5	1	4
Fat necrosis	1	0	1
Donor site			
Hernia	0		
Bulging	2	0	1
Seroma	1	0	1

8 required surgical revision (table 3). Microcirculatory impairment led to tissue necrosis in the wound margins of the original breast skin in 2 patients (14% of immediate reconstructions) with subsequent lack of ptosis, and to partial flap failure in 5 cases (15%), out of which 4 (12% of flaps) required surgical debridement and 1 healed spontaneously. One minor fat necrosis was biopsied 8 months postoperatively. Wound healing complications occurred in 4 of the 9 smokers (44%) and in 8 of the 16 overweight patients (50%), whereas none of the 10 patients with a BMI below 24 suffered partial flap necrosis. A similar rate of wound healing complications was observed in immediate and delayed reconstructions. Three surgical revisions were necessary at the abdominal donor site

due to persistent seroma or bulging. Abdominal bulging was seen in the two patients undergoing bilateral reconstructions. It was preexistent in one patient and related to flap harvesting in the other. No abdominal hernia occurred.

Aesthetic assessment: One patient died as a result of the disease during the observation period, and 5 failed to show up for the final assessment due to a severe wound healing complication (1) or for logistic reasons (4). The final outcome analysis of the remaining 26 patients was performed 10 to 51 (median 27.5) months after TRAM flap surgery. From the surgeon's point of view, 18 (69%) of the reconstructed breasts were judged to be good, 7 (27%) fair and 1 (4%) poor, although symmetry was considered to be achieved in only 53% of the unilateral breast reconstructions (fig. 1). The patients were even slightly more pleased with the aesthetic outcome: 20 (77%) rated the outcome as good, 5 (20%) as fair and 1 (4%) as poor. The one poor result was attributable to a major loss of original breast skin resulting in extensive scar formation and distortion of the breast. However, there was no meaningful correlation between the surgeons' or patients' evaluation of any type of procedure or predictive risk factors except that primary reconstructions tended to produce better scars. All but the dissatisfied patient would recommend the procedure to a friend and spoke of improved self-esteem due to the fact that their breast had been reconstructed in the present manner.

Discussion

Breast reconstruction with autologous tissue is a constant battle between vascularisation of the transplanted flap, donor site morbidity and aesthetic aspects, all of this taking place within the framework of oncological requirements which take absolute priority. Oncological safety was not the subject of this study and has been widely confirmed for all procedures included in the present concept [6, 7].

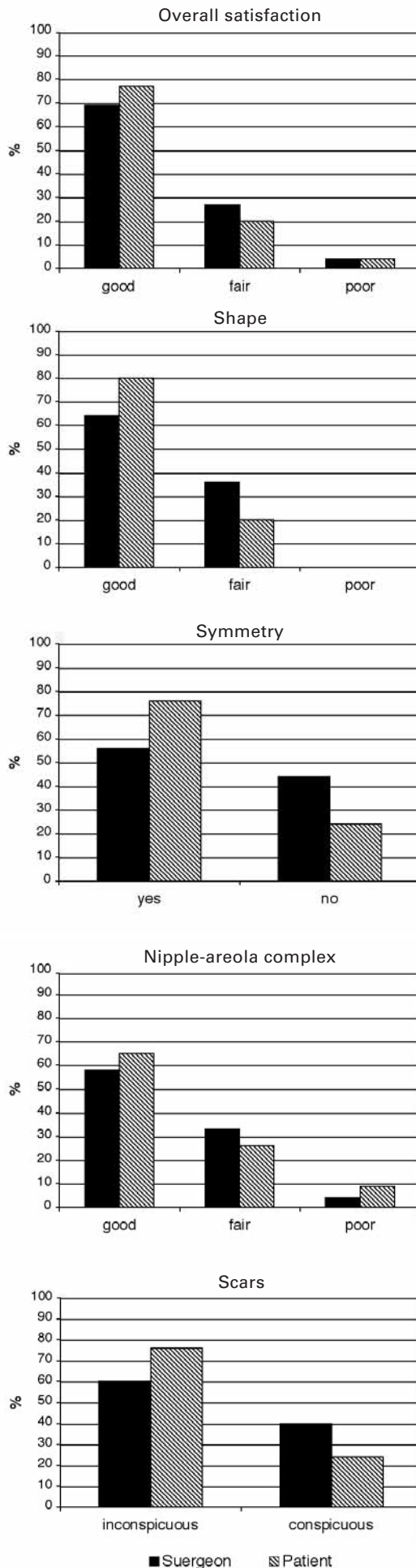
Impaired vascularisation is the main source of wound healing complications at the site of the reconstructed breast since it may eventually lead to ischaemic necrosis. Besides prolonging the treatment and necessitating repeated surgical corrections, ischaemia-related necrosis may seriously jeopardise the aesthetic outcome once a certain amount of tissue is affected, as demonstrated by the one poor result in this study. The preserved original breast skin is particularly susceptible to ischaemic tissue loss if additional incisions are performed to reduce excessive skin [5], and they have therefore been omitted in our recent cases. Another area at risk is the flap tissue on the contralateral side of the vascular pedicle, as shown in the five patients undergoing partial flap loss in our

series. Such complications can be avoided if the contralateral flap portions are discarded. However, this may limit the possibility of achieving symmetrical breast size and is therefore contrary to our therapeutic concept. In addition, our results suggest that ischaemia-related wound healing complications are increased by smoking and overweight, as confirmed in the largest published series of free TRAM flap reconstructions [16–20].

The worst vascular complication consists in total loss of the transplanted flap tissue due to thrombosis of the microvascular anastomoses, a scenario that did not occur in our series and has become very rare in the hands of experienced microsurgeons [16, 19]. Total flap loss may be circumvented if the flap is transferred in a pedicled manner, where the blood supply is provided by the superior epigastric vessels passing through the superior parts of the rectus muscle serving as the flap pedicle, as originally described [12]. However, because this is not the axial anatomical blood supply to the transplanted infraumbilical flap tissue, it increases the risk of critical ischaemia in the contralateral flap tissue and the subsequent above-mentioned complications [21].

Figure 1

Surgeon's and patient's evaluation of the aesthetic outcome after breast reconstruction with TRAM flaps (n = 26, median follow-up 27.5 months).



Another major factor in favour of free flap transfer is that the donor site defect can be restricted to the lower abdomen. Long-term donor site morbidity is characterised by herniation or bulging of the abdominal wall. No hernias occurred in our series, but one patient developed surgery-related abdominal bulging after bilateral flap harvest. Abdominal wall instability has been thought to correlate with the size of the abdominal wall defect [22–24], which provided the impetus for the development of the deep inferior epigastric perforator (DIEP) flap [25]. With this technique the entire rectus abdominis muscle is left in place, a position which can be achieved by dissecting 1 to 3 nourishing perforators out of the muscle. However, with our refined fascia- and muscle-sparing dissection technique [26] we were able to reduce abdominal wall instability to the level of DIEP flaps [27, 28] without the use of alloplastic material.

Overall satisfaction with the final result was high among the surgeons, and even slightly higher among the patients, as frequently reported in aesthetic outcome studies [4, 9, 29]. While accepting the result represents an important step in working up the psychological impact of the disease for the patient, the surgeon tends to have a critical attitude towards his work in terms of striving for betterment. Although similar patient satisfaction can be achieved with implants with or without additional soft tissue reconstructions [3, 9, 15], approximately half of those patients may require additional surgery in the long term due to prosthesis dislocation, capsular contraction or implant rupture [9], whereas the natural appearance after TRAM flap reconstruction remains unaffected once it is in place. Most interestingly, in some comparative outcome assessment studies [4, 29, 30] breast reconstruction with autologous tissue yielded similar or even greater patient satisfaction than breast conserving surgery in terms of health-related quality of life and cosmetic outcome, whereas the patients' body image scores were significantly lower and regrets at their decision keener in patients undergoing mastectomy without reconstruction [3, 4]. Considering that cosmesis and satisfaction after breast conserving surgery correlates with the percentage of breast volume excised [31], this may shift the decision towards mastectomy and immediate reconstruction with autologous tissue in cases of high tumour-to-breast volume ratio.

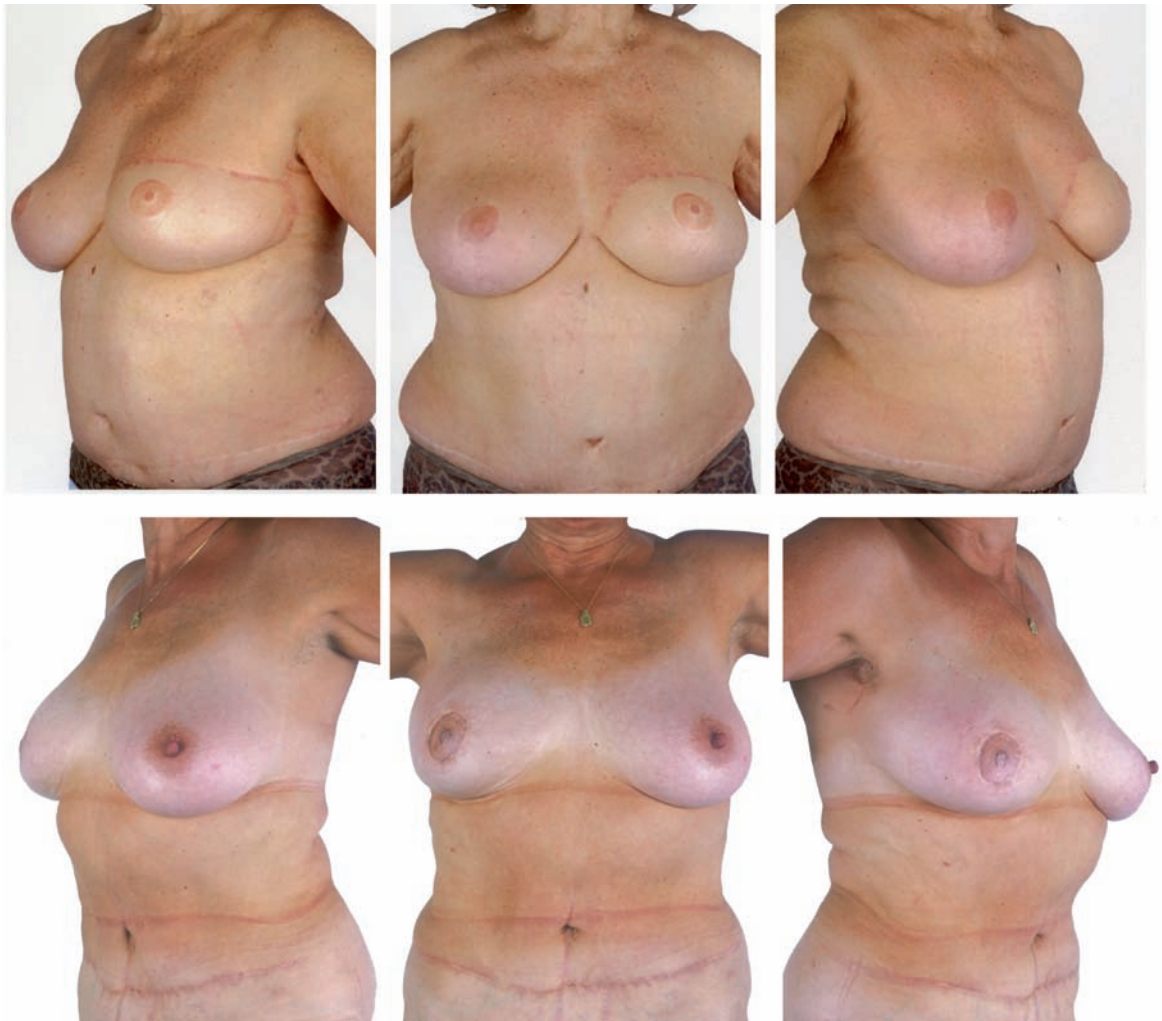The aesthetic outcome is determined by the shape, size and symmetry of the reconstruction as well as scars and the appearance of the NAC. All these factors can be markedly improved with the skin sparing mastectomy technique (fig. 2): the original skin texture and colour are maintained, the envelope provides a natural breast shape, and the scars can be hidden around the natural aesthetic borderline between breast skin and NAC. Although skin sparing mastectomy is normally restricted to patients receiving immediate breast

Figure 2**Delayed reconstruction (above).**

Sixty-seven year old patient 12 months after delayed breast reconstruction with free TRAM flap and contralateral breast reduction, and 8 months after NAC reconstruction with nipple-share from the healthy side and tattooing of the areola.

Immediate reconstruction (below).

Sixty-four year old patient 13 months after skin sparing mastectomy and immediate breast reconstruction with TRAM flap, nipple reconstruction with reimplantation of the original nipple and areola tattooing. Skin sparing mastectomy maintains the natural shape, texture and colour of the breast and provides inconspicuous scars placed in the natural aesthetic borderline defining the circumference of the areola. The scar at the abdominal donor site is hidden by the underwear in both patients.



reconstruction, it can also be applied if the reconstruction has to be delayed, eg due to adjuvant radiotherapy, which may jeopardise the aesthetic outcome after immediate reconstruction. In this scenario, we recommend inserting a breast implant as a filler to maintain the shape of the breast skin envelope until the definitive reconstruction can be performed.

We conclude that a high satisfaction rate and a good and permanent aesthetic outcome were obtained with breast reconstruction with autologous abdominal tissue, although repetitive, partly invasive surgical procedures were required and a relatively high rate of ischaemia-related wound healing complications occurred. This justifies our strategy of including patients presenting risks such as smoking and overweight. The risk of wound healing complications is minimised by free instead of pedicled tissue transfer, and by including a maximum number of feeding perforators into the flap. We developed a fascia-sparing dis-

section method to ensure the latter without jeopardising abdominal wall stability. Careful attention was paid to sparing the original breast skin envelope in order to maintain natural shape, skin texture and colour, and to avoiding scars except around the reconstructed NAC. These data may be of help in the decision-making process of patients eligible for breast reconstruction after mastectomy.

*Correspondence:**Prof. D. Erni**Department of Plastic and Hand Surgery**Inselspital, University of Berne**CH-3010 Berne**Switzerland**E-Mail: dominique.erni@insel.ch*

References

- Molenaar S, Oort F, Sprangers M, Rutgers E, Luiten E, Mulder J, et al. Predictors of patients' choices for breast-conserving therapy or mastectomy: a prospective study. *Br J Cancer*. 2004;90:2123-30.
- Rapiti E, Fioretta G, Verkooijen HM, Vlastos G, Schafer P, Sappino AP, et al. Survival of young and older breast cancer patients in Geneva from 1990 to 2001. *Eur J Cancer*. 2005;41:1446-52.
- Lantz PM, Janz NK, Fagerlin A, Schwartz K, Liu L, Lakhani I, et al. Satisfaction with surgery outcomes and the decision process in a population-based sample of women with breast cancer. *Health Serv Res*. 2005;40:745-67.
- Nano MT, Gill PG, Kollias J, Bochner MA, Malycha P, Winefield HR. Psychological impact and cosmetic outcome of surgical breast cancer strategies. *ANZ J Surg*. 2005;75:940-7.
- Meretoja TJ, Rasia S, von Smitten KA, Asko-Seljavaara SL, Kuokkanen HO, Jahkola TA. Late results of skin-sparing mastectomy followed by immediate breast reconstruction. *Br J Surg*. 2007;94:1220-5.
- Taylor CW, Horgan K, Dodwell D. Oncological aspects of breast reconstruction. *Breast*. 2005;14:118-30.
- Cunnick G, Mokbel K. Oncological considerations of skin-sparing mastectomy. *Int Semin Surg Oncol*. 2006;3:14.
- Bostwick J, Schefflan M. The latissimus dorsi musculocutaneous flap: a one-stage breast reconstruction. *Clin Plast Surg*. 1980;7:71-8.
- Tarantino I, Banic A, Fischer T. Evaluation of late results in breast reconstruction by latissimus dorsi flap and prosthesis implantation. *Plast Reconstr Surg*. 2006;117:1387-94.
- Allen RJ, Tucker CJ. Superior gluteal artery perforator free flap for breast reconstruction. *Plast Reconstr Surg*. 1995;95:1207-12.
- Papp C, Windhofer C, Gruber S. Breast reconstruction with the fasciocutaneous infragluteal free flap (FCI). *Ann Plast Surg*. 2007;28:131-6.
- Hartrampf CR, Schefflan M, Black PW. Breast reconstruction with a transverse abdominal island flap. *Plast Reconstr Surg*. 1982;69:216-25.
- Harashina T, Inoue T, Sasaki K, Tanaka I, Kiyozumi T. Reconstruction of breast after super-radical mastectomy with a pedicled latissimus dorsi flap and a free TRAM flap. *Br J Plast Surg*. 1988;41:361-5.
- Fontana V, Castro T, Polynice A. Preferences of healthy inner city women and the surgical treatment of early stage breast cancer. *Am Surg*. 2007;73:215-21.
- Saulis AS, Mustoe TA, Fine NA. A retrospective analysis of patient satisfaction with immediate postmastectomy breast reconstruction: comparison of three common procedures. *Plast Reconstr Surg*. 2007;119:1669-76.
- Banic A, Boeckx W, Greulich M, Guelinckx P, Marchi A, Rigotti G, et al. Late results of breast reconstruction with free TRAM flaps: a prospective multicentric study. *Plast Reconstr Surg*. 1995;95:1195-204.
- Chang DW, Reece GP, Wang B, Robb GL, Miller MJ, Evans GR, et al. Effect of smoking on complications in patients undergoing free TRAM flap breast reconstruction. *Plast Reconstr Surg*. 2000;105:2374-80.
- Chang DW, Wang B, Robb GL, Reece GP, Miller MJ, Evans GR, et al. Effect of obesity on flap and donor-site complications in free transverse rectus abdominis myocutaneous flap breast reconstruction. *Plast Reconstr Surg*. 2000;105:1640-8.
- Nahabedian MY, Momen B, Galdino G, Manson PN. Breast Reconstruction with the free TRAM or DIEP flap: patient selection, choice of flap, and outcome. *Plast Reconstr Surg*. 2002;110:466-75.
- Selber JC, Kurichi JE, Vega SJ, Sonnad SS, Serletti JM. Risk factors and complications in free TRAM flap breast reconstruction. *Ann Plast Surg*. 2006;56:492-7.
- Spear SL, Ducic I, Cuoco F, Taylor N. Effect of obesity on flap and donor-site complications in pedicled TRAM flap breast reconstruction. *Plast Reconstr Surg*. 2007;119:788-95.
- Kroll SS, Schusterman MA, Reece GP, Miller MJ, Robb G, Evans G. Abdominal wall strength, bulging, and hernia after TRAM flap breast reconstruction. *Plast Reconstr Surg*. 1995;96:616-9.
- Clugston P, Gingrass M, Azurin D, Fisher J, Maxwell G. Ipsilateral pedicled TRAM flaps: the safer alternative? *Plast Reconstr Surg*. 2000;105:77-82.
- Nahabedian MY, Dooley W, Singh N, Manson PN. Contour abnormalities of the abdomen after breast reconstruction with abdominal flaps: the role of muscle preservation. *Plast Reconstr Surg*. 2002;109:91-101.
- Allen RJ, Treece P. Deep inferior epigastric perforator flap for breast reconstruction. *Ann Plast Surg*. 1994;32:32-8.
- Erni D, Harder YD. The dissection of the rectus abdominis myocutaneous flap with complete preservation of the anterior rectus sheath. *Br J Plast Surg*. 2003;56:395-400.
- Blondeel N, Vanderstraeten GG, Monstrey SJ, Van Landuyt K, Tonnard P, Lysens R, et al. The donor site morbidity of free DIEP flaps and free TRAM flaps for breast reconstruction. *Br J Plast Surg*. 1997;50:322-30.
- Nahabedian MY. Secondary operations of the anterior abdominal wall following microvascular breast reconstruction with the TRAM and DIEP flaps. *Plast Reconstr Surg*. 2007;120:365-72.
- Dian D, Schwenn K, Mylonas I, Janni W, Jaenicke F, Friese K. Aesthetic result among breast cancer patients undergoing autologous breast reconstruction versus breast conserving therapy. *Arch Gynecol Obstet*. 2007;275:445-50.
- Cocquyt VF, Blondeel PN, Depypere HT, Van De Sijpe KA, Daems KK, Monstrey SJ, et al. Better cosmetic results and comparable quality of life after skin-sparing mastectomy and immediate autologous breast reconstruction compared to breast conservative treatment. *Br J Plast Surg*. 2003;56:462-70.
- Cochrane RA, Valasiadou P, Wilson AR, Al-Ghazal SK, Macmillan RD. Cosmesis and satisfaction after breast-conserving surgery correlates with the percentage of breast volume excised. *Br J Surg*. 2003;90:1505-9.

SMW

Established in 1871
Formerly: Schweizerische Medizinische Wochenschrift
Swiss Medical Weekly

The European Journal of Medical Sciences

The many reasons why you should choose SMW to publish your research

What Swiss Medical Weekly has to offer:

- SMW's impact factor has been steadily rising. The 2006 impact factor is 1.346.
- Open access to the publication via the Internet, therefore wide audience and impact
- Rapid listing in Medline
- LinkOut-button from PubMed with link to the full text website <http://www.smw.ch> (direct link from each SMW record in PubMed)
- No-nonsense submission – you submit a single copy of your manuscript by e-mail attachment
- Peer review based on a broad spectrum of international academic referees
- Assistance of professional statisticians for every article with statistical analyses
- Fast peer review, by e-mail exchange with the referees
- Prompt decisions based on weekly conferences of the Editorial Board
- Prompt notification on the status of your manuscript by e-mail
- Professional English copy editing

Editorial Board

Prof. Jean-Michel Dayer, Geneva
Prof Paul Erne, Lucerne
Prof. Peter Gehr, Berne
Prof. André P. Perruchoud, Basel
Prof. Andreas Schaffner, Zurich
(editor in chief)
Prof. Werner Straub, Berne (senior editor)
Prof. Ludwig von Segesser, Lausanne

International Advisory Committee

Prof. K. E. Juhani Airaksinen, Turku, Finland
Prof. Anthony Bayes de Luna, Barcelona, Spain
Prof. Hubert E. Blum, Freiburg, Germany
Prof. Walter E. Haefeli, Heidelberg, Germany
Prof. Nino Kuenzli, Los Angeles, USA
Prof. René Lutter, Amsterdam, The Netherlands
Prof. Claude Martin, Marseille, France
Prof. Josef Patsch, Innsbruck, Austria
Prof. Luigi Tavazzi, Pavia, Italy

We evaluate manuscripts of broad clinical interest from all specialities, including experimental medicine and clinical investigation.

We look forward to receiving your paper!

Guidelines for authors:

http://www.smw.ch/set_authors.html

All manuscripts should be sent in electronic form, to:

EMH Swiss Medical Publishers Ltd.
SMW Editorial Secretariat
Farnsburgerstrasse 8
CH-4132 Muttenz

Manuscripts: submission@smw.ch
Letters to the editor: letters@smw.ch
Editorial Board: red@smw.ch
Internet: <http://www.smw.ch>