

Reduction of airspace after lung resection through controlled paralysis of the diaphragm[☆]

Giovanni L. Carboni^a, Andreas Vogt^b, Jan R. Küster^a, Peter Berg^c,
Dirk Wagnetz^a, Ralph A. Schmid^{a,*}, André E. Dutly^a

^a Division of General Thoracic Surgery, University Hospital Bern, Switzerland

^b Department of Anesthesiology, University Hospital Bern, Switzerland

^c Division of Pulmonology, University Hospital Bern, Switzerland

Received 11 September 2007; received in revised form 29 October 2007; accepted 31 October 2007; Available online 3 December 2007

Abstract

Objectives: Residual airspace following thoracic resections is a common clinical problem. Persistent air leak, prolonged drainage time, and reduced hemostasis extend hospital stay and morbidity. We report a trial of pharmacologic-induced diaphragmatic paralysis through continuous pararenal injection of lidocaine to reduce residual airspace. The objectives were confirmation of diaphragmatic paralysis and possible procedure related complications. **Methods:** Six eligible patients undergoing resectional surgery (lobectomy or bilobectomy) were included. Inclusion criteria consisted of: postoperative predicted FEV1 greater than 1300 ml, right-sided resection, absence of parenchymal lung disease, no class III antiarrhythmic therapy, absence of hypersensitivity reactions to lidocaine, no signs of infection, and informed consent. Upon completion of resection an epidural catheter was attached in the pararenal tissue on the proximal pericardial surface, externalized through a separate parasternal incision, and connected to a perfusing system injecting lidocaine 1% at a rate of 3 ml/h (30 mg/h). Postoperative ICU surveillance for 24 h and daily measurement of vital signs, drainage output, and bedside spirometry were performed. Within 48 h fluoroscopic confirmation of diaphragmatic paralysis was obtained. The catheter removal coincided with the chest tube removal when no procedural related complications occurred. **Results:** None of the patients reported respiratory impairment. Diaphragmatic paralysis was documented in all patients. Upon removal of catheter or discontinuation of lidocaine prompt return of diaphragmatic motility was noticed. Two patients showed postoperative hemodynamic irrelevant atrial fibrillation. **Conclusion:** Postoperative pararenal catheter administration of lidocaine to ensure reversible diaphragmatic paralysis is safe and reproducible. Further studies have to assess a benefit in terms of reduction in morbidity, drainage time, and hospital stay, and determine the patients who will profit.

© 2007 European Association for Cardio-Thoracic Surgery. Published by Elsevier B.V. All rights reserved.

Keywords: Lung neoplasm; Postoperative complications; Chest tubes; Feasibility studies

1. Introduction

Residual airspace following thoracic surgery is a common problem. Up to 41% of patients undergoing lung resections have residual airspace on conventional radiography on the first postoperative day [1]. 76–90% of these show spontaneous obliteration within 2 days to 12 weeks from surgery [1–3]. In more extended operations like bilobectomies or combined resections the remaining lung is unable to fill the entire pleural cavity (Fig. 1). This may lead to a number of several short-term problems like reduced hemostasis and parenchymal air leak, which can cause more severe complications such as pleural empyema. Depending on their

severity, these complications may require reoperations therefore increasing morbidity, mortality, hospital stay, and ultimately health care costs [4].

Surgical options to prevent residual air space are limited. Since the undersized remaining lung cannot fill the pleural cavity entirely, one possibility is to reduce the intrathoracic volume. The easiest and most often used technique is crushing the phrenic nerve using a surgical clamp. This leads to a paralysis of the diaphragm and consecutively to an elevation, hereby decreasing the intrapleural space. The crushed phrenic nerve theoretically should recover ensuring restoration of diaphragmatic function. However, damage to the nerve may persist possibly causing respiratory problems. Pleural tenting [4,5], where a portion of parietal pleura is detached from the endothoracic fascia and placed over the remaining lung ensuring a reduced intrapleural space, is only feasible when the parietal pleura is intact. Any injury to the parietal pleura or extrapleural dissection makes pleural tenting impossible. Other disadvantages include injury to the

[☆] Presented at the 21st Annual Meeting of the European Association for Cardio-thoracic Surgery, Geneva, Switzerland, September 16–19, 2007.

* Corresponding author. Address: Division of General Thoracic Surgery, University Hospital Bern, CH-3010 Bern, Switzerland. Tel.: +41 316322330; fax: +41 316322327.

E-mail address: ralph.schmid@insel.ch (R.A. Schmid).

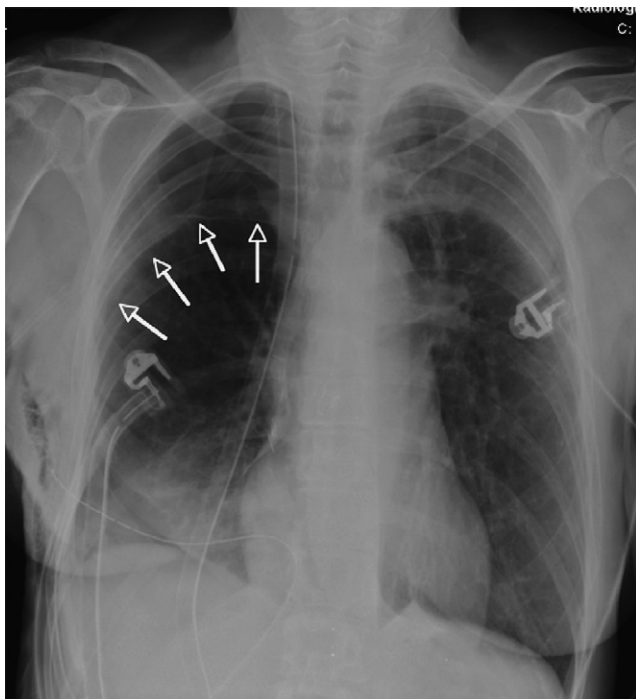


Fig. 1. Residual airspace following right lower bilobectomy for NSCLC in a 62-year-old patient.

intercostal nerves and the creation of a large wound after pleural detachment, which may lead to postoperative bleeding. Single intraoperative injection of a local anesthetic, thoracoplasty, pneumoperitoneum, and surgical dissection and reinsertion of the diaphragm on a higher level are rarely used [6].

We propose a more controllable paralysis of the diaphragm by placing an epidural catheter close to the phrenic nerve during surgery. Continuous injection of lidocaine will temporarily inhibit phrenic nerve function, reducing the volume of the pleural cavity. The objectives of this feasibility study were confirmation of diaphragmatic paralysis and assessment of possible procedure-related complications.

2. Methods

The present study is a proof of principle study to confirm safe reproducibility of transient diaphragmatic paralysis by periphrenic administration of lidocaine. It is a safe and well-controllable drug. The maximum bolus dose of lidocaine for adults is 300 mg (30 ml lidocaine 1%). A subcutaneous bolus injection of 100 mg (10 ml) is followed by a plasma level of 0.5 $\mu\text{g}/\text{ml}$. Toxic effects are usually seen at plasma levels of 8 $\mu\text{g}/\text{ml}$ or higher, which is 16-fold higher than the plasma levels reached after a subcutaneous injection of 100 mg. Based on these facts, we established the safe dose of 30 mg/h lidocaine in 1% solution for continuous administration. A plasma accumulation of lidocaine to reach levels with toxic effects can be virtually excluded.

Six eligible patients undergoing resectional surgery (lobectomy, bilobectomy) were included. Inclusion criteria consisted in postoperative predicted forced expiratory

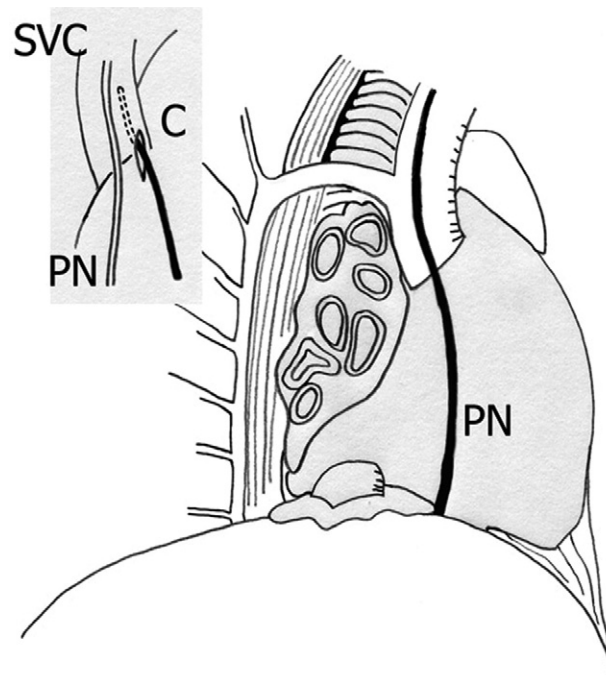


Fig. 2. The epidural catheter (C) administering lidocaine is placed in the fat pad on the apical pericardial surface adjacent to the phrenic nerve (PN); SVC, superior vena cava.

volume in 1 s (FEV1) greater than 1300 ml, right-sided resection, absence of parenchymal lung disease, no class III antiarrhythmic therapy, absence of hypersensitivity reactions to Lidocaine, no signs of local or systemic active infection, and informed consent. Informed consent was obtained in writing at least 1 day prior to surgery through the surgeon after careful explanation of the procedure and goals of the study. The study proposal was submitted to the local university ethics commission who granted its approval.

Upon completion of the lung resection, placement of an apical and a posterobasal chest drainage, an epidural catheter was attached in the periphrenic tissue on the proximal pericardial surface, fixed with an absorbable suture (Vicryl Rapid 4-0, Johnson & Johnson Medical, Ethicon Division, CH-8957 Spreitenbach), externalized through a separate incision and connected to a perfusing system injecting Lidocaine 1% at a rate of 3 ml/h (30 mg/h) (Fig. 2). Application of Lidocaine was started immediately. Perioperative analgesic therapy included the placement of an epidural catheter in all patients. Postoperative intensive care unit surveillance for 24 h and daily measurement of vital signs including blood pressure, heart rate, saturation and hemoglobin values were performed. Drainage output was recorded daily. A bedside spirometry was performed prior to surgery and starting from the first postoperative day every 24 h. Within 48 h from surgery fluoroscopic confirmation of diaphragmatic paralysis was obtained. Daily rounds with the patient included subjective assessment of any respiratory impairment. If no air leakage was detected the apical chest drain was removed within 24 h. The posterobasal drainage was taken away if output was below 300 mL in 24 h. The catheter removal concurred with the removal of the last chest tube when no procedural-related complications

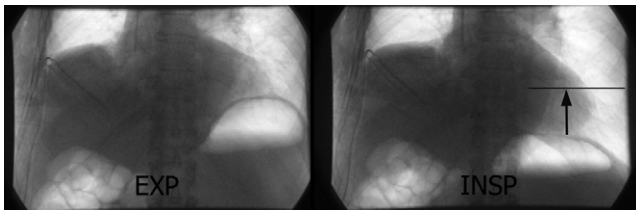


Fig. 3. Fluoroscopy on the second postoperative day showing absence of movement of the right diaphragm with functioning catheter in place.

occurred or on the 14th postoperative day. Patients were discharged within 1 day after discontinuation of the treatment. Radiologic imaging was obtained to assess proper return of diaphragmatic function. All patients were clinically re-evaluated within 2 weeks after discharge.

3. Results

Six patients were eligible in an approximate period of 6 months. The patients' characteristics are listed in Table 1. Four of six patients were diagnosed with non-small cell lung cancer (NSCLC). Two patients had pulmonary metastatic disease from a rectal cancer. Two patients underwent an upper lobectomy, two patients a lower lobectomy, and one patient an upper bilobectomy. The remaining patient with pulmonary metastasis underwent an upper lobectomy and three non-anatomic wedge resections of the remaining two lobes. No patients reported subjective respiratory impairment in the postoperative course. All patients received supplemental oxygen in the first 48 h after surgery (2–4 l/min). Oxygen saturation was maintained above 90%. Drainage time was on average 8 days (4–18). Three patients had a postoperative air leak; one patient had a prolonged air leak of 18 days. The FEV1 values dropped in average to 54% (45–76%) of the preoperative measurement on the first postoperative day. Before discharge the measurements raised to 67% (42–83%). A similar trend was noted in the measurements of forced vital capacity (FVC). Diaphragmatic paralysis was documented in all patients by fluoroscopy on the second postoperative day (Fig. 3). There were no allergic reactions to the catheter-administered local anesthetic. No special instruction for the nurses was needed as a normal perfusing system usually employed with an epidural catheter was used. Initial costs for the catheter system were 15 Euro and the costs for the amount of lidocaine injected per day were approximately 22 Euro. There were no catheter or perfuser malfunctions. Two patients developed atrial fibrillation on

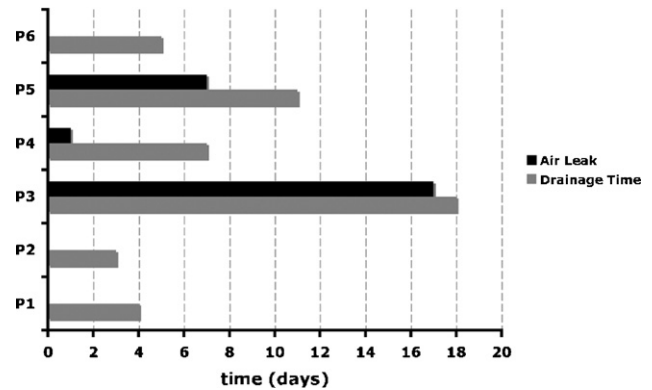


Fig. 4. Length of stays and air leaking of chest tubes in the six patients. Patient 3 and 5 underwent a bilobectomy and an upper lobe resection combined with three wedge resections of the remaining lobes, respectively.

the second postoperative day without hemodynamic instability. Lidocaine administration was discontinued for 24 h and therapy with a beta-blocking agent was started. Prompt conversion to normal cardiac rhythm occurred. After re-administration of lidocaine no tachyarrhythmia was noted. Residual airspace remained in the patient with prolonged air leak. Upon removal of catheter or discontinuation of lidocaine prompt return of diaphragmatic motility was noticed in the fluoroscopic control (Fig. 3).

4. Discussion

Postoperative residual space after lung surgery is a common problem and so far no controlled study reports its occurrence. Avoiding this problem is important because short-term problems such as air leak, persistent large drainage output, and bleeding lead to more serious complications (Fig. 4). Even if three quarters of the patients with residual air space will show complete reabsorption, 14% will develop complications [1]. An adequate intraoperative dissection strategy can contribute to minimize air leak but a small remaining lung especially after larger resections will not be large enough to fill the pleural cavity. In these cases a small air leak will probably be prolonged. The already mentioned strategies to avoid residual air space such as pneumoperitoneum, pleural tenting, and intraoperative crushing of the phrenic nerve are so far the most frequently used. Iverson et al. reported in 1976 of 50% diminished diaphragmatic function, and 20% permanent diaphragmatic

Table 1
Patients' characteristics

Patient	Sex	Age	Preop. FEV1 (%)	Preop. FVC (%)	Operation	Tumor	Stage
1	Male	72	2.89 (86)	3.78 (102)	RUL	NSCLC	IA (pT1pN0)
2	Female	55	2.13 (78)	3.42 (107)	RUL	NSCLC	IA (pT1pN0)
3	Female	61	2.07 (86)	3.36 (118)	RUBIL	NSCLC	IIIA (pT2pN2)
4	Male	63	3.17 (97)	5.48 (131)	RLL	NSCLC	IB (pT2pN0)
5	Male	76	2.58 (91)	3.86 (102)	RUL + 3×M	MR	na
6	Male	79	2.08 (87)	2.75 (85)	RLL	MR	na

RUL, right upper lobectomy; RLL, right lower lobectomy; RUBIL, right upper bilobectomy; RUL + 3×M, right upper bilobectomy and three metastasectomies; MR, metastatic rectal cancer.

paralysis after crushing the phrenic nerve [7]. There is no controlled data available on this subject. It is therefore surprising that it is widely accepted and even quoted in thoracic surgery textbooks [6,8] despite a not well-documented rate of permanent diaphragmatic dysfunction. We believe this warrants the avoidance of this technique. Pleural tenting and pneumoperitoneum may reduce the intrapleural space after resection [5]. Pleural tenting is not always feasible and bleeding complications could outweigh the advantages of diminished postoperative airspace. Pneumoperitoneum is reversible, but requires an access to the abdomen either transdiaphragmatically or transabdominally. Complications associated with pneumoperitoneum, although rare, can be devastating. However, a prospective study did show a reduced drainage time after perioperative institution of pneumoperitoneum [9]. Pleural tenting and pneumoperitoneum require a longer operating time, and even if successful both techniques harbor the potential of severe complications. Sporadic reports of thoracoplasty for managing air space problems are not encouraging [10]. It is a rarely required salvage-type procedure applicable in the late course of complicated persistent pleural space and not suitable for early management of residual air space. In the light of the mentioned shortfalls of the methods used to-date a well reproducible technique, which is fully reversible, is needed. A temporary diaphragmatic paralysis through continuous application of a local anesthetic close to the phrenic nerve is fully reversible and controllable. We demonstrated that a temporary dysfunction of the diaphragm is achieved and well tolerated by the patients. The technique requires only 2 min of additional operating time, is not difficult to perform, and has no added morbidity. Normal diaphragmatic function returns after catheter withdrawal and no procedure-related complications occur. Our results concur with the conclusions in a recent case report where a similar procedure was used to obliterate residual airspace [11]. Although the aim of the study was not evaluation of a better outcome using this technique we observed an unusual long air leak in two patients. Both patients underwent larger resections than standard lobectomy. In both cases unusual tedious intraoperative dissection was encountered because of undeveloped fissures and adhesions. Standard resections will rarely be followed by a persistent air leak. [3]. Obviously only a larger number of patients in a prospective trial can answer the question whether the presented technique will improve outcome in the subgroup of patients undergoing larger resections than lobectomy and especially those presenting with unusual difficult intraoperative dissection. The spirometric data we acquired are not sufficient to state anything about a possible impairment of lung function in

addition to the resection. The present study addressed only the feasibility of pharmacologic transient diaphragmatic paralysis. Further prospective evaluation is required to identify the utility in terms of shorter drainage time and lower occurrence of residual airspace-related complications. This would warrant its routine use in the armamentarium of the general thoracic surgeon facing larger lung resections.

5. Conclusion

Postoperative paraphrenic catheter administration of lidocaine to ensure reversible diaphragmatic paralysis is safe and reproducible. No procedure-related complications were noted. The technique is simple and inexpensive. Further studies have to assess a benefit in terms of reduction in morbidity after lung resection and determine the patients who will profit.

References

- [1] Solak O, Sayar A, Metin M, Turna A, Erdogu V, Pekcolaklar A, Gurses A. Definition of postresectional residual pleural space. *Can J Surg* 2007;50:39–42.
- [2] Wareham EE, Barber H, McGoeys JS, Miscall L. The persistent pleural space following partial pulmonary resection. *J Thorac Surg* 1956;31:593–600.
- [3] Alphonso N, Tan C, Utley M, Cameron R, Dussek J, Lang-Lazdunski L, Treasure T. A prospective randomized controlled trial of suction versus non-suction to the under-water seal drains following lung resection. *Eur J Cardiothorac Surg* 2005;27:391–4.
- [4] Okur E, Kir A, Halezeroglu S, Alpay AL, Atasalihi A. Pleural tenting following upper lobectomies or bilobectomies of the lung to prevent residual air space and prolonged air leak. *Eur J Cardiothorac Surg* 2001;20:1012–5.
- [5] Hansen JL. Parietal pleurolysis (the pleural tent) as a simultaneous space-reducing procedure in combination with pulmonary resection. *Acta Chir Scand* 1957;112:485–8.
- [6] Martini N, Ginsberg R. Lobectomy. In: Pearson F, Cooper J, Deslauriers J, Ginsberg R, Hiebert C, Patterson G, Urschel H, editors. *Thoracic surgery*. New York: Churchill Livingstone; 2002. p. 981–90.
- [7] Iverson LI, Mittal A, Dugan DJ, Samson PC. Injuries to the phrenic nerve resulting in diaphragmatic paralysis with special reference to stretch trauma. *Am J Surg* 1976;132:263–9.
- [8] Shields T, Ponn R. Complications of pulmonary resection. In: Shields T, Lo Cicero III JL, Ponn R, editors. *General thoracic surgery*. Philadelphia: Lippincott Williams and Wilkins; 2000. p. 481–505.
- [9] Toker A, Dilege S, Tanju S, Kiyan A, Kalayci G. Perioperative pneumoperitoneum after lobectomy–bilobectomy operations for lung cancer: a prospective study. *Thorac Cardiovasc Surg* 2003;51:93–6.
- [10] Hopkins RA, Ungerleider RM, Staub EW, Young Jr WG. The modern use of thoracoplasty. *Ann Thorac Surg* 1985;40:181–7.
- [11] Clavero JM, Cheyre JE, Solovera ME, Aparicio RP. Transient diaphragmatic paralysis by continuous para-phrenic infusion of bupivacaine: a novel technique for the management of residual spaces. *Ann Thorac Surg* 2007;83:1216–8.