

# The hysteroscopic view of infertility: the mid-secretory endometrium and treatment success towards pregnancy

A. Santi · R. Felser · N. A. Bersinger · D. M. Wunder ·  
B. McKinnon · M. D. Mueller

Received: 15 March 2011 / Accepted: 31 May 2011 / Published online: 22 June 2011  
© Springer-Verlag 2011

**Abstract** The purpose of this study was the analysis of a correlation, in infertile patients, between the quality of the endometrium based on its vascularisation and the chances of conception. Hysteroscopy was carried out to determine the quality of the endometrial surface using the Sakumoto–Masamoto classification (“good” vs. “poor” endometrium) in the secretory phase of the menstrual cycle. The results were set in relation to the outcome of the subsequent infertility treatment, i.e. the establishment of a pregnancy within the study period (4 years). In 108 (67%) of the 162 followed-up patients, the endometrium was endoscopically classified as “good”, while in 54 (33%) the result was “poor”. The overall pregnancy rate was 37% (60 patients); 47 of all pregnancies (78%) occurred in women with a “good” endometrium while 13 (22%) had a “poor” classification. This positive association between the establishment of a pregnancy in the follow-up and a “good” classification of the endometrial vasculature in the group with a “good” endometrium was significant ( $P=0.0165$ , Fisher’s exact test). This study confirms the usefulness of endometrial evaluation by hysteroscopy as a diagnostic

instrument for providing a prognosis of the chance for the patients to become pregnant.

**Keywords** Endometrium · Embryo implantation · Infertility · Hysteroscopy

## Background

One of the most difficult questions put forward by patients after the failure of a fertility therapy such as in vitro fertilisation (IVF) and intra-cytoplasmic sperm injection (ICSI) is related to the lack of success. The implantation rate per transferred embryo normally does not exceed 30%. Often the failure of “embryo implantation” is given as an explanation as the failure in one of the most critical stages at the beginning of conception, i.e. when apposition and implantation has to occur inside the uterine cavity. Current knowledge about the mechanism of these interactions is still difficult to interpret [1].

Various different suggestions have been made for investigating these mechanisms and attempting to understand which would be the characteristic elements of the endometrium that ensure ideal conditions for the embryo; but they have until today been limited to the so-called theory of the endometrial “opportunity window” [2] and did not offer effective clinical instruments for understanding which groups of patients would be at an increased risk of embryo implantation failure [3]. By using hysteroscopy as a diagnostic procedure for the assessment of pathologies inside the uterine cavity, it has, however, been shown that the differential characterisation of the endometrial surface could be a helpful tool for evaluating the in vivo vascularisation of the uterine mucosa. Already, Sakumoto et al. in 1992 in the first place [4], and after him Masamoto

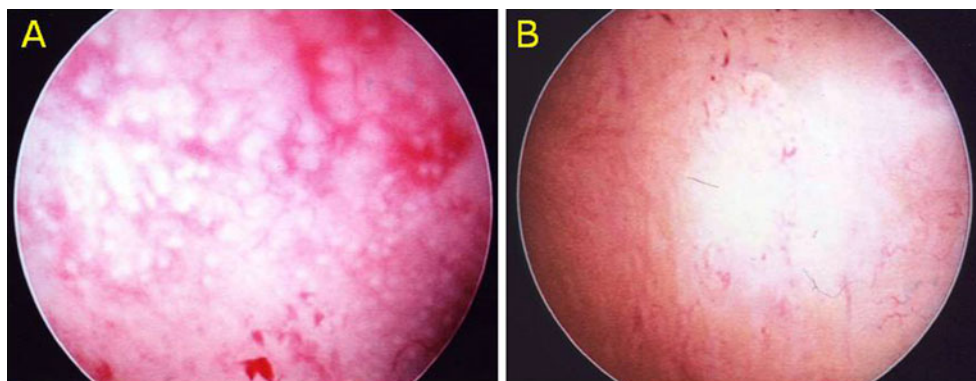
---

A. Santi · R. Felser · N. A. Bersinger (✉) · D. M. Wunder ·  
M. D. Mueller  
Department of Obstetrics and Gynaecology, Inselspital,  
University of Berne,  
DKF Murtenstrasse 35,  
Berne CH-3010, Switzerland  
e-mail: nick.bersinger@dkf.unibe.ch

B. McKinnon  
Department of Clinical Research, University of Berne,  
Berne, Switzerland

D. M. Wunder  
Department of Obstetrics and Gynaecology, Centre Hospitalier  
Universitaire Vaudois, University of Lausanne,  
Lausanne, Switzerland

**Fig. 1** Endoscopic examination of the endometrial surface and scoring. **a** “Masamoto good”: ring-type glandular openings and well-developed vascular networks are visible. **b** “Masamoto poor”: glandular openings are punctate typed, and the visible vasculature is sparse



et al. in 2000 [5], have described the technique and used this differentiation in order to demonstrate that the endometrium could be classified into two distinct groups: a “good” endometrium, which has circular gland openings and an intense vascular ramification on one hand, and a “poor” endometrium, which is characterised by a surface with a lower gland and vascular density on the other.

The purpose of this study was to demonstrate the impact of the hysteroscopy, according to this vascularisation-based staging, and to investigate whether this endometrium quality could be used as a tool to assess the potential to achieve a pregnancy irrespective of the chosen type of infertility treatment.

## Materials and methods

All infertile patients attending our fertility centre and with a regular menstrual cycle were asked to participate in this comparative, prospective study. They underwent a pre-operative transvaginal sonography (TVS), a full hormonal assessment (FSH, LH,  $17\beta$ -estradiol, thyroid-stimulating hormone and prolactin) in the serum on cycle days 3 to 5 and then a hysteroscopy in the second part of the menstrual cycle for evaluating the vascularisation of the endometrium. Informed, written consent was obtained from the patients after explanation of the study by the clinician prior to the procedure, and they were asked to avoid a pregnancy in the examination cycle. The study protocol was approved by the local ethical committee.

The inclusion criteria were infertility (absence of conception after 12 months of regular, unprotected intercourse), age less than 43 years, regular cycles (25–31 days) and normal hormonal values (including FSH <12 mU/mL)

had to be fulfilled. All partners provided a spermogram for the exclusion of male factor infertility. Further exclusion criteria were known causes of uterine malformations, endometrial adhesions and hormonal therapy such as oral contraceptives or other oestrogen–progesterone medications within the last 3 months before hysteroscopy. If necessary, the procedure was combined with a laparoscopy to test the tubal patency, and the hysteroscopy was done in most cases during the same operating session and under general anaesthesia. The ultrasonographers were located in the same university department, but not involved in the surgical procedure, and the surgeon was blinded to the TVS findings.

The endometrial surface was evaluated according to the Sakamoto–Masamoto grading (“good” vs. “poor”). Endoscopic findings were categorised as “good” with an appearance representing ring-type glandular openings and maximal glandular secretion or “poor” with a low development level of vessel networks on the endometrial surface. This is illustrated in Fig. 1. Hysteroscopic procedures were carried out when indicated (e.g. polyps, myomas, adhesions, septa). The diagnostic hysteroscopy was performed with a 5-mm-outer diameter scope (30°, Karl Storz) connected to a standard endoscopic camera, and a saline solution at low pressure (not higher than 60 mmHg) was used for the distension of the uterine cavity. Hysteroscopic findings were observed and analysed by three gynaecologists using videotape records.

The follow-up interval lasted for 12 months from hysteroscopy. Data were recorded and analysed for a correlation between the vascularisation score of the endometrium and the occurrence of embryo implantation (spontaneous pregnancy, successful outcome after hormonal stimulation with or without intrauterine insemination or

**Table 1** A 2×2 contingency table for endometrium evaluation and pregnancy outcome

Outcome	Endometrium “good”	Endometrium “poor”	Total
Pregnant	47	13	60
Not pregnant	61	41	102
Total	108	54	162

$P=0.0165$  by Fisher's exact test

successful IVF/ICSI-embryo transfer treatment). For statistical evaluation, the Fisher's exact test was applied using GraphPad Prism Software (San Diego, USA). For alpha, we considered 0.05 as cutoff value to avoid type I error.

## Findings

A total of 178 infertile women underwent a hysteroscopic assessment, and 162 (91%) of them could be followed up in our hospital. A "good" endometrium according to Sakumoto–Masamoto staging was diagnosed in 108 of them (67%), while 54 (33%) patients were graded as "poor". No differences in the distribution pattern of the causes and duration of infertility, the age of the patients (mean 33.8 years in the "good" and 33.6 in the "poor" group) or the pre-treatment day 3 serum level of follicle-stimulating hormone (6.8 and 7.4 U/L) were observed between these two groups.

A normal uterine cavity was reported in 133 (83%) women, while endometrial polyps, submucosal fibroids, adhesions or uterine malformations were found in 29 cases (17%). On the other hand, the pre-operative TVS indicated intrauterine pathologies in 15 cases (9.3%). The overall pregnancy rate was 37% (60 women); 15 women became pregnant spontaneously, 22 patients succeeded after follicular stimulation with recombinant gonadotropins (rFSH) and 23 after treatment with in vitro fertilisation and embryo transfer including ICSI.

In the total pregnancy group ( $N=60$ ), a "good" endometrium was found in 47 women (78%) while this was the case in 61 patients (60%) of the group who did not achieve a pregnancy. Forty-one patients with a "poor" endometrium did not succeed in getting pregnant. Only 13 patients with a "poor" endometrium did succeed in establishing pregnancy in the follow-up. The association between endometrium quality by Sakumoto–Masamoto classification and pregnancy outcome was statistically significant ( $P=0.0165$ ,  $OR=2.43$ ,  $CI=1.17–5.05$ ); the contingency matrix for the pregnancy outcome is shown in Table 1.

## Conclusion

Our results confirm those of the studies carried out by Sakumoto and Masamoto [4, 5], indicating that a hysteroscopic examination of the mid-secretory endometrium can be a reliable instrument for determining the chances of a patient to become pregnant. The classification in "good" and "poor" is leading to the conclusion that a poorly vascularised endometrium with limited glandular (secretory) structures may result in a tissue which is not suitable for a correct embryo implantation and endometrial development, and this irrespective of other factors of sterility.

Nevertheless, our results showed a lower fraction of patients (one third) with a "poor" endometrium in comparison to earlier studies (45.9% in the study of Sakumoto [4] and 61.3% in Masamoto et al. [5]): we believe that this difference can be explained with a different patient selection in the study groups. As a matter of fact, we did not focus on patients with a history of repeated abortions as it was the case in the study of Masamoto [5], but on a global infertile population.

Another clearly interesting but only partially surprising finding is the high percentage (17.2%) of intrauterine pathologies that have been diagnosed in the hysteroscopic examination when compared to the total number of patients with suspected intracavitary problems found in the pre-operative sonography (9.3% of all women, and this in spite of all ultrasound examinations having been carried out by the same team of experienced gynaecologists). These results, nevertheless, are in large agreement with previously published studies [6, 7].

We therefore conclude that a hysteroscopic examination, particularly in cases of idiopathic infertility or after several unsuccessful treatment cycles with in vitro fertilisation [8], is strongly indicated [9] and has the added benefit of providing a prognostic measure for determining the chances of the patient to become pregnant, in the future, in addition to its diagnostic significance [10].

**Declaration of interest** The authors report no conflicts of interest. The authors alone are responsible for the content and writing of the paper.

## References

1. Cakmak H, Taylor HS (2010) Implantation failure: molecular mechanisms and clinical treatment. *Hum Reprod Update* 17:252–253
2. Tabibzadeh S (1999) Molecular control of the implantation window. *Hum Reprod Update* 5:373–385
3. Diedrich K, Fauser BC, Devroey P, Griesinger G (2010) The role of the endometrium and embryo in human implantation. *Hum Reprod Update* 13:365–377
4. Sakumoto T, Sakumoto T, Inafuku K, Miyara M, Takamiyagi N, Miyake A, Shinkawa T, Nakayama M (1992) Hysteroscopic assessment of midsecretory-phase endometrium, with special reference to the luteal-phase defect. *Horm Res* 37:48–52
5. Masamoto H, Nakama K, Kanazawa K (2000) Hysteroscopic appearance of the mid-secretory endometrium: relationship to early phase pregnancy outcome after implantation. *Hum Reprod* 15:2112–2118
6. Grimbizis GF, Tsolakidis D, Mikos T, Anagnostou E, Asimakopoulos E, Stamatopoulos P, Tarlatzis BC (2010) A prospective comparison of transvaginal ultrasound, saline infusion sonohysterography, and diagnostic hysteroscopy in the evaluation of endometrial pathology. *Fertil Steril* 94:2720–2725

7. Kelecsi S, Kelekci S, Kaya E, Alan M, Alan Y, Bilge U, Mollamahmutoglu L (2005) Comparison of transvaginal sonography, saline infusion sonography, and office hysteroscopy in reproductive-aged women with or without abnormal uterine bleeding. *Fertil Steril* 84:682–686
8. Bozdog G, Aksan G, Esinler I, Yarali H (2008) What is the role of office hysteroscopy in women with failed IVF cycles? *Reprod Biomed Online* 17:410–415
9. Lorusso F, Ceci O, Bettocchi S, Lamanna G, Costantino A, Serrati G, Depalo R (2008) Office hysteroscopy in an in vitro fertilization program. *Gynecol Endocrinol* 24:465–469
10. Makrakis E, Makrakis E, Hassiakos D, Stathis D, Vaxevanoglou T, Orfanoudaki E, Pantos K (2009) Hysteroscopy in women with implantation failures after in vitro fertilization: findings and effect on subsequent pregnancy rates. *J Minim Invasive Gynecol* 16:181–187