

# High-resolution esophageal long-term ECG allows detailed atrial wave morphology analysis in case of atrial ectopic beats

Thomas Niederhauser · Thanks Marisa ·  
Andreas Haerberlin · Josef Goette · Marcel Jacoment ·  
Rolf Vogel

Received: 2 April 2012 / Accepted: 3 May 2012 / Published online: 18 May 2012  
© International Federation for Medical and Biological Engineering 2012

**Abstract** Detection of arrhythmic atrial beats in surface ECGs can be challenging when they are masked by the R or T wave, or do not affect the RR-interval. Here, we present a solution using a high-resolution esophageal long-term ECG that offers a detailed view on the atrial electrical activity. The recorded ECG shows atrial ectopic beats with long coupling intervals, which can only be successfully classified using additional morphology criteria. Esophageal high-resolution ECGs provide this information, whereas surface long-term ECGs show poor atrial signal quality. This new method is a promising tool for the long-term rhythm monitoring with software-based automatic classification of atrial beats.

**Keywords** Esophageal ECG · High resolution · Atrial wave morphology · Atrial ectopic beat

## 1 Introduction

The surface electrocardiogram (sECG) is routinely used to detect and characterize cardiac arrhythmias. Short lasting arrhythmias, i.e., paroxysmal arrhythmias, require long-term ECG recording in the outpatient setting [10] in order to establish the correct diagnosis and define the proper treatment. However, the sECG often lacks appropriate sensitivity for the atrial activity and P waves are hardly detected without the a priori time information of corresponding QRS complexes serving as fiducial marker [5]. This fact limits the successful classification of irregular atrial beats, e.g., atrial ectopic beats (AEBs) that are either blocked, do not affect the RR-intervals, or are masked either by the QRS complex or the T wave. Furthermore, sECG suffers from skin–electrode motion artifacts [9] and is often corrupted by electromyographic (EMG) noise, both reduce the signal-to-noise ratio.

In contrast to the sECG, the esophageal ECG (eECG) features high atrial signal amplitude [2]. The collapsed esophagus exerts continuous pressure on the esophageal electrode and the esophageal mucosa incessantly produces an electrolyte-like mucus. Both together guarantee tight electromechanical coupling between lead and body, even during deglutition, with adequate and stable signal quality suitable for long-term monitoring. In the past, many researchers investigated the potential of eECG to differentiate supraventricular arrhythmias [7], but the recordings were short-term, roughly high-pass filtered and included a surface lead for beat detection [3]. High-resolution long-term eECG signals were not considered for automatic beat classification using atrial wave morphology information. We suggest that such features increase the accuracy of irregular atrial beat identification.

---

T. Niederhauser · A. Haerberlin · R. Vogel (✉)  
ARTORG Center for Biomedical Engineering Research,  
University of Bern, Murtenstrasse 50, P.O. Box 44,  
3010 Bern, Switzerland  
e-mail: rolf.vogel@artorg.unibe.ch  
URL: www.artorg.unibe.ch

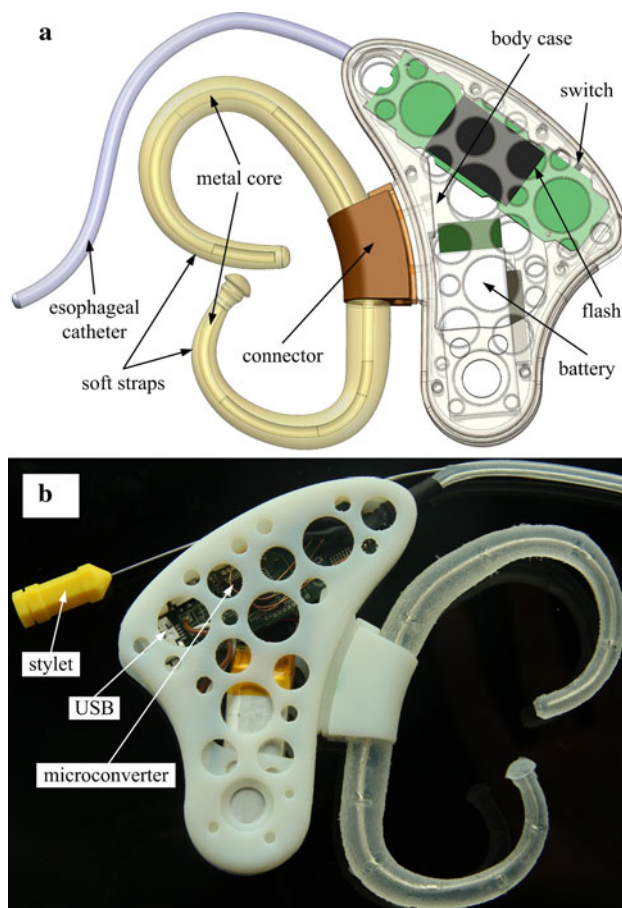
T. Niederhauser · T. Marisa · J. Goette · M. Jacoment  
Institute of Human Centered Engineering, Bern University  
of Applied Sciences, Biel, Switzerland

A. Haerberlin  
Department of Cardiology, Bern University Hospital,  
Bern, Switzerland

R. Vogel  
Department of Cardiology, Bürgerspital Solothurn,  
Solothurn, Switzerland

## 2 Materials and methods

We developed a high-resolution ECG recorder with special focus on the electrical properties of the esophageal lead and its bioelectric load, e.g., the site-typical baseline wander [3]. Figure 1 shows the recorder. The core of this system is a micro-converter (ADuC7060<sup>®</sup>, Analog Devices, USA) with 24-bit ADC. An expanded input range of  $\pm 25$  mV was realized by reducing amplifier's gain in combination with AC coupling to prevent saturation of the analog circuitry. As a result, a low-power input amplifier [4] with a  $-3$  dB-bandwidth of 0.5–250 Hz can be used that fulfills the amplitude response requirements for ECG devices [8] and obviates the need for a reference electrode. Nevertheless, the recorder provides an effective (noise-free) resolution of 18 bits [1], accordingly the voltage per bit calculates to 190 nV. Signals of two independent, bipolar channels are amplified with a high common-mode rejection ratio of 90 dB [4] and sampled at 512 Hz. The recorder's 1-GB flash memory allows continuous eECG data storing



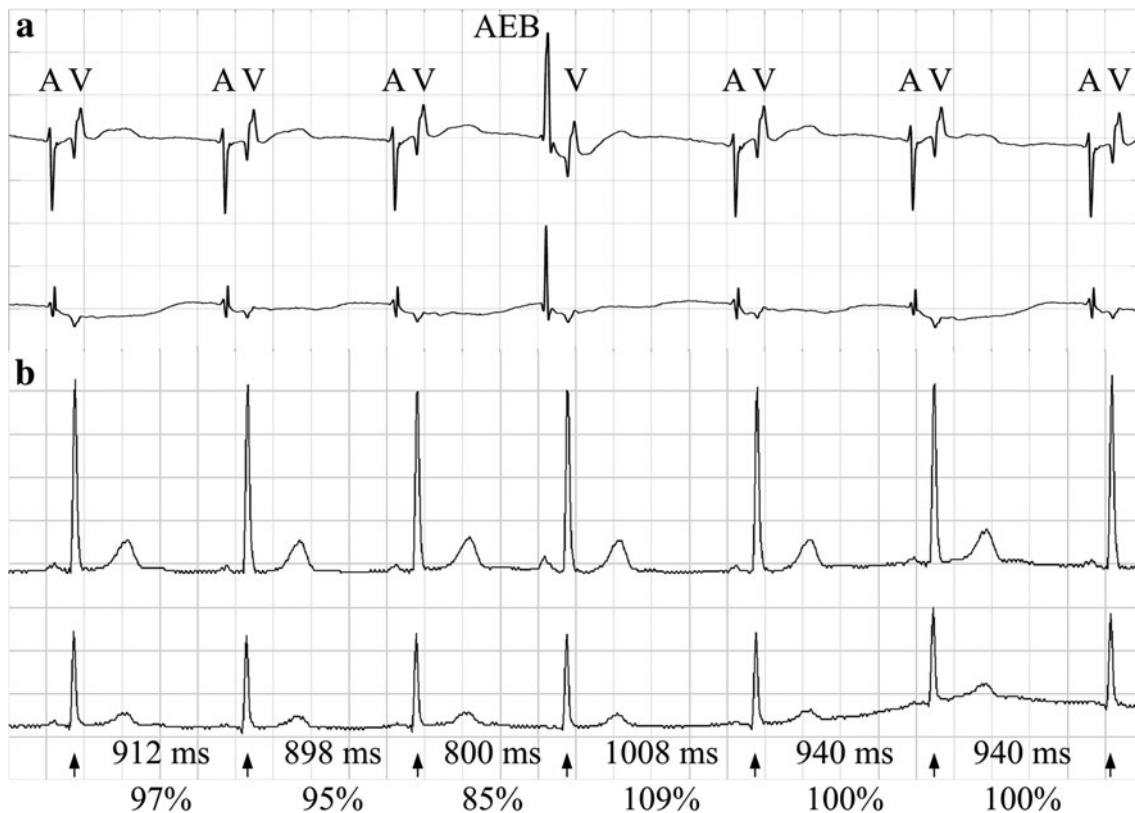
**Fig. 1** Computer-aided design (a, back view) and photograph (b, front view) of the 24-bit high-resolution esophageal ECG recorder. The recorder's main components are highlighted

up to 3 days. The circuit board and battery are placed into a dedicated body case that is worn around the ear (Fig. 1). The fixation is realized with silicon-based soft straps that are attached to the case using a simple mechanical connector. With the help of the metal core, the straps can be adapted to the patient's individual ear shape and size. During recording, the shape of the straps remains stable and guarantees stable hold. In addition, the recorder comprises a micro-USB interface for online data stream and offline data download and a switch to completely isolate the battery power supply.

We simultaneously recorded high-resolution eECG and sECG during 16 h in a patient who was enrolled in a clinical study aimed at the investigation of long-term eECG. The study was approved by the local ethics committee and informed consent was obtained from the patient. The eECG was recorded using a commercially available catheter (ESOSOFT 6S<sup>®</sup>, FIAB, Italy) with internal stylet (Fig. 1) connected to the previously described recorder. The sECG was acquired by a clinical approved Holter device (Lifecard CF<sup>®</sup>, Spacelabs Healthcare, USA) providing a frequency bandwidth of 0.05–40 Hz, a resolution of 12 bits, and a sampling frequency of 1,024 Hz. The eECG and sECG signals were digitally stored and processed offline with a custom-made software based on MATLAB<sup>®</sup> and Pathfinder SL<sup>®</sup>, respectively. The sECG signal was fully annotated. Esophageal and surface tracings were precisely synchronized with the help of ventricular ectopic beats that were identified in both leads.

## 3 Results

Figure 2 shows the ECG tracings during 5 s derived from two esophageal (eECG, 2a) and two surface leads (sECG, 2b). After the third ventricular beat, the morphology of only one atrial depolarization considerably changes in both eECG traces. In the fourth atrial beat, the main deflection flips from negative to positive accompanied by some modification of the amplitude. This event indicates that the electrical impulse was triggered by a source other than the sinoatrial node and, in turn, we classified this atrial beat as AEB. Furthermore, the repolarization of the AEB manifests in a slow negative wave as opposed to the normal atrial beat, where almost isoelectric lines are recorded. In contrast to that, the two sECG tracings are hardly affected and the little morphologic changes of the corresponding P wave could be missed easily during software-based automatic detection. In total, we annotated 40 examples of similar AEB's during the 16-h recording time in this patient.



**Fig. 2** Electrocardiogram (25 mm/s, 20 mm/mV) showing two bipolar esophageal leads (**a**) and two surface leads (**b**). The tracings are synchronized; A denotes atrial and V ventricular activity. The sudden change of the atrial wave deflection seen in both esophageal

tracings, eLeadV (ventricular lead, *above*) and eLeadA (atrial lead, *below*), indicates an atrial ectopic beat (AEB). The *arrows* indicate RR-intervals labeled with their duration in milliseconds and as percentage of the mean interval of the preceding 10 RR-intervals

#### 4 Discussion

In case of sECG, abnormal atrial beats are usually detected with the help of RR-intervals measured for consecutive R waves. An atrial beat, e.g., is classified as AEB if the ratio of the actual and the mean of preceding intervals underruns a certain threshold (e.g., 80 % [6]), and the QRS complex is not prolonged. In our case, the corresponding RR-intervals before and after the AEB are hardly affected (Fig. 2b, maximal alteration 15 %) and, therefore, automatic detection based on the time intervals fails. Of course, the AEB could be detected by increasing this threshold, but at the cost of an increased number of false positive AEB's, in particular in patients with sinus arrhythmia.

In contrast, AEBs in the high-resolution eECG signal are characterized by considerable morphologic changes with respect to preceding and subsequent atrial beats. To identify this pattern using an automatic approach, several features of the depolarization and the repolarization phase could be used. Moreover, the high-resolution eECG allows detailed analysis of the atrial wave morphology. Such an improved detection of APBs might be of clinical relevance because APBs can be used for risk stratification

after cryptogenic ischemic stroke [11]. Nevertheless, atrial and ventricular beats need to be detected and separated before the classification step. Considering the fact that eECG yields high atrial and ventricular signal amplitudes, this problem is solvable. An esophageal lead with short inter-electrode distance that primarily reflects atrial activity (eLeadA in Fig. 2a) is helpful in the particular cases of overlapping atrial and ventricular or blocked atrial signals.

The presented findings using our new high-resolution esophageal ECG are derived from a single case. Nevertheless, we have strong indications that objective parameters can be found in a larger trial comparing the long-term eECG and sECG in the assessment of irregular atrial activity.

#### 5 Conclusion

The high-resolution long-term eECG provides a detailed description of the atrial activity. In particular, the eECG allows morphologic analysis of irregular atrial events such as AEBs with long coupling intervals and promises to

facilitate their software-based automatic detection and classification.

**Acknowledgments** This work was funded by the Commission for Technology and Innovation CTI, Switzerland, the Department of Cardiology, Bern University Hospital and the Swiss Heart Foundation.

## References

1. ADuC7060 Data Sheet (2011) Analog Devices, Norwood, USA (Rev. C)
2. Benzádon MN, Ortega DF, Thierer JM, Torcivia RAS, Aldunate L, Alves de Lima AE, Navia D, Dorsa A, Rossi A, Trivi M (2006) Comparison of the amplitude of the P-wave from intracardiac electrocardiogram obtained by means of a central venous catheter filled with saline solution to that obtained via esophageal electrocardiogram. *Am J Cardiol* 98:978–981
3. DiCarlo LA, Lin D, Jenkins JM (1993) Automated interpretation of cardiac arrhythmias: design and evaluation of a computerized model. *J Electrocardiol* 26:53–67
4. Farshchi S, Pesterev A, Nuyujukian PH, Mody I, Judy JW (2007) Bi-Fi: an embedded sensor/system architecture for remote biological monitoring. *IEEE T Inf Technol B* 11:611–618
5. Goldwasser D, Bayés de Luna A, Serra G, Elosúa R, Rodríguez E, Guerra JM, Alonso C, Viñolas Prat X (2011) A new method of filtering T waves to detect hidden P waves in electrocardiogram signals. *Europace* 13:1028–1033
6. Hickey B, Heneghan C (2002) Screening for paroxysmal atrial fibrillation using atrial premature contractions and spectral measures. In: *Computers in cardiology*. IEEE, pp 217–220
7. Jenkins J, Wu D, Arzbaeher R (1979) Computer diagnosis of supraventricular and ventricular arrhythmias. A new esophageal technique. *Circulation* 60:977–987
8. Kligfield P, Gettes LS, Bailey JJ, Childers R, Deal BJ, Hancock EW, van Herpen G, Kors JA, Macfarlane P, Mirvis DM, Pahlm O, Rautaharju P, Wagner GS (2007) Recommendations for the standardization and interpretation of the electrocardiogram: part I: the electrocardiogram and its technology a scientific statement from the American Heart Association Electrocardiography and Arrhythmias Committee, Council on Clinical Cardiology; the American College of Cardiology Foundation; and the Heart Rhythm Society Endorsed by the International Society for Computerized Electrocardiology. *J Am Coll Cardiol* 49:1109–1127
9. Márquez MF, Colín L, Guevara M, Iturralde P, Hermosillo AG (2002) Common electrocardiographic artifacts mimicking arrhythmias in ambulatory monitoring. *Am Heart J* 144:187–197
10. Seet RCS, Friedman PA, Rabinstein AA (2011) Prolonged rhythm monitoring for the detection of occult paroxysmal atrial fibrillation in ischemic stroke of unknown cause. *Circulation* 124:477–486
11. Wallmann D, Tüller D, Wustmann K, Meier P, Isenegger J, Arnold M, Mattle HP, Delacrétaz E (2007) Frequent atrial premature beats predict paroxysmal atrial fibrillation in stroke patients. *Stroke* 38:2292–2294