

Randomized trial comparing the i-gel™ and Magill tracheal tube with the single-use ILMA™ and ILMA™ tracheal tube for fiberoptic-guided intubation in anaesthetized patients with a predicted difficult airway

M. Kleine-Brueggeny^{1,2†}, L. Theiler^{1,3*†}, N. Urwyler^{1,4}, A. Vogt¹ and R. Greif¹

¹ Department of Anesthesiology and Pain Therapy, Inselspital, University Hospital Bern, and University of Bern, Switzerland

² Department of Anesthesiology and Pain Medicine, University of Washington, Seattle, WA, USA

³ Department of Anesthesiology, Perioperative Medicine and Pain Management, University of Miami Miller School of Medicine, Gautier Bldg—Room 415, 1011 NW 15th Street, Miami, FL, USA

⁴ Department of Pathology, Stanford School of Medicine, CA, USA

* Corresponding author. E-mail: ltheiler@med.miami.edu

Editor's key points

- Some supraglottic airway devices (SADs) can be used as a conduit for fiberoptic-guided tracheal intubation.
- This study evaluated two SADs in 160 patients with risk factors for difficult intubation.
- Success of fiberoptic intubation was >90% overall, and similar using the i-gel™ and sILMA™.
- Seal pressure was lower with the i-gel™, but there were no other major differences between devices.

Background. The i-gel™ is a single-use supraglottic airway device (SAD) that allows fiberoptic-guided tracheal intubation through the device. Until now, no prospective data for this procedure are available. Therefore, in a prospective randomized controlled trial, we evaluated fiberoptic-guided tracheal intubation with a standard Rüschi™ PVC tracheal tube (TT) through the i-gel™ compared with the single-use ILMA™ (sILMA™) TT through the sILMA™ in patients with a predicted difficult airway.

Methods. With ethics committee approval and written informed consent, 160 patients were randomly assigned to either SAD. After placement of the SAD, a fiberoptic bronchoscope was introduced into the trachea as a railroad for the TT. Primary outcome variable was the first-attempt fiberoptic-guided intubation success rate. Secondary variables included time for insertion and intubation, airway leak pressures, fiberoptic view, and adverse events. Data are presented as mean (sd) or percentages. A *P*-value of <0.05 was considered statistically significant.

Results. Fiberoptic-guided intubation was successful at the first attempt in 76 patients (96%) using the i-gel™ and in 71 patients (90%) using the sILMA™ (*P*=0.21). Most of the failed intubations were rescued by conventional laryngoscopy. Airway leak pressure was higher for the sILMA™. There were no problems during removal of either type of SAD.

Conclusions. Fiberoptic-guided tracheal intubation through the i-gel™ using a standard Rüschi™ Magill TT is successful and an alternative to the sILMA™ with the sILMA™ TT.

Keywords: airway, complications; anaesthetic techniques, fiberoptic intubation; intubation, tracheal, laryngeal mask airway supraglottic airway devices

Accepted for publication: 2 March 2011

The i-gel™ (Intersurgical Ltd, Wokingham, Berkshire, UK) has proved popular with anaesthetists since its introduction into clinical practice. Its large airway diameter enables the introduction of a tracheal tube (TT) through the device.^{1,2} The use of a fiberoptic scope has been recommended, but this has never been studied in a prospective randomized controlled trial in humans.

The single-use intubating laryngeal mask airway (sILMA™, The Laryngeal Mask Company Limited, Le Rocher, Victoria, Mahé, Seychelles) with its corresponding ILMA™ TT plays an important role in the emergency pathway of various difficult airway algorithms.^{3,4} Success rate for tracheal intubation

using the reusable ILMA™ is up to 93% with the aid of a fiberoptic scope.⁵

Until now, there was only one trial in manikins⁶ evaluating the performance of intubation through the i-gel™ compared with the reusable ILMA™. The success rate of intubation through the ILMA™ is high, but so are the costs. Therefore, use of the ILMA™ in clinical practice may be limited to the unexpected difficult airway scenario. Clinicians initially may rely on the i-gel™ and then face the need to convert to a tracheal airway. In this case, they must know whether fiberoptic-guided intubation through the i-gel is feasible.

[†]These authors contributed equally to this work and share the first authorship.

Therefore, in this prospective, randomized, controlled, patient-blinded trial, we compared fibreoptic-guided tracheal intubation through the i-gel™ using a conventional, curved Magill tracheal PVC tube (Super SafetyClear, Rüschi GmbH, Kernen, Germany) with the single-use ILMA™ (sILMA™) with its commercially available sILMA™ PVC TT. Our hypothesis was that there would be a difference of no more than 15% between the two supraglottic airway devices (SADs) for the first-attempt success rate of fibreoptic-guided intubation.

Methods

Participants and anaesthesia

With written informed consent and ethics committee approval (Cantonal Ethics Committee Bern, Bern, Switzerland, approval number 79/08, August 29, 2008, ClinicalTrials.gov identifier: NCT00888875), 160 patients were included. Inclusion criteria were ASA physical status class I–IV, age 18–85 yr, undergoing elective surgery requiring tracheal intubation at the University Hospital of Bern, and showing at least one independent risk factor for a difficult airway. Independent risk factors for a difficult airway included documented difficult intubation in patient history, obesity with BMI >30 kg m⁻², thyromental distance <6 cm, inability to protrude the mandible or retrognathia, abnormal neck anatomy, modified Mallampati score >II,^{7 8} or mouth opening <3.5 cm.

Exclusion criteria were high risk of aspiration (non-fasted, gastroesophageal reflux disease), weight <30 kg, known difficult mask ventilation, mouth opening <20 mm,⁹ oral carcinoma or bleeding that restricted the use of SADs, or patients who did not speak German or who declined to participate.

The patients were blinded as to group allocation. We used online computer randomization (www.randomization.com) and sealed, opaque envelopes for randomization procedures. In group 1, we inserted an i-gel™ and fibreoptically intubated the trachea with a Rüschi™ Magill PVC TT. In group 2, we inserted an sILMA™ and fibreoptic intubation was performed with an sILMA™ TT. The last 40 patients underwent one visualized blind intubation attempt with the alternative TT (Rüschi™ TT for sILMA™, and sILMA™ TT for i-gel™) before the fibreoptic-guided intubation attempt was performed. The data from these last 40 patients are also included in an accompanying study.¹⁰ The primary outcome was success rate of fibreoptic intubation at the first attempt.

Airway management was performed under supervision of one of the senior study authors by staff anaesthesiologists with experience in the use of the i-gel™, the ILMA™, and in fibreoptic-guided tracheal intubation.

All patients received midazolam 7.5 mg orally 30 min before induction of anaesthesia. After institution of recommended anaesthetic monitoring, anaesthesia was induced with propofol 1.0–2.5 mg kg⁻¹ and fentanyl 2–3 µg kg⁻¹, and maintained with i.v. propofol to keep BIS 40–60. No neuromuscular blocking drugs were given before SAD insertion. After loss of the eye lash reflex, bag-mask ventilation was provided (maintaining SpO₂ >96%, and steady

values of endexpiratory CO₂). Then, the lubricated i-gel™ or sILMA™ was introduced according to randomization group. A stable head position was obtained with a doughnut-shaped pillow throughout the study. The head was maintained in the neutral position for insertion of the sILMA™ and with the neck extended for insertion of the i-gel™. After insertion of the SAD and completing all measurements related to the SAD, neuromuscular blocking drugs were administered to decrease the incidence of coughing during intubation, and to reduce complications during SAD removal.¹¹

SAD insertion

SAD insertion was performed according to the manufacturer's recommendations^{12 13} with small adjustments for size selection: a size 3 sILMA™ was chosen for patients weighing 30–50 kg, a size 4 for 50–70 kg, and a size 5 for patients >70 kg. For the i-gel™, a size 3 was used for patients weighing 30–50 kg (up to 60 kg, if patient's height was <160 cm), size 4 for 60–90 kg (down to 50 kg, if patient's height was >160 cm), and size 5 for patients >90 kg. This adaptation for the i-gel™ for patients in the weight range 50–60 kg was made to avoid the overlap between sizes 3 and 4. K-Y Lubricating Jelly (Johnson & Johnson Medical Limited, Gargrave, Skipton, UK) was used in all SADs. The cuff of the sILMA™ was fully deflated during insertion, and then inflated to a maximum of 60 cm H₂O,¹³ using a manometer (Rüschi™ GmbH, Kernen, Germany).

An initial assessment of ventilation was made by gently squeezing the reservoir bag and observing end-tidal carbon dioxide waveforms and chest movements. In the case of adequate ventilation, leak pressure was measured as described below. Adequate ventilation was defined as two consecutive tidal volumes of at least 6 ml kg⁻¹ ideal body weight (height in cm–100) during pressure-controlled ventilation at 17 cm H₂O.^{14 15}

In the case of inadequate ventilation, up to three minor airway interventions were allowed (e.g. adjusting head/neck position, changing depth of insertion).¹⁶ If the first SAD failed after three insertion attempts, the other SAD was used, again allowing three insertion attempts and minor airway manoeuvres.¹⁴

Time necessary for insertion was measured from the time the face mask was taken away from the face until the appearance of CO₂ on the capnograph.

Intubation

A fibrescope (Acutronic Medical Systems AG, Hirzel, Switzerland) was primed with a lubricated size 7.0 mm Rüschi™ Magill PVC TT or a lubricated 7.0 mm sILMA™ TT according to randomization (Rüschi PVC tube in the case of i-gel™, sILMA™ tube in the case of sILMA™). After preoxygenation of the patient's lungs, and when neuromuscular block was confirmed by loss of twitch response to nerve stimulation (train-of-four stimulation, TOF-Watch®SX, Organon Teknika AG, Pfäffikon, Switzerland), the breathing system was briefly disconnected and the TT and fibrescope

inserted through the airway port. We graded best fibreoptic view on the glottis from the outlet of the SAD from 1 to 4 (1, vocal cords entirely visible; 2, vocal cords or arytenoid cartilages partially visible; 3, epiglottis only visible; 4, no laryngeal structures visible) as previously proposed.¹⁷ After intubation with the fibrescope, the TT was railroaded into the trachea. To pass the epiglottic elevating bar in the case of the sILMA™, the TT was inserted to the 15 cm depth mark (black line) and advanced beyond the epiglottic elevating bar of the sILMA™ together with the scope (tube first technique). Then, the larynx was seen and the fibreoptic scope was advanced into the trachea. The tip of the TT pointed upwards, so the black writing on the tube faced posteriorly.¹³ To facilitate advancement of the TT over the fibreoptic scope, the following manoeuvres were permitted: anticlockwise rotation of the TT by 90°, the SAD adjusted by 'Chandy' manoeuvres,^{5 13} by the 'up-down' manoeuvre, or by changing the inclination of the patient's head. These adjustments of the SAD were also allowed if the fibrescope could not be inserted into the trachea, but not for the initial evaluation of fibreoptic view.⁵ If fibreoptic intubation failed, either the alternative SAD was used or the airway was secured according to the attending anaesthesiologists' decision. The position of the TT in the trachea was verified fibreoptically. Our primary outcome variable was the first-attempt success rate of fibreoptic-guided tracheal intubation. Success was defined as end-tidal carbon dioxide confirmed placement of the TT within a maximum of 5 min tracheal intubation time.⁵

After intubation, the fibrescope was removed and the breathing circuit reconnected to the tube. Intubation time was measured from the time the breathing circuit was disconnected until the carbon dioxide curve appeared again on the monitor. An additional time point was set when the glottis was passed with the scope (time necessary to intubate the trachea with the fibrescope).

To remove the SADs, we used the sILMA™ stabilizer rod for both SADs, according to the ILMA™ user booklet.¹³ Time to remove the SAD was measured from disconnection of the breathing system until reappearance of the carbon dioxide curve on the monitor. At this time, the study was finished and anaesthesia was maintained according to the attending anaesthesiologist.

Airway leak pressure

Airway leak pressure was measured by closing the expiratory valve of the circle breathing system at a fixed gas flow of 3 litres min⁻¹ and noting the airway pressure (max. allowed 40 cm H₂O) at which equilibrium was reached or air was leaking audibly.¹⁸ Air entering the stomach was detected by auscultation over the epigastrium when measuring oropharyngeal leak.¹⁴

Adverse events

All adverse events were recorded, defined as suspicion of aspiration/regurgitation (gastric fluid in the ventilation tube

or in the hypopharynx), hypoxia (SpO₂ <92%), hypotension (mean arterial pressure <55 mm Hg), hypertension (mean arterial pressure ±20% over pre-induction baseline), changes in heart rate ±20%, pre-induction value, bronchospasm, airway obstruction, coughing, dental, tongue, or lip trauma.

Evaluation of postoperative complaints

On postoperative day 1, an investigator who was blinded to patient allocation, anaesthesia, and the performance of airway management interviewed the patient to obtain data about side-effects. In the case of ambulatory surgery, we called the patients by phone. Asked items included: sore throat, hoarseness, dysphagia, postoperative nausea and vomiting, rescue medication, pain, analgesics taken, and any unscheduled re-hospitalization.

Statistical analysis

There are no clinical trials prospectively evaluating fibreoptic intubation through the i-gel™ SAD in humans. Joo and Rose⁵ showed a 93% first-attempt success when intubating through the ILMA™ using a fibreoptic scope. Pandit and colleagues¹⁹ had an 80% first-attempt success when fibreoptic-guided intubation was performed via the classic LMA and an outright failure of 10% because of the aperture bars. A clinically significant difference in success of 15% was assumed in a study (ILMA™ vs C-Trach™) by Liu and colleagues²⁰ in accordance with the data of Pandit and colleagues¹⁹ who found a difference of 15% comparing fibreoptic intubation through ILMA™ vs the classic LMA™. On the basis of our experience with the i-gel™, we expected the difference of the fibreoptically guided tracheal intubation success rate to be <15%, and calculated that a sample of 160 patients was necessary, given $\alpha=0.05$ and a power of 80%.

For our primary outcome variable, the success rate of fibreoptic-guided tracheal intubation, and other frequency data, we compared values using the χ^2 test. The SADs were evaluated as intention-to-treat according to randomization. Continuous data were analysed using the Mann-Whitney test if normality distribution could not be assumed; otherwise Student's *t*-test was used. We analysed all data with SPSS V.15 (SPSS Inc., Chicago, IL, USA/SPSS Schweiz AG, Zürich, Switzerland). Data are presented as mean (SD), or percentage. A probability value of <0.05 was considered statistically significant.

Results

One hundred and sixty-five patients were undergoing general anaesthesia with tracheal intubation and presented at least one predictor of difficult airway management during the 349 days of the study. Four patients did not give informed consent. One was not randomized because of changes in surgical procedure, and so 160 patients were randomized, 91 (57%) of whom were male (Fig. 1). Twenty-two anaesthetists participated in the study. There were no differences in baseline patient characteristics (Table 1).

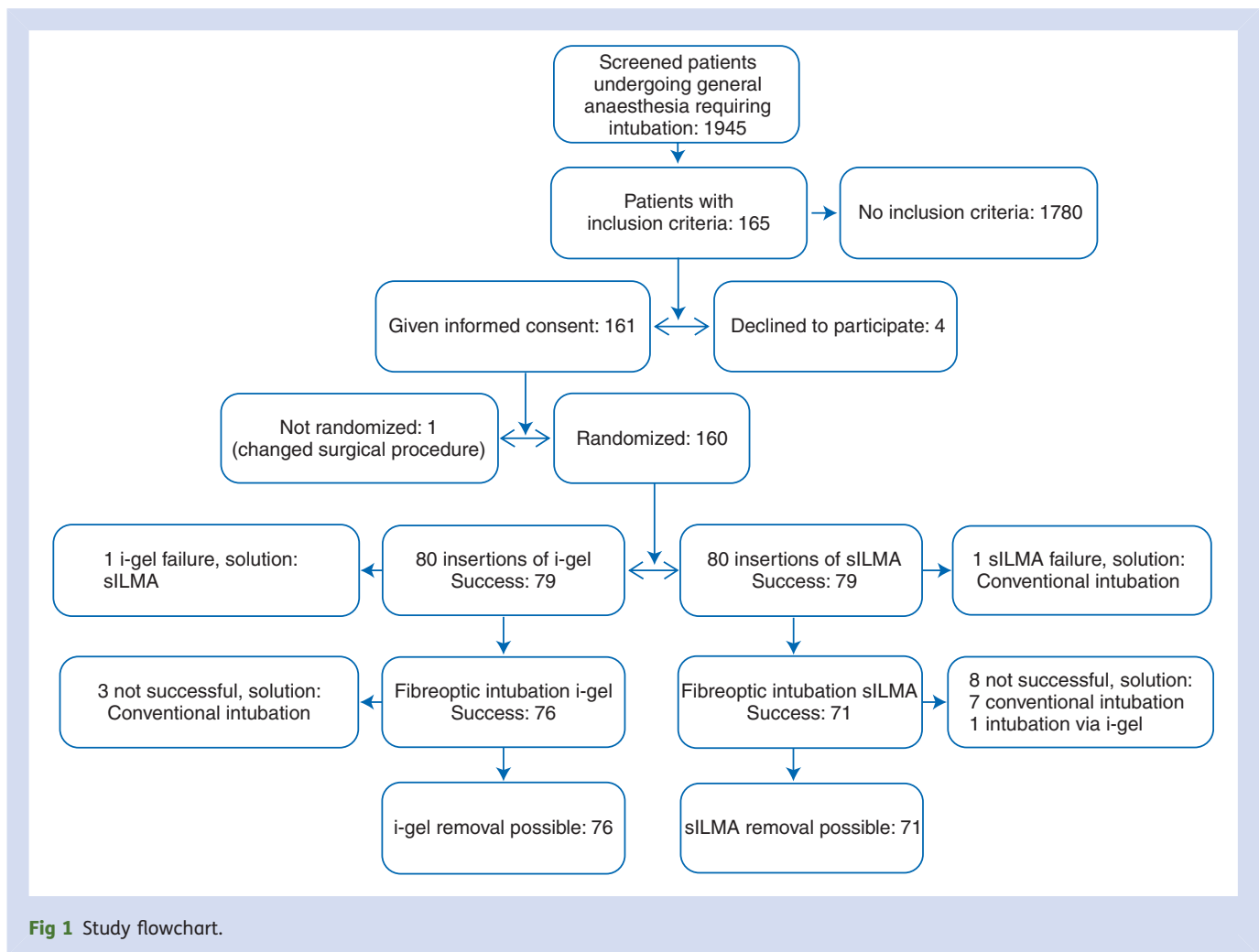


Fig 1 Study flowchart.

Face-mask ventilation was deemed to be easy in 108 cases, in the other 52 cases either two-handed ventilation or a Guedel airway was necessary. Vital signs did not differ significantly between the two SADs throughout the study.

Insertion of the SADs

We found no difference in the insertion success rates between i-gelTM and sILMATM ($P=1.00$, Table 2). In one case of insufficient ventilation with an sILMATM, the airway was secured by oral intubation. One i-gelTM failed because of inadequate ventilation without hypoxia. This patient's lungs were ventilated successfully using the sILMATM.

One i-gelTM had to be changed from size 4 to 5 in a male patient of 88 kg and 173 cm and one sILMATM had to be changed from size 4 to 5 in another male of 67 kg and 174 cm because of excessive airway leaks, although the size selection was according to the manufacturer's descriptions.

There were no differences in first-attempt success rates and rate of minor interventions necessary (Table 2). Time of SAD insertion and tidal volumes between the two groups were equivalent as well. Airway leak pressure was lower for the i-gelTM compared with the sILMATM [mean (SD) 24 (8) vs 29 (7) cm H₂O, $P=0.001$].

Fiberoptic tracheal intubation

Ventilation failed with one i-gelTM and one sILMATM and the airway had to be secured by other means. Fiberoptic intubation was attempted via 79 i-gelsTM and 79 sILMAsTM. There was no statistically significant difference in the primary outcome measure: the success rate at first attempt of fiberoptically guided tracheal intubation was 76 (96%) using the i-gelTM with the Magill PVC TT compared with 71 (90%) using the sILMATM with its sILMATM TT ($P=0.21$, Table 3).

There was no difference in fiberoptic laryngeal view ($P=0.42$). Epiglottic downfolding was more frequent in the sILMATM compared with the i-gelTM (16% vs 1%, $P=0.01$). The mean time necessary for intubation was 72 (42) s for the i-gelTM group and 65 (37) s for the sILMATM group ($P=0.34$). The time necessary for the fibroscope to intubate the trachea did not differ significantly between i-gel and sILMATM ($P=0.54$). However, the time to railroad the tubes over the fibroscopes varied greatly between the two SADs [i-gelTM: mean 28 (17) s, sILMATM: mean 18 (15) s, $P<0.001$].

The three patients in the i-gelTM group in whom fiberoptic intubation was impossible despite correction manoeuvres all underwent tracheal intubation using conventional

Table 1 Patient characteristics and perioperative data, presented as mean (SD) or number

	i-gel™ + Rüsch PVC tube (n=80)	sILMA™ + sILMA™ tube (n=80)
Age (yr)	56 (21–85)	57 (22–83)
Gender (M/F)	24/56	45/35
ASA I/II/III/IV	11/41/28/0	6/37/35/2
Height (cm)	173 (9)	168 (8)
Weight (kg)	90 (18)	88 (19)
BMI (kg m ⁻²)	30 (6)	31 (4)
Patients with BMI >30 kg m ⁻²	41	45
Thyromental distance <6 cm	9	7
No jaw protrusion	2	2
Presence of sleep apnoea	44	34
Mallampati I/II/III	26/38/16	31/35/14
Mouth opening <3.5 cm	9	7
Mask ventilation possible without help	54	53
Duration of surgery (min)	140 (99)	139 (81)
Duration of anaesthesia (min)	226 (120)	226 (100)

Table 2 SAD insertion, presented as mean (SD) or number. *P<0.001 between the groups

	i-gel™ (n=80)	sILMA™ (n=80)
Success at first attempt	75	75
Overall success	79	79
Minor intervention necessary	20	16
Time of insertion (s)	23 (15)	28 (23)
Tidal volume (ml)	668 (242)	655 (230)
Airway leak pressure (cm H ₂ O)	24 (8)	29 (7)*

laryngoscopy. The eight failed sILMA™ intubations were managed by conventional intubation seven times and once by fibreoptic intubation through the i-gel™ (Fig. 1).

Removal of the SAD

All inserted SADs were removed without complications using the sILMA™ exchange rod. There was no difference in removal time between the SADs [39 (13) s for the i-gel™ compared with 40 (16) s for the sILMA™, P=0.624].

Adverse events and postoperative complaints

We found no differences in haemodynamic changes during insertion or intubation between the groups. Four i-gel™

Table 3 Fibreoptic intubation through the SADs, presented as mean (SD) or number. *P<0.01. †Laryngeal view was graded from 1 to 4 (1, vocal cords entirely visible; 2, vocal cords or arytenoid cartilages partially visible; 3, epiglottis only visible; 4, no laryngeal structures visible)¹⁶

	i-gel™ (n=79)	sILMA™ (n=79)
Fibreoptic intubation successful at first attempt	76	71
Laryngeal view 1/2/3/4†	54/12/7/6	47/14/13/4
Epiglottic downfolding	1	13*
Time for intubation (s)	72 (42)	65 (37)

(5%) and two sILMAs™ (3%) were stained with blood after removal (P=0.65).

Desaturation (Sp_{O₂} <90%) occurred in one obese patient (BMI 37 kg m⁻²) after induction of anaesthesia and before insertion of the SAD despite 3 min preoxygenation. Face-mask ventilation was established quickly and Sp_{O₂} recovered promptly. There were no other adverse events.

The incidence of postoperative sore throat was 14% (i-gel™) and 9% (sILMA™), respectively, P=0.45. There were no other postoperative complaints.

Discussion

In this prospective, randomized, controlled, patient-blinded clinical trial, we found equally high success rates for fibreoptic-guided tracheal intubation with the Rüsch™ Magill TT via the i-gel™, and with the single-use ILMA™ TT via the sILMA™ in a patient population with predictors of difficult airway management.

The fibreoptic-guided intubation with the Rüsch™ Magill TT through the i-gel™ failed in only 4%. The 90% success rate for the sILMA™ group was slightly lower than the 93% described earlier for the reusable ILMA™.⁵ This might be attributed to our study population presenting predictors of difficult airway management or to the different material of the single-use ILMA™ (PVC) and the reusable ILMA™ (silicone). However, an earlier comparison of the reusable and the single-use ILMA™ in 84 patients with normal airway anatomy found the performance of both devices to be equal.²¹ The few failed fibreoptic intubations were evenly distributed among the anaesthesiologists and we did not find an influence of the anaesthesiologist on the time necessary for intubation. Also, our *post hoc* analysis detected no decrease in intubation time over the study course, indicating the absence of a learning curve.

There was no statistically significant difference in the intubation success rate between i-gel™ and sILMA™ (96% vs 90%, P=0.211). The 95% confidence interval of this difference in success rate was -2% to 15%. We do not know to what extent the success rate would have changed if we had used an sILMA™ TT with the i-gel™, but this was not the goal of the study. The differences in success rates using different TTs with the ILMA™ have been studied by others,

with inconclusive results.^{5 22–24} It took longer to railroad the RüschtTM Magill PVC TT over the intubated fibroscope. We speculate that the softer tip of the sILMATM TT allowed easier advancement.²⁵

Our study confirmed the high airway seal pressures for both SADs which were published by other study groups.^{5 26} Airway leak pressures for the sILMATM were higher than previously reported for the reusable ILMATM.²⁷

Postoperative complaints were rare and we did not find any statistically significant differences between the two airway sets. However, there was a statistically not significant difference in the incidence of postoperative sore throat with the i-gelTM/RüschtTM PVC TT (14%) compared with the sILMATM/sILMATM TT (9%, $P=0.45$). Both the stiffness of the RüschtTM PVC TT and the i-gelTM may have been contributing factors.

As a limitation, this study was performed on patients with predictors of difficult mask ventilation, difficult laryngoscopy, and difficult intubation. Because of ethical considerations, we did not include patients with a previously known difficult airway, denying them the advantage of an awake fiberoptic intubation. It is possible that the devices used in the present study perform differently in patients with real difficult airway, but that was not in the scope of this study.

In the last 40 patients, a visualized blind intubation attempt was performed before fiberoptic intubation (these data are included in an accompanying study).¹⁰ This TT was withdrawn, and the patients were intubated by fiberoptic guidance according to the randomized airway device. To rule out any potential effect of the blind intubation attempt on the later fiberoptic intubation, we compared both subgroups (the last 40 patients vs the first 120 patients) and found no difference in time for fiberoptic intubation ($P=0.12$ for the i-gelTM and $P=0.38$ for the sILMATM). There was no significant difference in failure rate: 1.6% (i-gelTM) and 5% (sILMATM) in the first 120 patients compared with 2.5% (i-gelTM) and 5% (sILMATM) in the last 40 patients ($P=0.99$).

In conclusion, we found that in 160 patients with predictors for difficult airway management, fiberoptic-guided tracheal intubation with a standard RüschtTM Magill PVC TT through an i-gelTM was as successful as the use of an sILMATM with its sILMATM TT. The i-gelTM and RüschtTM Magill TT may be a reliable and cost-effective alternative to the sILMATM with its sILMATM TT.

Acknowledgements

Special thanks to Jeff Crowder, BA, Austria and Brian Swenson, MD, USA for proofreading the English of this manuscript.

Conflict of interest

None declared.

Funding

This work was supported by a departmental research grant. i-gelsTM were supplied free of charge by Intersurgical

(distributed by Manfred Kienast, MK-Med, Eyholz, Switzerland), sILMATM devices were sold at a special research price (Serge Viel, Laubscher, Basel, Switzerland). Fiberoptic scopes were provided by Acutronic (Acutronic Medical Systems AG, Hirzel, Switzerland).

References

- Sharma S, Scott S, Rogers R, Popat M. The i-gelTM airway for ventilation and rescue intubation. *Anaesthesia* 2007; **62**: 419–20
- Michalek P, Hodgkinson P, Donaldson W. Fiberoptic intubation through an I-gelTM supraglottic airway in two patients with predicted difficult airway and intellectual disability. *Anesth Analg* 2008; **106**: 1501–4
- Henderson JJ, Popat MT, Latta IP, Pearce AC. Difficult Airway Society guidelines for management of the unanticipated difficult intubation. *Anaesthesia* 2004; **59**: 675–94
- Practice guidelines for management of the difficult airway: an updated report by the American Society of Anesthesiologists Task Force on Management of the Difficult Airway. *Anesthesiology* 2003; **98**: 1269–77
- Joo HS, Rose DK. The intubating laryngeal mask airway with and without fiberoptic guidance. *Anesth Analg* 1999; **88**: 662–6
- Michalek P, Donaldson W, Graham C, Hinds JD. A comparison of the I-gelTM supraglottic airway as a conduit for tracheal intubation with the intubating laryngeal mask airway: a manikin study. *Resuscitation* 2010; **81**: 74–7
- Mallampati SR, Gatt SP, Gugino LD, et al. A clinical sign to predict difficult tracheal intubation: a prospective study. *Can Anaesth Soc J* 1985; **32**: 429–34
- Samsoon GL, Young JR. Difficult tracheal intubation: a retrospective study. *Anaesthesia* 1987; **42**: 487–90
- Preis C, Czerny C, Preis I, Zimpfer M. Variations in ILMATM external diameters: another cause of device failure. *Can J Anaesth* 2000; **47**: 886–9
- Theiler L, Kleine-Brueggenev M, Urwyler N, Graf T, Luyet C, Greif R. Randomized clinical trial of the i-gelTM and Magill tracheal tube or single-use ILMATM and ILMATM tracheal tube for blind intubation in anaesthetized patients with a predicted difficult airway. *Br J Anaesth* 2011 (in press)
- van Vlymen JM, Coloma M, Tongier WK, White PF. Use of the intubating laryngeal mask airway: are muscle relaxants necessary. *Anesthesiology* 2000; **93**: 340–5
- User Guide for the i-gelTM Single Use Supraglottic Airway*. Intersurgical, 2006
- ILMA Fastrach Instruction Manual*. Laryngeal Mask Company, 2006
- Brimacombe J, Keller C, Brimacombe L. A comparison of the laryngeal mask airway ProSeal and the laryngeal tube airway in paralyzed anesthetized adult patients undergoing pressure-controlled ventilation. *Anesth Analg* 2002; **95**: 770–6
- Hohlrieder M, Brimacombe J, von Goedecke A, Keller C. Guided insertion of the ProSeal laryngeal mask airway is superior to conventional tracheal intubation by first-month anesthesia residents after brief manikin-only training. *Anesth Analg* 2006; **103**: 458–62
- Ferson DZ, Rosenblatt WH, Johansen MJ, Osborn I, Ovassapian A. Use of the intubating LMA-Fastrach in 254 patients with difficult-to-manage airways. *Anesthesiology* 2001; **95**: 1175–81
- Theiler LG, Kleine-Brueggenev M, Kaiser D, et al. Crossover comparison of the laryngeal mask Supreme and the i-gelTM in

- simulated difficult airway scenario in anesthetized patients. *Anesthesiology* 2009; **111**: 55–62
- 18 Keller C, Brimacombe JR, Keller K, Morris R. Comparison of four methods for assessing airway sealing pressure with the laryngeal mask airway in adult patients. *Br J Anaesth* 1999; **82**: 286–7
- 19 Pandit JJ, MacLachlan K, Dravid RM, Popat MT. Comparison of times to achieve tracheal intubation with three techniques using the laryngeal or intubating laryngeal mask airway. *Anaesthesia* 2002; **57**: 128–32
- 20 Liu EH, Goy RW, Lim Y, Chen FG. Success of tracheal intubation with intubating laryngeal mask airways: a randomized trial of the LMA Fastrach and LMA CTrach. *Anesthesiology* 2008; **108**: 621–6
- 21 Teoh WHL, Lim Y. Comparison of the single use and reusable intubating laryngeal mask airway. *Anaesthesia* 2007; **62**: 381–4
- 22 Francksen H, Renner J, Scholz J. A comparison of two endotracheal tubes for intubation via new I-gel™ laryngeal mask. *Eur J Anaesthesiol* 2009; **64**: 1118–24
- 23 Baskett PJ, Parr MJ, Nolan JP. The intubating laryngeal mask. Results of a multicentre trial with experience of 500 cases. *Anaesthesia* 1998; **53**: 1174–9
- 24 Kanazi GE, El-Khatib M, Nasr VG, et al. A comparison of a silicone wire-reinforced tube with the Parker and polyvinyl chloride tubes for tracheal intubation through an intubating laryngeal mask airway in patients with normal airways undergoing general anesthesia. *Anesth Analg* 2008; **107**: 994–7
- 25 Kristensen MS. The Parker Flex-Tip tube versus a standard tube for fiberoptic orotracheal intubation: a randomized double-blind study. *Anesthesiology* 2003; **98**: 354–8
- 26 Bamgbade OA, Macnab WR, Khalaf WM. Evaluation of the i-gel™ airway in 300 patients. *Eur J Anaesthesiol* 2008; **25**: 865–6
- 27 Gerstein NS, Braude DA, Hung O, Sanders JC, Murphy MF. The Fastrach Intubating Laryngeal Mask Airway: an overview and update. *Can J Anaesth* 2010; **57**: 588–601