

## 福島県立医科大学 学術機関リポジトリ



Title	Indications for partial superficial parotidectomy for benign parotid gland tumors using the retrograde approach
Author(s)	Suzuki, Masahiro; Nakaegawa, Yuta; Kobayashi, Tetsuro; Kawase, Tomotaka; Ikeda, Masakazu; Murono, Shigeyuki
Citation	Fukushima Journal of Medical Science. 66(2): 73-77
Issue Date	2020
URL	<a href="http://ir.fmu.ac.jp/dspace/handle/123456789/1320">http://ir.fmu.ac.jp/dspace/handle/123456789/1320</a>
Rights	© 2020 The Fukushima Society of Medical Science. This article is licensed under a Creative Commons [Attribution-NonCommercial-ShareAlike 4.0 International] license.
DOI	10.5387/fms.2020-06
Text Version	publisher

This document is downloaded at: 2021-11-05T05:20:46Z



## Indications for partial superficial parotidectomy for benign parotid gland tumors using the retrograde approach

Masahiro Suzuki, Yuta Nakaegawa, Tetsuro Kobayashi, Tomotaka Kawase,  
Masakazu Ikeda and Shigeyuki Muroho

*Department of Otolaryngology, Fukushima Medical University School of Medicine, Fukushima, Japan*

(Received March 3, 2020, accepted May 12, 2020)

### Abstract

A recent systematic review and meta-analysis suggest that retrograde parotidectomy is a safe procedure with no significant difference in facial nerve paralysis rates when compared to anterograde parotidectomy. The aim of the current study was to establish indications for partial superficial parotidectomy using the retrograde approach. To this end, the two surgical techniques were compared in terms of postoperative facial nerve paralysis, tumor size, location of the tumor, and surgical time. For tumor diameters of 30 mm or less, mean surgical time in the retrograde parotidectomy group was significantly shorter than in the anterograde parotidectomy group ( $p < 0.05$ ). Our study indicates that retrograde parotidectomy may be more effective than anterograde parotidectomy for partial superficial parotidectomy for benign parotid tumors of 30 mm or less.

**Key words :** superficial parotidectomy, parotid tumor, facial nerve

### Introduction

Most parotid gland tumors (80%) are benign<sup>1)</sup>, and the goal of parotidectomy is resection with facial nerve preservation. The usual approach to parotid tumors encompasses the identification of the facial nerve trunk near the tragal pointer and the posterior belly of the digastric muscle, and preparation of the nerve in an anterograde manner along its branches. This is defined as anterograde parotidectomy (AP)<sup>2)</sup>. The alternative approach is retrograde parotidectomy (RP), wherein peripheral branches of the facial nerve are identified first and then dissected posteriorly to the main trunk<sup>3)</sup>.

According to a previous study of benign parotid surgery in Great Britain, 4% of head and neck surgeons routinely used the retrograde approach only, while 9% used both anterograde and retrograde approaches<sup>4)</sup>. Benefits of RP have been reported to be a low incidence of facial nerve paralysis, shorter operating time, decreased intraoperative blood loss, and less removal of normal parotid tissue compared

with AP for benign parotid gland tumors<sup>5-7)</sup>. Furthermore, a recent systematic review and meta-analysis suggests that RP is a safe procedure with no significant difference in facial nerve paralysis rates when compared to AP<sup>2)</sup>. Surgeons engaged in parotidectomy, therefore, should be familiar with the retrograde approach in addition to the anterograde approach, which is an established and standard method for facial nerve identification<sup>2)</sup>. However, although there are several reports comparing RP with AP<sup>5,7-9)</sup>, few studies have focused on its indications for benign parotid tumors.

The aims of the current study were to compare the outcomes of anterograde and retrograde approaches in partial superficial parotidectomy for patients with benign parotid gland tumors, focusing on postoperative facial paralysis and surgical time, and to establish indications for partial superficial parotidectomy using the retrograde approach.

Corresponding author : Masahiro Suzuki E-mail : [suzuma@fmu.ac.jp](mailto:suzuma@fmu.ac.jp)

©2020 The Fukushima Society of Medical Science. This article is licensed under a Creative Commons [Attribution-NonCommercial-ShareAlike 4.0 International] license.  
<https://creativecommons.org/licenses/by-nc-sa/4.0/>

## Materials and methods

### Patients

A total of 85 patients with benign superficial parotid gland tumor treated at our institute between April 2006 and December 2017 were included in this study. No patients had facial nerve paralysis preoperatively; AP and RP were performed in 39 and 46 patients, respectively. This study was approved (No. 2247) by our institutional review board, which is guided by local policy, national law, and the World Medical Association Declaration of Helsinki.

### Surgical procedures

In all patients of the two groups, we used a bipolar nerve stimulator (Keisei nerve stimulator TS-260, Keisei Medical Industrial Co., Ltd., Tokyo, Japan) intraoperatively. The stimulation intensity was 30–50 Vp, and the duration of the stimulation was 150 ms. AP was performed using a standard approach for facial nerve identification. RP was performed with identification of the marginal mandibular branch of the facial nerve in 41 patients (89.1%), the buccal branch in four patients (8.7%), and the zygomatic branch in one patient (2.2%).

### Comparison of AP and RP

The two surgical techniques were compared in terms of postoperative facial nerve paralysis, tumor size, location of the tumor, and surgical time to establish indications for partial superficial parotidectomy using the retrograde approach.

### Statistical analysis

The data were evaluated with SPSS software, version 12 (SPSS, Chicago, IL). The Mann-Whitney U test was used to compare age, tumor size, and surgical time. The chi-squared test or Fisher exact test was used to compare sex, histopathology, facial nerve paralysis, and location of the tumor. A *p* value less than 0.05 was considered to be statistically significant. The described statistics are mean and standard deviation (SD).

## Results

### Patients characteristics

Patient ages ranged from 19 to 79 years, with a mean of 51.6 in the AP group and 54.9 in the RP group. There were 15 (38.5%) and 25 (54.3%) males and 24 (61.5%) and 21 (45.7%) females in the

Table 1. Clinical parameters for AP versus RP

Variable	AP ( <i>n</i> =39)	RP ( <i>n</i> =46)	<i>p</i> value
1. Age (years)			n.s.
Mean±SD	51.6±15.2	54.9±13.1	
2. Sex			n.s.
Male	15	25	
Female	24	21	
3. Histopathology			n.s.
Pleomorphic adenoma	26	23	
Warthin tumor	10	16	
Basal cell adenoma	2	3	
Lymphoepithelial cyst	1	1	
Oncocytoma	0	1	
Lymphoid tissue	0	2	

n.s. : not significant

AP and RP group, respectively, with no significant difference between the two (Table 1). The main histological types among the AP and RP group were pleomorphic adenoma in 26 and 23 patients, Warthin tumor in 10 and 16 patients, and basal cell adenoma in 2 and 3 patients, respectively. There were no significant differences of histopathological distribution between the two groups (Table 1).

### Characteristics of the tumor

The mean tumor size was 31.5 mm in the AP group and 31.6 mm in the RP group, with no significant difference between the two (Table 2). By previous report<sup>5)</sup>, the main localization of parotid tumors was divided into four parts: parotid tail, angle of mandible, pre-auricular, and near the mastoid area.

Table 2. Outcome variables for AP versus RP

Variable	AP ( <i>n</i> =39)	RP ( <i>n</i> =46)	<i>p</i> value
1. Facial nerve paralysis			
None	34	28	
Temporary	5	17	0.011
Permanent	0	1	n.s.
2. Clinical size (mm)			n.s.
Mean±SD	31.5±12.5	31.6±14.7	
3. Location			0.008
Parotid tail	15	33	
Angle of mandible	1	2	
Pre-auricular	6	5	
Near the mastoid area	17	6	
4. Surgical time (min)			n.s.
Mean±SD	150.9±38.2	144.4±60.5	

n.s. : not significant

In the AP group, the majority of parotid tumors were located in the parotid tail ( $n=15$ ) and near the mastoid area ( $n=17$ ). In the RP group, the parotid tumors were mostly found in the parotid tail ( $n=33$ ). There were significant differences in the locations of the tumors between the two groups (Table 2).

#### Facial paralysis

No paralysis was observed in 34 patients (87.2%) in the AP group and 28 patients (60.9%) in the RP group. Temporary paralysis was observed in 5 (12.8%) and 17 (37.0%) patients in the AP and RP groups, respectively, a significant difference ( $p < 0.05$ ). In the parotid tail, temporary paralysis was observed in 2 (13.3%) and 12 (36.4%) patients in the AP groups and RP groups, respectively, showing no significant difference. Near the mastoid, temporary paralysis was observed in 2 (11.8%) and 3 (50.0%) patients in the AP groups and RP groups, respectively, showing no significant difference. Among tumor diameters of 30 mm or less, it was observed in 2 of 23 (8.7%) and 9 of 29 (31.0%) patients in the AP and RP groups, respectively, showing no significant difference. Among tumor diameters of more than 30 mm, it was observed in 3 of 16 (18.8%) and 8 of 16 (50.0%) patients in the AP and RP groups, respectively, showing no significant difference. None in the AP group had permanent paralysis while one patient had it in the RP group, showing no significant difference (Table 2).

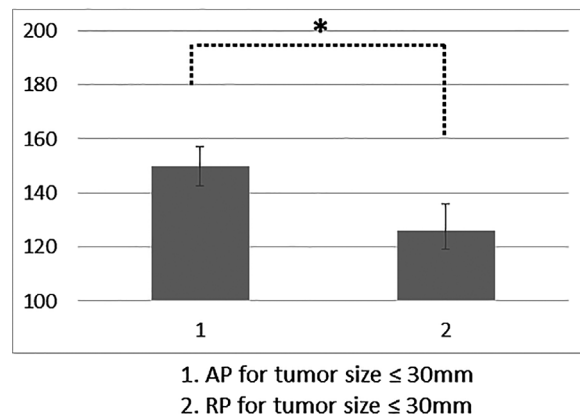
#### Surgical time

The mean surgical time of all 85 patients was 147.4 minutes: 150.9 minutes in the AP group and 144.4 minutes in the RP group, with no significant difference between the groups (Table 2). For tumor diameters of 30 mm or less, the mean surgical times were 148.7 and 124.2 minutes in 23 AP cases and 30 RP cases, respectively. The mean surgical time of the 30 RP cases was significantly shorter than that of the 23 AP cases ( $p < 0.05$ , Figure 1). For tumor diameters of more than 30 mm, the mean surgical times were 154.0 and 182.3 minutes in 16 AP cases and 16 RP cases, respectively. This difference did not achieve statistical significance (Figure 2).

### Discussion

In surgery for a parotid gland tumor, it is essential to dissect the tumor from the surrounding normal parotid tissue without exposure of the tumor

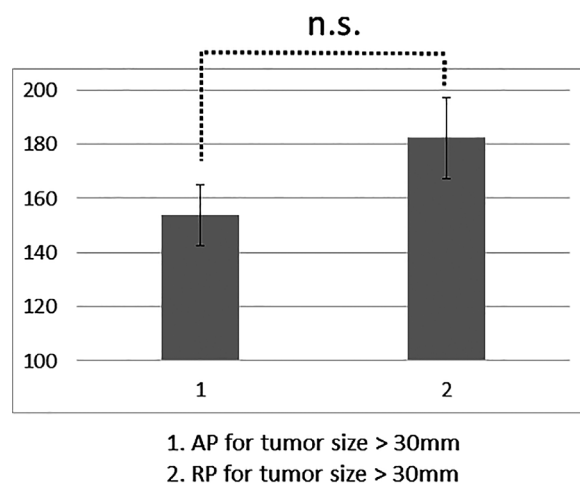
#### Mean surgical time in minutes



\* :  $p < 0.05$

Figure 1. For tumor diameters of 30 mm or less, the mean surgical time of the RP group was significantly shorter than that of the AP group ( $p < 0.05$ ).

#### Mean surgical time in minutes



n.s. : not significant

Figure 2. For tumor diameters of more than 30 mm, the difference of the mean surgical times was not significant between the AP and RP groups.

capsule and to preserve the facial nerve intact<sup>7</sup>).

In this study, when the tumor diameter was 30 mm or less, the incidence of temporary paralysis was not significantly different between the AP and RP groups, but the surgical time of RP was significantly shorter than that of AP. This is in agreement with a report by Emodi *et al.*, that RP should be used when the tumor size is small<sup>5</sup>. Therefore, we consider that a tumor diameter of 30 mm or less can be an indication for using the retrograde approach. However, although it was not significant, there was a

trend toward relatively higher incidence of temporary paralysis in the RP group than the AP group in those lesions. Although duration and grade of temporary paralysis were not examined in detail, the temporary paralysis of almost all patients recovered within six months in both AP and RP groups. Still, there is room for improvement. Other advantages of RP over AP include having more parotid tissue after surgery, better sensory preservation around the auricle, and lower risk revision surgery<sup>2)</sup>. As for lesions located at the tail of the parotid gland, RP using the marginal mandibular branch was often chosen. In those cases, the great auricular nerve, which is usually sacrificed with AP, can be preserved in RP using the marginal mandibular branch. If the main trunk of the facial nerve is not exposed in the primary RP, standard AP is possible in a revision surgery for a recurrent parotid gland tumor.

AP is the most established and widely used technique in parotid surgery. With the AP technique, the main trunk of the facial nerve is identified via its relationship with the tympanomastoid suture, the tragal pointer, or the posterior belly of the digastric muscle<sup>5)</sup>. According to Witt *et al.*<sup>10)</sup>, the tympanomastoid fissure is a key structure used to find the main trunk of the facial nerve, located 2 to 4 mm inferior to the tragal pointer.

RP is a surgical technique that starts with identification of the peripheral branches of the facial nerve for facial nerve preservation. In their cadaveric study, Zhong and Ashwell found that the distance from the angle of the mandible to the marginal mandibular branch of the facial nerve is short. The angle of the mandible is the preferred landmark in RP<sup>11)</sup>. RP is not commonly performed and few studies have focused on indications for RP for benign parotid tumors. Stankovic *et al.* stated that RP is technically more challenging and, therefore, young surgeons should familiarize themselves with AP first<sup>2)</sup>. Surgeons engaged in parotid surgery should be familiar with both methods of parotidectomy. Guntinas-Lichius *et al.* reported that both methods were necessary in 25% of patients undergoing parotidectomy for benign parotid disease<sup>12)</sup>.

Facial nerve paralysis is one of the major concerns of surgery for benign parotid gland tumor.

In a systematic review, there was no significant difference between the AP and RP groups in the pooled odds ratio for either temporary or permanent facial nerve paralysis<sup>2)</sup>. In addition, according to the same review<sup>2)</sup>, temporary facial nerve paralysis was noted in 18.2% and permanent facial nerve paralysis occurred in 0.9% of patients treated with RP.

In the current study, temporary facial nerve paralysis was noted in 32.6% (15/46) and permanent facial nerve paralysis occurred in 2.1% (1/46) of patients treated with RP. The incidence of temporary facial nerve paralysis among our patients seemed to be relatively higher than that of the systematic review. One of the possible reasons is that peripheral branches of the facial nerve are thinner than the main trunk, which may make it difficult to trace the facial nerve protectively. Secondly, in some patients in the RP group, the peripheral branches of the facial nerve might be mistaken for cervical nerves, which are sensory nerves, because of their possible anastomosis. Domet *et al.* reported that 33 anastomoses were identified in 22 adult necks between the cervical branch and the transverse cervical cutaneous nerve<sup>13)</sup>. Thirdly, partial superficial parotidectomy was frequently performed by younger surgeons in our hospital.

This might affect the slightly longer mean surgical time of RP at our hospital, 144.6 minutes, compared with previous studies reporting that it ranged from 68.4 to 145 minutes<sup>2)</sup>.

Our study is retrospective and has some limitations. Firstly, selection bias cannot be ruled out in terms of the significant differences in the locations of the tumors between the AP and RP groups. Secondly, the influence of the surgeons' experience was not examined.

## Conclusions

Although AP is a basic and reliable method, RP is comparable to it with regard to the occurrence of permanent facial nerve paralysis as well as surgical time. Our study indicates that RP may be more effective than AP for partial superficial parotidectomy for benign parotid gland tumors of 30 mm or less. Further studies are necessary to establish indications for partial superficial parotidectomy using the retrograde approach.

## Conflict of interest disclosure

The authors declare no conflicts of interest associated with this manuscript.

## References

1. Spiro RH. Salivary neoplasms : overview of a 35-year experience with 2,807 patients. *Head Neck Surg*, **8** : 177-184, 1986.
2. Stankovic P, Wittlinger J, Timmesfeld N, Stephan

- SH, Georgiew R, Günzel T, *et al.* Antero- vs. retrograde nerve dissection in parotidectomy : a systematic review and meta-analysis. *Eur Arch Otorhinolaryngol*, **275** : 1623-1630, 2018.
3. Kligerman MP, Song Y, Schoppy D, Divi V, Megwalu UC, Haughey BH, *et al.* Retrograde Parotidectomy and facial nerve outcomes : A case series of 44 patients. *Am J Otolaryngol*, **38** : 533-536, 2017.
  4. O'Regan B, Bharadwaj G, Elders A. Techniques for dissection of the facial nerve in benign parotid surgery : a cross specialty survey of oral and maxillofacial and ear nose and throat surgeons in the UK. *Br J Oral Maxillofac Surg*, **46** : 564-566, 2008.
  5. Emodi O, El-Naaj IA, Gordin A, Akrish S, Peled M. Superficial parotidectomy versus retrograde partial superficial parotidectomy in treating benign salivary gland tumor (pleomorphic adenoma). *J Oral Maxillofac Surg*, **68** : 2092-2098, 2010.
  6. Bhattacharyya N, Richardson ME, Gugino LD. An objective assessment of the advantages of retrograde parotidectomy. *Otolaryngol Head Neck Surg*, **131** : 392-396, 2004.
  7. Furusaka T, Tanaka A, Matsuda H, Hasegawa H, Asakawa T, Shigihara S. Cervical branch of the facial nerve approach for retrograde parotidectomy compared with anterograde parotidectomy. *Acta Otolaryngol*, **134** : 1192-1197, 2014.
  8. O'Regan B, Bharadwaj G. Comparison of facial nerve injury and recovery rates after antegrade and retrograde nerve dissection in parotid surgery for benign disease : prospective study over 4 years. *Br J Oral Maxillofac Surg*, **49** : 286-291, 2011.
  9. Anjum K, Revington PJ, Irvine GH. Superficial parotidectomy : antegrade compared with modified retrograde dissections of the facial nerve. *Br J Oral Maxillofac Surg*, **46** : 433-434, 2008.
  10. Witt RI, Weinstein GS, Rejto IK. Tympanomastoid suture and digastric muscle in cadaver and live Parotidectomy. *Laryngoscope*, **115** : 574-577, 2005.
  11. Zhong W, Ashwell K. A cadaveric study of surgical landmarks for retrograde parotidectomy. *Ann Med Surg (Lond)*, **9** : 82-85, 2016.
  12. Guntinas-Lichius O, Klussmann JP, Wittekindt C, Stennert E. Parotidectomy for benign parotid disease at a university teaching hospital : outcome of 963 operations. *Laryngoscope*, **116** : 534-540, 2006.
  13. Domet MA, Connor NP, Heisey DM, Hartig GK. Anastomoses between the cervical branch of the facial nerve and the transverse cervical cutaneous nerve. *Am J Otolaryngol*, **26** : 168-171, 2005.