

## Brief Communications

# Brief note on infestation of *Diplectanum* sp. in Asian seabass

Kurva Raghu Ramudu<sup>1\*</sup>, Saloni Shivam<sup>1</sup>, N. K. Sanil<sup>2</sup>, P. Vijayagopal<sup>2</sup>, P. P. Suresh Babu<sup>1</sup>, A. Anuraj<sup>1</sup>, N. G. Vaidya<sup>1</sup>, K. Navanath K<sup>1</sup> and Jayasree Loka<sup>1</sup>

<sup>1</sup> Karwar Research Centre of ICAR-Central Marine Fisheries Research Institute, Karwar, Uttara Kannada-581 301, Karnataka

<sup>2</sup> ICAR-Central Marine Fisheries Research Institute, Kochi-682 018, Kerala

\*E-mail: ram.raghu77@gmail.com

Recently open sea cage farming has emerged as an alternative and additional income source for fishermen and fish farmers in India. Asian seabass, *Lates calcarifer* is widely used in open sea cage culture due to its high market demand. In cage farming, high stocking densities and poor water quality enhance the parasite loads of the cultured fishes. In this study, 47 specimens of Asian seabass collected from cages located in Naganathwada, Sunkeri, Ankola were analysed with the aim of identifying the parasites prevalent among this species. All external and internal organs of each fish were examined separately under microscope for parasites. The collected monogenean parasites were washed in a 0.85% saline solution and fixed in 70% ethanol and identified. Most of the infected fishes had dark coloration of the body and postmortem findings revealed gills with excessive mucus secretion and sticking of the gill tips with greyish coloration. Heavy infestations can induce a range of histopathological changes to the epithelium, which facilitates the invasion and establishment of a range of secondary bacterial, viral and fungal infections. This study revealed the prevalence of infection with *Diplectanum* sp. was high in Sunkeri followed by Ankola and Naganathwada while severity of infection was same in all the three locations. No mortality due to this infestation was recorded but these parasites can induce stress, reduce the fitness of the host and risk other secondary infections. Hence, screening for the presence of these parasites at regular intervals to take precautionary measures for their control and prevention is needed.

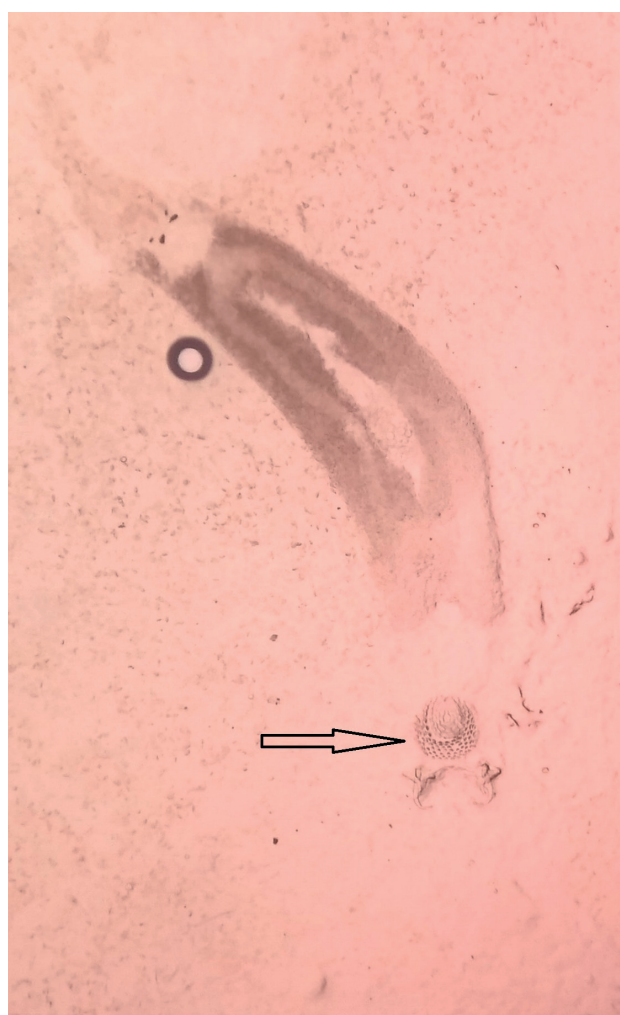


Fig.1. *Diplectanum* sp. (400x) with squamodisc indicated