

Characterization, passive and active treatment in strabismic amblyopia: a narrative review

Myriam Milla^{1,2}, David P. Piñero²

¹Department of Optometry, OFTALVIST Alicante, Alicante 03016, Spain

²Group of Optics and Visual Perception, Department of Optics, Pharmacology and Anatomy, University of Alicante, San Vicente del Raspeig, Alicante 03690, Spain

Correspondence to: David P. Piñero. Department of Optics, Pharmacology and Anatomy, University of Alicante, Crta San Vicente del Raspeig s/n 03016, San Vicente del Raspeig, Alicante 03690, Spain. david.pinyero@ua.es

Received: 2019-08-23 Accepted: 2020-03-15

Abstract

• Strabismic amblyopia is characterized by a distorted spatial perception. In this condition, the neurofunctional disorder occurring during first years of life provoke several monocular and binocular anomalies such as crowding, deficits in the accommodative response, contrast sensitivity, and ocular motility abilities. The inhibition of the binocular function of the brain by the misaligned amblyopic eye induces a binocular imbalance leading to interocular suppression and the reduction or lack of stereoacuity. Passive treatments such as occlusion, optical and/or pharmacological penalization, and Bangerter foils has been demonstrated to be potentially useful treatments for strabismic amblyopia. Recent researches have proved new pharmacological options to improve and maintain visual acuity after occlusion treatment in strabismic amblyopia. Likewise, the active vision therapy, in the last years, is becoming a very relevant therapeutic option in combination with passive treatments, especially during and after monocular therapy, in the attempt of recovering the imbalanced binocular vision.

• **KEYWORDS:** amblyopia; strabismus; occlusion; vision therapy; strabismic amblyopia; penalization; Bangerter foil

DOI:10.18240/ijo.2020.07.18

Citation: Milla M, Piñero DP. Characterization, passive and active treatment in strabismic amblyopia: a narrative review. *Int J Ophthalmol* 2020;13(7):1132-1147

AMBLYOPIA: GENERAL DESCRIPTION

Amblyopia (lazy eye) is described as a limitation of the visual function of one or both eyes with no pathological cause. It is a disorder of spatial vision which cannot be improved by refractive correction^[1]. Clinically, amblyopia can be defined as the presence in one or both eyes of a visual acuity of 6/12 or worse, with one or more lines of difference in visual acuity between eyes in unilateral amblyopia^[2]. This condition is an alteration of the visual cortex function which is due to suppression and deprivation of one eye leading to unilateral visual deterioration^[3].

The first binocular experience begins at birth and the development is almost complete at 24mo of age^[4]. At this stage of life, any obstacle impeding the brain from receiving correctly a clear and similar image from each eye may lead to the development of amblyopia^[4]. Likewise, the longer the duration of the abnormal visual experience, the higher the level of amblyopia is^[5]. If the images from both eyes are not similar, the phenomenon of retinal rivalry appears, which is the capacity of the visual system to detect and discriminate those fusionable stimuli from those which are not.

Amblyopia has been considered structurally monocular^[6-8] and the correction of the abnormal visual input and penalisation of the “normal” input has been considered the mainstay of therapy for amblyopia^[9]. The neural mechanisms of amblyopia are not completely understood even though they have been investigated with electrophysiological recordings in animal models and more recently with innovative neuroimaging techniques in humans^[10]. New research is being developed on neuronal rivalry due to early functional imbalance^[11] between both eyes in amblyopia and neural plasticity in adult patients^[12].

Binocular vision is the sum of sensorial and motor balance in the first months of life. If there is any anatomical-physiological failure in this phase of development, a functional imbalance between both eyes is created. Binocular competition is what determines which eye is dominant. The information that the brain receives from each eye can be modified by different functional anomalies, leading to amblyopia. Depending on such functional anomalies, the following types of amblyopia can be defined.

Anisometropic or refractive amblyopia: this sensorial alteration is produced by a refractive error and by a significant difference in the magnitude of such error between both eyes. In this latter case, the brain receives two projected images of different sizes. The greater the difference, the more difficult is the fusion of images from both eyes to create one single three-dimensional image. The most common refractive errors with a high amblyopiogenic value, from more to less effect, are hyperopia, astigmatism, and myopia.

Strabismic amblyopia: caused by the deviation in one of the eyes. In this case, the brain receives two different images with different spatial projection, one of them coming from the eye with the squint. This situation leads to a neuronal vulnerability as the brain cannot create a combination of images from both eyes to generate a stereoscopic vision.

Furthermore, both refractive and strabismic amblyopia can coexist in the same patient resulting in mixed anisometropic amblyopia, which is the combination of a refractive error and the misalignment of one eye. Another cause for amblyopia is the presence of a specific pathology inducing an abnormal entry of visual information due to corneal lesions, congenital cataracts and ptosis^[13] at a young age, avoiding the generation of a normal binocular experience. Because of the above-mentioned options, there is a dramatic loss of visual acuity in an apparently healthy eye and some other perceptual anomalies including deficits in contrast sensitivity and stereopsis^[14].

Good anatomical and physiological balance of the eyes is not the only requirement for a functional binocular vision. A correct development of all the monocular functions is also necessary to transform the information coming from each one in a three-dimensional perception. The following monocular functions can be altered in strabismic, anisometropic or mixed amblyopia.

Accommodative response: amblyopia does not only have a negative effect on visual acuity, but also creates an unequal accommodative response between the amblyopic and dominant eye. There is a marked limitation of the accommodative response in almost all the spatial frequency range due to an early abnormal visual experience associated with the presence of squint and/or anisometropia^[15], with a prolonged effect on the sensory visual system^[16].

Crowding: this phenomenon is more characteristic of strabismic amblyopia. This effect in the amblyopic eye is a simultaneous fixation originated around the fixation zone, the fovea. The effect is that there are multiple interferences in the images which result in an unclear image at the cortical level coming from the amblyopic eye. The critical distance for crowding increases with retinal eccentricity^[17-18].

Contrast sensitivity: defined as the inverse of contrast threshold which is the least contrast necessary to perceive a stimulus.

Strabismic amblyopia is characterized by a high spatial frequency disorder, whereas in anisometropic amblyopia the limitation in sensitivity is across the whole frequency range^[19-22].

Ocular motility: the behaviour of ocular motility has been assumed to be another disorder of strabismic amblyopia^[23]. Hand-eye coordination^[24] is associated to a reduction in the ability of movement cortical control due to amblyopia^[23]. Eccentric fixation has its origins in an increase in the saccade reaction time to starting a movement^[24] and asymmetric saccades to tracking movements during reading. Defective spatial localization is also an important feature of strabismic amblyopia^[25-26]. Amblyopia in general is associated with slower reading speed in school-age children^[27].

The sensory rivalry in the visual cortex on the part of the dominant eye is an effect of an inhibitory activation of the visual information from the amblyopic eye. This cortical phenomenon which occurs in conditions of binocular vision has been catalogued throughout clinical history as "suppression", "neutralisation", "inhibition" or "exclusion". The first author who developed this concept occurring in amblyopia was Javal. This phenomenon is a mechanism in the brain faced with different stimuli coming from both eyes during the development of binocular vision. According to this, a scotoma is developed to avoid diplopia and confusion. The suppression can be present in both types of amblyopia, anisometropic (the difference between images in size and contrast) and strabismic (the difference in spatial projection). One study performed an experiment to evaluate the degree of suppression in patients with strabismic, anisometropic and mixed amblyopia^[28], measuring the degree of suppression in 42 amblyopic patients. The results of this study demonstrated that a stronger suppression was associated with greater interocular difference in visual acuity and a weaker stereopsis. Patients with strabismus presented stronger interocular suppression^[29-30] than anisometropic amblyopia^[31].

Recently, the measurement of the suppression has been shown to have a prognostic value for occlusion therapy^[28]. Considering the role of suppression in amblyopia, new therapeutic options such as the use of dichoptic tools^[32] to measure and treat suppression leading to better monocular and binocular results have been developed.

The main objective of this review is to widen the knowledge about strabismic amblyopia, analyzing the bases of the currently available clinical treatments.

In summary, the following monocular clinical findings can be observed in strabismic amblyopia: reduces visual acuity (far or near distances) in amblyopic eye; reduced contrast sensitivity, mainly for high spatial frequencies; eccentric fixation; reduced accommodative response; crowding effect

due to unstable foveal fixation; reduces spatial localization; Anomalous oculomotor behaviour: slower saccadic movements.

Binocularly, the following conditions can be observed in strabismic amblyopia: interocular suppression due to active cortical inhibition from dominant eye in binocular vision conditions, anomalous retinal correspondence (ARC), and lack of stereopsis.

Epidemiology and Risk Factors Strabismus develops in approximately 5% to 8% of the general population^[33]. The visual cortical structure is generated during fetal development in the absence of external causes and without any light stimuli. There is a consensus in the literature that there is a significant hereditary component in the cause of strabismus^[34]. In addition, strabismic amblyopia is present within the first year of life in a great part of cases^[35]. Early diagnosis, strabismus surgery^[36], and active and/or passive^[37-38]. Adequate treatment selection are important factors to recover the binocular imbalance.

Bilateral and Unilateral Sensory Adaptation: Eccentric Fixation and Anomalous Sensorial Correspondence The success of the treatment in amblyopia depends on a complete and early examination, analyzing sensory and motor factors that can affect the development of binocular vision^[34-35]. Before six months old, the visual system is only monocular, and the fovea fixation is important to initiate a normal binocular vision. An image must be projected in the macular area called fovea. In addition, in the fovea, there is a higher density of cells called cones providing the maximum visual acuity^[39]. The development of the fusion starts from the fovea maturation at around six months of life. In this period, if a sensorial and/or motor imbalance occurs due to different types of amblyopia, suppression will be active in the visual cortex^[28]. In addition, there will be an anomalous binocular adaptation to connect the information coming from both eyes.

Strabismus amblyopia is characterized by an imbalance of the sensorial and motor system. Differences between both eyes due to a squint during the first months of life can originate an eccentric fovea fixation and ARC^[40], which is a binocular condition generated by the absence of a correct bifoveal fixation.

Eccentric Fixation Eccentric fixation is a monocular sensorial disorder associated with a unilateral and constant eye deviation, as happens in strabismic amblyopia^[40]. This condition can be also present in non-strabismic cases, causing a drastic reduction of visual acuity and contrast sensitivity, as well as a loss of directional monocular capacity^[39].

The degree of eccentricity of fixation is defined as the distance where the fixation point is located with respect to the fovea in the non-dominant eye and can be nasal or temporal depending on the type of strabismus^[41-42]. The fixation can be stable or unstable and the position of eccentric fixation is analysed

under monocular conditions, with an ophthalmoscopy-based observation technique called visuscopy^[40]. It can be also measured with subjective techniques depending on the patient's answer, such as the use of the Haidinger brush^[43], which is only perceived by the fovea. Currently, new imaging objective methods have been developed to measure eccentric fixation such as the use of optical coherence tomography (OCT) systems^[40,44] (Figure 1) and microperimeters^[41]. The OCT allows a complete analyse of the macula area for pathology screening but also can be used to quantify fixation changes before and after amblyopic treatments^[40]. Likewise, it has been demonstrated that the foveolar thickness in eyes with moderate to severe amblyopia is significantly greater than in the non-amblyopic eye^[42].

Occlusion, opaque contact lenses, vertical prisms, and pleoptic methods have been used for eccentric fixation treatment^[45]. In order to weaken a stable eccentric fixation, occlusion in the amblyopic eye is employed. In this way, in the absence of light, the fixation becomes unstable and the dominant eye occlusion should be the following step of the treatment. Concerning pleoptics, its use started around the 1950s. Bangerter and Cüppers were the main authors who used them to treat eccentric fixation in amblyopia^[46], being Bangerter the first clinician using the pleoptic methods (pleoptophor and cheiroscope)^[47] and reporting his experience with them. Afterwards, Cüppers simplified and modified these methods for a more general use by clinicians including instruments, such as the visuscope, euthyscope, flickering light and the coordinator^[48].

In strabismic amblyopia treatment, the most effective option for total or partial improvement in eccentric fixation was the combination of pleoptic methods with conventional occlusion (Table 1)^[45,47-50]. In cases of a non-effective occlusion therapy, pleoptic and orthoptic techniques may lead to an improvement in patients with strabismic amblyopia and eccentric fixation^[47,49]. Another application of Cüppers methods was the evaluation of the macular fixation reflex to early diagnosis in the prevention of amblyopia^[51].

In summary, pleoptic methods (Bangerter and Cüppers) emerged as an early stimulation of foveal fixation in infants with strabismic amblyopia. Eccentric fixation is vulnerable and treatable by occlusion or passive treatment, but active treatment seems to be necessary to maintain central fixation in some cases^[52]. Some forms of pleoptic and orthoptic treatment have been implemented and combined nowadays and defined as active visual therapy.

Anomalous Sensorial Correspondence Strabismic amblyopia is not only a monocular condition, it can also lead to a binocular disorder. Specifically, the dominant fovea originates a sensorial correspondence in the other eye without foveal

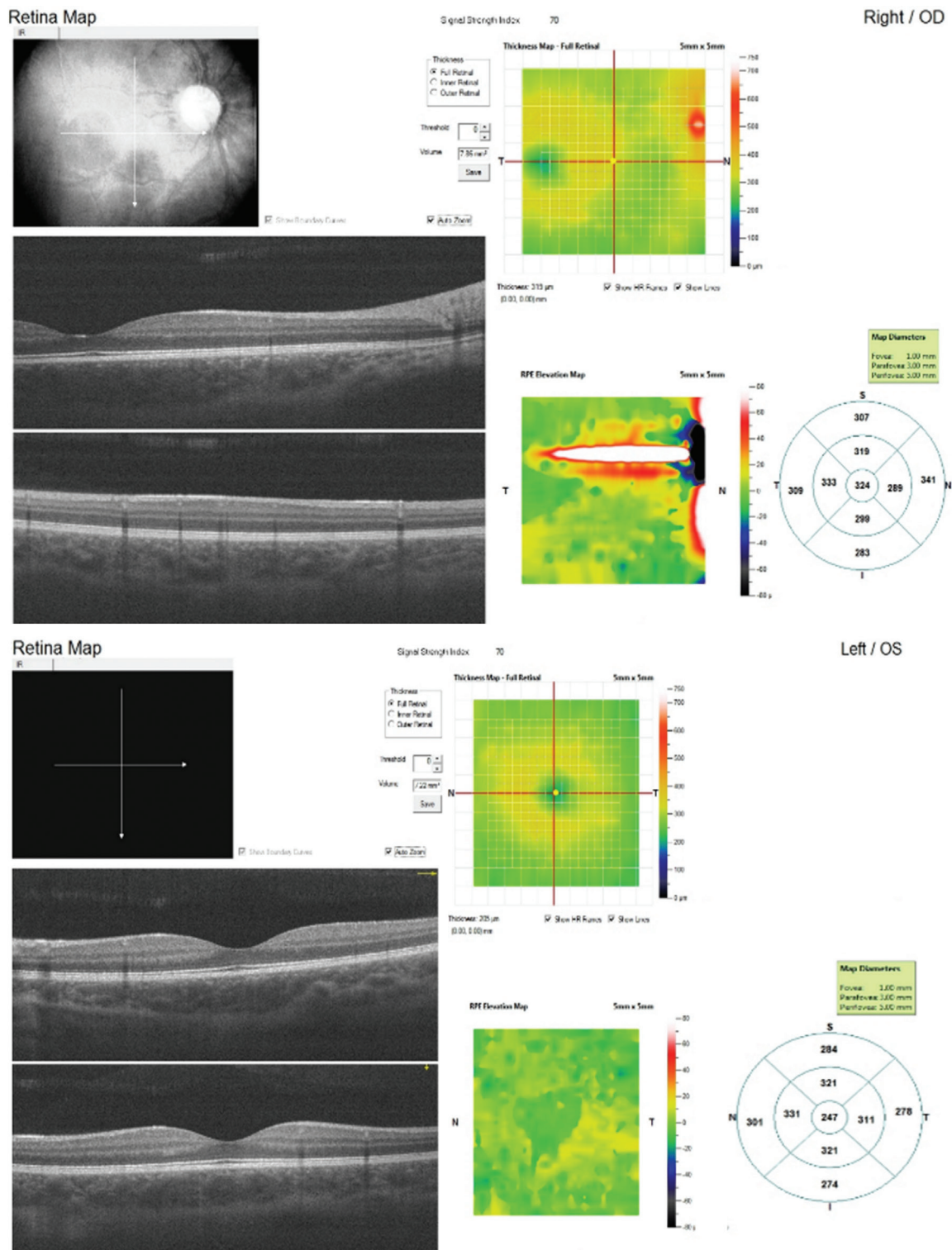


Figure 1 Eccentric fixation characterized by OCT in a 12-year child with strabismic amblyopia in right eye.

fixation to simulate a binocular vision. As foveal fixation is not possible in the strabismic eye, the visual directions of both eyes are not coincident, and an anomalous correspondence can be generated. This condition is called ARC. In other words, an anomalous binocular vision may be induced with some types of strabismus as some other sensorial binocular mechanisms including suppression, confusion or diplopia^[53]. The degree of strabismus and the stability of fixation are critical factors influencing on this sensorial adaptation.

When normal retinal correspondence (NRC) is present, bifoveal fixation exists after the correction of the deviation, with both eyes having the same point of monocular direction. In such case, the objective deviation measured by cover test or sinoptophore^[54] coincides with the subjective deviation. However, if ARC is present, bifoveal fixation is not possible because monocular directions of both eyes are not the same, with the presence of a minimal angle or degree of strabismus, called microtropia^[55] or microstrabismus, even after surgery

Clinical management of strabismic amblyopia

Table 1 Summary of the main clinical findings of the use of pleoptics in strabismic amblyopia with eccentric fixation

Authors	Main objectives	Year	Patients	Treatment	Main results
Vonnoorden and Lipsius ^[48]	To analyse the pleoptic therapy results in strabismic amblyopia	1964	58 strabismic amblyopia	Direct or inverse patching Cüppers and Bangerter pleoptics	Pleoptics did not produce a significant improvement of visual acuity
VerLee & Iacobucci ^[45]	To evaluate the results (visual acuity and central fixation) of treatment with Cüppers pleoptic method and occlusion	1967	100 strabismic amblyopia	50 patients with Cüppers 50 patients with full-time occlusion (dominant eye)	Occlusion was better than pleoptic therapy in all age range
Schmidt & Stapp ^[49]	To compare the results of occlusion and euthyscope together with occlusion	1977	63 strabismic amblyopia (average age 7y)	Group with occlusion Group with euthyscope followed by occlusion	No significant difference was apparent after comparison of both forms of treatment Four of 6 patients with occlusion (without success) therapy improved with pleoptics followed by further occlusion
Jablonski & Tomlinson ^[47]	To evaluate pleoptic and orthoptic methods after no effective occlusion treatment	1979	64 patients (4-17y) with amblyopia (20/30-20/100)	Pleoptic+orthoptic	After therapy, 64 patients achieved 20/30 or better 25 patients achieved stereopsis After therapy, visual acuity was followed in 27 patients and 88% maintained 20/30 or better of visual acuity (fusion or ARC)
Bogdan ^[50]	To analyse the results of pleoptic together with occlusion	1992	161 strabismic amblyopia	Active treatment with amblyophor and occlusion	A total cure was found in 38%, improvement in 46% and fail in 16% of cases

ARC: Anomalous retinal correspondence.

or prism treatment. It should be considered that ARC, central scotoma, reduced or absent stereopsis, amblyopia and eccentric fixation are considered special characteristics of microtropia^[40]. Eccentric fixation is a failure of the monocular directional capacity whereas ARC is a binocular vision disorder leading to an anomalous correspondence between eyes.

Concerning microtropia^[54] or monofixation syndrome^[55], there are some hypotheses about sensorial adaptations in this condition. Parks^[56] concluded that small angle deviation and a binocular projection leading to a peripheral binocular condition are present in microtropia or monofixation syndrome. According to Lang in 1983^[57], 1% of the general population has microstrabismus of less than 5 degrees. In addition, this author stated that microtropia may be primary constant, primary decompensating or secondary. Microtropia can be defined as with or without identity depending if the deviation can be detected or not with the cover test^[58]. Some theories and potential etiologies have been described for microtropia, such as genetic default, suppression, insufficient correction of hyperopia, insufficient strabismus surgery or an imperfectly cured amblyopia^[59].

The management of microtropia has been suggested to be based on treating anomalous correspondence with after-images and on performing intensive postoperative orthoptic training as a solution for small residual deviations^[58]. Diplopia and the impossibility of obtaining bifoveal fixation and full stereoacuity may be risks of microtropia treatment. However, a study performed by Houston *et al*^[59] in 1993 contradicts these risks. This study showed the results of the treatment (mid-time occlusion therapy and close work during patching) of 30

patients with microtropia (eccentric fixation and ARC). These authors reported that 21 of these patients improved stereopsis to levels of 60-120s of arc or better. Another study evaluating the results of microtropia treatment with occlusion therapy was conducted by Cleary *et al*^[58]. In this series, NRC, improvement of visual acuity to 6/5 and stereopsis to 30s of arc were observed after treatment in 7 patients^[58]. Scientific evidence on the efficacy of orthoptic methods to treat microtropia in strabismic amblyopia has not been reported.

Passive Treatment of Strabismic Amblyopia Optical correction is the first step before the selection of the adequate therapy to treat the visual reduction in strabismic amblyopia. The relationship between accommodation and convergence must be considered in esotropia and amblyopia therapy. Infant refractive correction substantially reduces accommodative esotropia and amblyopia incidence, with no interference in the emmetropization process^[60]. Correcting refractive errors in one or both eyes produces an equal accommodative response, as well as an improved and stable visual acuity in both eyes (Table 2)^[61]. Therefore, the prescription of refractive correction should be considered as the sole initial treatment for children with strabismic or mixed amblyopia (Table 2)^[62-64]. Improved visual acuity before initiating other types of treatments would presumably make occlusion or penalisation therapies less onerous, improving compliance and avoiding unnecessary patching^[61-62,65]. Contact lenses, including opaque contact lenses for patching^[66], and bifocal optical lenses are other alternatives of refractive correction in strabismic amblyopia. Besides optical correction, controversy about the correct treatment of strabismic amblyopia remains despite the

Table 2 Summary of the main clinical findings of optical correction that can be observed in strabismic amblyopia according to scientific peer-reviewed literature

Authors	Type of study	Main objectives	Year	Patients	Treatment	Main results
Stewart <i>et al</i> ^[62]	Retrospective study	To describe the visual response to spectacle correction (“refractive adaptation”)	2004	Strabismic (<i>n</i> =16) mixed (<i>n</i> =31) and anisometric (<i>n</i> =18) amblyopia patients Mean age 5.1±1.4y	Optical correction only	Average of visual acuity improvement in the 3 types of amblyopia (from 0.67±0.38 to 0.43±0.37 logMAR) Regardless of amblyopia type, refractive adaptation should be a first state before any therapy
Cotter <i>et al</i> ^[64]	Prospective, interventional case series	To report data on the response of previously untreated strabismic amblyopia to spectacle correction	2007	12 strabismic amblyopia patients	Optical correction only	Visual acuity improved a mean of 2.2±1.8 lines 2 lines or more in the amblyopic eye in 9 patients 3 patients had only interocular difference ≤1 line
Cotter <i>et al</i> ^[63]	Prospective, multicentre, cohort study	To determine visual acuity improvement with optical adaptation in children with strabismic and combined strabismic-anisometric	2012	146 children with strabismic (<i>n</i> =52) and mixed (<i>n</i> =94) amblyopia patients	Optical correction only	Visual acuity improved a mean of 2.6 lines Resolution of amblyopia occurred in 32% More improvement of visual acuity in strabismic amblyopia (strabismic 3.2 vs mixed 2.3)

available scientific evidence. The negative impact on school-aged children, the true fulfilment of occlusion time and the new options for treatment in adult patients have led to new forms of amblyopia management. Occlusion, pharmacological and/or optical penalization, and Bangerter foils are the classical methods for amblyopia treatment. New pharmacological medications, such as Levodopa or Carbidopa, perceptual learning, dichoptic training, the use of virtual reality and transcranial stimulation are new options under investigation currently.

Occlusion Direct occlusion (patching on the dominant eye) has been considered as a standard treatment in all types of amblyopia, including strabismic amblyopia. Full-time occlusion was the overriding treatment during many years as amblyopia was considered a monocular problem. However, the degree of residual binocularity and interocular suppression have been shown to predict the monocular visual acuity, being a significant etiological mechanism of vision loss in amblyopia^[67]. Several studies have confirmed that the average improvement in visual acuity is better in mixed anisometric amblyopia than in strabismic amblyopia^[67-71].

Another concern after cessation of patching is the recurrence of amblyopia, with approximately one fourth of successfully treated amblyopic children experiencing a recurrence within the first year after treatment^[72]. The risk of recurrence is greater when patching is stopped abruptly^[73-74] and microstrabismus is present^[75].

Less intensive occlusion treatments can be successful in strabismic amblyopia (Table 3)^[75-80]. The accommodation stimulation during occlusion time has been proved to improve visual acuity in strabismic amblyopia (Table 3)^[81-87]. It should be considered that the accommodative response is mainly mediated by the level of focusing at fovea. Therefore,

the performance of near vision activities as well as direct accommodative training are simultaneously generating some type of fixation training, although in some cases additional active treatment with pleoptic methods may be necessary. Then, occlusion therapy combined with near activities is not only promoting an improvement of visual acuity but also in the accommodative range and even in contrast sensitivity, which are normally deficient in the strabismic eye.

Finally, the efficacy of occlusion therapy has been shown to be not so dependent on patient’s age. Indeed, strabismic amblyopia has been demonstrated that can be recovered after 6y^[66]. According to the peer-reviewed literature revised on patching in strabismic amblyopia, 2 to 6h of occlusion seems to be the most adequate option in moderate amblyopia. The combination of 6h of occlusion and near activities or vision therapy is the most optimum protocol to follow in severe amblyopia.

Drug Therapy

Atropine Atropine is one option of passive treatment called pharmacological penalization^[88]. It is administered topically in the dominant eye, manipulating the refractive status of the eye and a thereby affecting alignment, focus and amblyopia^[89]. The atropine effectiveness alone or together with other methods has been evaluated as a passive therapy of treatment in strabismic amblyopia patients (Table 4)^[90-99].

As occlusion treatment, the atropine protocol has been modified and reduced but trying to maintain the same effectiveness. “Weekend atropine” has been shown to be as effective as daily atropine^[90] and patching in children with both moderate and severe amblyopia as well as specifically in strabismic amblyopia^[90-93]. Furthermore, the atropine and the occlusion treatment have similar rates of reverse amblyopia such as daily atropine vs full-time occlusion and improvement

Clinical management of strabismic amblyopia

Table 3 Summary of the main clinical findings of occlusion therapy that can be observed in strabismic amblyopia according to scientific peer-reviewed literature

Authors	Type of study	Main objectives	Year	Patients	Treatment	Main results
Holmes <i>et al</i> ^[81]	Prospective randomized multicentre clinical trial	To compare visual outcome of full-time vs 6h patching daily combined with near activities	2003	175 strabismic or mixed amblyopia patients (20/100 to 20/400) 3-7y	Full-time occlusion vs 6h (each combined with at least 1h of near activities)	Average visual improvement 4.7 lines full-time occlusion vs 4.8 lines part-time occlusion
Repka <i>et al</i> ^[82]	Randomized multicentre clinical trial	To compare 2h vs 6h of daily occlusion combined with near activities	2003	189 strabismic or mixed amblyopia patients (20/40 to 20/80) <7y	2h daily occlusion + near activities vs 6h daily occlusion + near activities	Average visual improvement 2.40 lines in each group
Awan <i>et al</i> ^[77]	Randomized clinical trial	To investigate the compliance with patching therapy with occlusion dose monitors	2005	52 strabismic or mixed amblyopia patients (6/12-6/48 Snellen)	No patching vs 3h occlusion vs 6h occlusion (all groups with optical correction)	Effective Patching: 3h-55min 6h-1h 52min Compliance rate: 57.5% 3h vs 41.2% 6h Mean visual improvement 0.24 in no patching, 0.29 in 3h patching and 0.34 in 6h patching
Wallace <i>et al</i> ^[83]	Prospective randomized multicentre clinical trial	To compare 2h of daily patching combined with 1h of near activities vs only optical correction treatment	2006	108 strabismic or mixed amblyopia patients (20/40 to 20/400) 3 to 7 years old	Daily occlusion for 2h+near activities for 1h vs control group: optical correction	The average improvement was 1.1 lines in the patching group and 0.5 lines in control group Best optical correction, 2h of occlusion and near activities for 1h improves moderate to severe amblyopia
PEDIG group ^[84]	Randomized clinical trial	To evaluate the improvement of visual acuity with 2h of occlusion plus near activities vs 2h occlusion plus distance activities	2008	425 strabismic and/or anisometropic amblyopia patients (20/40-20/400) 3 to <7y	Group 1: 2h of patching+near activities vs Group 2: 2h of patching+distance activities	Average visual improvement in each group: 2.6 lines with distance activities vs 2.5 lines with near activities
Singh <i>et al</i> ^[78]	Prospective interventional case series	To compare the efficacy of part-time vs full-time occlusion	2008	100 strabismic (n=25), mixed (n=18) and anisometropic (n=57) amblyopia patients 7-12y	Occlusion: 2h 4h 6h Full-time	Severe amblyopia (vision 20/100 or worse): 6h of full-time occlusion significantly more effective than two hours occlusion
Alotaibi <i>et al</i> ^[85]	Prospective study	To evaluate the outcome of part-time occlusion therapy with or without near activities	2012	130 strabismic and/or anisometropic amblyopia patients	Daily part-time occlusion (65 with 3h+near activities/65 without)	Average improvement of 6.7±2.37-line logMAR (near activities) and 5.3±2.04-line logMAR (without)
Agervi <i>et al</i> ^[79]	Randomized trial	To compare visual acuity, binocular function and refractive errors with alternate-day patching for 8h or more and patching for ≥8h (6d/wk)	2013	40 strabismic amblyopia patients Mean age: 4.3y	1 st refractive correction Group 1: alternate-day patching for ≥8h Group 2: patching for ≥8h (6d/wk)	Final median visual acuity group 1 (0.0 logMAR) vs group 2 (0.1 logMAR) Binocular function improved with both treatments

in ocular alignment and binocularity after treatment in strabismic amblyopia^[94-95].

The weekend atropine protocol combined with full optical correction in severe strabismic amblyopia seems to be according to the scientific literature a satisfactory option. However, in moderate amblyopia, the visual improvement achieved with daily atropine or weekend atropine does not seem to differ significantly.

Levodopa/Carbidopa Levodopa/Carbidopa is a pharmacological combination which is used for the treatment of Parkinson's disease as well as for the treatment of tremors (shaking), stiffness and slow movements caused by lack of dopamine. Levodopa is a central nervous system agent, acting as a precursor amino-acid of dopamine in the brain. Carbidopa

is a decarboxylase inhibitor medication^[100]. Experimental studies with animals have shown that visual deprivation was linked to retinal dopamine concentration^[101]. In humans, the use of levodopa/carbidopa has been shown to affect contrast sensitivity and binocular suppression in amblyopia^[88]. This pharmacological combination has been proved in humans with amblyopia, being used in most of cases in strabismic amblyopia (Table 5)^[102-106]. Several reports used levodopa/carbidopa together with occlusion treatment, suggesting that levodopa may add to the effect of occlusion. Furthermore, levodopa/carbidopa are effective in severe amblyopia and bilateral amblyopia, promoting the improvement and maintenance of visual acuity after treatment^[103-105]. Therefore, the use of levodopa is an effective and safe option for the

Table 4 Summary of the main clinical findings of atropine penalization that can be observed in strabismic amblyopia according to scientific peer-reviewed literature

Authors	Type of study	Main objectives	Year	Patients	Treatment	Main results
North & Kelly ^[90]	Retrospective study	To evaluate the effect of atropine	1991	189 strabismic amblyopia patients	Atropine (1%)	Atropine does not seem to impair the strabismus degree
Simons <i>et al</i> ^[95]	Retrospective study	To compare the visual outcome and binocularity of occlusion vs penalization treatment	1997	192 strabismic amblyopia patients	Before occlusion +AP (n=87) AP (n=75) Part-time occlusion (n=30)	No significant difference was found in the multivariate analyses controlling for initial-visit age, acuity, and binocularity status
Simons <i>et al</i> ^[96]	Retrospective study	To evaluate the monocular and binocular outcome (with three types of penalization)	1997	163 strabismic amblyopia patients	Traditional full-time atropine (n=38) (DA) OP (n=52) Atropine instillation 1-3d/wk (n=73) (WA)	Reduction of amblyopia (1.7-2.7 logMAR lines) DA, OP, WA produce a statically significant monocular and binocular improvement
Kaye <i>et al</i> ^[99]	Prospective study	To evaluate the visual acuity of OP and AP after occlusion therapy	2002	42 strabismic and anisometropic amblyopia patients Mean age: 4.73y	1 st patching (36wk before) OP AP (1%)	Improvement with optical COAT (20/113 to 20/37) 22 patients recommenced occlusion after COAT 20 patients (93%) maintained VA
Repka <i>et al</i> ^[91]	Prospective randomized multicentre clinical trial	To compare daily to weekend atropine	2004	168 strabismic, mixed and anisometropic amblyopia patients <7y	DW vs AW Amblyopia 20/40 to 20/80	Visual improvement in each group 2.3 lines Stereoacuity outcomes were similar in both groups
Repka <i>et al</i> ^[94]	Randomized clinical trial	To evaluate the change in alignment after amblyopia treatment (atropine vs patching)	2005	357 strabismic, mixed, anisometropic amblyopia patients <7y	Occlusion vs atropine Amblyopia (20/40-20/100)	161 (45%) achieved ortho: after 2y strabismus was present in 18% patching vs 16% atropine 91 (25%) presented microtropia (1-8 prism diopter): after 2y worsening of deviation 13 % patching vs 15% atropine 105 (29%) had heterotropia (>8 prism diopter): after 2y 13% patching vs 16% atropine improved to ortho without surgery
Tejedor & Ogallar ^[97]	Randomized clinical trial	To compare visual acuity and stereoacuity with AP and OP	2008	70 strabismic or anisometropic amblyopia patients	Atropine 1% (AP) OP	Visual acuity improvement (AP 3.4 vs OP 1.8 logMAR lines) Interocular difference improvement AP 2.8 vs OP 1.3 logMAR lines No significant difference in stereoacuity (AP-OP)
Repka <i>et al</i> ^[93]	Prospective randomized multicentre clinical trials	To determine the effectiveness of weekend atropine for severe amblyopia	2009	100 patients with severe amblyopia (20/125 to 20/400) due to strabismus and/or anisometropia	Group 1 (60 children 3-6y): A-AW+plano lens vs B-AW+full optical correction Group 2 (40 children 7-12y): C-AW vs D-2 daily occlusion	Group 1: average improvement 4.5 lines B vs 5.1 lines A Group 2: average improvement 1.5 lines C vs 1.8 lines D
PEDIG <i>et al</i> ^[92]	Randomized clinical trial	To evaluate the effectiveness of augmenting the effect of atropine by changing the lens over the fellow eye to plano in children with residual amblyopia	2015	73 patients (3 to <8y) with residual amblyopia (20/32 to 20/160)	WA vs DA plus plano lens	Average improvement: DA 1.1 lines vs WA 0.6 lines

OP: Optical penalization; AP: Atropine penalization; WA: Atropine weekend; DA: Atropine daily; COAT: Correction and atropine penalization treatment.

treatment of amblyopia and may be considered as a first-line treatment in amblyopia^[107].

Serotonin receptor inhibitor fluoxetine/catecholamine modulator citicoline/acetylcholinesterase inhibitor donepezil These substances have been suggested as potential treatment options in amblyopia, which can be considered a developmental brain disorder leading to vision loss due to asymmetric or inadequate visual stimulation early in life^[108].

Citicoline is used for Alzheimer's disease and other types of dementia, head trauma, cerebrovascular disease such as stroke, age-related memory loss, Parkinson's disease, attention deficit-hyperactive disorder (ADHD), and glaucoma^[108]. Donepezil is used for the symptomatic treatment of mild and moderate Alzheimer's disease^[108]. The fluoxetine is a widely prescribed medication for treatment of depression^[109], with some neurological clinical reports demonstrating

Table 5 Summary of the main clinical findings of levodopa/carbidopa treatment that can be observed in strabismic amblyopia according to scientific peer-reviewed literature

Authors	Type of study	Main objectives	Year	Patients	Treatment	Mainly results
Gottlob & Stangler-Zuschrott ^[102]	Cross-over, double-masked study	Efficacy and tolerance of a levodopa in normal and strabismic amblyopia. Effect on sensitivity and fixation point scotomas	1990	Strabismic amblyopia	Levodopa (one single administration)	Levodopa induces short-term changes on contrast sensitivity (increase) and fixation point scotomas (reduction in size) in amblyopic eyes
Procyanoy <i>et al</i> ^[106]	Randomized, double-blind, parallel, and placebo-controlled study	Efficacy and tolerance of a levodopa/carbidopa together with occlusion	1999	78 strabismic amblyopia patients 7 to 17y	Levodopa+part-time occlusion (3h/d) vs Placebo+full-time occlusion	0.51 mg/kg per day is well tolerated and produces a clinical and statistically significant short-term improvement in visual acuity in children with amblyopia
Dadeya <i>et al</i> ^[103]	Randomized, double-blind study	To evaluate the role of levodopa/carbidopa in the treatment of strabismic amblyopia	2009	30 strabismic amblyopia patients 3-12y	Levodopa/carbidopa (0.50 mg+1.25 mg/kg)+ full-time occlusion	Improvement and maintenance of visual acuity in 100% of children <8 years old and 60% of children >8 years old
Rashad ^[104]	Prospective study	To compare a weight-adjusted dose of carbidopa-levodopa	2012	63 patients with different types of amblyopia 12y	LC (n=28) vs O (n=35)	LC>O (42.5% vs 30%) in adult patients LC>O (34.3% vs 22%) in severe amblyopia Levodopa may add to the effect of occlusion in severe amblyopia and bilateral amblyopia
Sofi <i>et al</i> ^[105]	Prospective randomised placebo-controlled study	Efficacy and tolerance of levodopa/carbidopa	2016	63 patients with different types of amblyopia 5 to 20y	Group 1: Levodopa/carbidopa+full-time occlusion Group 2: Placebo+full-time occlusion	Levodopa/carbidopa can be used together with conventional occlusion therapy in amblyopia particularly in older children and severe cases of amblyopia, being well tolerated

LC: Levodopa/carbidopa+occlusion; O: Occlusion only.

that also restores plasticity in the adult visual cortex^[109-110]. Fluoxetine can reinstate early-life critical period-like neuronal plasticity and has been used to recover functional vision in adult rats with amblyopia^[111]. Currently, there is no doubt about the possibility of treatment of amblyopia in adult patients as neuronal plasticity is still present. However, these pharmacological therapies have shown limited efficacy in adult patients with amblyopia^[112]. These studies point toward the intracortical inhibitory transmission as a crucial brake for therapeutic rehabilitation and recovery from amblyopia in the adult brain^[112]. Nevertheless, more research is still needed to evaluate the use of these new drugs specifically only in strabismic amblyopia and to check for possible adverse effects after treatment.

Penalization Therapy

Optical penalization The main objective of optical penalization is the change the focus of the image of the dominant eye by means of optical overcorrection. As atropine, optical penalization has a high acceptability, and has been used alone as an alternative for treating amblyopia or for its maintenance^[113]. In addition, optical penalization has been also used as a maintenance treatment after occlusion treatment^[99,113], and even to the improve the motor instability in strabismic patients. However, the minimal refractive penalization required for an optical treatment is not clear and defined, ranging in studies from +3.00 to +1.25 D^[114].

A report with 163 strabismic amblyopic patients evaluated

the monocular and binocular outcome with daily atropine, optical penalization and weekend atropine. The three types of penalization produced a statistically significant reduction in amblyopia (from 1.7 to 2.7 logMAR lines)^[96]. In addition, the effectiveness of optical penalization and atropine was evaluated in 166 strabismic or anisometric patients. A similar improvement of visual acuity with both types of penalization was found: 77% of patients with optical penalization and 76% of patients with atropine^[115].

Bangerter foils Another type of penalization treatment is the use of Bangerter foils (Ryser Optik AG, St. Gallen, Switzerland) or neutral density filters^[116]. Its use began at the end of the 20th century as an alternative to measure interocular suppression scotoma in amblyopic patients^[117]. The main objective of Bangerter foils is to reduce the contrast sensitivity and luminance in the non-amblyopic eye in order to avoid interocular suppression and to improve binocular balance in amblyopia^[118].

A significant improvement at 3mo of treatment was registered in 30 children with strabismic amblyopia^[119]. Furthermore, the reduction of interocular differences in strabismic amblyopia can improve the development of motor fusion, as has been reported in a study including 46 strabismic amblyopic patients. Specifically, 61% of patients developed motor fusion that was maintained at 13.3mo after treatment^[120]. Therefore, Bangerter foils may be an alternative after monocular treatment or primary option in strabismic amblyopia^[121] in order to reduce

interocular suppression and to improve fusion development^[122]. According to the literature, this option seems to be an alternative in moderate cases of strabismic amblyopia, but not in severe cases as an important reduction of visual quality is required in the dominant eye and children try to avoid the filter looking over the glasses. Indeed, a significant correlation of the visual acuity achieved at 3mo of treatment with Bangerter foils in strabismic amblyopia with the baseline visual acuity difference among eyes has been reported^[119]. It should be considered that the selection of the filter to prescribe is based on the criteria defined by Odell *et al*, which were to achieve a reduction of visual acuity in the non-amblyopic eye capable of inverting the ocular dominance^[119].

Other Treatments

Transcranial magnetic stimulation Transcranial direct stimulation is a new experimental treatment of amblyopia. Recent studies show that repetitive transcranial magnetic stimulation (rTMS) of the visual cortex can temporarily improve contrast sensitivity in the amblyopic eye, including the experimental studies conducted to this date some strabismic cases^[123-125]. A recent report with rats have shown that transcranial direct-current stimulation (tDCS) treatment improves the visual acuity of the amblyopic eye, with a significant increase of parvoalbumin-positive cells in three areas of the visual cortex (V1M, V1B and V2L), both in the stimulated hemisphere but also in the non-stimulated hemisphere^[126]. More research is still needed before the clinical application of this treatment in order to define the best protocols to optimize the outcome and to minimize the potential side effects.

Active treatment of strabismic amblyopia Binocular balance is the step following monocular stimulation. The active treatment to recover binocular imbalance in a crucial step for a complete rehabilitation of amblyopia. The active therapy adds visual exercises and/or self-monitoring systems such as biofeedback that combined with passive treatment may lead to a successful management of strabismic patients^[127].

Strabismic amblyopia is characterized by interocular difference due to central suppression. The dichoptic training is a tool to monitor changes in interocular differences and suppression occurring in amblyopia^[128]. Individuals with strabismic amblyopia have a very low probability of improvement with only monocular training, with potentially better outcomes using dichoptic training, and even better with direct stereo training^[129]. Recently, it has been shown that amblyopes possess binocular cortical mechanisms for both threshold and supra threshold stimuli^[130-131]. One critical factor is that active vision therapy under binocular conditions should be conducted after ensuring that bifoveal fixation is present. In strabismic amblyopia, this can be achieved with a previous compensation

of the deviation with lenses, prisms or surgery.

Visual training based on perceptual learning has been shown to be effective in children and adults with anisometropic amblyopia^[132-134]. This new method of amblyopia treatment together with occlusion has evidenced that may significantly speed up the time of recovery in children with amblyopia^[135]. In addition, there is a significant transfer of learning from the amblyopic to the dominant eye during perceptual learning treatment^[136]. However, to this date, there is no study evaluating the results of perceptual learning specifically in strabismic amblyopia. In most of studies, only a minimal portion of patients enrolled in the study had strabismic amblyopia and therefore it is difficult to extract specific conclusions about the use of perceptual learning in this condition^[137-138]. It is curious that the lowest visual improvements that has been reported with perceptual learning were reported in those series including a significant proportion of strabismic patients^[137-138]. Possibly, the use of visual training with perceptual learning should be combined with patching in this type of patients, but this is something that should be addressed in future studies.

Concerning dichoptic training, it is critical the presence of bifoveal fixation to initiate the treatment (prism, surgery) as well as the presence of a tolerable interocular difference in visual acuity (no more than 3 lines of difference)^[139]. For this reason, in some cases, perceptual learning, dichoptic training and even patching are combined. Most part of the research on dichoptic training is related to anisometropic amblyopia^[131-133]. Only a limited number of studies has included strabismic amblyopic patients in their samples and therefore it is difficult to extract consistent conclusions of this type of treatment in strabismic amblyopia^[140]. All these researches suggest that dichoptic training may be considered as a phase of the visual training in strabismic amblyopia once the bifoveal fixation is restored. More studies are still necessary to confirm this issue. Finally, an incipient evidence of the use of virtual reality in anisometropic amblyopia has been published, showing the capability of this type of training of improving the visual acuity and promoting stereopsis^[141]. However, there is no evidence to this date of the use of this type of therapy in strabismic amblyopia.

Treatment failure In some cases, the visual recovery achieved following the protocols established by the peer-reviewed literature is limited in strabismic amblyopia, even with a complete failure of the treatment. A potential cause for this unsuccessful outcome may be the presence of sensory adaptations, such as retinal correspondence anomaly or eccentric or unstable fixation, that have not been detected in the baseline examination and have limited the visual rehabilitation. In such cases, a complete visual sensory examination is recommended to discard this potential source of

limitation of the visual outcome. Kirandi *et al*^[142] confirmed in a previous study that a large interocular difference in the best-corrected visual acuity was a risk factor for both functional and relative failure of amblyopia treatment. This suggests that passive and active treatment should be combined in this type of cases to achieve a more successful visual acuity recovery, but this should be confirmed in future studies. Likewise, Seol *et al*^[143] concluded in another study that intermittent atropine penalization for 4mo could improve best corrected visual acuity in children with amblyopia for whom patch therapy has failed. Specifically, these authors stated that atropine penalization could be especially effective in younger children and those with poor best corrected visual acuity at the start of atropine penalization in the amblyopic eye^[143].

CONCLUSIONS

Strabismic amblyopia is a type of amblyopia with some clinical peculiarities that differentiate it from anisometropic amblyopia in terms of clinical signs, treatment planning and visual prognosis. Refractive correction is a mandatory first step before initiating and planning any treatment in this condition. Research studies have confirmed that strabismic amblyopia can be treated successfully with part-time occlusion and weekend atropine, obtaining a similar effectiveness in even severe amblyopia. The use of 6-hour occlusion combined with the performance of near vision activities seems to be the best option of occlusion treatment in this amblyopic condition. Concerning the use of optical penalization and Bangerter foils, more information on the real effectiveness of these treatment options and the level of penalization required with each one is still needed to define general and consistent recommendations about their use in strabismic amblyopia. An alternative effective option of treatment in strabismic amblyopia is the use of levodopa/carbidopa combined with occlusion, although the potential long-term effects of this medication is still unknown. As far as other drug therapies, more research is needed to evaluate the use of these new drugs only in strabismic amblyopia and to check for possible adverse effects after treatment.

Concerning active vision therapy, minimal scientific evidence has been still provided in strabismic amblyopia, especially in the area of perceptual learning training, in spite of the more consistent evidence reported in anisometropic amblyopia. Future studies should be conducted to assess the potential greater benefit of combining passive methods with the recent methods of active vision therapy. Finally, transcranial magnetic stimulation is another potential option of treatment in strabismic amblyopia, but the evidence about its efficiency and safety is still very poor.

Finally, it should be remarked the relevant limitations of studies analysing the outcomes of strabismic amblyopia

treatment. First, the samples evaluated are normally small which is a consequence of the relatively limited prevalence of strabismic amblyopia. According to this, more multicentre studies should be conducted to overcome this limitation. One of the most controversial issues on amblyopia research is the combination of strabismic and anisometropic amblyopes, considering that the behaviour and prognosis of these two conditions are different. More studies evaluating specifically the outcomes of treatment of strabismic amblyopia are needed in order to provide more specific treatment criteria for this sample of patients. Likewise, comparative clinical trials evaluating outcomes of a specific treatment but considering a sample of strabismic amblyopes exclusively are lack and would be necessary in the future to understand better this condition and provide more realistic data to patients about the prognosis of such condition.

ACKNOWLEDGEMENTS

Foundation: Supported by the Ministry of Economy, Industry and Competitiveness of Spain within the program Ramón y Cajal (RYC-2016-20471).

Conflicts of Interest: Milla M, None; Piñero DP, None.

REFERENCES

- 1 Hashemi H, Pakzad R MSc, Yekta A, *et al*. Global and regional estimates of prevalence of amblyopia: a systematic review and meta-analysis. *Strabismus* 2018;26(4):168-183.
- 2 Hernández-Rodríguez CJ, Piñero DP. Active vision therapy for anisometropic amblyopia in children: a systematic review. *J Ophthalmol* 2020;2020:1-9.
- 3 Elflein HM. Amblyopia. Epidemiology, causes and risk factors. *Ophthalmologe* 2016;113(4):283-288.
- 4 Korah S, Philip S, Jasper S, Antonio-Santos A, Braganza A. Strabismus surgery before versus after completion of amblyopia therapy in children. *Cochrane Database Syst Rev* 2014(10):CD009272.
- 5 Vagge A, Nelson LB. Amblyopia update: new treatments. *Curr Opin Ophthalmol* 2016;27(5):380-386.
- 6 Hess RF, Thompson B, Baker DH. Binocular vision in amblyopia: structure, suppression and plasticity. *Ophthalmic Physiol Opt* 2014;34(2):146-162.
- 7 Webber AL, Camuglia JE. A pragmatic approach to amblyopia diagnosis: evidence into practice. *Clin Exp Optom* 2018;101(4):451-459.
- 8 Kraus CL, Culican SM. New advances in amblyopia therapy I: binocular therapies and pharmacologic augmentation. *Br J Ophthalmol* 2018;102(11):1492-1496.
- 9 Papageorgiou E, Asproudis I, Maconachie G, Tsironi EE, Gottlob I. The treatment of amblyopia: current practice and emerging trends. *Graefes Arch Clin Exp Ophthalmol* 2019;257(6):1061-1078.
- 10 Dai PS, Zhang JL, Wu J, Chen ZL, Zou BJ, Wu Y, Wei X, Xiao MY. Altered spontaneous brain activity of children with unilateral amblyopia: a resting state fMRI study. *Neural Plast* 2019;2019: 3681430.

- 11 Bonaccorsi J, Berardi N, Sale A. Treatment of amblyopia in the adult: insights from a new rodent model of visual perceptual learning. *Front Neural Circuits* 2014;8:82.
- 12 Tailor VK, Schwarzkopf DS, Dahlmann-Noor AH. Neuroplasticity and amblyopia: vision at the balance point. *Curr Opin Neurol* 2017;30(1):74-83.
- 13 Maurer D, McKEE SP. Classification and diversity of amblyopia. *Vis Neurosci* 2018;35:E012.
- 14 Murray SJ, Codina CJ. The role of binocularity in anisometric amblyopia. *J Binocul Vis Ocul Motil* 2019;69(4):141-152.
- 15 Chen AM, Manh V, Candy TR. Longitudinal evaluation of accommodation during treatment for unilateral amblyopia. *Invest Ophthalmol Vis Sci* 2018;59(5):2187-2196.
- 16 Toor S, Horwood A, Riddell P. The effect of asymmetrical accommodation on anisometric amblyopia treatment outcomes. *J AAPOS* 2019;23(4):203.e1-203.e5.
- 17 Tsirlin I, Colpa L, Goltz HC, Wong AMF. Visual search deficits in amblyopia. *J Vis* 2018;18(4):17.
- 18 Norgett Y, Siderov J. Effect of stimulus configuration on crowding in strabismic amblyopia. *J Vis* 2017;17(13):5.
- 19 Ulrich K, Palmowski-Wolfe A. Comparing three different contrast sensitivity tests in adults and in children with and without amblyopia. *Klin Monbl Augenheilkd* 2019;236(4):434-437.
- 20 Mohammadi A, Hashemi H, Mirzajani A, Yekta A, Jafarzadehpur E, Valadkhan M, Khabazkhoob M. Contrast and spatial frequency modulation for diagnosis of amblyopia: an electrophysiological approach. *J Curr Ophthalmol* 2019;31(1):72-79.
- 21 Gao TY, Ledgeway T, Lie AL, Anstice N, Black J, McGraw PV, Thompson B. Orientation tuning and contrast dependence of continuous flash suppression in amblyopia and normal vision. *Invest Ophthalmol Vis Sci* 2018;59(13):5462-5472.
- 22 Niemeyer JE, Paradiso MA. Contrast sensitivity, V1 neural activity, and natural vision. *J Neurophysiol* 2017;117(2):492-508.
- 23 Niechwiej-Szwedo E, Colpa L, Wong AMF. Visuomotor behaviour in amblyopia: deficits and compensatory adaptations. *Neural Plast* 2019;2019:6817839.
- 24 Maiello G, Kwon M, Bex PJ. Three-dimensional binocular eye-hand coordination in normal vision and with simulated visual impairment. *Exp Brain Res* 2018;236(3):691-709.
- 25 Niechwiej-Szwedo E, Goltz HC, Chandrakumar M, Wong AM. Effects of strabismic amblyopia and strabismus without amblyopia on visuomotor behavior: III. Temporal eye-hand coordination during reaching. *Invest Ophthalmol Vis Sci* 2014;55(12):7831-7838.
- 26 Fronius M, Sireteanu R, Zubcov A, Büttner A. Preliminary report: monocular spatial localization in children with strabismic amblyopia. *Strabismus* 2000;8(4):243-249.
- 27 Kelly KR, Jost RM, De La Cruz A, Birch EE. Amblyopic children read more slowly than controls under natural, binocular reading conditions. *J AAPOS* 2015;19(6):515-520.
- 28 Li JR, Thompson B, Lam CS, Deng DM, Chan LY, Maehara G, Woo GC, Yu MB, Hess RF. The role of suppression in amblyopia. *Invest Ophthalmol Vis Sci* 2011;52(7):4169-4176.
- 29 Babu RJ, Clavagnier S, Bobier WR, Thompson B, Hess RF. Regional extent of peripheral suppression in amblyopia. *Invest Ophthalmol Vis Sci* 2017;58(4):2329-2340.
- 30 Wong AM, Burkhalter A, Tychsen L. Suppression of metabolic activity caused by infantile strabismus and strabismic amblyopia in striate visual cortex of macaque monkeys. *J AAPOS* 2005;9(1):37-47.
- 31 Li JJ, Li JR, Chen ZD, Liu J, Yuan JP, Cai XX, Deng DM, Yu MB. Spatial and global sensory suppression mapping encompassing the central 10° field in anisometric amblyopia. *Invest Ophthalmol Vis Sci* 2017;58(1):481-491.
- 32 Zhou JW, Reynaud A, Yao ZM, Liu R, Feng LX, Zhou YF, Hess RF. Amblyopic suppression: passive attenuation, enhanced dichoptic masking by the fellow eye or reduced dichoptic masking by the amblyopic eye? *Invest Ophthalmol Vis Sci* 2018;59(10):4190-4197.
- 33 Shapira Y, Machluf Y, Mimouni M, Chaiter Y, Mezer E. Amblyopia and strabismus: trends in prevalence and risk factors among young adults in Israel. *Br J Ophthalmol* 2018;102(5):659-666.
- 34 Preising MN, Steinmüller PH, Lorenz B. Recruitment of suitable families to identify causative genes in hereditary strabismus. *Klin Monbl Augenheilkd* 2015;232(10):1158-1164.
- 35 Guimaraes S, Vieira M, Queirós T, Soares A, Costa P, Silva E. New pediatric risk factors for amblyopia: strabismic versus refractive. *Eur J Ophthalmol* 2018;28(2):229-233.
- 36 Koo EB, Gilbert AL, VanderVeen DK. Treatment of amblyopia and amblyopia risk factors based on current evidence. *Semin Ophthalmol* 2017;32(1):1-7.
- 37 Ing MR, Norcia A, Stager D Sr, Black B, Hoffman R, Mazow M, Troia S, Scott W, Lambert S. A prospective study of alternating occlusion before surgical alignment for infantile esotropia: one-year postoperative motor results. *J AAPOS* 2006;10(1):49-53.
- 38 Osborne DC, Greenhalgh KM, Evans MJE, Self JE. Atropine penalization versus occlusion therapies for unilateral amblyopia after the critical period of visual development: a systematic review. *Ophthalmol Ther* 2018;7(2):323-332.
- 39 Campbell RJ, Coupland SG, Buhmann RR, Kertes PJ. Effect of eccentric and inconsistent fixation on retinal optical coherence tomography measures. *Arch Ophthalmol* 2007;125(5):624-627.
- 40 García-García MÁ, Belda JI, Schargel K, Santos MJ, Ruiz-Colecha J, Rey C, García-García P, Mompean B. Optical coherence tomography in children with microtropia. *J Pediatr Ophthalmol Strabismus* 2018;55(3):171-177.
- 41 Molina-Martín A, Piñero DP, Pérez-Cambrodí RJ. Reliability and intersession agreement of microperimetric and fixation measurements obtained with a new microperimeter in normal eyes. *Curr Eye Res* 2016;41(3):400-409.
- 42 Rajavi Z, Sabbaghi H, Behradfar N, Yaseri M, Aghazadeh Amiri M, Faghihi M. Macular thickness in moderate to severe amblyopia. *Korean J Ophthalmol* 2018;32(4):312-318.

Clinical management of strabismic amblyopia

- 43 Scholtz SK, Lingelbach B, Krogmann F, Auffarth GU. "Mystery is in the eye of the beholder": the history of the "haidinger's brushes". *Klin Monbl Augenheilkd* 2018;235(8):927-929.
- 44 Nakamoto Y, Takada R, Tanaka M, Matsumoto F, Aomatsu K, Tachibana K, Eguchi H, Kusaka S. Quantification of eccentric fixation using spectral-domain optical coherence tomography. *Ophthalmic Res* 2018;60(4):231-237.
- 45 VerLee DL, Iacobucci I. Pleoptics versus occlusion of the sound eye in the management of strabismic amblyopia with eccentric fixation. *Am J Ophthalmol* 1967;63(2):244-250.
- 46 Priestley BS, Byronhm, Weseley AC. Pleoptic methods in the management of amblyopia with eccentric fixation. *Am J Ophthalmol* 1959;48:490-502.
- 47 Jablonski M, Tomlinson E. A new look at pleoptics. *Ophthalmology* 1979;86(12):2112-2114.
- 48 Vonnoorden GK, Lipsius RM. Experiences with pleoptics in 58 patients with strabismic amblyopia. *Am J Ophthalmol* 1964;58:41-51.
- 49 Schmidt D, Stapp M. The effect of euthyscope- and occlusion therapy in cases of convergent strabismus. Comparative, prospective examinations (author's transl). *Klin Monbl Augenheilkd* 1977; 171(1):105-117.
- 50 Bogdan F. The importance of the pleoptophor in treating children with amblyopia. *Oftalmologia* 1992;36(3):251-256.
- 51 Baranowska-George T, Litwińska J, Danieyko-Osman M. Prevention of amblyopia by active production of the macular fixation reflex in infants. *Klin Oczna* 1992;94(4):108-110.
- 52 Atrata R, Hromádková L, Rehůrek J. Effect of early surgery in essential infantile esotropia on the quality of binocular vision. *Cesk Slov Oftalmol* 2002;58(1):36-41.
- 53 Schor C. Perceptual-motor computational model of anomalous binocular correspondence. *Optom Vis Sci* 2015;92(5):544-550.
- 54 Lysons D, Tapley J. Is microtropia a reliable indicator of the presence of amblyopia in anisotropic patients? *Strabismus* 2018; 26(3):118-121.
- 55 Savino G, Abed E, Rebecchi MT, Spreca M, Tredici C, Dickmann A. Acute acquired concomitant esotropia and decompensated monofixation syndrome: a sensory-motor status assessment. *Can J Ophthalmol* 2016;51(4):258-264.
- 56 Parks MM. After the eyes are straightened what is the ophthalmologist's responsibility? *Ophthalmology* 1986;93(8):1020-1022.
- 57 Lang J. Microtropia. *Int Ophthalmol* 1983;6(1):33-36.
- 58 Cleary M, Houston CA, McFadzean RM, Dutton GN. Recovery in microtropia: implications for aetiology and neurophysiology. *Br J Ophthalmol* 1998;82(3):225-231.
- 59 Houston CA, Cleary M, Dutton GN, McFadzean RM. Clinical characteristics of microtropia—is microtropia a fixed phenomenon? *Br J Ophthalmol* 1998;82(3):219-224.
- 60 Ha SG, Suh YW, Kim SH. Esodeviation without correction for tapering hyperopia in refractive accommodative esotropia. *Can J Ophthalmol* 2018;53(5):453-457.
- 61 Asper L, Watt K, Khuu S. Optical treatment of amblyopia: a systematic review and meta-analysis. *Clin Exp Optom* 2018;101(4): 431-442.
- 62 Stewart CE, Moseley MJ, Fielder AR, Stephens DA, MOTAS Cooperative. Refractive adaptation in amblyopia: quantification of effect and implications for practice. *Br J Ophthalmol* 2004;88(12): 1552-1556.
- 63 Writing Committee for the Pediatric Eye Disease Investigator Group, Cotter SA, Foster NC, et al. Optical treatment of strabismic and combined strabismic-anisometric amblyopia. *Ophthalmology* 2012;119(1):150-158.
- 64 Cotter SA, Edwards AR, Arnold RW, et al; Pediatric Eye Disease Investigator Group. Treatment of strabismic amblyopia with refractive correction. *Am J Ophthalmol* 2007;143(6):1060-1063.
- 65 Chen AM, Cotter SA. The amblyopia treatment studies: implications for clinical practice. *Adv Ophthalmol Optom* 2016;1(1):287-305.
- 66 Garcia-Romo E, Perez-Rico C, Roldán-Díaz I, Arévalo-Serrano J, Blanco R. Treating amblyopia in adults with prosthetic occluding contact lenses. *Acta Ophthalmol* 2018;96(3):e347-e354.
- 67 Agrawal R, Conner IP, Odom JV, Schwartz TL, Mendola JD. Relating binocular and monocular vision in strabismic and anisometric amblyopia. *Arch Ophthalmol* 2006;124(6):844-850.
- 68 Arikan G, Yaman A, Berk AT. Efficacy of occlusion treatment in amblyopia and clinical risk factors affecting the results of treatment. *Strabismus* 2005;13(2):63-69.
- 69 Beardsell R, Clarke S, Hill M. Outcome of occlusion treatment for amblyopia. *J Pediatr Ophthalmol Strabismus* 1999;36(1):19-24.
- 70 Repka MX, PEDIG. Moderate amblyopia in children less than seven years of age: experience of the amblyopia treatment study 1. Meeting of the International Strabismological Association. Sydney, Australia: Swets & Zeitlinger Publishers. 2003;163-166.
- 71 Pediatric Eye Disease Investigator Group. The clinical profile of moderate amblyopia in children younger than 7 years. *Arch Ophthalmol* 2002;120(3):281-287.
- 72 Holmes JM, Beck RW, Kraker RT, et al, Pediatric Eye Disease Investigator Group. Risk of amblyopia recurrence after cessation of treatment. *J AAPOS* 2004;8(5):420-428.
- 73 Holmes JM, Melia M, Bradfield YS, Cruz OA, Forbes B, Pediatric Eye Disease Investigator Group. Factors associated with recurrence of amblyopia on cessation of patching. *Ophthalmology* 2007;114(8): 1427-1432.
- 74 Nilsson J, Baumann M, Sjöstrand J. Strabismus might be a risk factor for amblyopia recurrence. *J AAPOS* 2007;11(3):240-242.
- 75 Maconachie GD, Gottlob I. The challenges of amblyopia treatment. *Biomed J* 2015;38(6):510-516.
- 76 Elder MJ. Occlusion therapy for strabismic amblyopia. *Aust N Z J Ophthalmol* 1994;22(3):187-191.
- 77 Awan M, Proudlock FA, Gottlob I. A randomized controlled trial of unilateral strabismic and mixed amblyopia using occlusion dose monitors to record compliance. *Invest Ophthalmol Vis Sci* 2005;46(4):1435-1439.

- 78 Singh I, Sachdev N, Brar GS, Kaushik S. Part-time occlusion therapy for amblyopia in older children. *Indian J Ophthalmol* 2008;56(6):459-463.
- 79 Agervi P, Kugelberg U, Kugelberg M, Zetterström C. Two-year follow-up of a randomized trial of spectacles plus alternate-day patching to treat strabismic amblyopia. *Acta Ophthalmol* 2013;91(7):678-684.
- 80 Varadharajan S, Hussaindeen JR. Visual acuity deficits in the fellow eyes of children with unilateral amblyopia. *J AAPOS* 2012;16(1):41-45.
- 81 Holmes JM, Kraker RT, Beck RW, Birch EE, Cotter SA, Everett DF, Hertle RW, Quinn GE, Repka MX, Scheiman MM, Wallace DK, Pediatric Eye Disease Investigator Group. A randomized trial of prescribed patching regimens for treatment of severe amblyopia in children. *Ophthalmology* 2003;110(11):2075-2087.
- 82 Repka MX, Beck RW, Holmes JM, Birch EE, Chandler DL, Cotter SA, Hertle RW, Kraker RT, Moke PS, Quinn GE, Scheiman MM, Pediatric Eye Disease Investigator Group. A randomized trial of patching regimens for treatment of moderate amblyopia in children. *Arch Ophthalmol* 2003;121(5):603-611.
- 83 Wallace DK, Pediatric Eye Disease Investigator Group, Edwards AR, et al. A randomized trial to evaluate 2 hours of daily patching for strabismic and anisometropic amblyopia in children. *Ophthalmology* 2006;113(6):904-912.
- 84 Pediatric Eye Disease Investigator Group. A randomized trial of near versus distance activities while patching for amblyopia in children aged 3 to less than 7 years. *Ophthalmology* 2008;115(11):2071-2078.
- 85 Alotaibi AG, Fawazi SM, Alenazy BR, Abu-Amero KK. Outcomes of 3 hours part-time occlusion treatment combined with near activities among children with unilateral amblyopia. *Saudi Med J* 2012;33(4):395-398.
- 86 Holmes JM, Repka MX, Kraker RT, Clarke MP. The treatment of amblyopia. *Strabismus* 2006;14(1):37-42.
- 87 Holmes JM, Edwards AR, Beck RW, et al, Pediatric Eye Disease Investigator Group. A randomized pilot study of near activities versus non-near activities during patching therapy for amblyopia. *J AAPOS* 2005;9(2):129-136.
- 88 Singh A, Nagpal R, Mittal SK, Bahuguna C, Kumar P. Pharmacological therapy for amblyopia. *Taiwan J Ophthalmol* 2017;7(2):62-69.
- 89 Wang JY. Compliance and patching and atropine amblyopia treatments. *Vision Res* 2015;114:31-40.
- 90 North RV, Kelly ME. Atropine occlusion in the treatment of strabismic amblyopia and its effect upon the non-amblyopic eye. *Ophthalmic Physiol Opt* 1991;11(2):113-117.
- 91 Repka MX, Cotter SA, Beck RW, et al, Pediatric Eye Disease Investigator Group. A randomized trial of atropine regimens for treatment of moderate amblyopia in children. *Ophthalmology* 2004;111(11):2076-2085.
- 92 Pediatric Eye Disease Investigator Group, Wallace DK, Lazar EL, Repka MX, Holmes JM, Kraker RT, Hoover DL, Weise KK, Waters AL, Rice ML, Peters RJ. A randomized trial of adding a Plano lens to atropine for amblyopia. *J AAPOS* 2015;19(1):42-48.
- 93 Repka MX, Kraker RT, Beck RW, et al, Pediatric Eye Disease Investigator Group. Treatment of severe amblyopia with weekend atropine: results from 2 randomized clinical trials. *J AAPOS* 2009;13(3):258-263.
- 94 Repka MX, Holmes JM, Melia BM, Beck RW, Gearing MD, Tamkins SM, Wheeler DT, Pediatric Eye Disease Investigator Group. The effect of amblyopia therapy on ocular alignment. *J AAPOS* 2005;9(6):542-545.
- 95 Simons K, Gotzler KC, Vitale S. Penalization versus part-time occlusion and binocular outcome in treatment of strabismic amblyopia. *Ophthalmology* 1997;104(12):2156-2160.
- 96 Simons K, Stein L, Sener EC, Vitale S, Guyton DL. Full-time atropine, intermittent atropine, and optical penalization and binocular outcome in treatment of strabismic amblyopia. *Ophthalmology* 1997;104(12):2143-2155.
- 97 Tejedor J, Ogallar C. Comparative efficacy of penalization methods in moderate to mild amblyopia. *Am J Ophthalmol* 2008;145(3):562-569.
- 98 von Noorden GK, Attiah F. Alternating penalization in the prevention of amblyopia recurrence. *Am J Ophthalmol* 1986;102(4):473-475.
- 99 Kaye SB, Chen SI, Price G, Kaye LC, Noonan C, Tripathi A, Ashwin P, Cota N, Clark D, Butcher J. Combined optical and atropine penalization for the treatment of strabismic and anisometropic amblyopia. *J AAPOS* 2002;6(5):289-293.
- 100 Senek M, Aquilonius SM, Askmark H, Bergquist F, Constantinescu R, Ericsson A, Lycke S, Medvedev A, Memedi M, Ohlsson F, Spira J, Westin J, Nyholm D. Levodopa/carbidopa microtablets in Parkinson's disease: a study of pharmacokinetics and blinded motor assessment. *Eur J Clin Pharmacol* 2017;73(5):563-571.
- 101 Mao JF, Liu SZ, Qin WJ, Li FY, Wu XY, Tan Q. Levodopa inhibits the development of form-deprivation myopia in Guinea pigs. *Optom Vis Sci* 2010;87(1):53-60.
- 102 Gottlob I, Stangler-Zuschrott E. Effect of levodopa on contrast sensitivity and scotomas in human amblyopia. *Invest Ophthalmol Vis Sci* 1990;31(4):776-780.
- 103 Dadeya S, Vats P, Malik KP. Levodopa/carbidopa in the treatment of amblyopia. *J Pediatr Ophthalmol Strabismus* 2009;46(2):87-90; quiz 91-92.
- 104 Rashad MA. Pharmacological enhancement of treatment for amblyopia. *Clin Ophthalmol* 2012;6:409-416.
- 105 Sofi IA, Gupta SK, Bharti A, Tantry TG. Efficiency of the occlusion therapy with and without levodopa-carbidopa in amblyopic children-a tertiary care centre experience. *Int J Health Sci (Qassim)* 2016;10(2):249-257.
- 106 Procianoy E, Fuchs FD, Procianoy L, Procianoy F. The effect of increasing doses of levodopa on children with strabismic amblyopia. *J AAPOS* 1999;3(6):337-340.
- 107 Yang XB, Luo DY, Liao M, Chen BJ, Liu LQ. Efficacy and tolerance of levodopa to treat amblyopia: a systematic review and meta-analysis. *Eur J Ophthalmol* 2012;0.

- 108 Gore C, Wu C. Medical therapies of amblyopia: translational research to expand our treatment armamentarium. *Semin Ophthalmol* 2016;31(1-2):155-158.
- 109 Maya Vetencourt JF, Sale A, Viegi A, Baroncelli L, De Pasquale R, O'Leary OF, Castrén E, Maffei L. The antidepressant fluoxetine restores plasticity in the adult visual cortex. *Science* 2008;320(5874):385-388.
- 110 Sharif MH, Talebnejad MR, Rastegar K, Khalili MR, Nowroozzadeh MH. Oral fluoxetine in the management of amblyopic patients aged between 10 and 40 years old: a randomized clinical trial. *Eye (Lond)* 2019;33(7):1060-1067.
- 111 Huttunen HJ, Palva JM, Lindberg L, Palva S, Saarela V, Karvonen E, Latvala ML, Liinamaa J, Booms S, Castrén E, Uusitalo H. Fluoxetine does not enhance the effect of perceptual learning on visual function in adults with amblyopia. *Sci Rep* 2018;8:12830.
- 112 Baroncelli L, Maffei L, Sale A. New perspectives in amblyopia therapy on adults: a critical role for the excitatory/inhibitory balance. *Front Cell Neurosci* 2011;5:25.
- 113 France TD, France LW. Optical penalization can improve vision after occlusion treatment. *J AAPOS* 1999;3(6):341-343.
- 114 Paris V. An alternative treatment for amblyopic strabismus: optical penalization. *Bull Soc Belge Ophthalmol* 2000;276:31-40.
- 115 Repka MX, Ray JM. The efficacy of optical and pharmacological penalization. *Ophthalmology* 1993;100(5):769-774; discussion 774-775.
- 116 Cadera W, Pachtman MA, Ellis FD, Helveston EM. Depth of strabismic amblyopia determined with neutral density filters. *Am J Ophthalmol* 1983;95(6):763-766.
- 117 Aggarwal DP, Verma G. Static perimetry in the study of amblyopic scotomata. *Br J Ophthalmol* 1980;64(9):713-716.
- 118 Iacobucci IL, Archer SM, Furr BA, Martonyi EJ, Del Monte MA. Bangerter foils in the treatment of moderate amblyopia. *Am Orthopt J* 2001;51:84-91.
- 119 Laria C, Pinerò DP. Characterization of bangerter filter effect in mild and moderate amblyopia associated with strabismus. *Binocul Vis Strabolog Q Simms Romano* 2012;27(3):174-186.
- 120 Abrams MS, Duncan CL, McMurtrey R. Development of motor fusion in patients with a history of strabismic amblyopia who are treated part-time with Bangerter foils. *J AAPOS* 2011;15(2):127-130.
- 121 Habeeb SY, Arthur BW, ten Hove MW. The effect of neutral density filters on testing in patients with strabismic amblyopia. *Can J Ophthalmol* 2012;47(4):348-350.
- 122 Chen ZD, Li JR, Thompson B, Deng DM, Yuan JP, Chan L, Hess RF, Yu MB. The effect of Bangerter filters on binocular function in observers with amblyopia. *Invest Ophthalmol Vis Sci* 2014;56(1):139-149.
- 123 Thompson B, Mansouri B, Koski L, Hess RF. Brain plasticity in the adult: modulation of function in amblyopia with rTMS. *Curr Biol* 2008;18(14):1067-1071.
- 124 Thompson B, Mansouri B, Koski L, Hess RF. From motor cortex to visual cortex: the application of noninvasive brain stimulation to amblyopia. *Dev Psychobiol* 2012;54(3):263-273.
- 125 Tuna AR, Pinto N, Brardo FM, Fernandes A, Nunes AF, Pato MV. Transcranial magnetic stimulation in adults with amblyopia. *J Neuroophthalmol* 2020;40(2):185-192.
- 126 Castaño-Castaño S, Martínez-Navarrete G, Morales-Navas M, Fernández-Jover E, Sánchez-Santed F, Nieto-Escámez F. Transcranial direct-current stimulation (tDCS) improves detection of simple bright stimuli by amblyopic Long Evans rats in the SLAG task and produces an increase of parvalbumin labelled cells in visual cortices. *Brain Res* 2019;1704:94-102.
- 127 Hess RF, Thompson B. Amblyopia and the binocular approach to its therapy. *Vision Res* 2015;114:4-16.
- 128 Levi DM, Knill DC, Bavelier D. Stereopsis and amblyopia: a mini-review. *Vision Res* 2015;114:17-30.
- 129 Barrett BT, Panesar GK, Scally AJ, Pacey IE. Binocular summation and other forms of non-dominant eye contribution in individuals with strabismic amblyopia during habitual viewing. *PLoS One* 2013;8(10):e77871.
- 130 Hess RF, Mansouri B, Thompson B. A new binocular approach to the treatment of amblyopia in adults well beyond the critical period of visual development. *Restor Neurol Neurosci* 2010;28(6):793-802.
- 131 Liu XY, Zhang JY. Dichoptic training in adults with amblyopia: additional stereoacuity gains over monocular training. *Vision Res* 2018;152:84-90.
- 132 Jia WL, Lan FF, Zhao X, Lu ZL, Huang CB, Zhao WX, Li M. The effects of monocular training on binocular functions in anisometric amblyopia. *Vision Res* 2018;152:74-83.
- 133 Vedamurthy I, Knill DC, Huang SJ, et al. Recovering stereo vision by squashing virtual bugs in a virtual reality environment. *Philos Trans R Soc Lond B Biol Sci* 2016;371(1697):20150264.
- 134 Chen ZD, Li JR, Liu J, Cai XX, Yuan JP, Deng DM, Yu MB. Monocular perceptual learning of contrast detection facilitates binocular combination in adults with anisometric amblyopia. *Sci Rep* 2016;6:20187.
- 135 Li RW, Provost A, Levi DM. Extended perceptual learning results in substantial recovery of positional acuity and visual acuity in juvenile amblyopia. *Invest Ophthalmol Vis Sci* 2007;48(11):5046-5051.
- 136 Li RW, Klein SA, Levi DM. Prolonged perceptual learning of positional acuity in adult amblyopia: perceptual template retuning dynamics. *J Neurosci* 2008;28(52):14223-14229.
- 137 Herbison N, MacKeith D, Vivian A, Purdy J, Fakis A, Ash IM, Cobb SV, Eastgate RM, Haworth SM, Gregson RM, Foss AJ. Randomised controlled trial of video clips and interactive games to improve vision in children with amblyopia using the I-BiT system. *Br J Ophthalmol* 2016;100(11):1511-1516.
- 138 Bau V, Rose K, Pollack K, Spoerl E, Pillunat LE. Effectivity of an occlusion-supporting PC-based visual training programme by horizontal drifting sinus gratings in children with amblyopia. *Klin Monbl Augenheilkd* 2012;229(10):979-986.

- 139 Hess RF, Mansouri B, Thompson B. A binocular approach to treating amblyopia: antisuppression therapy. *Optom Vis Sci* 2010; 87(9):697-704.
- 140 Hess RF, Babu RJ, Clavagnier S, Black J, Bobier W, Thompson B. The iPod binocular home-based treatment for amblyopia in adults: efficacy and compliance. *Clin Exp Optom* 2014;97(5):389-398.
- 141 Žiak P, Holm A, Halička J, Mojžiš P, Piňero DP. Amblyopia treatment of adults with dichoptic training using the virtual reality oculus rift head mounted display: preliminary results. *BMC Ophthalmol* 2017;17(1):105.
- 142 Kirandi EU, Akar S, Gokyigit B, Onmez FEA, Oto S. Risk factors for treatment failure and recurrence of anisometropic amblyopia. *Int Ophthalmol* 2017;37(4):835-842.
- 143 Seol BR, Yu YS, Kim SJ. Effect of 4-month intermittent atropine penalization in amblyopic children for whom patch therapy had failed. *J Pediatr Ophthalmol Strabismus* 2017;54(6):375-380.