


Accepted Manuscript

Extent of resection and long-term survival of pineal region tumors in Helsinki
Neurosurgery

Joham Choque-Velasquez, MD, Julio Resendiz-Nieves, MD, PhD, Behnam Rezai
Jahromi, MD, Roberto Colasanti, MD, Rahul Raj, MD, PhD, Juho Vehviläinen, MD,
Olli Tynninen, MD, Juhani Collan, MD, Mika Niemelä, MD, PhD, Juha Hernesniemi,
MD, PhD



PII: S1878-8750(19)32085-6

DOI: <https://doi.org/10.1016/j.wneu.2019.07.169>

Reference: WNEU 12969

To appear in: *World Neurosurgery*

Received Date: 15 February 2019

Revised Date: 22 July 2019

Accepted Date: 23 July 2019

Please cite this article as: Choque-Velasquez J, Resendiz-Nieves J, Jahromi BR, Colasanti R, Raj R, Vehviläinen J, Tynninen O, Collan J, Niemelä M, Hernesniemi J, Extent of resection and long-term survival of pineal region tumors in Helsinki Neurosurgery, *World Neurosurgery* (2019), doi: <https://doi.org/10.1016/j.wneu.2019.07.169>.

This is a PDF file of an unedited manuscript that has been accepted for publication. As a service to our customers we are providing this early version of the manuscript. The manuscript will undergo copyediting, typesetting, and review of the resulting proof before it is published in its final form. Please note that during the production process errors may be discovered which could affect the content, and all legal disclaimers that apply to the journal pertain.

Title page**Title**

Extent of resection and long-term survival of pineal region tumors in Helsinki Neurosurgery

Author names and affiliations:

Joham Choque-Velasquez, MD,¹ Julio Resendiz-Nieves, MD, PhD,¹ Behnam Rezai Jahromi, MD,¹ Roberto Colasanti, MD,^{2,3} Rahul Raj, MD, PhD,¹ Juho Vehviläinen, MD,¹ Olli Tynninén, MD,⁴ Juhani Collan, MD,⁵ Mika Niemelä, MD, PhD,¹ Juha Hernesniemi, MD, PhD⁶

¹Department of Neurosurgery, Helsinki University Hospital, University of Helsinki, Helsinki, Finland

²Department of Neurosurgery, Umberto I General Hospital, Università Politecnica delle Marche, Ancona, Italy

³Department of Neurosurgery, Ospedali Riuniti Marche Nord, Pesaro, Italy

⁴Department of Pathology, University of Helsinki and HUSLAB, Helsinki University Hospital, Helsinki, Finland

⁵Department of Radiation Oncology, Cancer Center, Helsinki University Central Hospital, Finland.

⁶"Juha Hernesniemi" International Center for Neurosurgery, Henan Provincial People's Hospital, Zhengzhou, China

E-mail: *Joham Choque-Velasquez, johchove@hotmail.com; Julio C. Resendiz-Nieves, julio.resendiz-nieves@hus.fi; Behnam Rezai Jahromi, behnam.rezai-@gmail.com; Roberto Colasanti, roberto.colasanti@gmail.com; Rahul Raj, rahul.raj@hus.fi; Juho Vehviläinen, juho.vehvilainen@hus.fi; Olli Tynninén, Olli.Tynninén@hus.fi; Juhani Collan, juhani.collan@hus.fi; Mika Niemelä, mika.niemela@hus.fi; Juha Hernesniemi, juha.hernesniemi@icloud.com

Corresponding author:

Joham Choque-Velasquez, MD

Department of Neurosurgery, Helsinki University Hospital,

Topeliuksenkatu 5, 00260 Helsinki, Finland

Email: johchove@hotmail.com

ACCEPTED MANUSCRIPT

Manuscript**Title**

Extent of resection and long-term survival of pineal region tumors in Helsinki Neurosurgery

Abstract:

Background: Pineal region tumors represent challenging surgical lesions with wide ranges of survival rates reported in different surgical series. Here, we emphasize the role of the complete microsurgical resection (CMR) in order to obtain a favorable long-term outcome of pineal region tumors.

Methods: We report a retrospective study of pineal region tumors operated in Helsinki Neurosurgery between 1997 and 2015. Information was obtained from the hospital records, and an evaluation of the Finnish population register was conducted in July 2018 to determine the current status of the patients.

Results: 76 pineal region tumors were operated. The survival rate was 62 % at a mean follow up of 125 ± 105 (0-588) months, and the disease-related mortality was limited to 14 (18.4%) patients. Up to July 2018, twenty-nine patients had died. 2 patients died 1 and 3 months after surgery with delayed thalamic infarctions, 12 patients with disease progression, and 15 had non disease-related deaths. Only one patient was lost in the long-term FU. 10/14 disease-related deaths occurred during the first 5 years of follow up: 5 diffuse gliomas, 3 germ cell tumors, 1 Grade II-III PPTID, and 1 meningioma. CMR was linked to better tumor free survival and long-term survival rates with exception of diffuse gliomas.

Conclusion: CMR, in the setting of a multidisciplinary management of pineal region tumors, correlates with favorable survival rates and with minimal mortality. Surgically treated grade II-IV gliomas conform a particular group with high mortality within the first 5 years independently of the microsurgical resection.

Key words:

Microneurosurgery, Multidisciplinary management, Pineal region lesions, Pineal tumors, Radiochemotherapy, Sitting position, Supracerebellar infratentorial approach

Introduction

The pineal region or the so called posterior incisural space/quadrigeminal cistern is a deep intracranial structure that may harbor a big variety of neurosurgical diseases such as benign pineal cysts, a wide range of pineal region tumors, vascular malformations, and aneurysms.¹⁻⁷

The pineal region represents a microsurgical challenging location. Since the introduction of the operative microscope and, later, of the endoscope, the surgical outcome of these pathologies improved dramatically. On the other hand, in the last decades, the development of the radiochemotherapy has made possible, in selected cases, less invasive therapeutic modalities, in particular for germinomatous tumors.⁸⁻¹² However, in opposition to all these therapeutic development, the diagnostic imaging of pineal region tumors still lacks precision, and histopathological and immunohistochemical examination is required for the definitive diagnosis.

Even though the above-mentioned technical advances improved the surgical outcome of pineal region lesions and different surgical series reported wide ranges of survival rates, long term follow up data are still scarce in the literature.⁸⁻¹²

Herein, we present the long-term surgical outcome of patients with pineal region tumors operated in Helsinki Neurosurgery (HN) between 1997 and 2015. Moreover, we aim to emphasize the importance of the complete microsurgical resection (CMR), in the setting of a multidisciplinary management of pineal region lesions (microneurosurgery and radiochemotherapy), in order to obtain a favorable long-term outcome.

Methods

Population

Following the Institutional Ethics Board approval number HUS/2772/2017, we retrospectively reviewed the patients with pineal region tumors that were consecutively operated on in our department between 1997 and 2015. Few previously treated patients underwent surgical removal of a persistent or recurrent pineal lesion during the study period. Definitive histological diagnoses were recorded and, in case of unclear diagnosis, the histological samples were re-revised by our neuropathologist. IMPAX version 6.5.5.1608 (Agfa, Mortsels, Belgium) was employed for the presurgical radiological evaluation, and for the post-operative imaging and evaluation of the extent of tumor resection as well. Finally, we examined the medical records to determine the preoperative status of the patients, the immediate and long

term clinical follow up of the patients, and one of the coauthors (RR) revised the Finnish population register in July 2018 in order to determine their current status.

The modified Rankin scale (mRS) was used to categorize and compare the preoperative, immediate postoperative, and long-term postoperative functional status of the patients. The correlations between the grade of microsurgical resection and mortality, pineal tumor free outcome, and volume of the lesion were analyzed using the Chi square and Mann-Whitney U test. P values <0.05 were considered significant. SPSS version 22 (SPSS Inc., Chicago, IL, USA) was used.

Complete microsurgical resection of pineal region lesions

CMR was introduced as a key component of the protocol for the management of the pineal region lesions when the senior author (JH) became the chairman of the Department of Neurosurgery in Helsinki in 1997. Thus, the term “subtotal resection” (STR) of the tumor was conveniently coined to refer just a very small and usually firmly adhesive residual piece attached to the venous walls or infiltrating critical structures, after a procedure aiming at a complete removal of the lesion. Few biopsies were performed by other colleagues as a part of the initial management of the lesions.

As above-mentioned, the pineal region is a very challenging surgical location because it is surrounded by critical neurovascular structures. Thus, the microsurgical principle “*Simple, clean, fast and safe*” under high operative magnification, is imperative for an efficient surgery.¹³⁻¹⁶

General approach for pineal region lesions during the study period

In HN, most of the patients harboring pineal region tumors associated with subacute or chronic symptoms are transferred from primary centers, the department of Neurology, or from some other hospitals across Finland or from abroad. Moreover, few cases are diagnosed as incidental findings after diagnostic imaging for unrelated symptoms.

All patients harboring a pineal lesion underwent the following examinations: tumor markers in blood and cerebrospinal fluid (CSF), endocrine assessment, basal pituitary hormone tests, CSF sampling for cytology, CT studies, and MRI (T1WI, T2WI, T1 with gadolinium enhanced/Fat suppression, FLAIR, and diffusion weighted sequences). Moreover, proton density, spectroscopy, tractography, CSF flow studies, and MR angiography/venography, may also be additionally required. In general, the preoperative evaluation of the deep venous system is the most valuable factor in planning the surgical strategy of pineal region tumors.

The therapeutic decision after all preliminary studies is recommended by the neurooncological team composed by a neurosurgeon, an oncologist, a neuropathologist, a radiologist, and a neurologist. Once the histological diagnosis is confirmed, the neurooncological team determines all further management, and the required adjuvant treatment.

In case of patients harboring pineal region tumors associated with hydrocephalus, acute and rapidly progressive hydrocephalus may initially require external ventriculostomy, endoscopic third ventriculostomy, ventriculoperitoneal/ventriculoatrial shunt, or direct removal of the lesions. This neurosurgical decision-making is related with the cytology study of the CSF, the presence of tumor markers in blood or CSF, and the preference of the surgeon. On the other hand, slow progressive hydrocephalus is generally treated by direct removal of the lesion.

Pre-microsurgical stage

Positioning and draping the patient are procedures made under the previously well-described protocol developed in Helsinki for a more ergonomic variant of the classic sitting position, the sitting praying position.¹⁻⁵

The supracerebellar infratentorial (SCIT) approach, which is suitable for infratentorial lesions behind and below the neurovascular structures, is the most frequently used route for pineal region surgery at our institution. Along the years a modified paramedian approach to the pineal region was perfected and performed routinely due to complications observed with the classic midline approach.^{3,16,17} The occipital interhemispheric (OIH) approach with or without transtentorial opening, is more suitable for tumors with large supratentorial segments extending behind and above the corpus callosum and the deep venous system. This approach is the second most frequently used at our institution and was widely described in another manuscripts.^{4,5} The transcortical, and the subtemporal approach are less frequently performed for lesions extended laterally to the temporo-occipital gyri. Other approaches might be also used according to specific locations of recurrent or residual tumors.

Microneurosurgery

When a proper pre-microsurgical stage is achieved, good microscopic job will be more fluent.¹⁶ Efficient microneurosurgery is only achieved after a continuous training, adequate knowledge of microsurgical principles and a proper neuroanatomical knowledge.

We summarize our microsurgical strategy for approaching pineal region tumors as follow: ^{13,15}

1. After a suboccipital craniotomy, the dura is opened under the microscope based on the transverse sinus. An occipital interhemispheric approach requires a superior sagittal sinus-based dura opening. Strong retraction with dural stitches provides an adequate surgical view along the approaches.

2. Under high magnification, we access the quadrigeminal cistern after a SCIT approach and the pericallosal cistern whether the OIH approach is performed. In both cases, CSF is continuously released along the access instead of preoperative spinal catheter placement. On the other hand, opening of the cisterna magna is often unnecessary in SCIT approach.
3. Along the SCIT approach, the quadrigeminal cistern is recognized as a dark tight membrane covering its dorsal and superior walls. We proceed to sharply open it uncovering the pineal tumor. After an OIH approach, the tumor may be directly recognized following the falx towards the splenium as no membrane covers the lesion.
4. We proceed to coagulate and cut the posterior or superior walls of the tumor, and microsurgical ring forceps help us to obtain a tumor sample for the immediate and definitive histological study.
5. A critical aspect before intending to remove the tumor consists in the proper preoperative evaluation of the MRI to define some degree of differentiation between the tumor and surrounding structures through some cleavage plane. Throughout our intraoperative evaluation, we could identify that opposite to infiltrative gliomas, most of pineal region tumors tend to preserve regular borders without aggressive microscopic infiltration of the surrounding parenchymal structures. This aspect remains as a key component for CMR without damage of the neurovascular structures.
6. Internal decompression of the tumor with a thumb regulated suction and bipolar forceps or ring microforceps is followed by a conventional microsurgical dissection aiming to reach the posterior wall of the third ventricle. The tumor is separated from the adjacent neurovascular tissue, under soft but continuous traction using bipolar microforceps or ring microforceps. Cotton dissection and water dissection techniques are useful tools as well, and a microsurgical mirror or an endoscope may find out some residual tumor at the inferior hidden area.
7. Another essential aspect along the microneurosurgery is closely related with the adherence and infiltration of the tumor into external layers of the deep venous system. The tumor should be carefully and softly dissected by water dissection technique, cotton dissection, and using microscissors and bipolar microforceps avoiding any vascular injury that may produce immediate or delayed complications. The postoperative evaluation of our “subtotal” resections demonstrated small residual pieces attached to these vessels.
8. Microsurgical dissection of meningiomas follows same aforementioned principles. However, extreme caution should be taken while dissecting surrounding arterial and venous vessels. Moreover, falcotentorial attachments of the tumor should be sectioned aiming a CMR.
9. Accurate hemostasis with a patient observation of any leak under continuous saline irrigation guaranties preventing postoperative hemorrhagic events.

10. Closing under the microscope looks beneficial for a better hemostasis, precise wound margin approximation, atraumatic handling of tissues, and improvement of the surgical dexterity. All those elements, together with the use of a paramedian SCIT approach, instead of a more traumatic midline approach, associated to new dura sealing agents might be essential to reduce the high risk of postoperative cerebrospinal leak and meningitis in pineal region surgery.^{3,17}

Neuroanesthesia

The main objective of neuroanesthesia is to maintain optimal perfusion and oxygen delivery to the central nervous system during the treatment. Moreover, intraoperatively, neuroanesthesia has to provide good surgical conditions. Some neuroanesthesiological considerations for pineal region surgery in sitting position were detailed previously.^{1,2}

Adjuvant therapy

The radiation therapy and the chemotherapy represent essential tools in the management of pineal region tumors. They were used as adjuvant therapy few weeks after the microsurgical resection of pineal region tumors with aggressive behavior such as high grade gliomas, high grade pineal parenchymal tumors (PPT), germinomas, mixed germ cell tumors, immature teratomas, high grade ependymomas, papillary tumors of the pineal region (PTPR), microcellular metastases; and also after recurrences of those malignant and some more benign tumors such as meningiomas. In very few cases, radiochemotherapy was used as a primary line of treatment. Along our study and according to the current literature, we noticed new protocols emerging constantly. The different protocols used at our institution according to the definitive diagnosis of the tumor are described in Table 1.

Results

One hundred forty seven pineal regions lesions (pineal cysts, vein of Galen malformations, arteriovenous malformations, cavernous venous malformations, posterior cerebral artery aneurysms and pineal region tumors) were operated in HN between 1997 and 2015. Seventy-six patients with pineal region tumors (38 females and 38 males) were operated during the study period: 23 (30%) PPT, 12 (16%) germ cell tumors (GCT), 10 (13%) meningiomas, 10 (13%) pilocytic astrocytomas, 6 (8%) grade II-IV diffuse gliomas, and 15 (20%) other tumors (Table 3). The mean age of the patients was $38,4 \pm 24$ years (5 months - 82 years). The average length, height, and width of the lesions were respectively 2.8, 2.5 and 2.6 cm with maximal dimensions of 9x7.3x5.8 cm. Detailed information of the study population are summarized in Figure 1, Table 2 and 3.

Around 90% of the cases were initially operated by SCIT approach, and 10% by OIH approach. These two surgical approaches were combined in very few cases, at the same stage or in multiple stages. Other surgical routes (such as the suboccipital midline approach to the fourth ventricle, the anterior interhemispheric approach, the subtemporal approach, the occipital transtentorial approach, and the parietal transcortical approach) were selected in few cases or combined with the two above mentioned most used approaches. The senior author JH performed the microsurgical removal of most of the tumors.

90% of the cases were operated on with patients in the sitting praying position. Other positions included the prone, supine, semisitting and park bench positions, particularly for biopsies, endoscopic procedures, brachytherapy, and for complementary multistage surgical procedures.

The survival rate for our surgically treated 76 pineal region tumors was 62 % (47/76) at a mean follow up of 125 ± 105 (0-588) months. However, the disease-related mortality of our series was limited to 14 (18.4%) patients. Up to July 2018, twenty-nine patients had died. No perioperative death was reported, 2 patients had delayed postoperative complications and died after 1 and 3 months since surgery, 12 patients had died with disease progression, and the other 15 died with reasons unrelated to the disease. Eleven disease-related deaths occurred during the first 10 years of follow up: 5 diffuse gliomas, 3 GCT, 2 Grade II-III pineal parenchymal tumor of intermediate differentiation (PPTID), and 1 meningioma. All of them except a grade II-III PPTID had died within the first 5 years.

Only a foreign grade II-III PPTID patient was lost at the long term follow up after partial resection. Moreover, another foreign patient with a large hemangiopericytoma who was operated twice in Finland, was contacted by email in 2017. She was alive more than 11 years since the initial gross total resection of the lesion, with some dependency for her daily activities after the second surgery for a recurrent tumor in 2014.

Pineal tumors in pediatric patients

Pineal region tumors in 22 young patients (30%) with ages ranging between 0- and 21-year-old were mainly characterized by GCT, pilocytic astrocytomas, pineocytomas, pineoblastomas and diffuse gliomas.

The first group of 10 patients (6 males, 4 females) includes children up to 6-year-old with 3 pilocytic astrocytomas and 7 other tumors (ganglioneuroblastoma, GCT, arachnoid cyst, PTPR, WHO grade II glioma, pineoblastoma, pineocytoma). Six patients (60%) debuted with hydrocephalus, 7 (70%) patients underwent SCIT approach, and 7 (70%) patients were operated on in the sitting position. Three disease related deaths (30%) belong to this group and only one patient is dependent at the last follow up (mRS:3).

The second group of 15 patients (10 males, 5 females) includes patients ranging between 14- and 21-year-old. The tumors were characterized by 7 GCT, 2 pineocytomas, 2 pilocytic astrocytomas, 1 pineoblastoma, 1 choroid plexus papilloma, 1 WHO grade II-III PPTID, 1 glioblastoma multiforme. Ten patients (67%) debuted with hydrocephalus, 14 (93%) patients underwent SCIT approach, and the sitting position was employed in 14 (93%) patients. Four disease related deaths (27%) belong to this group and only one patient is dependent at the last follow up (mRS:4)

Hydrocephalus and pineal tumors

Fifty-three (70%) of the seventy-six studied patients presented with preoperative obstructive hydrocephalus (information about preoperative hydrocephalus was unavailable in two cases) (Table 2).

Twenty-four of them underwent initial shunt surgery before tumor removal, two patients had initial endoscopic third ventriculostomy, while direct removal of the lesion was performed in twenty-seven patients. Most of the patients received initial shunt surgery during the first half of the study period. This group of patients underwent an average of more than two (2.3) shunt-related surgeries along the follow up. Seven patients undergoing initial shunt surgery suffered shunt removal due to different reasons and did not require a shunt device at the last radiological follow up.

Three patients (two pediatric and one adult) with large pineal region pilocytic astrocytomas had the higher number of shunt-related surgeries with ten, six and five procedures, respectively. All of them underwent initial shunt surgery with multiple shunt disfunctions during the follow up. The patient with the ten shunt-related surgeries was a 2-year old boy with a giant tumor, initially considered inoperable who underwent shunt surgery and radiotherapy in 1985, brachytherapy in 1995, and microsurgical removal of the tumor only in 2000.

Only one of the twenty-seven patients undergoing direct removal of the lesion required further endoscopic third ventriculostomy for persistent hydrocephalus due to a blood clot in the aqueduct. Finally, a ventriculoperitoneal shunt, still present at the last radiological follow up, was implanted in this patient. Regarding the two patients undergoing initial endoscopic ventriculostomy, one did not require any further treatment after complete resection of the lesion. However, the other patient underwent stereoscopic biopsy, shunt surgery due to persistent hydrocephalus, and brachytherapy. One more patient required endoscopic third ventriculostomy due to shunt dysfunction after initial shunt surgery and removal of the tumor. At the last radiological evaluation, forty-nine patients (64%) of our study population did not require shunts.

Microsurgical management of pineal region tumors

Table 4 describes the differences between the CMR, STR, and partial resection of our pineal tumors series.

Complete microsurgical resection

A CMR during the treatment was possible in 70% of the cases (53 patients). Only three of them (4%) showed recurrences in the pineal region at the last follow-up. A PPTID II-III and a meningioma are alive and have very small controlled recurrences 178 and 135 months after surgery. The third one, a patient with a locally recurrent germinoma and panventricular metastasis, died due to the progression of the disease 46 months after surgery and radiotherapy-based adjuvant therapy.

An anaplastic meningioma, and a diffuse grade II glioma had died 1 and 3 months after surgery with delayed postoperative infarctions. A patient with a pineoblastoma had multiple intracranial and spinal metastases without recurrence of the pineal tumor and died 173 months after surgery. A patient harboring a Glioblastoma multiform died 9 months after the initial surgery; nevertheless, the lesion did not recur in the pineal region, but in the cerebellum with multiple foci and important edema. A mature pineal teratoma, which initially had concomitant small intraventricular and interhemispheric tumors, is still alive 229 months since the initial surgery, free of recurrence with very slowly growing concomitant lesions. Fifteen patients died in this CMR group with 5 disease-related deaths (2 gliomas, 1 germinoma, 1 pineoblastoma, and an anaplastic meningioma).

Subtotal resection

A STR was achieved in 14 patients (18.4%) and, after adjuvant radiochemotherapy, only 2 of them were disease-free at the last follow up, an ependymoma and a mixed germ cell tumor that are alive 165 and 86 months after surgery. Five patients, 1 grade III glioma, 1 glioblastoma, 1 mixed GCT, 1 giant immature teratoma, and 1 giant grade II-III PPTID died respectively 52, 5, 11, 1, and 39 months after the initial surgery and a proper adjuvant therapy. The last 3 tumors had spinal metastases.

Another PPTID II-III with very small controlled disease died from pneumonia few weeks after a suicide attempt. A patient with a gliosis/glioma died 2 months after surgery (the reason of death was unavailable). Four patients, 3 pilocytic astrocytomas and 1 epidermoid tumor are alive with very small controlled lesions 231, 136, 139, and 376 months after the initial surgery. Summarizing, seven patients died in this STR group with 5 disease-related deaths (2 gliomas, 1 mixed germ cell tumor, 1 teratoma, and a PPTID II-III).

Partial resection

A partial resection was carried out in 5 cases (6.6%): the resection of the cystic component of a germinoma initially treated by radiation therapy 6 years before, a grade III glioma with thalamic infiltration, a pineal meningioma associated with a lymphoma of the splenium, a giant pilocytic astrocytoma (that initially was unsuccessfully treated with external radiation therapy 15 years and later with brachytherapy 5 years before surgery), and a large PPTID II-III. The first four patients died 223, 12, 77, and 324 months after the initial surgery. The last PPTID was operated in a foreign patient, who was lost at the follow up. Thus, we had 3 disease-related deaths in this group.

Biopsy and adjuvant therapy

Two grade II-III PPTID followed biopsy and radiotherapy. One of them died with poor neurological condition and well controlled tumor, 8 years after brachytherapy. The other patient is alive 368 months after the initial procedure, without evident tumor at the imaging.

We could not determine the grade of removal of the lesion in two patients harboring a ganglioneuroblastoma and an undefined tumor. Both died 23 and 35 months after surgery, respectively. Death reason was unavailable as well.

Survival rate and surgical features of different type of tumors

Throughout our analysis, we determined three well-differentiated groups of tumors. The first one has a very good survival outcome after surgical treatment and it is composed by arachnoid cysts, ependymomas, epidermoid tumors, hemangioblastomas, mature teratomas, papillary tumors of the pineal region, choroid plexus papilloma, pilocytic astrocytomas, pineocytomas, and solitary fibrous tumors/hemangiopericytomas. All of them represent 33% of the pineal region tumors and had an overall survival of 90-100% at an average follow up of 182 ± 121 (45-588) months. Only 2 patients died after a long follow up: an epidermoid tumor patient died 246 months after gross total resection without recurrence of the tumor, and a pilocytic astrocytoma 324 months after multiple combined therapies, respectively. Interestingly, we could recognize that the histologic phenotype of some tumor that underwent two or more surgeries, such as a WHO grade I Pilocytic astrocytoma, a WHO grade II papillary tumor of a pineal region, and a WHO grade II Hemangiopericytoma, evolved into more aggressive WHO grade II, III, and III tumors, respectively, between surgeries. Grade II-III PPTID, pineoblastomas, germinomas and non germinomatous GCT with exception of mature and immature teratomas represent 38% of tumors in the pineal region and had a moderate survival between 60 to 70% at an average follow up of 132 ± 86 (0-368) months. Germinomas, the most radiosensitive tumors, were diagnosed in 7 patients. CMR was achieved in 71% of the cases. We had 2 deaths in our series. A patient underwent CMR of a local germinoma and

adjuvant pineal-panventricular radiotherapy without chemotherapy. One year after the initial treatment the patient had a metastatic spinal recurrence controlled by radiochemotherapy. However, 2 years after the initial treatment the patient presented small recurrences in the left frontal horn and in the third ventricle with no response to adjuvant therapy and with posterior multiple large panventricular metastases. The patient died 46 months since surgery. Another patient was treated initially with radiation therapy after a biopsy in 1992. In August 1998, the patient returned to the department with a residual tumor and a large cystic component in the pineal region. The patient underwent partial resection with removal of the cystic component. In 2010, the patient had a stroke event and the MR imaging revealed a spinal metastatic tumor that required radiochemotherapy. The patient with multiple intracranial and spinal metastases died in 2011, 223 months after the initial treatment.

Ten meningiomas of the pineal region represent 13% of the tumors with 50% of overall survival at an average follow up of 94.5 ± 56 (1-205) months. Even though this group has a high mortality, only a case suffered a delayed postoperative thalamic infarction and died 1 month since surgery. Two patients had died due to multisystemic atrophy and an intractable lymphoma of the corpus callosum respectively, while the other 2 patients died at 91 and 83 years old without recurrence of the lesion and without postoperative complications. All of them underwent CMR except a patient with a lymphoma of the corpus callosum that underwent partial resection. Two falcotentorial meningiomas included in this series had superior and anterior location with a minimal tentorial component.

Gliomas, immature teratomas, ganglioneuroblastomas, microcytic cancer metastases, and neuroepithelial cysts are lesions with very bad prognosis in our series. They represent 13% of the tumors, and all of them died between 1 and 68 (mean: 18 ± 23) months. The neuroepithelial cyst and the microcytic metastasis died of reasons unrelated to the intracranial lesion. The median survival rate for the rest of these tumors was 5 months.

Clinical follow up and mortality

Preoperatively, 15 (19.7%) patients harbored independent functional status with a mRS 0-2, and 59 (77.6%) patients had some degree of dependency with a mRS 3-5. Information was unavailable in 2 patients. Regarding the immediate postoperative follow up, 55 (72.4%) patients achieved a mRS 0-2, and 18 (23.7%) patients had a mRS ≥ 3 . Information was unavailable in three patients; however, no perioperative mortality was reported. At the last clinical evaluation, 14 (18.4%) disease-related deaths (mRS 6) were reported. 48 (63.2%) patients had a mRS 0-2, and 12 (15.8%) patients had a mRS 3-5. Information was unavailable in 2 patients (Table 2). Moreover, evaluation of the Finnish population register in July 2018 revealed other 15 death patients without disease-related complications. Eight patients died of reasons unrelated to the disease, and the information regarding the death in patients with good operative outcome was

unavailable in 6 patients. A patient harboring an undefined apoplexic tumor who died 3 months after surgery did not register a specific reason of death. However, we highly suspect a death related to the course of the disease.

Complete microsurgical resection and mortality of the disease

As mentioned, 14 disease-related deaths were found in our series. Two of these patients, an anaplastic meningioma, and a diffuse grade II glioma had delayed postoperative thalamic infarctions and died 1 and 3 months after surgery, respectively. A patient with a giant immature teratoma had a good postoperative recovery, however, the postoperative MRI a week after surgery revealed spinal metastasis. The patient died at home 1 month after surgery. A WHO grade II-III PPTID patient, neurologically disabled, died 39 months after surgery. Eight patients with diffuse grade II-IV gliomas (4), germ cell tumors (3), and a pineoblastoma died of disease progression. A PPTID patient with very small controlled tumor after biopsy and brachytherapy died 8 years after the procedure with a slowly progressive neurological impairment. A giant pilocytic astrocytoma patient, who initially underwent biopsy and radiotherapy followed by brachytherapy few years later and finally multiple surgeries after the senior author became the chairman in Helsinki Neurosurgery, died more than 27 years after the initial treatment.

Table 5 summarizes the characteristics of those 14 disease-related deaths. 2 patients died of delayed postoperative complications, 7 patients had a progressive tumor growth with intracranial and/or spinal metastases, and 5 patients died without or with very small controlled pineal region tumor, but with intracranial or spinal metastases in 4 of them. The most aggressive tumors were diffuse grade II-IV gliomas followed by non germinomatous GCT. Overall, at 5-years follow-up, the mortality of both, gliomas plus non germinomatous GCT, represents the 50% of the entire mortality related to the disease. Moreover, the mortality of diffuse gliomas did not correlate with the degree of surgical resection; differently from the two non germinomatous GCT, which were subtotally resected and died due to progressive disease. An anecdotal glioblastoma case underwent CMR without local recurrence along the follow up. However, multiple cerebellar foci with important peritumoral edema appeared at the last stage of the disease and were the cause of death. Another illustrative case is represented by a patient with a germinoma who died 46 months after surgery, despite a CMR and a successive pineal-panventricular radiotherapy.

Discussion

We report our results of 76 pineal region tumors operated between 1997 and 2015 in the centralized Department of Neurosurgery-Helsinki University Hospital, which covers around 1,6 million people from the south area of Finland.¹⁸ 62% of the patients were alive at the last follow up; however, the disease-related mortality was limited to 14 (18.4%)

patients. Up to July 2018, twenty-nine patients had died with only one patient lost in the long term-FU. Eleven disease-related deaths occurred during the first 10 years of follow up: 5 diffuse gliomas, 3 germ cell tumors, 2 Grade II-III PPTID, and 1 meningioma. All of them except a grade II-III PPTID had died within the first 5 years. According to our analysis, the complete microsurgical resection was linked to better tumor free survival and long-term survival rates with exception of diffuse grade II-IV gliomas.

CMR of pineal region tumors seems effective for the treatment of concomitant hydrocephalus. Initial shunt surgery before removal of the tumor is associated to an increased number of shunt-related surgeries, particularly in those patients who underwent subsequent incomplete removal of the lesion. The number of initial endoscopic third ventriculostomies in our series is small and prevent to generate conclusions. However, two of our four patients required further shunt-surgery for persistent hydrocephalus. We believe that small ostomies associated with a reduced experience of the surgeon might play a role in this regard.

The protocol for the management of all pineal tumors along the study period remained similar. A complete microsurgical resection was our primary aim in most of the cases, with very few cases undergoing initial biopsy and subsequent adjuvant radiochemotherapy. However, currently, the policy for the management of pineal region lesions with hydrocephalus in our department, as in other specialized centers, includes endoscopic third ventriculostomy associated with tumor biopsy and further management, particularly in case of high suspicion of radiosensitive germinomas. In this regard, risks of intraprocedural bleeding, inadequate sampling, and inappropriate definitive management should be taken into account.

The approach to pineal region tumors in children did not have substantial changes compared to the adult population. The supracerebellar infratentorial approach was the most frequently used. The sitting praying position was also performed as frequent as in adult patients. However, tight elastic bandages in the lower extremities replaced the unavailable antigravity trousers for small children.^{2,19} Particular anesthetic considerations for pediatric population, as earlier described, consist in the use of ringer solution, saline solution with antibiotics, and mannitol at average volumes of 600 ml., 200 ml., and 125 ml., respectively; and the occasional use of hydroxyethyl starch in bigger volumes than in adult patients.¹⁹

Sitting praying position

The head of the patient, which is tilted beyond the projection of the anterior wall of the thorax, is usually 20°-30° flexed, preserving a distance between the chin and sternum. For this purpose, the table is bent around 90°-100° elevating the upper torso of the patient. All this sequence maintains the horizontal axis of the tentorium parallel to the

floor, with less than 90° in relation to the axis of the surgeon. The Anesthesia Team will modify the position of the table according to the requirements of the surgeon. In pineal region surgery, other surgical positions such as the prone, semisitting or park bench positions are rarely utilized when an absolute contraindication for the sitting position exists, or when the lesion is better accessed by a different approach. Inside the operation room, teamwork coordination is essential. This proper teamwork can be clearly exemplified with the immediate reaction of the anesthesiologist in case of venous air embolism during the surgery. The access and compression of both jugular veins by the anesthesiologist is very effective to find the leak, which is repaired by the surgeon using hemostatic agents or direct suturing.¹⁻³

The supracerebellar infratentorial approach

The supracerebellar infratentorial paramedian approach (SCIT), a less invasive variant of the midline suboccipital approach, represents an efficient surgical approach to the pineal region we developed in the last years due to the relative high rate of complications with the classic midline approach, as shown in Table 6.^{3,6,17} Using this approach the pineal region is accessed over the superior surface of the cerebellar hemisphere. The quadrigeminal cistern is opened laterally without damaging the midline vascular structures. Moreover, thanks to the gravity effect offered by the praying sitting position, a retraction less approach might be performed.

Outcome and long term follow up

The long term follow up in our series allowed us to determine properly the course of the managed pineal region lesions. Thus, recurrences after complete resection, or incomplete removal followed by standard adjuvant therapy and functional outcome were clearly seen.

Large data analysis about unselected pineal region tumors might be summarized as follow. Pineal tumors in the French National Register, which included pineal parenchymal tumors (PPT), germ cell tumors, gliomas, pineal cysts, and primitive neuroepithelial tumors had an average survival of 49% within an average follow up of 5.8 (1-23) years. From 452 patients, 328 underwent direct surgery, and 164 (50%) had a complete removal (50%), 24% a partial removal, and in the 26% of the patients the quality of removal were not mentioned. The overall mortality was 137 patients (30%), and 20% of the patients were lost at the follow up. The overall postoperative mortality was 1.8%. They mentioned that after ten years patients were considered cured and the follow-up ended.⁸

Pineal tumors in the surveillance, epidemiology, and end results data of cancer in the United States mainly based on GCT, PPT, and gliomas published in 2010, had a 5-year overall survival of 65% ± 2.1%, and the median survival time was 19.3 years. The 5-year overall survival for GCT was 78.9%, 61% for gliomas, and 47.2% for PPT. According to

their analysis, non-germ cell tumors and no radiotherapy were factors associated with a negative outcome. The extent of surgical tumor resection did not affect survival in any histologic subgroup. However, the disclosed information revealed that surgical data was available for 552 patients: 224 patients had no surgery, only 32 (6%) underwent total excision, and 296 had other surgeries.⁹

Data of Brain Tumor Registry of Japan revealed that the most frequent tumor in the pineal region was germinoma (49.2%) followed by pineocytoma (8.5%), glioma (6.5%), pineoblastoma (5.1%), malignant teratoma (5.2%), and other teratomas (5.1%). The 5-year survival rate of germinomas, pineocytomas, and pineoblastomas was 89.4%, 84.1% and 46.1%, respectively.¹⁰ Burdenko Neurosurgery Institute in Russia reported their results of 287 patients with histologically verified pineal region tumors from 700 pineal tumors mainly distributed as GCT (31%), PPT (27%), glial tumors (27%), and miscellaneous (15%). Gross total resection was achieved in 148 operations (58%), subtotal resection in 74 (29%) and partial in 33 (13%). The projected 5-year and 10-year survival rates were: 95% and 88% for germinomas, 80% and 50% for high grade gliomas, 44% and 0% for high grade PPT, and 20% and 0% for malignant GCT, respectively.¹¹

A report from the international gamma knife research foundation after stereotactic radiosurgery for pineal region tumors described an actuarial local control and survival rates of 81% and 76% at 20 years for pineocytomas, 50% and 56% at 5 years for PPTID, 27% and 48% at 5 years for pineoblastomas, 33% and 100% at 5 years for papillary tumors of the pineal region, 80% and 80% at 20 years for germinomas, and 61% and 67% at 5 years for tumors of unknown histology.¹²

Our survival rates were superior to those published in the literature. Moreover, the evaluation of the Finnish population register to determine the current status of our patients remarks the validity of our study. The analysis of the overall survival of our series uncovered some tumors of bad prognosis such as metastatic tumors, immature teratomas, ganglioneuroblastomas, and gliomas II-IV. However, the specific mortality analysis determined that grade II-IV gliomas are the unique type of lesion characterized by very aggressive behavior, independently of the degree of resection, and are associated with high mortality during the first five years after surgery. The second most aggressive lesion corresponds to some non germinomatous GCT, particularly immature teratomas and mixed GCT, whose mortality correlates with the degree of resection. Other tumors with a progressive disease in spite of CMR were a germinoma that underwent radiotherapy-based adjuvant therapy, and a pineoblastoma with a metastatic recurrence 14 years after surgery.

PPTs except pineocytomas are usually reported as tumors with bad prognosis. 100% of our pineocytoma patients and pineoblastoma patients were alive more than 20 and 10 years, respectively. On the other hand, the 5-and 10-year

survival rate for our grade II-III PPTIDs were 92% and 71%, respectively. On the basis of the current literature as well as of our data, we strongly believe that the good surgical outcome of PPT patients is directly related with the CMR followed by a proper adjuvant radiochemotherapy.²⁰⁻²²

Primary glioblastomas in the pineal region are well documented by the literature and show an average survival of 7 months.²³ Similarly, a comprehensive literature review of gliomas in the pineal region revealed that grade II and III gliomas have a dismal outcome compared to their hemispheric counterparts. On the other hand, grade I pilocytic astrocytomas have a good prognosis. In this regards, the categorization of pilocytic astrocytomas and non pilocytic grade II-IV pineal gliomas would better represent the prognosis of this entity.²⁴

Our results confirm these findings. Pilocytic astrocytomas had a very good prognosis with a 5-year and 10-year overall survival rate of 100%. However, giant tumors requiring multiple surgeries were usually described. CMR was possible in 60% of the cases. Only partial resection was possible after external and internal radiotherapy in a particular giant tumor. On the other hand, and in spite of our small number of diffuse grade II-IV gliomas, we may conclude that these tumors have a high mortality during the first 5 years after surgery, which does not correlate with the extent of the surgical resection.

Meningiomas of the pineal region might be divided as falcatentorial and velum interpositum meningiomas. Frequent recurrences are observed in patients after subtotal resection, and with atypical and anaplastic meningiomas. However, some authors justify the partial resection of the meningiomas, and the use of radiosurgery for residual tumors or local recurrences attached to the deep venous system, since severe neurological complications have been reported in the literature after occlusion of the deep venous system.²⁵⁻²⁸ Even though, in our series, the mortality related to surgical complications is reduced to a patient, we consider extremely important the recognition and the preservation of the deep arterial and venous systems, which are commonly involved into the tumor, particularly in large meningiomas. Whether those structures are insufficiently dissected, radiation therapy might play an important role in the management of residuals or recurrent tumors.

The current literature supports the radiochemotherapy as the first line of treatment for germinomas. This is based on the excellent outcomes in the North Asian population series, where germinomas account for more than 40% of the pineal region tumors.^{10,29} However, in our population, where germinomas represent less than 10% of our pineal tumors, the protocol for their management becomes challenging. Since the senior author introduced the CMR as a primary concept for the management of pineal lesions, the immediate intraoperative histological analysis did not offer a consistent diagnosis of the lesions. Moreover, as almost 50% of our germ cell tumors were non germinomatous and mixed tumors, with less response to radiation and chemotherapy, radical removal of the lesions had to be performed. Currently, based

on the development of magnetic resonance imaging and serum or cerebrospinal fluid tumor markers, we may accomplish a better screening of these lesions that might allow us to perform biopsies followed by radiochemotherapy. Herein, we present our long term results about tumors of the pineal region. Even though important findings were reached, future research is required to determine the impact of the adjuvant radiochemotherapy associated to the CMR in every specific group of pineal lesions. Diffuse gliomas of the pineal region remain challenging lesions for neurosurgeons and require important research for alternative management. Our internal analysis gave us already a clue about the correlation between different protocols of radiation therapy and chemotherapy and the survival of tumors, such as PPT or germinomas. On the other hand, future research is also needed to extend the surveillance analysis of the present series in order to report longer follow up outcomes. After all, we may also remark that it is extremely important to determine the treatment modality for these rare and complex lesions, based on the oncological advisory commission of every neurooncological department.⁸

A limitation of this study remains in the retrospective approach of the cases. However, as pineal tumors are rare, we still aim to enhance the importance of the microneurosurgery as a treatment modality for a favorable long-term outcome.

Conclusion

Complete microsurgical resection, in the setting of a multidisciplinary management of surgically treated pineal region tumors in HN, correlates with favorable tumor free survival and long-term survival rates with minimal postoperative mortality. Surgically treated diffuse gliomas of the pineal region should be considered a particular group harboring high mortality independently of the microsurgical resection.

References:

1. Choque-Velasquez J, Colasanti R, Resendiz-Nieves JC, et al. Venous air embolisms and sitting position in Helsinki pineal region surgery. *Surg Neurol Int.* 2018;9:160. doi:10.4103/sni.sni_128_18
2. Choque-Velasquez J, Colasanti R, Resendiz-Nieves JC, et al. Praying Sitting Position for Pineal Region Surgery: An Efficient Variant of a Classic Position in Neurosurgery. *World Neurosurg.* 2018;113:e604-e611. doi:10.1016/j.wneu.2018.02.107
3. Choque-Velasquez J, Colasanti R, Resendiz-Nieves JC, et al. Supracerebellar Infratentorial Paramedian Approach in Helsinki Neurosurgery: Cornerstones of a Safe and Effective Route to the Pineal Region. *World Neurosurg.* 2017;105:534-542. doi:10.1016/j.wneu.2017.06.007
4. Choque-Velasquez J, Colasanti R, Resendiz-Nieves J, et al. Papillary Tumor of the Pineal Region in Children: Presentation of a Case and Comprehensive Literature Review. *World Neurosurg.* 2018;117:144-152. doi:10.1016/j.wneu.2018.06.020
5. Choque-Velasquez J, Resendiz-Nieves J, Colasanti R, Collan J, Hernesniemi J. Microsurgical Management of Vascular Malformations of the Pineal Region. *World Neurosurg.* 2018;117:e669-e678. doi:10.1016/j.wneu.2018.06.110
6. Choque-Velasquez J, Raj R, Hernesniemi J. One burr-hole craniotomy: Supracerebellar infratentorial paramedian approach in Helsinki Neurosurgery. *Surg Neurol Int.* 2018;9:162. doi:10.4103/sni.sni_164_18
7. Iacoangeli M, Colasanti R, Esposito D, et al. Supraorbital subfrontal trans-laminar endoscope-assisted approach for tumors of the posterior third ventricle. *Acta Neurochir (Wien).* 2017;159(4):645-654. doi:10.1007/s00701-017-3117-0
8. Mottotese C, Beuriat PA, Szathmari A. Pineal tumours: Experience of the French National Register and the Lyon School, results and considerations. *Neurochirurgie.* 2015;61(2-3):223-235. doi:10.1016/j.neuchi.2014.02.006
9. Al-Hussaini M, Sultan I, Abuirmileh N, Jaradat I, Qaddoumi I. Pineal gland tumors: experience from the SEER database. *J Neurooncol.* 2009;94(3):351-358. doi:10.1007/s11060-009-9881-9
10. Shibui S, Nomura K. Statistical analysis of pineal tumors based on the data of Brain Tumor Registry of Japan. *Prog Neurol Surg.* 2009;23:1-11. doi:10.1159/000210049
11. Konovalov AN, Pitskhelauri DI. Principles of treatment of the pineal region tumors. *Surg Neurol.* 2003;59(4):250-268.
12. Iorio-Morin C, Kano H, Huang M, et al. Histology-Stratified Tumor Control and Patient Survival After Stereotactic Radiosurgery for Pineal Region Tumors: A Report From the International Gamma Knife Research Foundation. *World Neurosurg.* 2017;107:974-982. doi:10.1016/j.wneu.2017.07.097
13. Velasquez JC, Lau J, Kozyrev D, et al. Clean, fast and preserving normal anatomy: "the Helsinki revolution" in microneurosurgery. *J Neurosurg Sci.* 2016;60(1):44-53.
14. Choque-Velasquez J, Kozyrev DA, Colasanti R, et al. The open access video collection project "Hernesniemi's 1001 and more microsurgical videos of Neurosurgery": A legacy for educational purposes. *Surg Neurol Int.* 2017;8:188. doi:10.4103/sni.sni_158_17
15. Hernesniemi J, Niemelä M, Dashti R, et al. Principles of microneurosurgery for safe and fast surgery. *Surg Technol Int.* 2006;15:305-310.
16. Hernesniemi J, Niemelä M, Karatas A, et al. Some collected principles of microneurosurgery: simple and fast, while preserving normal anatomy: a review. *Surg Neurol.* 2005;64(3):195-200. doi:10.1016/j.surneu.2005.04.031

17. Choque-Velasquez J, Resendiz-Nieves JC, Rezai Jahromi B, et al. The microsurgical management of benign pineal cysts: Helsinki experience in 60 cases. *Surg Neurol Int.* 2019;10(103). doi:10.25259/SNI-180-2019
18. HUS - Key figures. <http://www.hus.fi/en/about-hus/key-figures/Pages/default.aspx>. Accessed October 13, 2018.
19. Lindroos A-C, Niiya T, Randell T, Romani R, Hernesniemi J, Niemi T. Sitting position for removal of pineal region lesions: the Helsinki experience. *World Neurosurg.* 2010;74(4-5):505-513. doi:10.1016/j.wneu.2010.09.026
20. Nakazato Y, Jouvett A, Scheithauer BW. Pineoblastoma. In: *WHO Classification of Tumours of the Central Nervous System*. Lyon: International Agency for Research on Cancer (IARC); 2007:126-127.
21. Parikh KA, Venable GT, Orr BA, et al. Pineoblastoma-The Experience at St. Jude Children's Research Hospital. *Neurosurgery.* 2017;81(1):120-128. doi:10.1093/neuros/nyx005
22. Tate M, Sughrue ME, Rutkowski MJ, et al. The long-term postsurgical prognosis of patients with pineoblastoma. *Cancer.* 2012;118(1):173-179. doi:10.1002/cncr.26300
23. Moon K-S, Jung S, Jung T-Y, Kim I-Y, Lee M-C, Lee K-H. Primary glioblastoma in the pineal region: a case report and review of the literature. *J Med Case Reports.* 2008;2:288. doi:10.1186/1752-1947-2-288
24. Magrini S, Feletti A, Marton E, Longatti P. Gliomas of the pineal region. *J Neurooncol.* 2013;115(1):103-111. doi:10.1007/s11060-013-1200-9
25. Nowak A, Dziedzic T, Czernicki T, Kunert P, Marchel A. Falcatentorial and velum interpositum meningiomas: two distinct entities of the pineal region. *Neurol Neurochir Pol.* 2014;48(6):397-402. doi:10.1016/j.pjnns.2014.09.009
26. Konovalov AN, Spallone A, Pitzkhelauri DI. Meningioma of the pineal region: a surgical series of 10 cases. *J Neurosurg.* 1996;85(4):586-590. doi:10.3171/jns.1996.85.4.0586
27. Castellano F, Ruggiero G. Meningiomas of the posterior fossa. *Acta Radiol Suppl.* 1953;104:1-177.
28. Pendl G. Management of pineal region tumors. *Neurosurg Q.* 2002;12(4):279-298.
29. Dho Y-S, Jung K-W, Ha J, et al. An Updated Nationwide Epidemiology of Primary Brain Tumors in Republic of Korea, 2013. *Brain Tumor Res Treat.* 2017;5(1):16-23. doi:10.14791/btrt.2017.5.1.16

Figure Legends

Fig.1 Age distribution in patients with pineal region tumors in the Department of Neurosurgery, Helsinki University Hospital.

Table 1. Different adjuvant therapy protocols used at Helsinki Neurosurgery according to the definitive diagnosis of the tumor

| Tumor | Radiotherapy | Chemotherapy |
|--|--|---|
| Glioblastoma multiforme | <ul style="list-style-type: none"> 54 Gy of focal fractionated external radiotherapy | <ul style="list-style-type: none"> Multiple doses of Temozolomide 150mg/m² |
| Pineoblastoma | <ul style="list-style-type: none"> Fractionated external radiotherapy with 36 Gy craniospinal radiation and additional 18 Gy boost of radiation on the tumoral bed after gross total resection. | <ul style="list-style-type: none"> Medulloblastoma protocol: initially, vincristine 1.5mg/m² once a week for 6 weeks is set. Six weeks after this initial treatment, a new scheme of chemotherapy is administrated every 6 weeks with 8 cycles of lomustine: 75mg/m²x1; cisplatin: 75mg/m²x1; and vincristine: 1,5 mg/m²x3 on days 0, 7, and 14. It is employed for children and patients with high risk of metastases such as incomplete resection or tumor recurrences. |
| Grade II-III Pineal parenchymal tumor of intermediate differentiation. | <ul style="list-style-type: none"> Fractionated external radiation therapy with 54 Gy divided in a daily dose of 1.8-2Gy was delivered in selective cases, such as high grade PPTID with pleomorphic histology including pineoblastoma features, after partial resection of the lesion and, after recurrence of the tumor at the follow up. Brachytherapy with iodine-125 seeds was used in a case | <ul style="list-style-type: none"> No chemotherapy was administered in our series, but we recommend to use it in case of a pediatric presentation |
| A large recurrent grade III papillary tumor of the pineal region in a pediatric case | <ul style="list-style-type: none"> Fractionated external radiotherapy of 54Gy divided in a daily dose of 1,8Gy after gross total resection. | <ul style="list-style-type: none"> High grade ependymoma protocol: cisplatin-cyclophosphamide-vincristine-etoposide, delivered in four intravenous cycles, each lasting 21 days: 1) days 1, 8, and 15 for the first three cycles: vincristine, 1.5 mg/m², 2) days 1, 2, 3: etoposide, 100 mg/m², 3) day 1: cisplatin, 100 mg/m², and 4) days 2, 3: cyclophosphamide, 1000 mg/m². |
| Ependymoma. | <ul style="list-style-type: none"> Fractionated radiation therapy with 54 Gy was used for a small remnant in a grade I-II | <ul style="list-style-type: none"> Recommended in high grade ependymomas as mentioned above. |
| Germinoma | <ul style="list-style-type: none"> Currently, fractionated radiotherapy of 45Gy (30,6 ventricular area and a booster of 14,4Gy to the hypophysis-pineal region) divided in a daily dose of 1,8Gy. | <ul style="list-style-type: none"> Post radiation chemotherapy with etoposide 100mg/m² days1-5, cisplatin 20mg/m² days 1-5, and bleomycin 30,000 IU days 1, 8, and 15. |
| Mixed germ cell tumors | <ul style="list-style-type: none"> Fractionated radiotherapy. Variable doses of craniospinal radiotherapy or whole- | <ul style="list-style-type: none"> Chemotherapy after gross total resection based on the above |

| | | |
|---|--|---|
| | ventricular radiation therapy are applied according to the poor or intermediate prognosis of the lesion based on the histopathology (poor: yolk sac tumor-choriocarcinoma-embryonal carcinoma; intermediate: germinoma-teratoma) and serum markers (poor >2000 UI) of α -fetoprotein and β -human chorionic gonadotropin. | etoposide-cisplatin-bleomycin protocol |
| Immature teratoma | <ul style="list-style-type: none"> Requires radiochemotherapy. However, the unique case in our series had a bad neurological outcome and did not receive any complementary treatment. | |
| Microcellular metastases | <ul style="list-style-type: none"> 30 Gy of whole brain external radiation therapy. | <ul style="list-style-type: none"> Chemotherapy according to the primary tumor |
| Small recurrent meningiomas or pilocytic astrocytomas | <ul style="list-style-type: none"> Mainly treated by focal external radiation therapy. | |

Table 2. Characteristics of the 76 patients with surgically treated pineal region tumors.

| | |
|--|---|
| Population | 76 patients; Age: $38,4 \pm 24$ (0.4 - 82) years; 38 females and 38 males |
| Symptoms of presentation | <p>Symptoms: anosmia, ataxia, balance disturbances, cognitive deficits, disorientation, facial and corporal sensory deficits headache, memory deficits, nausea, psychomotor disturbances, seizures, tremor, vomit, unconsciousness, urinary incontinence, vertigo, walking difficulties, motor deficits.</p> <p>Visual and oculomotor abnormalities: anisocoria, double vision, Parinaud's syndrome, visual field defects, and unspecific visual disturbances.</p> <p>Rare presentations: apoplectic hemorrhage, Asymptomatic germ cell tumor with diabetes insipidus and hormonal imbalance.</p> |
| Hydrocephalus in pineal tumors: 53 patients (70%) | <p>Initial treatment:</p> <p>Initial shunt surgery before tumor removal: 24 patients. Mean: 2.3 (1-10) shunt related surgeries.</p> <p>Endoscopic third ventriculostomy: 2 patients</p> <p>Direct removal of the tumor: 27 patients</p> |
| Pineal tumor Size (cm) | Mean (Maximal): Length: 2.8 (9) cm; Height: 2.5 (7.3) cm; Width: 2.6 (5.8) cm |
| Surgical approach | <p>Supracerebellar infratentorial approach: \pm 90%</p> <p>Occipital interhemispheric approach: \pm 10%</p> <p>Other approaches: combined supra and infratentorial approaches, anterior interhemispheric approach, telovelar approach, subtemporal approach, transcortical approach</p> |
| Surgical position | Sitting position: 90%; Others (supine, park bench): 10% |
| Microsurgical resection | Complete: 53; Subtotal: 14; Partial: 5; Biopsy: 2; UI: 2 |
| Preoperative functional status | mRS 0:4; mRS 1:3; mRS 2:8; mRS 3:17; mRS 4:28; mRS 5:14; UI: 2 |
| Immediate postoperative evaluation | mRS 0:3; mRS 1:22; mRS 2:30; mRS 3:8; mRS 4:7; mRS 5:3; UI: 3 |
| Functional status at the last clinical evaluation, 125 \pm 105 (0.5-588) months; and deaths in | <p>mRS 0: 20; mRS 1: 15; mRS 2: 13; mRS 3: 7; mRS 4: 3; mRS 5: 2; mRS 6: 14; UI: 2</p> <p>Deaths in July 2018: 29 (14 disease related, 8 unrelated to the disease, 6 unknown reason of death)</p> |

| | |
|--|--|
| July 2018 | |
| Final status at the last clinical evaluation | Improved: 54 (20 symptom free) patients No change in mRS: 4 patients (2 patients were dependent due to other comorbidities) Worsened: 17 patients (14 disease related deaths) UI: 2 |

mRS: modified Rankin Scale; UI: unavailable information

Table 3. Pineal region tumors operated in HUH between 1997-2015

| Diagnosis | Cases | Survival rate (%) | 5-year survival rate (%) | 10-year survival rate (%) | Follow up (months) |
|--|-----------|-------------------|--------------------------|---------------------------|--------------------------|
| Pineal parenchymal tumors: | 23 | 70 | 95 | 88 | 160±89 (0-368) |
| 16 PPTID # | | 63 | 92 | 71 | 143±100 (0-368) |
| 3 pineoblastomas | | 67 | 100 | 100 | 161.3±13 (147-173) |
| 4 pineocytomas | | 100 | 100 | 100 | 224.5±18 (204-246) |
| Germ cell tumors | 12 | 67 | 72 | 57 | 106±81 (1-229) |
| 7 germinomas | | 71 | 86 | 75 | 113,7±75 (46-223) |
| 1 mature teratoma | | 100 | | | 229 |
| 1 immature teratoma | | 0 | | | 1 |
| 3 mixed germ cell tumors | | 67 | | | 11, 86, and 148 |
| Pilocytic astrocytomas * | 10 | 90 | 100 | 100 | 143.7±88 (52-324) |
| Meningiomas | 10 | 50 | 89 | 75 | 94.5±56 (1-205) |
| Diffuse gliomas (WHO grade II, III and IV) | 6 | 0 | - | - | 13.8±19 (2-52) |
| 1 WHO grade II gliomas | | | | | 3 |
| 2 WHO grade III gliomas | | | | | 12-52 |
| 2 Glioblastoma multiforme | | | | | 5-9 |
| 1 Quadrigeminal glioma/gliosis | | | | | 2 |
| Solitary fibrous tumor-Hemangiopericytoma | 2 | 100 | | | 45, and >132 |
| Ependymoma | 2 | 100 | | | 122-165 |
| Epidermoid | 2 | 50 | | | 246-376 |
| Arachnoid cyst& | 1 | 100 | | | 172 |
| Ganglioneuroblastoma | 1 | 0 | | | 23 |
| Hemangioblastoma | 1 | 100 | | | 78 |

| | | | | | |
|--------------------------------------|----|-----|----|----|-----------------|
| Microcytic cancer metastasis | 1 | 0 | | | 8 |
| Neuroepithelial cyst | 1 | 0 | | | 68 |
| Papillary tumor of the pineal region | 1 | 100 | | | 54 |
| Choroid plexus papilloma | 1 | 100 | | | 588 |
| Undefined tumors | 2 | 0 | | | 3-35 |
| Total | 76 | 62 | 84 | 76 | 125±105 (0-588) |

PPTID, pineal parenchymal tumor of intermediate differentiation

A PPTID case did not have a histology report

* Three cases were reported as atypical, diffuse type and a tumor change from a grade I astrocytoma to grade II after one year from partial resection. One case belongs to an anterior vermis region tumor.

& Wide microsurgical fenestration of the cyst with complete obliteration observed at the follow up.

Table 4. Differences between the complete microsurgical resection, subtotal resection, and partial resection of 76 pineal tumors operated in Helsinki Neurosurgery between 1997 and 2015 (P value calculated between CMR and STR+PR as No-CMR).

| Grade of surgical resection* | Complete microsurgical resection | Subtotal resection | Partial resection | P value |
|--|---|--|--|---------|
| | 70% (53) | 18% (14) | 7% (5) | |
| General Mortality | 28% (15/53) | 50% (7/14) | 80% (4/5) | P<0.05 |
| Mortality of the disease | 9% (5/53) | 36% (5/14) | 60% (3/5) | P<0.01 |
| Pineal tumor free at last FU | 94% (50/53) | 14% (2/14) | 0% (0/5) | P<0.001 |
| Pineal tumor volume (mm ³) | 9773±11952 (500-53261) | 25660±33764 (392-122500) | 31387±34255 (5750-90000) | P=0.2 |
| Mortality of the disease | 2 diffuse gliomas, 1 germinoma, 1 pineoblastoma, 1 anaplastic meningioma. | 2 diffuse gliomas, 1 mixed germ cell tumor, 1 teratoma, and a PPTID II-III | Germinoma, a diffuse glioma, and a giant pilocytic astrocytoma | |

FU, follow up; CMR, Complete microsurgical resection; PPTID, pineal parenchymal tumor of intermediate differentiation; PR, partial resection; STR, subtotal resection

*4 cases, 2 cases that underwent biopsies, and 2 cases with unavailable information were excluded from the analysis. The absolute number of cases is written between parentheses.

Table 5. Mortality related with complications of the surgery or progression of the disease.

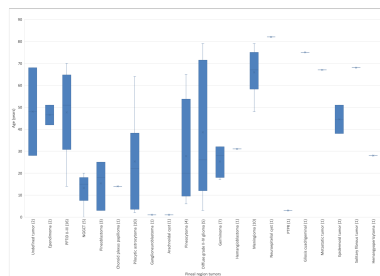
| Tumor number of cases) | Mortality along the FU (cases) | Mortality in the first 5 years (cases) | CMR | Reason of death (surveillance in months) | STR | Reason of death (surveillance in months) | P | Reason of death (surveillance in months) | B+B | Reason of death (surveillance in months) |
|----------------------------|--------------------------------|--|-----|--|-----|--|---|--|-----|--|
| Grade II-IV glioma (6) | 83 % (5) | 83 % (5) | 2 | Thalamic Infarction (3 m.), CT+cerebellar infiltration (9 m.) | 2 | PT+ICI (5 and 52 m.) | 1 | PT+ICI (12 m.) | | |
| Grade II-III PPTID (16) | 13 % (2) | 6 % (1) | | | 1 | CT+SI (39) | | | 1 | CT+brain atrophy, rigidity, aphasia (101 m.) |
| Germinoma (7) | 29 % (2) | 14 % (1) | 1 | PT+ICI (46 m.) | | | 1 | PT+ICI+SI (223 m.) | | |
| NGGCT (5) | 40 % (2) | 40 % (2) | | | 2 | CT+SI (1 m.), PT+ICI (11 m.) | | | | |
| Meningioma (10) | 10 % (1) | 10 % (1) | 1 | Thalamic Infarction (1 m.) | | | | | | |
| pilocytic astrocytoma (10) | 10 % (1) | 0 % (0) | | | | | 1 | PT+ICI (324 m.) | | |
| Pineoblastoma (3) | 33 % (1) | 0 % (0) | 1 | CT+ICI(pons)+SI (173 m.) | | | | | | |
| Total | 14 | 10 | 5 | | 5 | | 3 | | 1 | |

B+BT, biopsy plus brachytherapy; CT, controlled tumor; CMR, complete microsurgical resection; ICI, intracranial infiltration; NGGCT, non germinomatous germ cell tumor; PR, partial resection; PT, progressive

tumor; PPTID, pineal parenchymal tumor of intermediate differentiation; SI, spinal infiltration; STR, subtotal resection.

Table 6. Supracerebellar infratentorial approach and postoperative complications in surgery of pineal region tumors (Chi-Square, $p < 0.05$).

| Approach | Postoperative complications related to the approach | % |
|--|---|-----|
| Midline supracerebellar infratentorial approach (number of patients: 28) | Bacterial meningitis: 4 Wound infection: 3 Epidural hematoma: 1 (8 patients) | 29% |
| Supracerebellar infratentorial paramedian approach (number of patients: 35) | Wound infection: 2 Cerebrospinal fluid leak: 1 (3 patients) | 9% |



ACCEPTED MANUSCRIPT

Title

Extent of resection and long-term survival of pineal region tumors in Helsinki Neurosurgery

Abbreviations and Acronyms

CMR, complete microsurgical resection; CSF, cerebrospinal fluid; HN, Helsinki Neurosurgery; GCT, germ cell tumors; mRS, modified Rankin scale; OIH, occipital interhemispheric approach; PPT, pineal parenchymal tumors; PPTID, pineal parenchymal tumor of intermediate differentiation; SCIT, supracerebellar infratentorial paramedian approach; STR, subtotal resection