

Department of Oral and Maxillofacial Diseases
&
Doctoral Programme in Oral Sciences
University of Helsinki
Helsinki, Finland

**MOLAR-INCISOR HYPOMINERALIZATION:
OBSERVATIONS FROM GROUPS OF FINNISH
CHILDREN AND A TREATMENT PRACTICE
SURVEY AMONG FINNISH DENTISTS**

Emma Wuollet

DOCTORAL DISSERTATION

To be presented, with the permission of the Faculty of Medicine of the University of Helsinki, for public examination in lecture hall 1, Metsätalo (Unioninkatu 40), University of Helsinki, on August 31st, 2020 at 12 noon.

Helsinki 2020

SUPERVISORS

Docent Janna Waltimo-Sirén, DDS, PhD
Department of Oral and Maxillofacial Diseases, University of Helsinki,
Helsinki, Finland

Professor emerita Satu Alaluusua, DDS, PhD
Department of Oral and Maxillofacial Diseases, University of Helsinki,
Helsinki, Finland

REVIEWERS

Professor emerita Vuokko Anttonen, DDS, PhD
Department of Cariology, Endodontology and Pediatric Dentistry,
University of Oulu, Oulu, Finland

Professor emeritus Hannu Hausen, DDS, PhD
Research Unit of Oral Health Sciences,
University of Oulu, Oulu, Finland

OPPONENT

Professor Jan Kühnisch, DDS, PhD
Department of Conservative Dentistry and Periodontology,
Ludwig Maximilians University of Munich, Munich, Germany

The Faculty of Medicine uses the Urkund system (plagiarism recognition) to
examine all doctoral dissertations.

ISBN 978-951-51-6373-8 (paperback)
ISBN 978-951-51-6374-5 (PDF)

Unigrafia Oy
Helsinki 2020

“The more you know, the more you know you don't know.”

Aristotle

ABSTRACT

Developmental defects of enamel (DDE) include disorders that vary in appearance, causes and effects. Enamel development has long been studied and its structure is well understood. However, many aspects related to the onset of enamel defects remain unsolved. In particular, enamel hypomineralization of the first permanent molars (FPMs), called Molar Incisor Hypomineralization (MIH), has attracted much interest among researchers of pediatric dentistry. In hypomineralized enamel, the mineral content is reduced. Clinical appearance varies from small, opaque defects in enamel to extensive enamel breakdown. Consequently, depending on the severity of the defect, the patient may be totally unaware of it or suffer from extreme sensitivity and rapid caries development. The treatment of hypomineralized teeth may be challenging. Many aspects have to be taken into account, such as patient age, cooperation, occlusion, available resources and severity and symptoms of the lesion.

This doctoral thesis investigated the background and clinical effects of MIH in a group of Finnish children, as well as Finnish dentists' treatment practices concerning symptomatic, severely hypomineralized FPMs. The Study I population was a convenience sample of 818 children aged 7–13 years from different regions of Finland. Their teeth were examined for MIH using the criteria in line with those of the European Academy of Paediatric Dentistry (EAPD). The possible associations with factors related to the family's socio-economic status and the child's living environment were assessed using the parent-filled questionnaire. Analyses did not show any significant association between MIH and the studied factors. However, the prevalence of the disorder varied regionally, and the prevalence difference was greatest between Jalasjärvi (8.0%) and Lappeenranta (25.2%).

Study II investigated the possible association between MIH and childhood illnesses and antibiotics. Patient records of 287 children from two locations, Lammi and Jalasjärvi, were obtained from the local health centers. Occurrence of illnesses and exposure to antibiotics during the child's first three years of life were investigated and the data was combined with the information of the dental examination. The children who were diagnosed with acute otitis media (AOM) and the children who were prescribed penicillin, amoxicillin, or macrolide antibiotics had increased risk for hypomineralization in FPMs and permanent incisors compared to the children without such illness or medication history.

In a subset of the patients (Study III) whose caries experience had also been recorded (n = 636), MIH was found to be associated with the occurrence of

caries in FPMs (DMFT > 0) as well as with the number of decayed or filled FPMs. MIH was a greater risk factor for caries than low socio-economic status. However, among MIH patients, the FPMs with hypomineralization defects were not more likely restored or decayed than their FPMs without clinically visible hypomineralization.

Study IV, which is part of a collaborative Scandinavian study, explored the treatment practices of Finnish dentists by using an electronic questionnaire which was sent to the members of the Finnish Dental Society Apollonia (N = 3,840). Respondents were asked what treatment they would choose for a 9-year-old patient suffering from symptomatic, severe hypomineralization in the first permanent molar. The most common choice among the 765 respondents was tooth restoration with composite resin (45.0%). Pediatric dentists, on the other hand, preferred stainless-steel crowns. In addition, treatment practices varied from one area to another, and in the Helsinki-Uusimaa area it was more common than in other areas to refer an MIH patient forward.

In summary, the prevalence of MIH seems to vary between regions for a reason that remains unknown. None of the studied background factors were significantly associated with MIH. This thesis suggests a potential harmful effect of childhood illness or antibiotics on enamel development. This finding is waiting to be confirmed with further, prospective studies. In addition, MIH is a significant caries risk factor, especially in a low-caries population. However, unsolved issues related to the development and diagnosis of MIH need to be addressed in order to clarify the etiology and to prevent development of the disorder.

TIIVISTELMÄ

Hammaskiilteen kehityshäiriöt ovat ulkoasultaan, syiltään ja vaikutuksiltaan vaihteleva kokonaisuus. Vaikka kiilteen kehitystä on tutkittu jo pitkään ja sen rakenne on jo hyvin selvillä, monet kiillehäiriöiden syntyyn liittyvät asiat ovat vielä arvailujen varassa. Erityisesti ensimmäisten pysyvien poskihampaiden kiilteen hypomineralisaatio, Molaari-Inkisiivi Hypomineralisaatio (MIH), on herättänyt paljon kiinnostusta lasten hammashoidon parissa työskentelevien keskuudessa. Hypomineralisaatiohäiriöisen hampaan kiilteen mineraalipitoisuus on paikoin alentunut. Kliinisesti hypomineralisaatiohäiriö vaihtelee pienistä kiilteen värimuutoksista laaja-alaisiin vaurioihin, jotka johtavat kiilteen rikkoutumiseen. Vastaavasti vaurion vakavuudesta riippuen potilas voi olla itse tietämätön häiriöstä tai kärsiä äärimmäisestä hampaiden tuntoherkkyydestä ja nopeasta karioitumisesta. Hypomineralisaatiohampaiden hoito voi olla haastavaa. Monet näkökohdat on otettava huomioon, kuten potilaan ikä, yhteistyökyky, purenta, käytettävissä olevat resurssit sekä vaurion vakavuus ja oireet.

Tämä väitöstutkimus selvitti Molaari-Inkisiivi Hypomineralisaation yleisyyttä, taustatekijöitä ja kliinisiä vaikutuksia suomalaisessa lapsiaineistossa, sekä hoitokäytäntöjä suomalaisten hammaslääkärien keskuudessa. Osatyö I koostui 818:n 7–13-vuotiaan lapsen mukavuusotoksesta eri puolilta Suomea. Heidän hampaansa tutkittiin MIH:n varalta käyttäen EAPD:n (European Academy of Paediatric Dentistry) kanssa yhteensopivia kriteerejä. Vanhempien täyttämän kyselylomakkeen avulla pyrittiin selvittämään mahdollisia yhteyksiä MIH:n ja perheen sosioekonomisen aseman sekä lapsen elinympäristöön liittyvien tekijöiden välillä. Analyysissä ei tullut esiin tilastollisesti merkittäviä yhteyksiä MIH:n ja tutkittujen tekijöiden välillä. Kuitenkin huomattiin, että häiriön yleisyys vaihteli paikkakunnittain, ja ero oli suurin Jalasjärven ja Lappeenrannan välillä, 8,0 % - 25,2 %.

Osatyö II selvitti MIH:n yhteyttä lapsuusiän sairauksiin tai lääkityksiin. Kahden paikkakunnan, Lammin ja Jalasjärven, terveystieteiden keskuksista hankittiin tutkimukseen osallistuneiden 287:n lapsen hoitokertomukset. Hoitokertomuksista kerättiin tiedot ensimmäisen kolmen ikävuoden sairauksista ja lääkityksistä, ja ne yhdistettiin hammastutkimusaineistoon. Lapsilla, joilla oli diagnosoitu akuutti välikorvantulehdus tai joille oli määrätty penisilliini-, amoksisilliini- ja makrolidi-antibiootteja, oli suurentunut riski ensimmäisten pysyvien molaarien ja inkisiivien hypomineralisaatioon.

Osajoukolla, joiden hampaiden reikiintyminen oli myös tutkittu (n = 636), todettiin MIH:n olevan yhteydessä poskihampaiden kariesleesioiden esiintymiseen (DMFT > 0) ja karioituneiden tai paikattujen poskihampaiden

lukumäärään (Osatyö III). MIH oli suurempi kariksen riskitekijä kuin alhainen sosioekonominen status. Kuitenkaan MIH-potilaiden ensimmäiset pysyvät poskihampaat, joissa oli kiilteen hypomineralisaatiota, eivät olleet suuremmalla todennäköisyydellä paikattuja tai karioituneita kuin heidän ensimmäiset pysyvät poskihampaansa ilman hypomineralisaatiota.

Osatyö IV, osa pohjoismaista yhteistutkimusta, selvitti kyselyllä suomalaisten hammaslääkärrien hoitokäytäntöjä. Sähköinen kyselylomake lähetettiin Suomalaisen hammaslääkäriseura Apollonian jäsenille (N = 3840). Kyselyssä pyydettiin kertomaan, minkä hoitovaihtoehdon hammaslääkäri valitsisi 9-vuotiaalle esimerkkipotilaalle, joka kärsii oireilevasta, vakavasta hypomineralisaatiosta ensimmäisessä pysyvässä poskihampaassa. Yleisin valinta 765:n vastaajan keskuudessa oli yhdistelmämuovipaikkaus (45,0 %). Lasten hammashoidon erikoishammaslääkärit kuitenkin suosivat ruostumattomia teräskruunuja. Lisäksi hoitokäytännöt vaihtelivat alueittain, ja Helsinki-Uusimaan alueella oli muita alueita yleisempää lähettää MIH-potilas eteenpäin sen sijaan, että hoitaisi itse.

Yhteenvedona voidaan todeta, että MIH-prevalenssi vaihtelee alueittain tuntemattomaksi jääneestä syystä. Mikään tutkituista taustatekijöistä ei ollut tilastollisesti merkitsevästi yhteydessä häiriöön. Väitöstutkimus antaa viitteitä sairauksien tai antibioottien epäsuotuisasta vaikutuksesta kiilteen kehitykseen. Tämä löydös vaatii vahvistukseen lisää prospektiivisiä tutkimuksia. Sen lisäksi voidaan todeta, että MIH on merkittävä kariksen riskitekijä erityisesti väestössä, jossa kariesta esiintyy vain vähän. MIH-muutosten syntyprosessiin ja diagnostiikkaan liittyvien kysymysten selvittäminen on tärkeää, jotta päästäisiin selville muutosten etiologiasta ja vaikuttamaan ennaltaehkäisevästi niiden kehittymiseen.

CONTENTS

Abstract.....	4
Tiivistelmä	6
List of original publications.....	11
Abbreviations.....	12
1 Introduction.....	13
2 Review of the literature	15
2.1 Tooth development	15
2.1.1 General features	15
2.1.2 Amelogenesis.....	16
2.1.3 The structure of mature enamel	19
2.1.4 The timing of tooth formation	20
2.2 Developmental defects of enamel.....	21
2.2.1 Prevalence of developmental defects of enamel.....	22
2.2.2 Etiology of developmental defects of enamel	25
2.3 Molar-Incisor Hypomineralization	29
2.3.1 Definition	29
2.3.2 Prevalence	33
2.3.3 Properties of hypomineralized enamel.....	33
2.3.4 The onset of MIH	35
2.3.5 Etiology.....	37
2.3.6 Clinical implications	41
2.3.7 Treatment.....	43
3 Aims of the study	48

4	Study subjects, materials, and methods.....	49
4.1	Study subjects	49
4.1.1	Study population in the clinical studies (I, II and III)	49
4.1.2	Dentists participating in the survey (Study IV).....	51
4.2	Materials and Methods	52
4.2.1	Dental examination (Studies I, II, and III)	52
4.2.2	Questionnaire for parents (Studies I and III).....	53
4.2.3	Medical records (Study II).....	54
4.2.4	Questionnaire for dentists (Study IV).....	55
4.2.5	Statistical methods.....	56
4.2.6	Ethical considerations.....	57
5	Results	59
5.1	Background factors of MIH (Study I).....	59
5.2	The association between MIH and childhood illnesses and medications (Study II)	61
5.2.1	Childhood illnesses	62
5.2.2	Medications.....	63
5.3	The association between MIH and dental caries, SES as a confounding factor (Study III)	63
5.4	Questionnaire survey for dentists (Study IV).....	66
6	Discussion	69
6.1	Background factors of MIH	69
6.2	The association between MIH and childhood illnesses and antibiotics.....	71
6.3	The association between MIH and dental caries	71
6.4	Dentists' perceptions on the treatment of hypomineralized molar	72
6.5	Limitations of the study material	74

6.6	Future perspectives.....	75
7	Conclusions.....	77
	Acknowledgements.....	78
	References	80

LIST OF ORIGINAL PUBLICATIONS

This thesis is based on the following publications:

I Wuollet E, Laisi S, Salmela E, Ess A, Alaluusua S. Background factors of molar-incisor hypomineralization in a group of Finnish children. *Acta Odontol Scand* 2014, 72: 963-9; doi: 10.3109/00016357.2014.931459

II Wuollet E, Laisi S, Salmela E, Ess A, Alaluusua S. Molar-incisor hypomineralization and the association with childhood illnesses and antibiotics in a group of Finnish children. *Acta Odontol Scand* 2016, 74: 416-22; doi: 10.3109/00016357.2016.1172342

III Wuollet E, Laisi S, Alaluusua S, Waltimo-Sirén J. The association between Molar-Incisor Hypomineralization and dental caries with socioeconomic status as an explanatory variable in a group of Finnish children. *Int J Environ Res Public Health* 2018, 15: 1324; doi: 10.3390/ijerph15071324

IV Wuollet E, Tseveenjav B, Furuholm J, Waltimo-Sirén J, Valen H, Mulic A, Ansteinsson V, Uhlen MM. Restorative material choices for extensive carious lesions and hypomineralization defects in children: a questionnaire survey among Finnish dentists. *Eur J Paed Dent* 2020, 21: 29-34, DOI 10.23804/EJPD.2020.21.01.06

The publications are referred to in the text by their roman numerals.

The original publications are reproduced with the permission of the copyright owners or under the terms of the Creative Commons Attribution (CC BY) license (<http://creativecommons.org/licenses/by/4.0/>).

ABBREVIATIONS

AI	Amelogenesis imperfecta
AOM	Acute otitis media
CPP-ACP	Casein phosphopeptide-amorphous calcium phosphate
DDE	Developmental defects of enamel
DMH	Deciduous molar hypomineralization
EAPD	European Academy of Paediatric Dentistry
EDJ	Enamel-dentin junction
FDI	World Dental Federation
FPM	First permanent molar
GIC	Glass ionomer cement
KLK4	Kallikrein-related peptidase 4
MIH	Molar-Incisor Hypomineralization
MIH2	At least one first permanent molar and at least one permanent incisor affected by demarcated hypomineralization
MMP20	Matrix metalloproteinase 20, enamelysin
PEB	Post-eruptive breakdown
RC	Resin composite
RCT	Randomized controlled trial
SEM	Scanning electron microscopy
SES	Socio-economic status
SL	Sakari Laisi
SSC	Stainless-steel crown
VAS	Visual Analog Scale

1 INTRODUCTION

Dental enamel has a unique structure, designed to meet its challenging task of grinding food for digestion under high pH variations and mechanical forces. Healthy enamel can withstand these requirements, but in case of structural weaknesses, an individual may encounter problems related to oral health and functions.

Tooth development follows a complex cascade of spatially and temporally regulated events. Cells responsible for enamel formation, ameloblasts, are ectoderm-derived, highly specialized cells with changing morphology and function (Nanci 2018). Teeth develop inside the growing jaw bones, and at the time of their eruption into the oral cavity, enamel formation is completed and ameloblasts die. Completely formed enamel is acellular and consists of approximately 95% mineral and 5% organic material and water by weight (Simmer & Fincham 1995). Thus, dysfunction of ameloblasts can cause permanent structural changes in the enamel which become visible after the tooth erupts. The clinically visible defects can be divided into three main types (FDI Working Group 1992). In hypoplastic lesions, enamel is thinner than normally developed enamel, and in hypomineralized lesions, the mineral content is reduced leading to altered enamel color. Further, the border of the hypomineralized lesion may be either well-defined i.e. demarcated or diffuse.

Developmental defects of enamel (DDE) may occur in combination with other dental malformations or as a single phenomenon in otherwise normally developed dentition. In addition, enamel defects are observed in numerous different syndromes. Genetic conditions that affect only enamel formation, form the heterogeneous group of amelogenesis imperfecta (AI) which affects all teeth (Wright et al. 2015). Dental fluorosis, which occurs as discoloration and pits in the enamel, usually in all teeth, was identified in the early 20th century in areas with high fluoride content in drinking water (Dean 1934). Discoloration of enamel was also observed after tetracycline antibiotics were prescribed to children with developing teeth (Davies et al. 1962, Sanchez et al. 2004). In addition, local factors, such as trauma or infection of a primary tooth, may cause alterations in the enamel of the underlying permanent tooth (Altun et al. 2009).

In the late seventies, Swedish clinicians suspected that the number of children with severe enamel hypomineralization in permanent incisors and first permanent molars (FPMs) had increased. They conducted an epidemiological study (Koch et al. 1987), and found that, of children born in 1970, 15.4% were affected by such defects, compared to 3.6–7.3% of the children born in the preceding and following years (1966, 1969, 1971, 1972 and 1974). The prevalence of “idiopathic enamel hypomineralization“ was not affected by

water fluoride level (Koch 2003). In Helsinki, Finland, the prevalence of “non-fluoride hypomineralization“ in FPMs was 19.3% among children born in 1983 - 1989 (Leppäniemi et al. 2001). About half of the affected children had severe or moderate defects meaning that hypomineralization had led to enamel breakdown after eruption. In 2003, the name Molar-Incisor Hypomineralization (MIH) became established and diagnostic criteria for epidemiological studies were determined (Weerheijm et al. 2003). According to the criteria of the European Academy of Paediatric Dentistry (EAPD), MIH affects 1–4 of the FPMs and frequently also permanent incisors, which develop simultaneously with FPMs. According to the criteria, hypomineralized areas have well-defined, i.e. demarcated, boundaries between the defected and healthy enamel. The increased amount of proteins in defective enamel results in a less translucent, opaque, appearance. Hence, the defects are also called opacities. In mildly affected areas, enamel appears white, but in more severe hypomineralization, the color varies from yellow to brown (Weerheijm et al. 2003, Farah et al. 2010a). The more severe lesions carry a greater risk of enamel breakdown after eruption (Da Costa-Silva et al. 2011; Cabral et al. 2019). The size of the opacities vary between and within individuals and teeth. The global prevalence of MIH was recently estimated to be 12.9% (Schwendicke et al. 2019).

According to the existing literature, children with MIH receive more treatments than their peers (Jälevik & Klingberg 2012), and the treatment outcomes of their FPMs are inferior to those without MIH (Kotsanos et al. 2005). Children with MIH report dental hypersensitivity during daily activities (Petrou et al. 2015). The altered mineral and protein composition create challenges for restoration with conventional techniques (Sönmez & Saat 2017). Tooth extraction is an appropriate treatment in the most severe cases, but it requires taking several tooth and patient-related factors into account (Elhennawy & Schwendicke 2016).

Despite the intense research, many issues related to MIH remain unsolved. The structural properties of hypomineralized enamel differ from unaffected enamel (Elhennawy et al. 2017b) but the onset and the mechanism of the hypomineralization is not clear. While genetic predisposition to MIH is probable, environmental factors are suspected to increase the risk of MIH (Teixeira et al. 2018). This dissertation addresses factors associated with the etiology of MIH, as well as its clinical consequences and treatment.

2 REVIEW OF THE LITERATURE

2.1 TOOTH DEVELOPMENT

2.1.1 GENERAL FEATURES

Tooth development in humans begins already at developmental week six, when the oral epithelium in the embryo's primary oral cavity thickens to form the dental lamina. The epithelium soon proliferates and grows into the underlying ectomesenchyme, forming dental placodes at the site where future teeth will develop (Figure 1). The current understanding is that each tooth family has its own respective placode from which the teeth sequentially originate (Jussila & Thesleff 2012). Development is guided by inductive tissue interactions. The formation of the individual tooth begins by the budding of the epithelium, which becomes surrounded by the condensed ectomesenchymal cells derived from the neural crest (Figure 1). The bud continues morphogenesis and develops into a cap-like structure. Before that transition, a signaling center called primary enamel knot forms, to guide the formation of tooth shape (Jernvall et al. 1994).

Epithelial cells form the enamel organ, which will contribute to the development of enamel. It is divided into inner and outer enamel epithelium, and the cells of the inner enamel epithelium will become enamel-forming cells, ameloblasts. The outer enamel epithelium, together with stellate reticulum and stratum intermedium cells of enamel organ, support the function of ameloblasts. Mesenchymal cells form the dental papilla, which eventually develops into dentin-forming cells (odontoblasts) and the cells of tooth pulp (fibroblasts and undifferentiated mesenchymal cells). The peripheral portion of the mesenchyme, which surrounds the dental papilla and the epithelium of the tooth, forms a tooth follicle, which will later give rise to periodontal tissue that attaches the tooth to alveolar bone (Jussila & Thesleff 2012).

The enamel organ continues to develop, and during the next step, called the bell stage, secondary enamel knots are formed in molars at the sites of the future tooth cusp tips (Jussila & Thesleff 2012). The surrounding epithelium and the underlying mesenchyme proliferate, and the cusp formation begins. Odontoblasts and ameloblasts begin their final differentiation and secretion of the matrix at the bell stage (Figure 1). Epithelial-mesenchymal interactions, mediated by several different signal molecules, guide the differentiation of these cells (Jussila & Thesleff 2012). It has been proposed that vitamin D is also involved in these interactions (Mesbah et al. 2002).

After crown development, the inner and outer enamel epithelium initiate the root development by forming the Hertwig's epithelial root sheath (HERS) (Jussila & Thesleff, 2012). As the root increases in length, the tooth begins to erupt. During eruption, alveolar bone surrounds the teeth and the eruption depends on the strictly regulated bone re-formation (Thesleff & Nieminen 2005). The bone is removed between the crown and the oral cavity, and new bone is formed at the base of the roots. When the tooth erupts to oral cavity, the surface epithelium disappears apoptically. First teeth erupting are the primary central incisors in the mandible.

Based on animal models, it is thought that permanent teeth start to develop from the lingual side of each deciduous tooth, as an extension of the dental lamina (Jussila & Thesleff 2012). Permanent molars with no precursor primary teeth are thought to develop sequentially, originating from their own placode, as the dental epithelium extends posteriorly while jaws grow. The development of human dentition continues to the early adulthood when the third permanent molars erupt.

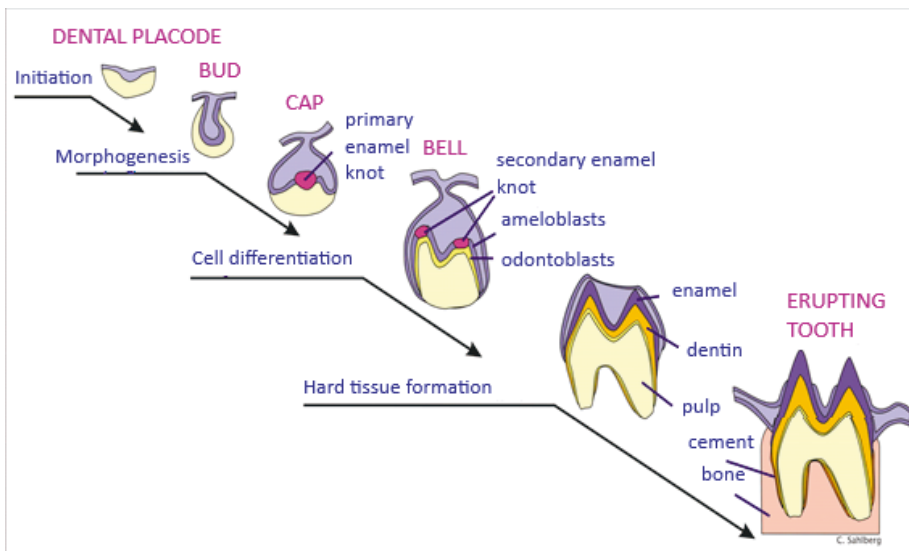


Figure 1. A schematic drawing of tooth developmental stages. With the courtesy of C. Sahlberg.

2.1.2 AMELOGENESIS

Amelogenesis means the formation of enamel. Enamel formation begins at the tips of the cusps and progresses cervically towards the root. Amelogenesis begins when a small layer of predentin is produced by odontoblasts. During

amelogenesis, ameloblasts undergo several morphological and functional changes depending on the phase of the enamel formation. These changes can be classified into presecretory, secretory, transition and maturation stages (Robinson et al. 1995). Presecretory stage ameloblasts have just left the mitosis and differentiate into secretory ameloblasts. The cells become elongated and the nucleus and mitochondria polarize to the proximal end of the cell. Typical Tomes' protrusions are formed on the distal end of the cell, where secretion of the enamel matrix proteins through the cell membrane occurs (Nanci 2018). The secretory stage ameloblasts' main function is to secrete the enamel matrix proteins and enzymes. The mineralization of the enamel matrix starts immediately after the secretion of the matrix proteins. Ions of supersaturated solution crystallize and form hydroxyapatite (Simmer & Fincham 1995). At the distal part of the Tomes' process, crystals form into rods perpendicular to the cell wall. At the proximal part of the Tomes' process, near the intercellular junctions, crystals do not arrange into rods, but are irregularly organized forming the interrod enamel. At the beginning, the mineral content of the enamel is about 30% by volume, the remainder being made up of water and organic matter (Robinson et al. 1995). Crystals grow in length as the ameloblasts secrete more proteins and retreat from the enamel-dentin junction (EDJ), and the enamel layer thickens. Only later, during the maturation stage when the matrix proteins disappear, do crystals grow rapidly in width.

When the enamel matrix starts to form, ameloblasts lose their connection to blood vessels. Vascularization is achieved by blood vessels of outer enamel epithelium. This is possible when the stellate reticulum, which originally resides between inner and outer enamel epithelium, narrows (Nanci 2018).

While the exact function of enamel matrix proteins is unknown, they are suggested to control crystal formation, so that minerals are organized into a unique, hard and abrasion-resistant structure. During the secretory stage, crystal elongation is catalyzed while mineral accumulation on the sides of the crystals is inhibited (Nanci 2018). Proteins may also maintain the optimal pH for mineralization (Robinson et al. 1995). Many of those proteins are unique to the enamel. Amelogenins are a heterogeneous group of proteins, which make up 90% of the matrix proteins (Robinson et al. 1995). Amelogenins are thought to inhibit the lateral growth of hydroxyapatite crystals (Simmer & Fincham 1995), although some crystal thickening is seen even with the presence of remnant proteins, at least in mice (Simmer et al. 2009). Enamelin and ameloblastin are the non-amelogenin matrix proteins. Ameloblastin is mainly seen in the surface of secretory stage enamel and is rapidly degraded. Enamelin is the least prevalent of the enamel proteins. Intact protein is only seen in the newly formed enamel near the ameloblasts (Simmer & Hu 2002). Smaller fragments reside inside the enamel, bind to minerals and inhibit

crystal growth, which is believed to control mineralization and enhance elongation of crystals (Nanci 2018).

In addition, the matrix contains numerous proteolytic and phosphorolytic enzymes. Enamelysin (MMP20) and kallikrein 4 (KLK4) are the main matrix-degrading proteases (Nanci 2018). MMP20 is a calcium-dependent protease, which is seen in enamel during the secretory stage. MMP20-null mice display an altered rod pattern (Caterina et al. 2002) and the enamel is softer compared to controls (Bartlett et al. 2004). It seems that although MMP20 is expressed during the secretory stage, its functions extend to the maturation stage as well (Bartlett et al. 2004; Bartlett et al. 2011). KLK4 is believed to be secreted into enamel of its full thickness, when Tomes' processes of ameloblasts diminish (Nanci 2018). KLK4 degrades remaining amelogenins and non-amelogenins slowly. KLK4-null mice developed an enamel of full thickness with decussating enamel rods, but amelogenins were inadequately removed and the crystals were separated from each other (Simmer et al. 2009). KLK4 expression seems to be dependent on TGF β 1 (TGF β ; transforming growth factor beta) signaling, since ameloblast-specific TGF β receptor II knockout mice expressed reduced KLK4 mRNA levels and a decreased mineral content in enamel (Cho et al. 2013).

At the transition stage, when the enamel has reached its final thickness, the ameloblasts stop producing matrix proteins and become mature matrix-degrading cells. The cells become shorter and cuboidal, Tomes' processes disappear and about 25% of the ameloblasts die through apoptosis. (Nanci 2018). The cleavage of matrix proteins that began in the secretion stage accelerates and tissue fluid replaces the removed material (Robinson et al. 1995). During the transition stage, ameloblasts re-establish a basal lamina, which is protected from KLK4 (Nanci 2018).

In the maturation stage, ameloblasts transport calcium and phosphate ions into the enamel and protein and water out of the enamel. The mineral content of the enamel increases rapidly, and the amount of proteins decreases. Crystal width increases so that in mature enamel, crystals are pressed into each other and their hexagonal shape is lost (Nanci 2018). During maturation, ameloblasts alternate the structure of their cell membrane facing the enamel between a smooth and a ruffled morphology. This alternation fluctuates along the crown from the cervical margins to the cusps and results in pH changes in enamel. Apparently, ameloblasts' functional change is rapid and occurs several times a day (Nanci 2018). The cell modulation also involves intercellular junctions and probably facilitate the diffusion of molecules, such as foreign material and plasma proteins, into the enamel tissue.

The mature ameloblasts remain on the surface of the enamel with the other cells of the reduced enamel organ and regulate the final mineralization. When

the tooth erupts, the epithelium disappears, and it is no longer possible to repair the enamel through tissue formation.

2.1.3 THE STRUCTURE OF MATURE ENAMEL

Human enamel contains more than 95% mineral by weight (Simmer & Fincham 1995), which is arranged into crystals that are chemically calcium hydroxyapatite $[Ca_{10}(PO_4)_6(OH)_2]$ but differ in shape, size and organization from elsewhere formed calcium hydroxyapatite (Simmer & Hu 2002). Carbonate, fluoride, sodium and magnesium ions are also incorporated in the enamel apatite lattice (Simmer & Fincham 1995; Robinson et al. 1995). The rest of the enamel is composed of water (4%) and organic matrix residuals of different enamel proteins (1% by weight).

In mature enamel, crystals are grouped into rods, whose directions correspond to the route of ameloblasts from the EDJ to the enamel surface. Ribbon-like crystals run along the longitudinal axes of the rods. The area between the rods, where crystals are arranged in a different orientation, is called interrod enamel. When enamel matures and the organic matrix is replaced by minerals, the rods become partially separated from the interrod enamel by a thin, mineral-free zone called the enamel sheet, where matrix proteins, like ameloblastin cleavage products, accumulate (Simmer & Hu 2002). However, the rod sheet is discontinuous in the area where rod crystals enter interrod enamel. The outermost enamel does not have rod orientation, which makes it continuous with interrod and the first-formed enamel at the EDJ (Nanci 2018).

In ground sections of calcified teeth, a series of lines can be identified that follow the enamel formation. The short-term enamel cross striations are thought to be due to the circadian rhythm in the function of secretory ameloblasts (Antoine et al. 2009). However, it has also been suggested that striations are longitudinally cut rods (Nanci 2018). The long-term striations, striae of Retzius, have been shown to represent a circaseptan rhythm in enamel production by ameloblasts, with 6–11 cross striations between the striae of Retzius (FitzGerald 1998). Another explanation is that the striae of Retzius separate cohorts of ameloblasts recruited for enamel production when the crown grows, and an increasing number of cells are needed for amelogenesis (Nanci 2018). In some specimens, an enlarged stria called neonatal line can be detected and it supposedly forms at the time of birth. Striae of Retzius also manifest as grooves on enamel surface, i.e. perikymata (Nanci 2018).

2.1.4 THE TIMING OF TOOTH FORMATION

Both radiographic and histological methods have been used to assess tooth formation times. In a living individual, a developing tooth can be first detected when a bone crypt is visible in a radiograph. The dental germ inside the crypt is not radiologically visible because the mineralization of hard tissue matrices has not initiated, or the newly produced enamel and dentin has not yet been mineralized to the extent visible in radiographs. Once the mineralization has reached a certain extent, the developmental stage of the tooth can be followed with radiological methods. Several indices are available for orthodontic treatment planning and for forensic age assessment. Using radiographic methods, marked variations in tooth formation times between populations have been detected (Reid & Dean 2006).

Histological methods can be applied to extracted or naturally exfoliated teeth or postmortal specimens and they provide more accurate analysis of the developmental stages. However, limitations also apply to histological methods: the methods are time-consuming, and specimens are prone to artefacts of preparatory methods. Usually histological studies contain less samples than studies using radiographs. Histological studies calculate the enamel formation time based on incremental lines and enamel cross striations. In this manner, Reid & Dean (2006) estimated enamel formation of FPMs to take up to 3.4 years with only a few months' variation between populations. The chronology of the developmental stages for different teeth is shown in Table 1.

Table 1. *The chronology of the tooth developmental stages based on histology. Data adopted from Welbury et al. 2012.*

Stage of development	Primary maxillary teeth					Time		
	i1	i2	c	m1	m2			
Hard tissue formation begins	13-16	14.7-16.5	15-18	14.5-17	16-23.5	Weeks after ovulation		
Crown formation complete	1.5	2.5	9	6	11	Months after birth		
Stage of development	Primary mandibular teeth					Time		
	i1	i2	c	m1	m2			
Hard tissue formation begins	13-16	14.7-16.5	16-18	14.5-17	17-19.5	Weeks after ovulation		
Crown formation complete	2.5	3	8-9	5-6	8-11	Months after birth		
i1: central incisor, i2: lateral incisor, c: canine, m1: first molar, m2: second molar								
Stage of development	Permanent maxillary teeth							
	I ₁	I ₂	C	P ₁	P ₂	M ₁	M ₂	M ₃
Hard tissue formation begins	3-4mo	10-12mo	4-5mo	18-24mo	24-30mo	32-36wk	30-36mo	7-9yr
Crown formation complete	3.3-4.1yr	4.4-4.9yr	4.5-5.8yr	6.3-7.0yr	6.6-7.2yr	2.1-3.5yr	6.9-7.4yr	12.8-13.2yr
Stage of development	Permanent mandibular teeth							
	I ₁	I ₂	C	P ₁	P ₂	M ₁	M ₂	M ₃
Hard tissue formation begins	3-4mo	3-4mo	4-5mo	18-24mo	24-30mo	32-36wk	30-36mo	8-10yr
Crown formation complete	3.4-5.4yr	3.1-5.9yr	4.0-4.7yr	5.0-6.0yr	6.1-7.1yr	2.1-3.6yr	6.2-7.4yr	12.0-13.7yr
I ₁ : central incisor, I ₂ : lateral incisor, C: canine, P ₁ : first premolar, P ₂ : second premolar, M ₁ : first molar, M ₂ : second molar, M ₃ : third molar, wk: gestational week, mo: months after birth, yr: years after birth (with decimal).								

2.2 DEVELOPMENTAL DEFECTS OF ENAMEL

For a long time, researchers have been interested in developmental defects of enamel. In the World's Columbian Dental Congress (Chicago, Ill.) 1893, one of the special topics was "Are white and yellow spots upon the enamel of the permanent teeth caused by alveolar abscess the result of death of the pulp in

the deciduous teeth, or are they sequelae of zymotic fevers?” (Committee on essays, 1892). Early in the 20th century, water fluoridation was found to increase the prevalence of enamel defects. In 1934, Dean (1934) assessed the first criterion for “Mottled enamel diagnosis”, to measure defects associated with excess fluoride. This was later modified by Thylstrup & Fejerskov (1978). Further, a more sensitive index to record the prevalence of fluorosis, the Tooth Surface Index of Fluorosis was developed in 1984 (Horowitz et al. 1984). However, these indices assume that the enamel changes are due to fluoride, even though “enamel mottling” has also been found in areas with low fluoride content in drinking water (Goward 1976). A group of descriptive indices that classify enamel defects by clinical appearance were simultaneously developed (Al-Alousi et al. 1975; Suckling et al. 1976; Murray & Shaw 1979). Because of the several number of the different indices, a Working Group of the FDI Commission on Oral Health, Research and Epidemiology recommended the use of the Developmental Defects of Enamel (DDE) Index (1982). In this index, enamel defects were categorized as opacities, hypoplasia, and discoloration. The term opacity refers to a hypomineralized area with a color change but normal thickness which is surrounded by healthy enamel. In hypoplasia, enamel thickness is locally reduced in the forms of pits or grooves, or enamel is partially or completely absent. Also, the number and demarcation (demarcated or diffuse borders) of defects as well as the location of defects are recorded. However, it was soon noticed that the DDE index was time-consuming to use, and categorization required modification (Clarkson & O’Mullane 1989). A new, modified index was presented in 1992 (FDI Working Group 1992). Based on the results from the studies that had used the previous index, classification of defects was done as follows: demarcated opacity, diffuse opacity, hypoplasia, other defects, and different combinations of those. The size limit of a single defect was set to 1 mm or more in diameter. For screening surveys, it was instructed to examine only the index teeth rather than the whole dentition: the buccal surfaces of the maxillary first premolars, canines and incisors and mandibular first molars (FDI Working Group 1992).

2.2.1 PREVALENCE OF DEVELOPMENTAL DEFECTS OF ENAMEL

Because the classifications of DDE have markedly changed during the last century, comparison between the prevalence rates is difficult. The review of the original DDE index found that the percentage of children affected by DDE ranged from 17% to 99% (FDI Working Group 1992). When the modified DDE index has been used, similar prevalence rates have been reported, from 7.6% (Opydo-Szymaczeka et al. 2018) to 92.1% (Wong et al. 2016) (Table 2). Prevalence of children with demarcated opacities has varied between 2.7% (Opydo-Szymaczeka et al. 2018) and 53.4% (Ellwood & O’Mullane 1994). Hypoplasias have been the least frequent DDE type in all studies, ranging from 0.8% (Ravindran & Saji 2016) to 16.7% (Seow et al. 2011). Diffuse opacities

have shown the greatest variance on prevalence which has varied from 2% (Ravindran & Saji 2016) to 91.7% (Wong et al. 2016).

Table 2. DDE prevalence in studies that have investigated children with permanent teeth (written in English) using the modified DDE index (FDI Working Group 1992).

Study	Country	Teeth	N (children)	age (years)	F (mg/L)	Demarcated opacities %	Diffuse opacities %	Hypoplasia %	Combined %	Any defect %
Ellwood & O'Mullane 1994	North Wales	index teeth	2,390	11–12	< 0.1	44.8–53.4	12.1–21.1	6.4–12.5		
Jälevik et al. 2001a	Sweden	incisors and FPMs	516	7–8	< 0.1	25.0	7.5	0.8		33.3
Arrow 2008	Australia	FPMs	511	7.1 (mean)	0.8	15.9	43.6	2.5	9.2	71.2
Seow et al. 2011	Australia	all teeth	354	13.5 (mean)	0.1	20.9	20.1	16.7		57.6
Vargas-Ferreira et al. 2014	Brazil	index teeth	1,210	8–12	0.6–1.0	29.5	35.0	3.7		64.0
Opydo-Szymaczek & Gerreth 2015	Poland	incisors and molars	225 + 245	6–8 and 12–14	0.1–0.4	12.1	10.9	2.8		25.7
Ravindran & Sajji 2016	India	index teeth	2,500	12–15		28.2	2	0.8	3.25	32.0
Wong et al. 2016 (longitudinal follow-up)	Hong Kong	incisors and FPMs	432	a. 12 b. 15	0.5	a. 7.6 b. 7.0	a. 91.7 b. 85.0	a. 1.6 b. 1.2		a. 92.1 b. 85.0
Jälevik et al. 2018	Sweden	all teeth	796	12, 15, 19	< 0.1	18.1	5.3	1.4	8.4	33.2
Opydo-Szymaczeka et al. 2018	Poland	all erupted teeth	a. 2,224 b. 2,230	a. 5–8 b. 11–15	0.3–0.9	a. 2.7 b. 5.4	a. 3.0 b. 4.3	a. 1.9 b. 1.9		a. 7.6 b. 11.6

Index teeth: buccal / labial surfaces of 10 teeth (11–14, 21–24, 36, 46). Combined: combination of different defects. FPM: first permanent molar. F: fluoride level in drinking water.

2.2.2 ETIOLOGY OF DEVELOPMENTAL DEFECTS OF ENAMEL

DDE can be roughly classified into genetic and environmental (acquired) defects, based on suspected etiology (Figure 3). While several factors have been suspected to be associated with DDE, on an individual level, the causal factor usually remains unknown and the etiology is considered multifactorial. Figure 2 illustrates a possible threshold theory for ameloblast disruption and defect formation. This model is analogous with a theory of the mechanisms of different enamel defects, presented by Suga (1989), where the assumption was that ameloblasts are capable of recovery from injury, unless the injury is too severe. The transition stage was thought to be particularly vulnerable to environmental influences (Suga 1989). The factors that have been found to be associated with DDE are discussed in the following sections.

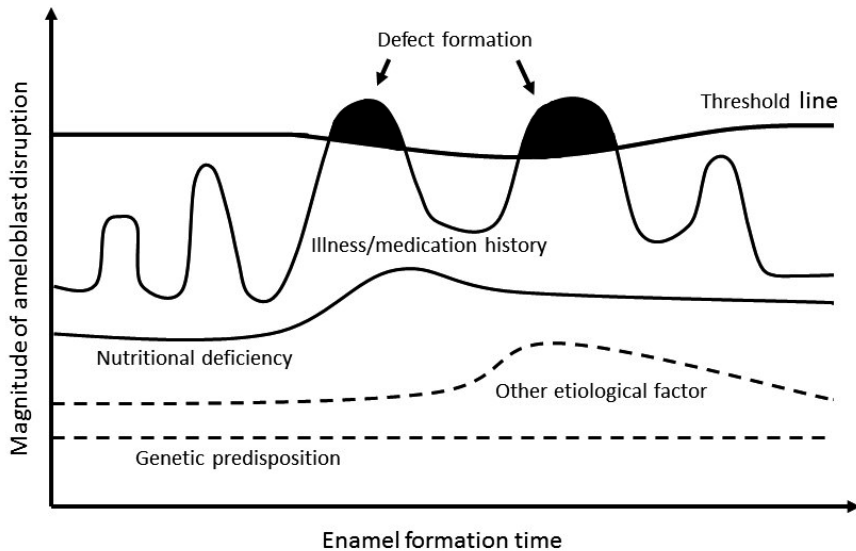


Figure 2. Threshold model for the formation of a developmental enamel defect. Modified from Goodman & Rose (1990).

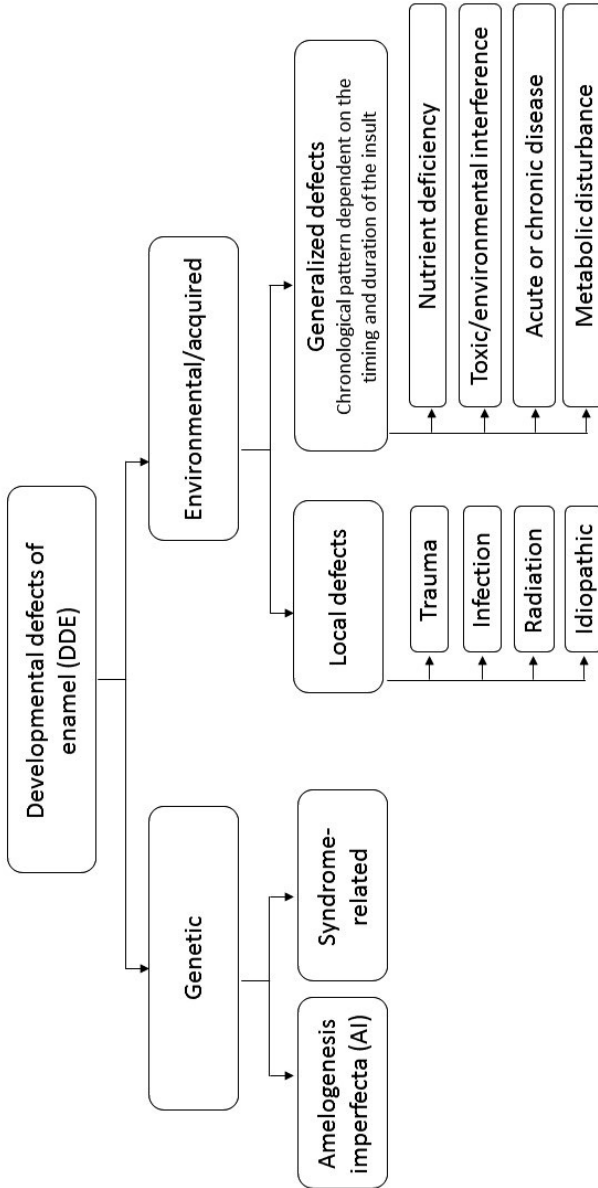


Figure 3: A schematic approach for the classification of developmental defects of enamel.

2.2.2.1 Genetic disorders

Amelogenesis imperfecta (AI) is a rare group of hereditary conditions that cause enamel defects without developmental alterations in other organs. There are at least 20 different genes with known mutations that cause AI (Wright et al. 2015, Kim et al. 2020). For example, mutations in gene coding enamel matrix protein enamelin (ENAM) may cause either autosomal dominant or recessive AI. Mutations in AMELX gene which codes amelogenins cause X-linked AI. Mutations have also been identified for genes coding proteolytic enzymes KLK4 and MMP20. However, similar phenotypes, ranging from hypoplastic to hypomaturation defects of varying severity, are seen in different gene mutations, and the same gene mutation may cause different phenotypes (Prasad et al. 2016).

In addition, there are several other genetic disorders, where enamel defects are only one of the several possible organ changes and symptoms. Examples include junctional epidermolysis bullosa (Wright et al. 1993), tricho-dento-osseus syndrome (Price et al. 1999) and an autoimmune disease called polyendocrinopathy-candidiasis-ectodermal dystrophy (APECED). APECED is particularly prevalent among some historically isolated populations such as Finns (Kisand & Peterson 2015). In 2015, Wright et al. (2015) listed over 70 genes reported to be associated with enamel defects.

2.2.2.2 Environmental factors

Localized defects of enamel in permanent teeth are seen after trauma to the precursor primary tooth (Andreasen & Ravn 1971; Altun et al. 2009). Persistent infection of the primary tooth can also alter the development of the underlying permanent tooth, a phenomenon called Turner tooth after Mr. Turner who first described such a case (Turner 1912).

Systemic cause is suspected when the defects are more generalized, or when the affected permanent tooth does not have a precursor primary tooth (permanent molars). Water fluoridation or naturally high fluoride content in drinking water increases the prevalence of diffuse opacities (Clarkson & O'Mullane 1989; Nunn et al. 1992; Ekanayake & van der Hoek 2002; Wong et al. 2006) and mechanisms by which fluoride interferes with enamel development are widely studied (Robinson 2014). However, it has been questioned whether dental fluorosis is caused solely by fluoride or whether it is accentuated by other factors, such as malnutrition, high altitude, chronic illness or genetic factors (Cutress & Suckling 1990).

Already in 1978, Small & Murray (1978) were concerned about the occurrence of enamel defects in optimal and low fluoride areas and listed an extensive

number of possible etiological factors, based on the literature of that time. In anthropological studies, enamel hypoplasia has been used as a marker of physiological stress (Goodman & Rose 1990). In living Chinese, the Great Chinese Famine increased the prevalence of linear enamel hypoplasia (Zhou & Corruccini 1998). Low birth weight and premature birth are associated with DDE in primary teeth, but there is not enough evidence for such an association in permanent teeth (Jacobsen et al. 2014). Severe chronic childhood diseases, such as liver disease (Ferrazzano et al. 2013; Alanzi et al. 2019) and chronic renal failure (Davidovich et al. 2005) may affect enamel development leading to permanent defects. Congenital syphilis, which is predominantly linked with typical tooth malformations, may also be associated with milder enamel defects, such as hypoplasia (Nissanka-Jayasuriya et al. 2016). DDE is more prevalent in celiac patients than in healthy children, although the association was significant only in children with primary dentition, according to a review and meta-analysis by Souto-Souza et al. (2018). In Saudi-Arabia, malnourished children had a higher prevalence of DDE (Rugg-Gunn et al. 1997; Rugg-Gunn et al. 1998). The role of calcium and phosphate homeostasis regulators, such as vitamin D, has been studied, although mainly in animal models, and suggest hypocalcemia to be associated with mineralization defects in all tooth hard tissues (Nikiforuk & Fraser 1979; Foster et al. 2014).

The effect of environmental toxicants on developing teeth has raised concerns. After accidental exposures to high concentrates of tetrachlorodibenzo-p-dioxin (TCDD) in Seveso, Italy, 1976, and to polychlorinated biphenyls (PCBs) and polychlorinated dibenzofurans (PCDFs) in Taiwan, 1978, developmental dental defects have been detected (Alaluusua et al. 2004; Wang et al. 2003). Moreover, Slovenian children living in an area heavily contaminated by PCBs had increased prevalence of DDE (Jan & Vrbic 2000). Current background levels of dioxins are thought to be too small to affect the prevalence of DDE (Alaluusua & Lukinmaa 2006). Recently, however, based on the findings of animal experiments, the suggestion has re-emerged that toxicants, especially endocrine disrupting chemicals (EDCs) such as bisphenol A, could interfere with enamel development (Jedon et al. 2013; Jedon et al. 2014; Jedon et al. 2016).

Tetracycline antibiotics have the ability to form a chelate with calcium ions and incorporate developing tooth hard tissues, leading to a permanent discoloration of teeth. They may also increase the risk of enamel hypoplasia, and minocyclin has also been associated with pigmentation of various tissues (Sanchez et al. 2004). Recent studies indicate that doxycycline antibiotics would not cause staining and may be safe to use in children (Volovitz et al. 2007; Todd et al. 2015; Pöyhönen et al. 2017).

The effect of common childhood illnesses or medications on enamel development have gained attention, but prospective studies are few. Most

studies have been conducted retrospectively and rely on parental recall, which increases the bias. In 1987, Suckling et al. (1987) investigated the association between DDE and childhood illnesses and found that prevalence of hypoplasia was higher among children who had suffered from chicken pox during the first three years of life. More recently, no association was found between DDE and illnesses (Wong et al. 2014). In the Iowa Fluoride study, where the Fluorosis Risk Index (FRI) was used to study DDE, amoxicillin administered at the age of 3–6 months increased the risk of fluorosis in incisors, independent of fluoride exposure (Hong et al. 2005), and the risk of fluorosis in whole dentition was increased if a child had received amoxicillin at the age of 20–24 months (Hong et al. 2011).

The effect of amoxicillin and other antibiotics on enamel development has been studied in animal experiments. Sahlberg et al. (2013) found that amoxicillin interfered with enamel development in cultured mouse molars and the effect was potentiated with fluoride. Kuscu et al. (2013) exposed pigs to amoxicillin for 20 days and found decreased enamel mineral composition in microCT imaging but clinical defects were not seen. Mihalas et al. (2016) exposed mice to amoxicillin/clavulanate for 60 days and enamel hypomineralization was clinically seen in their lower incisors. Histological evaluation revealed morphological changes in maturation and transitional ameloblasts, whereas secretional ameloblasts did not differ from those of the control group. However, a recent study which investigated enamel mineral composition in mice treated with amoxicillin, amoxicillin/clavulanate and erythromycin, found no difference in enamel mineral content compared to controls (Serna Munoz et al. 2018). Nonetheless, antibiotics, as well as the non-steroidal anti-inflammatory drug acetaminophen, altered the expression of cyclo-oxygenase 2 in the maturation stage enamel.

In the last twenty years, the etiology of demarcated opacities in first permanent molars, the entity called Molar-Incisor Hypomineralization (MIH), has gained increasing interest.

2.3 MOLAR-INCISOR HYPOMINERALIZATION

2.3.1 DEFINITION

During the last decades, a considerable number of DDE studies have concentrated on enamel hypomineralization in early developing permanent teeth, FPMs and incisors. The first reports describing specifically the enamel hypomineralization of FPMs are from the 1980s. Koch et al. (1987) illustrated how Swedish clinicians had encountered a considerable clinical problem of

children with extensive and severe hypomineralization of enamel in their permanent incisors and FPMs. They conducted an epidemiological study of 2,252 children living in Jönköping, Sweden, and found that 15.4% of the children born in 1970 were affected by such defects, whereas among children born in 1966, 1969, 1971, 1972 and 1974, the corresponding figures ranged between 3.6 and 7.3%. The examined children were 8 to 13 years old. For that study, the researchers developed a scoring system, where they divided incisors and FPMs into units and considered enamel changes in either color (white, yellow, brown) or structure (rough, abraded, disintegrated, atypical restoration replacing broken-down hypomineralized enamel). They used the term “idiopathic enamel hypomineralization”, and excluded enamel changes diagnosed as AI, fluorosis, hypomineralization caused by local trauma or infection, or “major disturbances in general health”. The affected children born in different years represented a similar pattern of defects: at least one FPM was always affected and FPMs were also more severely affected than incisors. Later, they called this entity “Morbus S” after one of the affected children and compared its prevalence to the prevalence of fluorosis, diagnosed using the Dean’s criteria (Koch 2003). The prevalence and severity of fluorosis was higher among children born in Uppsala, where water fluoride content was 1-1.2 ppm, than among children not born in Uppsala. However, such a difference was not obvious in the prevalence of Morbus S. The Morbus S prevalence figures were 5.5% for Uppsala-born children and 6.7% for children born elsewhere. Therefore, it was assumed that Morbus S was distinct from fluorosis.

In the 1990s, an increasing number of studies concentrated on hypomineralization defects in FPMs. Researchers from the Netherlands published a pilot study of the etiology of “cheese molars” (van Amerongen & Kreulen 1995). The name was used to describe the appearance of hypomineralized enamel resembling old Dutch cheese. They did not conduct a prevalence study but stated that FPMs are frequently identified as cheese molars. Later, a group of 11-year-old Dutch children were examined, and 9.7% had cheese molars (Weerheijm et al. 2001a).

In Finland, “non-fluoride hypomineralization” was considered a clinical problem and the prevalence of such defects among children in certain Helsinki schools was studied (Leppäniemi et al. 2001). FPMs of 7- to 13-year-old children were examined for enamel hypomineralization using a scoring system similar to the one developed by Koch et al. (1987). Defects were categorized into mild (smooth enamel with a color change: white, yellow or brown), moderate (broken enamel) or severe (lesions affecting both enamel and dentin, atypical fillings replacing affected hard tissues, or tooth extraction because of severe hypomineralization). Hypoplasia, “diffuse opacities indicating fluorosis” and genetic dental disorders were not included. The

prevalence of children with hypomineralized FPM(s) was 19.3%. Of them, 46.1% had mild defects and 53.8% had severe or moderate defects.

In Sweden, Jälevik et al. (2001a) examined the enamel of permanent teeth of 516 7- and 8-year-old children. To describe the entity of demarcated opacities in FPMs, they used the term Molar-Incisor Hypomineralization (MIH). The term had been recently proposed to cover all the different names used to describe what was apparently the same condition (Weerheijm et al. 2001b). In Jälevik et al. (2001a) study, MIH was diagnosed when a child had at least one FPM affected with a demarcated opacity, which was either mild (a normal hard surface), moderate (loss of surface enamel without a need for treatment) or severe (disintegrated enamel requiring restoration or already restored). Defects smaller than 2 mm were not registered. They found that 95 children (18.4%) had MIH. Of them, 18.9% had only one FPM affected, 33.7% had two or more affected FPMs and 47.4% had both molars and incisors affected by demarcated opacities. They also reported that 33.3% of the children had some form of DDE at least in one permanent tooth. Diffuse opacities were registered in 7.5% of the children and 0.8% had hypoplasia in one or several (front) teeth.

Interest in enamel hypomineralization in FPMs continued to increase and was the topic of the 6th Congress of the European Academy of Paediatric Dentistry in Dublin, Ireland 2002. The name MIH was suggested for future use. Despite not attaining complete agreement on naming the condition, it nonetheless became established. Some suggested that the prevalence of hypomineralized FPMs was increasing. As data on the prevalence of MIH were lacking, criteria were established for further epidemiological studies (Weerheijm et al. 2003). In addition to previous DDE indices, post-eruptive breakdown (PEB) and atypical restorations were included. The definition for PEB is the following: “A defect that indicates a deficiency of the surface after eruption of the tooth. Loss of initially formed surface enamel after tooth eruption. The loss is often associated with a pre-existing demarcated opacity.” (Weerheijm et al. 2003). Atypical restorations were defined as follows: “The size and shape of restorations are not conforming to the caries picture. In most cases, in molars, there will be restorations extended to the buccal or palatal smooth surface. At the border of the restorations an opacity can frequently be noticed. In incisors a buccal restoration not related to trauma can be noticed.” (Weerheijm et al. 2003). MIH defects were limited to demarcated opacities, as diffuse opacities were thought to be independent of MIH and related to fluorosis. Also, hypoplasia was excluded from MIH diagnosis as well as white-spot lesions, white cuspals and marginal ridges, erosion, tetracycline staining and AI.

The EAPD judgement criterion was widely used but researchers needed a more standardized data collection instrument for clinical practice as well as epidemiological surveys. After the 12th EAPD Congress in 2014, the criterion for MIH was presented by Ghanim et al. (2015). They proposed two forms, a

short form and a long form. In the short form, index teeth are FPMs, permanent incisors and second primary molars, while the long form is used to record enamel defects in all erupted teeth. A category named “Enamel defects other than MIH” is used for demarcated hypomineralization in teeth other than index teeth, as well as diffuse opacities, hypoplasia (pits, grooves, areas) and AI. Moreover, “atypical caries” and the extension of the lesion are included in the criterion as well. Enamel defects of one millimeter or less in diameter are not recorded. This MIH Index was later tested and validated (Ghanim et al. 2019).

Another index, MIH-SSS, was recently presented for scoring the severity of MIH (Cabral et al. 2019). When this criterion was tested in a longitudinal setting, it was found that yellow opacities progressed to PEB more often than white opacities.

The enamel development in second primary molars and permanent canines partly overlaps that of the enamel development in FPMs and incisors. Demarcated opacities in second primary molars are associated with MIH (Elfrink et al. 2012; Mittal et al. 2016; da Silva Figueiredo Se et al. 2017). The term Deciduous Molar Hypomineralization (DMH) was introduced by Elfrink et al. (2009) to describe the entity of MIH-like defects in second primary molars. The prevalence of DMH was found to be 4.9% among 5-year-old Dutch children (Elfrink et al. 2008). A study from Germany found that 19.2% of the children with MIH had opacities in the tips of their canines (Dietrich et al 2003). Norwegian researchers investigated 16-year-old children and found that the tips of canines were affected in 22.8% of the individuals with MIH while in the group of children without MIH, canines were affected in 1.6% (Schmalfuss et al. 2016).

The definition of MIH has been questioned. It is recommended that epidemiological studies be carried out on 8-year-olds, when FPMs have erupted but are not yet affected by caries (Weerheijm et al. 2003). Notably, tooth eruption is still ongoing, and canines, premolars and second permanent molars cannot be examined. In a group of 8- to 13-year-old Indian children, 27.3% of the individuals with MIH had “MIH-like defects” in canines and premolars (Bhaskar & Hedge 2014). Jälevik et al. (2019) found that half of the children who fulfilled the MIH criteria (at least one FPM affected with a demarcated opacity) also had additional teeth (canines, premolars and /or second permanent molars) affected with diffuse opacities, demarcated opacities or hypoplasia. Moreover, diagnosing MIH showed to be challenging. One-fourth of the children who had been diagnosed with MIH, later appeared to be affected by other enamel disturbances instead, mainly by diffuse opacities. The authors suggest that patchy cloud-like defects may be misinterpreted as mild MIH. Recently, new findings suggest that children with

MIH may more likely also have other dental anomalies than their peers (Walshaw et al. 2019).

2.3.2 PREVALENCE

To date, numerous MIH prevalence studies have been conducted. Recently, two systematic reviews have assessed the prevalence of MIH. Zhao et al. (2018) reviewed 70 studies written in English or Chinese and found a global prevalence of 14.2% (95% CI 12.6–15.8). Sample size was found to affect the heterogeneity of results. There was no prevalence difference between genders, but prevalence was higher among 10-year-olds or younger than among older children (15.1 vs. 12.1%). Moreover, prevalence differences between continents were detected: the highest prevalence was found in South America (18%) and the lowest in Africa (10.9%). Schwendicke et al. (2018) conducted a systematic review without language restrictions and reached 99 eligible studies that defined MIH using either EAPD criteria or its modifications, or components of some other indices, such as the DDE index. A global prevalence of 12.9% was found (95% CI 11.7–14.3) (Schwendicke et al. 2019). The EAPD definition was used by most of the studies ($n = 74$) and these studies found significantly higher prevalence of MIH, 14.5%, than the studies using other definitions, 10.2%. The sampling method, however, did not affect the results. Significant prevalence differences between countries were detected, but there were also significant prevalence differences within countries. In Brazil, for instance, the prevalence rates ranged from 2.5% (Rodrigues et al. 2015) to 40.2% (Soviero et al. 2009). There were no studies from the US or Canada included in the review, but recently, a study from Wisconsin, USA, reported that the prevalence of MIH was 9.6% among children from the Milwaukee public school system (Davenport et al. 2019).

2.3.3 PROPERTIES OF HYPOMINERALIZED ENAMEL

Different methods, such as scanning electron microscopy (SEM) and transmission electron microscopy imaging, X-ray tomography and sulphate-polyacrylamide gel electrophoresis have been used to study the properties of hypomineralized enamel in extracted teeth (Elhennawy et al. 2017b). Different preparation and sectioning techniques may be may reside behind somewhat heterogenous findings. However, differences between the affected and sound enamel have been detected.

2.3.3.1 Chemical properties

Magnum et al. (2010) characterized the protein composition of hypomineralized enamel in extracted human FPMS. Severe defects had 3- to 15-fold higher protein content than normal, but the proteins seemed to be something other than the main matrix proteins, amelogenins. A variety of body fluid proteins were found. Moreover, broken lesions contained hemoglobin as a major component, whereas intact lesions contained albumin. Further, the authors concluded that surface integrity affects the protein composition of hypomineralized enamel. Similarly, Farah et al. (2010b) detected 8- to 21-fold higher protein content in hypomineralized enamel, with brown lesions containing the highest amount of protein. Serum albumin, alpha-1-antitrypsin and antithrombin III were identified in yellow and brown enamel samples. Recently, Malmberg et al. (2019) reported that hypomineralized enamel contained 8 times more organic matter than normal enamel. Consequently, hydroxyapatite content was lower in hypomineralized enamel. Based on the protein component studies, MIH is distinguishable from hypomaturity type AI, where amelogenins seem to correspond to the increased protein content (Wright et al. 1997).

2.3.3.2 Mechanical properties

The mean hardness and elastic modulus of hypomineralized enamel is lower than in sound enamel (Mahoney et al. 2004), but higher variance in hardness values was found in hypomineralized enamel (Fagrell et al. 2010).

2.3.3.3 Structural properties

Jälevik & Norén (2000) studied the morphology of extracted and sectioned MIH molars using polarized light microscopy. They reported that the porous zone in the enamel did not always extend through the whole enamel layer but was located in the inner enamel close to EDJ. Also, when the whole enamel layer was affected, the degree of porosity was not uniform throughout the enamel. Cervical enamel was always unaffected. A similar observation was made by Suga (1989) who investigated the developing enamel of human third molars germs as well as monkey permanent teeth germs. It was suggested that hypomineralization was more extensive in thick than in thin enamel. Moreover, the surface was found to have a higher degree of mineralization, both in erupted and unerupted teeth (Suga 1989).

Later, Jälevik et al. (2005) studied hypomineralized teeth using SEM. The structural changes varied depending on the hypomineralization degree. The more severe the defect, the more irregular the crystal orientation. In severely porous areas, interrod areas were wide and the rods were very thin and irregular. The border between hypomineralized and normal enamel followed

the rods. Similar structural changes have been reported elsewhere: the loss of distinct boundaries between rods (Mahoney et al. 2004) and considerably wider rod sheaths in hypomineralized enamel compared to sound enamel (Xie et al. 2008; Chan 2010). Enamel surface was porous and fractured specimens revealed disorganized crystals (Crombie et al. 2013).

Fagrell et al. (2013) examined extracted FPMs which were severely affected by MIH using light microscopy and stereo microscopy. Normal features of enamel, such as Hunter-Schreger bands, Retzius lines and enamel prisms were seen in both normal and hypomineralized enamel. Hypomineralized lesion extended through the whole enamel layer and the distinction between hypomineralized and normal enamel followed a rod, not an incremental line. At the center of the hypomineralized lesion, the enamel surface appeared porous, otherwise it was normally mineralized. Mesio Buccal cusps, where the enamel development in FPMs starts, were most often and most severely affected.

2.3.4 THE ONSET OF MIH

Despite extensive studies on the structure of hypomineralized enamel, the onset and mechanism of hypomineralization is not known. Even the exact timing of the mineralization in FPMs is not well known. Butler (1967) investigated the development of upper FPMs using jaws of fetuses and described that mineralization was first seen at the tip of the mesio Buccal cusp of FPMs in 30- to 34-week-old fetuses. Somewhat more developed fetuses (32 to 35 weeks) had FPMs where mineralization had extended cervically from the mesio Buccal cusp, further on the buccal and mesial sides than on the lingual and distal sides. In older, 36-week-old specimens, mineralization in the tips of mesio palatal and disto Buccal cusps was observed. Earlier Logan & Kronfeld (1933) had stated that mineralization of FPMs does not start before birth. Their material consisted of jaws of 25 children from newborn to 15-year-olds, who had died for various reasons, most often due to tuberculosis or associated diseases. At the postnatal age of six months, the tips of the mesial cusps of the upper FPMs and all cusps of the lower FPMs were mineralized, but mineralization had not reached the occlusal fissure. At one year of age, the crown was mineralized, and at the age of one-and-a-half years, the mineralization of the crown had increased “considerably”. According to their material, at three years of age, the crowns of FPMs were fully mineralized. More recently, Reid & Dean (2006) used fully formed FPMs and estimated, by calculating the incremental lines and enamel cross striations, that initial mineralization begins at the time of the birth.

A Finnish study evaluated radiographs taken from both living individuals as well as postmortem during medicolegal autopsies, and the bone crypt of

mandibular FPMs was found to be visible in newborns (age 0.00 years) (Nyström et al. 2007). They used the method developed by Demirijan et al. (1973) to grade the permanent tooth developmental stages from radiographs, and the first stage, where the tips of tooth cusps have a thin layer of mineralized tissue was seen at about the age of two months (0.20 years boys, 0.19 years, girls) although this age was expected to be too high because of material characteristics. The authors had earlier reported that in skull radiographs, initial mineralization of mandibular FPMs was visible already at the age of one month (Nyström & Ranta 2003). The average age when FPMs were at the fourth stage (the entire crown is visible, but root development has not started), was 2.79 years (boys) and 2.84 years (girls) (Nyström et al. 2007). The radiologic evaluation does not give detailed information on the mineralization status, but it can be supposed that during the first (A) and second (B) Demirijan stage, ameloblasts are mainly in the secretory stage, and at the beginning of the third (C) Demirijan stage, the majority of ameloblasts have reached the maturation stage. Finally, all ameloblasts (the most cervical ameloblasts being the last) would reach the maturation stage by the beginning of the fourth Demirijan stage. If this deduction is accurate, it can be estimated that during the first year of life, ameloblasts in FPMs are in the secretory stage, and the first cells reach the maturation stage after the first birthday (attainment age for stage C is 1.19 and 1.35 years), in boys a little later than in girls (Nyström et al. 2007).

Jälevik et al. (2005) suggested that the ameloblast function was normal during the secretion phase, since the basic enamel structure had been maintained in hypomineralized areas. However, the borders of the hypomineralization defect seem to follow the passage of the enamel rods, and Fagrell et al. (2013) estimated that the disturbance leading to MIH affects secretory ameloblasts during the first six to seven months of life. A possible mechanism for the hypomineralization could be that at the secretory stage, ameloblasts produce a matrix capable to initial mineralization, which produces normal rod structure, but the matrix is so dysfunctional that complete enamel maturation does not occur. This could be due, for example, to defective proteins or enzymes produced during the secretion stage. Moreover, during the maturation stage, basal lamina is essential for maintaining the optimal microenvironment for mineralization. Speculatively, if ameloblasts fail to establish basal lamina, enamel mineralization will be disrupted.

To answer the question of the variable clinical appearance of MIH, where all teeth that develop at same time do not show similar defects, Vieira & Manton (2019) proposed that the genetic influence on tooth development differs between teeth and the sides of the mouth within an individual. The idea was based on a finding from amelotin-deficient mice, where defects were restricted to one tooth (Nakayama et al. 2015). It was also suggested that the observation that only a particular area of the tooth is affected may be related to similar

mechanisms which cause different brain convolutions and fingerprints, through microenvironment influences and gene contributions. Another possible hypothesis is based on the finding that MIH opacities are rare in lingual surfaces of lower FPMs and palatal/lingual surfaces of incisors (Kevrekidou et al. 2015), where enamel is thinner than in buccal surfaces. Suga (1989) also reported that defects are more common in thick than in thin enamel. Perhaps producing a thick enamel is an arduous task for ameloblasts and the capability to recover from malfunctions is reduced. Moreover, the tooth size and enamel formation rate may be the reason why FPMs are the teeth most frequently affected by DDE, along with central incisors (Jälevik et al. 2018). DDE in incisors are often due to trauma to the precursor primary teeth which is not true for FPMs (Jälevik et al. 2018). One possible explanation for increased prevalence of DDE in FPMs could be that enamel formation time is shorter than in other permanent teeth (Table 1). Hypothetically, ameloblasts' "threshold line" for disruption is lower in FPMs than in other permanent teeth (Figure 2).

2.3.5 ETIOLOGY

When Koch et al. (1987) detected a higher prevalence of hypomineralized FPMs among children born in 1970, an environmental factor interfering with enamel development was suspected. Several studies have been conducted on the etiology of MIH. In 2016, a systematic review on the etiology of MIH by Silva et al. included 25 studies (Silva et al. 2016). Only five of them were prospective and most collected information on the etiological factors using questionnaires or interviews. Adjustment for confounding variables was rarely done and the studied exposures lacked consistency and detail. However, considerable evidence for the association between MIH and early childhood illnesses was found. Here, a brief review of the etiology of MIH is presented based on recent literature.

2.3.5.1 Genetics

Since conclusive evidence of the etiology of MIH is missing, it has been speculated that there is a genetic susceptibility to develop MIH. There are no studies reporting on familial occurrence of MIH. Teixeira et al. (2018) examined 167 pairs of twins and found that monozygotic twins were more likely to both be affected by MIH than dizygotic twins. However, the results indicate that MIH is a multifactorial condition with genetic susceptibility since there were also monozygotic twins of whom only one individual was affected. Based on those results, Vieira (2019) calculated a 20% heritability for MIH.

A few potential gene mutations associated with MIH have been reported. Jeremias et al. (2013b) studied the association between MIH and the polymorphisms in genes related to enamel development. In a Brazilian population, individuals with an A allele in ENAM rs3796704 marker were protected against MIH development. Instead, a G allele was associated with the severe MIH. In a Turkish population, individuals with a G allele of the same marker were 17 times more likely to have MIH than those with an A allele. In addition, significant associations were found between MIH and certain markers of the TUFT1, AMBN and TFIP11 genes. However, when Kühnisch et al. (2014a) conducted the genome-wide study of the association between gene polymorphism and MIH, they did not find any clear associations between MIH and genes involved in enamel formation (AMBN, AMTN, MMP20, TUFT1 were studied). The ENAM and AMELX/Y genes were not studied, however. The primary finding of the study was that the possible gene locus associated with MIH was SCUBE1, which is associated with cranial and tooth germ development, but also with bone morphogenetic protein (BMP) signaling. However, the study sample may not have been large enough to detect positive associations. Jeremias et al. (2016) further studied several MIH candidate genes in children with MIH and in their unaffected parents or siblings and found significant associations between MIH and certain single nucleotide polymorphisms (SNP) in the FAM83H, AMBN, BMP2, BMP7, BMP4, ENAM, MMP20, DLX3, FGFR1 and AMELX genes. Bussaneli et al. (2019) expanded the genetic research and studied certain SNPs in the immune response genes IL1A, IL1B, IL4, IL6, IL8, IL10, TNF α , TNF β 1, IL17A, TGF β R1 and STAT1. They found that polymorphism in the TGF β R1 gene was associated with the severity of MIH.

2.3.5.2 Pre- and perinatal period

Some studies have found that problems related to birth are associated with MIH. Van Amerongen & Kreulen (1995) evaluated the medical records of patients with “cheese molars” and found that 48% had encountered problems related to birth. They did not have a control group to compare results with. A Swedish study showed that MIH was more prevalent among preterm-born children (n = 82) than among their full-term controls (n = 82) (38% vs. 16%, respectively) (Brogårdh-Roth et al. 2011). The prevalence of diffuse opacities did not show such a trend but overall DDE in permanent dentition was more prevalent among preterm born children. In addition, Ghanim et al. (2013) retrospectively interviewed Iraqi mothers whose children were examined for MIH (n = 823) and reported that maternal illness during the third trimester, a birth weight of less than 2.5 kg, and neonatal hypoxia with incubation increased the odds of having MIH. However, conflicting results exist. Sönmez et al. (2013) examined a large population of children (n = 3,827) from randomly selected schools in Ankara, Turkey, and collected information on the possible etiological factors using questionnaires. Premature birth slightly

increased the odds for having MIH (OR 1.53) but low birth weight, illnesses during the last trimester, or birth complications did not. Similarly, Fagrell et al. (2011) in their prospective case-control study did not find an association between severe MIH (demarcated opacities with PEB and/or atypical restorations) and pre-, peri-, or neonatal problems. Sidaly et al. (2016) did not find an association between MIH and a five-minute Apgar score ≤ 5 . In their review, Silva et al. (2016) concluded that there is little evidence of the association between MIH and pre- and perinatal factors.

2.3.5.3 Childhood morbidity

The pilot study on “cheese molars” evaluated the childhood morbidity of the affected children using medical files and found that 67% had suffered from respiratory diseases (van Amerongen & Kreulen 1995). The authors speculated that oxygen shortage during the enamel development of FPMs can lead to defective enamel. Since then, studies concentrating on the illnesses or medications during the first years of a child’s life have been abundant, but mainly based on retrospective assessment of events from the first years of life (Jälevik et al. 2001b; Beentjes et al. 2002; Muratbegovic et al. 2007; Kuscu et al. 2008, Whatling & Fearne 2008; Kuscu et al. 2009; Arrow 2009; Souza et al. 2012; Ghanim et al. 2013; Sönmez et al. 2013; Pitiphat et al. 2014; Allazzam et al. 2014; Rodrigues et al. 2015), leading to a high risk of recall bias. Even the studies that used a prospective setting produced conflicting results. Fagrell et al. (2011) conducted a case-control study where they evaluated whether childhood morbidity was associated with severe MIH (demarcated opacities with PEB or atypical restorations or both). The children had participated in a prospective medical study, and a detailed diary was kept during the first years of life to register diseases, medications and feeding habits. There was no difference in the occurrence of illnesses or infectious diseases between children with severe MIH (n = 224) and their healthy peers (n = 253). Neither were medications during the first three years of life associated with severe MIH. However, Kühnisch et al. (2014b) examined 692 children who also were participating in a prospective medical study where the occurrence of respiratory diseases (bronchial asthma, bronchitis, pneumonia, or croup) was recorded from birth onwards. The original study sample was divided into intervention and non-intervention groups to examine different infant formulas. Analysis were adjusted to intervention status, and it was found that children with at least one episode of respiratory disease within the first four years of life had a 2.5-fold risk for having demarcated hypomineralization i.e. MIH in at least one FPM and incisor. They did not collect information on the systemic treatment of disease and hence an association with antibiotic therapy could not be verified. Earlier, Laisi et al. (2009) reported a positive correlation between MIH and at least one course of amoxicillin or erythromycin during the first year of life. The information about the antibiotic use was obtained from medical records.

2.3.5.4 Other environmental factors

The association between long breastfeeding and MIH aroused interest when a Finnish case-control study found that children with mineralization defects in their FPMs ($n = 40$) had been breastfed significantly longer than their peers ($n = 40$) (Alaluusua et al. 1996a). Similarly, breastfeeding was associated with mineralization defects in a selective group of children whose mothers had been encouraged to prolong breastfeeding. It was speculated that environmental toxicants are secreted through mother's milk and interfere with enamel development in FPMs. This speculation was further strengthened when dioxin concentrations in mothers' milk were found to be associated with DDE in FPMs in children born in 1987 (Alaluusua et al. 1996b). However, ten years later, in a group of children whose exposure to dioxins was estimated by measuring the levels in placental fat, no association was found between dioxin exposure and the occurrence or severity of MIH (Laisi et al. 2008). Moreover, the duration of breastfeeding, which was retrospectively assessed at the time of the dental examination, was not associated with MIH. Several other studies have retrospectively evaluated the association between breastfeeding and MIH, but no link has been found (Leppäniemi et al. 2001; Souza et al. 2012; Pitiphat et al. 2014; Allazzam et al. 2014; Tourino et al. 2016). Interestingly, in their prospective study Fagrell et al. (2011) investigated several factors related to a child's health and way of living, but only long breastfeeding (> 6 mo) and late introduction to gruel and infant formula (> 6 mo) were associated with severe MIH. The authors suggested the role of nutrition in enamel development.

A recent randomized controlled trial (RCT) found that a high dose of vitamin D₃ supplementation during the third trimester of pregnancy was associated with reduced odds of MIH in the offspring (Nørrisgaard et al. 2019). The intervention group received a daily dose of 2800 IU (70 mcg) of vitamin D while the dose of the control group was 400 IU/d (10 mcg). The prevalence of MIH was 15.1% in the intervention group and 27.5% in the control group. This was a new finding, since in previous studies, where serum 25-hydroxyvitamin D levels and first-year vitamin D supplementation were investigated, no association with MIH was found (van der Tas et al. 2016; Kühnisch et al. 2017). However, in the study by Kühnisch et al. (2017), 82.4 to 94.1% of the children had received vitamin D supplementation during the first year of life and it is possible that the study did not have enough power to detect possible prevalence differences between the supplementation and non-supplementation groups. Similarly, in the van der Tas et al. study from 2016, the overall prevalence of MIH was low, at 8.1%. Further studies would be needed to draw conclusions, but it can be suggested that high doses of vitamin D supplementation during pregnancy protect against enamel defects through either maternal or child developmental factors.

2.3.6 CLINICAL IMPLICATIONS

2.3.6.1 Hypersensitivity

When interviewed, 31% of the patients with MIH reported hypersensitivity during daily activities (Petrou et al. 2015). A recent study examined hypersensitivity using air blasts and tactile stimuli on FPMs with hypomineralization and on control teeth, which were the unaffected molars of the same child (Raposo et al. 2019). Only one unaffected molar out of 161 was hypersensitive after stimuli. MIH-affected molars with moderate defects (PEB) and severe defects (PEB involving dentin or atypical restoration) were significantly more sensitive to air blasts than molars with mild defects (demarcated opacities). After tactile stimuli, severely affected molars were significantly more sensitive than molars with mild or moderate defects, which may also be due to dentin caries that affected more than 90% of the severely affected molars.

Hypersensitivity may not only be due to exposed dentin and a consequent nerve response to dentinal fluid movement, but also a sign of chronic pulpal inflammation (Närhi et al. 1994). An immunocytochemical study that investigated pulpal status of the extracted, non-carious hypomineralized FPMs found that pulpal innervation in the pulp horn and in the occlusal subodontoblastic region was increased in hypomineralized teeth, both with and without enamel loss, compared to sound teeth (Rodd et al. 2007a). Also, the pulps of hypomineralized teeth with enamel loss contained more immune cells than sound teeth. There was no difference in the pulpal vascularity between hypomineralized and sound teeth, however. The same researchers also found that within the pulps of MIH-affected teeth, nerve fibers reactive to TRPV1, a noxious heat receptor, were more abundant than within the pulps of sound teeth (Rodd et al. 2007b). MIH-affected teeth with and without enamel loss had elevated neural expression of TRPV1 in the subodontoblastic region compared to sound teeth. Vascular TRPV1 expression differed between MIH and sound teeth in the pulp-horn region. The findings suggest pulpal inflammation and increased sensitivity to thermal changes in MIH-affected versus sound teeth.

2.3.6.2 Caries risk

Several studies have found a positive correlation between MIH and caries. Children with MIH have had higher DMFT values than their peers (Leppäniemi et al. 2001; Jeremias et al. 2013a; Petrou et al. 2014; Kosma et al. 2016; Grossi et al. 2017), or caries has been more prevalent among children with MIH than among children without MIH (Da Costa-Silva et al. 2010; Bhaskar & Hedge 2014). This is plausible considering the weakened structural

properties of the hypomineralized enamel. The challenge of studying the link between caries and MIH, however, is that observational bias cannot be eliminated. Moreover, in a cross-sectional study design, it is not possible to distinguish whether restorations and teeth extractions were originally conducted due to caries or PEB. A German study did not include atypical restorations in the F component of the DMF index and found no association between MIH and DMFT values in 10-year-old children (Heitmüller et al. 2013). However, when a similar study was conducted among 15-year-old children, a difference in DMFT values as well as in the number of non-cavitated caries lesions between children with MIH and children without MIH was found (Kühnisch et al. 2018).

2.3.6.3 Dental management problems

An increased number of treatments and hypersensitivity were supposedly the factors behind greater behaviour management problems and dental fear and anxiety among children with severe MIH, compared to children with normally mineralized molars (Jälevik & Klingberg 2002). Fortunately, when the same children were interviewed for dental fear and behaviour management problems nine years later, the children with severe MIH did not report to suffer from dental fear or anxiety more than their healthy peers (Jälevik & Klingberg 2012). However, behaviour management problems were still more common among those children and they had received treatments four times more often in their FPMs than did children from the control group. Two other studies did not find any association between MIH and dental anxiety or dental fear, measured using questionnaires completed by parents (Menoncin et al. 2019) or by children (Kosma et al. 2016).

2.3.6.4 Esthetic considerations

Based on the number of published studies, the clinical implications of hypomineralized incisors seem to be smaller than those of hypomineralized molars. Petrou et al. (2015) reported that none of the hypomineralized incisors had atypical restorations and only 1.5% had opacities with PEB. Ozgül et al. (2013) in their experimental study, investigated the sensitivity of hypomineralized incisors to cold stimuli using the Visual Analog Scale (VAS). Mean VAS ranged from 4.9 (uncomfortable) to 6.5 (distressing), and girls were more sensitive than boys. However, control teeth were not used as the study investigated the effect of a desensitizing treatment on hypomineralized incisors only. Presumably, the hypomineralization defects in incisors are mainly an esthetic concern.

A microabrasion technique is used to improve esthetics of the incisors with opacities. Wong & Winter (2002) reported that 53% of the patients were

satisfied with the tooth appearance after a six-month follow-up, while Sheoran et al. (2014) achieved a reduction of opacities in 96.7–97.2% of the teeth involved after a 1-month follow-up period. Of the patients, 60% reported moderate improvement and 40% exceptional improvement in esthetics.

2.3.7 TREATMENT

For teeth affected by MIH, several treatment modalities are available and can be adopted depending on the severity of the defect, symptoms and patient-related factors.

2.3.7.1 Controlling caries

Contemporary methods for controlling caries apply to hypomineralized teeth. Patients and parents must receive appropriate dietary and preventive advice (Lygidakis et al. 2010). As maintaining proper oral hygiene can be challenging due to tooth hypersensitivity, hypomineralized teeth may benefit from targeted preventive measures, such as the regular application of fluoride varnish and sealing the occlusal fissures and enamel with PEB. However, research on the efficacy of those measures in the prevention of caries is lacking.

Nevertheless, since hypersensitivity may affect the level of hygiene, methods that decrease tooth hypersensitivity should be part of the caries-prevention approach. Different topical products have been studied. Remineralization treatment with casein phosphopeptide-amorphous calcium phosphate (CPP-ACP) seems to be more effective for tooth sensitivity than topical fluoride, although the effect may not last for long (Ozgül et al. 2013). In addition, in a clinical study of 16 children with hypersensitive MIH-affected molars, the use of arginine toothpaste decreased the sensitivity of tooth immediately, and the desensitization was maintained during the eight weeks that the study lasted (Bekes et al. 2017).

A recent study evaluated the efficacy of customized treatments on children's oral hygiene and quality of life (Fütterer et al. 2020). Although different treatments were not comparable, since they were selected for individual teeth based on the severity of hypomineralization and symptoms, it was found that treatment (fissure sealants, fillings, or SSCs) significantly decreased the plaque accumulation and tooth hypersensitivity during the average six-month follow-up, especially among children belonging to higher severity groups. However, the authors mention that teeth with severe hypomineralization will not become symptom-free but require further monitoring after treatment.

When the success of fissure sealants was compared between children with and without MIH, it was found that among the children with MIH, sealants required retreatment earlier than among their peers (33.0 months vs. 55.6 months) (Kotsanos et al. 2005). Lygidakis et al. (2009) prospectively studied the survival of two different techniques of applying fissure sealants on FPMs with occlusal hypomineralization but without PEB. The use of a single-bottle adhesive system prior to application of the sealant enhanced the retention, since after a four-year follow-up period, 70.3% of the adhesive fissure sealants were still fully in place, while of the sealants placed using the conventional etch-and-seal technique, only 25.5% were present. Another prospective clinical study compared fissure sealants between MIH-affected and healthy FPMs (Fragelli et al. 2017). Selected teeth needed caries-preventive care, and MIH-affected FPMs did not have PEB. At 18 months, 62% of the sealants on hypomineralized molars and 72% of the sealants on control molars remained unchanged, but the difference was not statistically significant.

2.3.7.2 Restorative treatment

The altered properties of hypomineralized enamel set challenges for restorative treatment. Kotsanos et al. (2005) compared the FPM treatment outcomes in children with and without MIH. After an approximate four-year follow-up period, none of the restorations in the control group needed re-treatment, while among children with MIH, 61.1% of the amalgam restorations and 25.4% of the resin composite (RC) restorations had required re-treatment. The children with MIH had a total of 24 FPMs restored with stainless-steel crown (SSC) and none of them had required re-treatment during the follow-up period. Another observational study found that 85.3% of the RC restorations in MIH-affected FPMs had a good or acceptable outcome 4–5 years after the treatment, while the same was true for 49.2% of the glass ionomer cement (GIC) restorations (Mejère et al. 2005). In the same study, one tooth was restored with SSC and nine were restored with gold or porcelain castings, all of which were rated as good or acceptable.

In a four-year-long clinical study on the treatment of FPMs severely affected by MIH, RC restorations performed well, since none of the 49 restorations required replacement (Lygidakis et al. 2003). Cavity preparations were extended to the “sound” enamel, although sometimes discolored. Instead, a more recent RCT, which compared two different types of adhesives (self-etch and total-etch) for RC restorations on MIH-affected FPMs, did not achieve as good surveillance rates (De Souza et al. 2017). During the 18-month follow-up period, 68% of the restorations placed using self-etch adhesive and 54% of the restorations with total-etch adhesive survived. The difference between the groups was not significant. It was speculated that the poorer results were due to conservative cavity preparation, where defective enamel may have

remained at the margins. Indeed, another RCT found a significantly lower success rate (58.1%) for RC restorations with conservative cavity preparation, where cavity margins reside on hypomineralized but hard enamel, than for the RC restorations with more invasive preparation (81.3%), where cavity margins are extended to sound enamel (Sönmez & Saat 2017). However, when cavities with conservative design were treated with sodium hypochlorite (NaOCl) before bonding, surveillance rates were similar to those with more invasive cavity design (78.1%) with no significant difference to the RC restorations in the control group, molars without hypomineralization (87.1%). In that study, one-step self-etch adhesive with separate enamel etching was used. Several laboratory studies have been conducted to investigate different bonding strategies on hypomineralized teeth, but a 2016 systematic review concluded that the evidence is insufficient to prove that self-etch adhesives are inferior to etch-and-rinse adhesives (Ekambaram & Yiu 2016).

Recently, a 24-month long follow-up study found a 96.8% success rate for RC restorations in immature FPMs affected by caries and MIH (Gatón-Hernandez et al. 2020). Of the initial study participants, 86.2% (n = 281) completed the follow-up. In that study, caries was selectively removed, and the lesion was sealed with GIC interim material for six months before the final restoration with RC. The excellent success rate may have been promoted with preventive procedures that were implemented at every follow-up session: instructions to maintain oral hygiene and diet, plaque control, and application of fluoride varnish and CPP-ACP.

Fragelli et al. (2015) placed GICs on MIH-affected FPMs with structural loss or unsatisfactory restoration without removing the affected enamel. After a 12-month follow-up, 79% of the restorations were successfully retained. Markedly better results were achieved by Grossi et al. (2018) who studied the success of glass hybrid restorations on severely affected MIH teeth with caries using an atraumatic restorative treatment protocol. After 12 months, one restoration, which involved all tooth surfaces, failed, yielding a cumulative success rate of 98%. However, five restorations out of 60 were lost from the follow-up.

A clinical trial compared SSCs and nickel chrome alloy cast adhesive copings (CACs) on FPMs severely affected by MIH and on AI-affected molars (Zagdwon et al. 2003). They used the split-mouth design when applicable. Of 19 SSCs and 23 CACs, one SSC and two CACs failed during the 12- to 24-month follow-up period. The SSC failure was reported to be due to inaccurate crown size. There was no difference in the outcome between SSCs and CACs. The authors calculated that SSCs are more cost-effective than CACs. However, CAC restorations can be performed with conservative tissue removal. The success of gold CACs was later studied in a study by Gaardmand et al. (2013). Of 57 CACs, one was re-cemented after the first three months, and two required additional treatment because of caries after 43 and 68 months. The rest,

94.7%, survived (the mean follow-up time was 38.5 months). A conservative preparation technique is recommended for young FPMs due to wide pulp chambers and high pulp horns, as well as unsettled occlusions. Therefore, metal and composite onlays are potential management options for severely affected FPMs. While ceramic and zirconia onlays are frequently used in adults, those materials require more space and therefore may not be the ideal option in recently erupted teeth. A recent RCT studied the cast metal and RC onlays in FPMs severely affected by MIH and found survival rates of 85% for metal and 100% for the RC group in a 36-month follow-up period (Dhareula et al. 2019). The difference between the groups was not significant. The preparation margins were placed on sound enamel.

2.3.7.3 Extraction

Several factors, such as co-operation, occlusion and the developmental stage of the second permanent molar, have to be taken into account if the extraction of an FPM is being considered (Cobourne et al. 2014). Nevertheless, extraction may be an appropriate and cost-effective treatment if a child avoids repeated restorative treatments (Elhennawy et al. 2017a). This is especially valid if the occlusion favours spontaneous space closure. A recent review suggested extracting the FPM when the second permanent molar is in early bifurcation stage (Saber et al. 2018). It also advised clinicians to be more cautious in planning the extraction of the mandibular FPMs than maxillary FPMs. In the aforementioned study by Mejàre et al. (2005), 87% of individuals with at least one extracted FPM had acceptable space closure.

2.3.7.4 MIH in the Finnish Current Care guidelines on tooth restoration

The Finnish Medical Society Duodecim publishes evidence-based treatment recommendations for health care professionals in Finland. The aim is to provide a quick and easy source of information, especially for those working in outpatient and hospital clinics (Honkanen et al. 2016). A recently published guideline on tooth restoration includes treatment recommendations for FPMs affected by MIH, as follows (Working group set up by the Finnish Medical Society Duodecim and the Finnish Dental Society Apollonia, 2018):

- Mild defect (color or structural changes on free tooth surfaces, without symptoms): sealing the occlusal surface, regular fluoridation every three months.
- Moderate defect (atypical lesions mainly in coronal third of the crown; if breakdown is present it usually extends to 1–2 surfaces without cusps involved): If the tooth requires restoration, the soft tissue is removed. Hard tissue should not be removed due to color change alone. Otherwise treatment as with a mild defect.

- Extensive defect (post-eruptive breakdown, often hypersensitivity, may be associated with caries and may affect the pulp): The primary treatment is restoration with a crown (including SSC as an option) or restoration with indirect fillings.
- Defect extending to pulp (an X-ray indicates that the defect extends to the pulp; or the pulp is perforated during tooth preparation): Tooth extraction or pulpotomy and later extraction. Optimal extraction timing in the mandibula is when the crown development of the second permanent molar is completed and the root development is between beginning and half-way done, and in the maxilla before the second permanent molar has erupted.

Moreover, the guideline states that if an erupting FPM shows extensive MIH defects, it is recommended to protect the tooth with sealing or GIC filling. Once the tooth has erupted to occlusion, it can be restored with a permanent filling or crown. When restoring a hypomineralized tooth with RC or indirect filling, the adhesion should be done on healthy enamel and dentine. However, it is also instructed that hard, colored tissue does not have to be removed.

3 AIMS OF THE STUDY

The aim of this thesis was to investigate etiological factors of MIH in groups of Finnish children, concentrating on the living environment of the family and the child's illness and medication history, and to explore whether MIH is associated with an increased risk of dental caries taking into account the SES. Moreover, the MIH treatment practices among Finnish dentists were evaluated, in order to find out whether Finnish dentists follow the national guidelines when treating MIH patients and whether there are regional or other differences in treatment practices. Special emphasis was on the use of stainless-steel crowns.

The study hypotheses were:

- Illnesses or antibiotics in early childhood increase the risk of MIH (Study II).
- The prevalence of MIH is higher among children from higher socio-economic background (Study I).
- Dental caries is associated with MIH in first permanent molars, regardless of socio-economic status (Study III).
- Among Finnish dentists, stainless-steel crowns are not commonly used to treat symptomatic, hypomineralized first permanent molars with post-eruptive breakdown (Study IV).

4 STUDY SUBJECTS, MATERIALS, AND METHODS

4.1 STUDY SUBJECTS

4.1.1 STUDY POPULATION IN THE CLINICAL STUDIES (I, II AND III)

The Study I population was gathered from two sources (Figure 4). The other group consisted of children from Lammi, Jalasjärvi and Lappeenranta. Children from second to fifth grades (994 in total) from selected public schools were invited to participate in the study. The parents of 676 children (68%) approved the participation of their child in the clinical examination. The other group included children from the Oulu and Helsinki districts, a total of 167 children who had participated in a previous study focusing on the possible role of environmental toxicants on MIH (Laisi et al. 2008). They were originally recruited from maternity hospitals for a case-control study on the role of dioxins on cleft lip and cleft palate. One dentist, Sakari Laisi (SL) conducted the clinical examinations for both groups in the same manner. Parents from the Oulu and Helsinki districts had similarly approved the participation in the previous study. Thus, there were 843 eligible children. Further, 17 children were excluded due to unclear records and eight children because they had one or more unerupted FPMs, yielding to 818 final participants (Study I). The children were born between 1990–1999 and they were 7–13 years old at the time of the examination.

Lammi and Jalasjärvi are towns with less than 10,000 inhabitants each. Lammi is located in Southern Finland and Jalasjärvi in Western Finland. Lappeenranta is a city with a population of over 70,000 and located in an endemic fluoride area in Southeastern Finland. The pipe water in population centers, however, comes from a distance and contains less than 0.3 mg/L fluoride. Oulu is a city in Northern Finland with over 200,000 inhabitants. Helsinki has a metropolitan population of over one million and is located in Southern Finland.

Study II included 7- to 12-year-old children from Lammi (n = 140) and Jalasjärvi (n = 147) who had been born and living in the areas during their first four years of life and whose patient records from health centers were available. Because this was an etiological study, the children with low birth weight and childhood cancer were excluded to control for potential confounders (Figure 4).

Study III consisted of 261 children from Lappeenranta, 187 children from Jalasjärvi and 188 children from Lammi, altogether 636 children (64% of the invited children) who were examined for caries using the DMFT index (number of Decayed, Missing or Filled Teeth) (Figure 4). Children younger than eight years old were not included in the study to ensure that all FPMs were properly erupted.

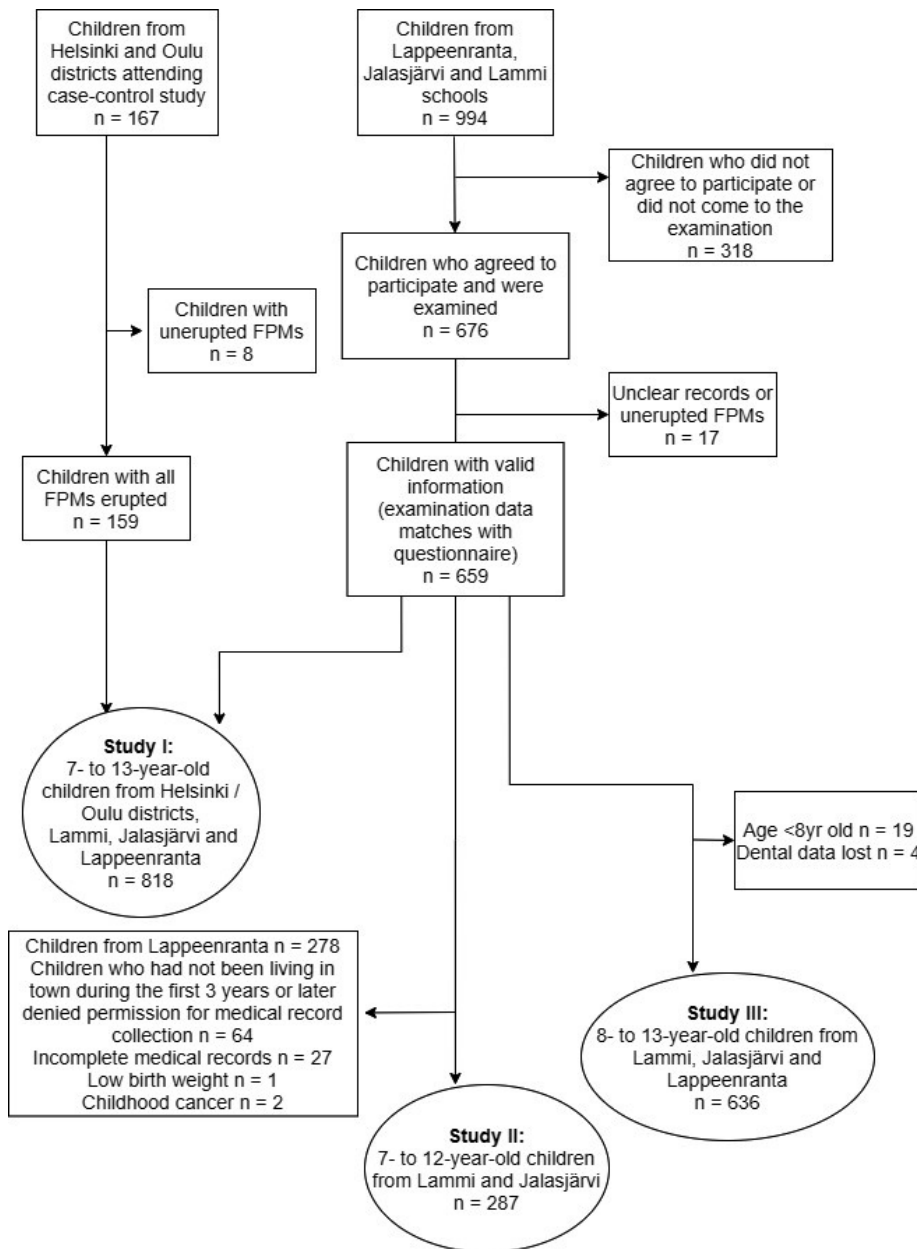


Figure 4. Flowchart showing the collection of the clinical study subjects.

4.1.2 DENTISTS PARTICIPATING IN THE SURVEY (STUDY IV)

The invitation to participate in the survey was sent via e-mail in February 2019 to all active members of the Finnish Dental Society Apollonia, a total of 3,840

dentists, including four authors of the study who were not eligible (Figure 5). Furthermore, 89 dentists did not have a valid e-mail address. Thus, a link to the electronic questionnaire (Questback Essential, Questback, Norway) was sent to 3,747 dentists. After one reminder, a total of 1,022 dentists replied to the questionnaire, yielding to a response rate of 27.3%. Figure 5 shows the reasons for further exclusions. The final number of participants was 765 (20.4% of the invited dentists) (Figure 5).

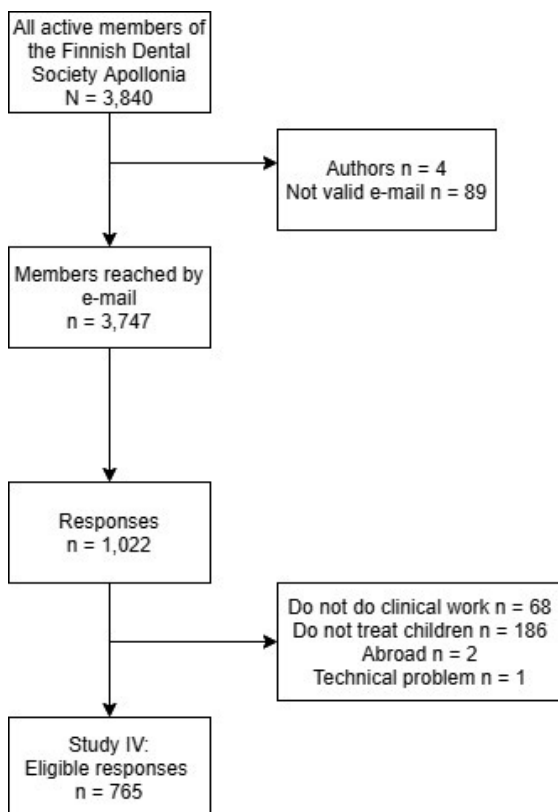


Figure 5. Flowchart showing the collection of the participants in the questionnaire survey.

4.2 MATERIALS AND METHODS

4.2.1 DENTAL EXAMINATION (STUDIES I, II, AND III)

One calibrated dentist (SL) performed all dental examinations in the dental clinic under standard dental lighting. According to the DDE and MIH examination guidelines (FDI Working Group 1992, Weerheijm et al. 2003),

the teeth were not dried, but the probe was used for plaque removal when necessary.

FPMs and permanent incisors were examined for MIH-characteristic hypomineralization defects, i.e. demarcated opacities, PEB, and atypical restorations replacing the affected dental hard tissue, in accordance with the judgement criteria for MIH, set by the European Academy of Paediatric Dentistry (EAPD) in 2003 (Weerheijm et al. 2003). Only lesions with a diameter of two millimeter or more were included. The diagnosis of MIH was set when a child had one or more FPMs affected with MIH-characteristic hypomineralization. There were no children with hereditary defects of dental hard tissues. In case of the partially erupted molars, only the visible tooth surfaces were examined.

Caries examination was conducted visually with the enhance of fiber-optic transillumination. The DMFT index was used to record caries in permanent teeth. Initial caries lesions, extractions due to orthodontic reasons and congenitally missing teeth were not included in the DMFT value. The diagnostic criteria for caries were in accordance with those of the WHO (World Health Organization 1997). Developmental defects or caries in primary teeth were not examined. The findings on MIH and dental caries were recorded manually on separate charts. The results of the dental examinations and the data gathered with the questionnaire were then combined in an electronic database.

The examiner (SL) was trained for recognizing MIH, diffuse opacities and hypoplasia by screening 21 subjects and calibrating with the gold standard, Satu Alaluusua (SA). The DDE index (FDI Working Group 1992) was used for the screening of diffuse opacities and hypoplasia. The inter-examiner kappa score between SL and SA for teeth with DDE (≥ 2 mm) was 0.96 and for classified defects (MIH, diffuse opacities and hypoplasia) it was 0.81. The intra-examiner kappa score was calculated by examining 20 children who participated in the study twice, at an interval of a few weeks, and the scores were 0.91 for teeth with DDE and 0.90 for classified defects. Similarly, the calibration was conducted for the screening of decayed teeth and the inter-examiner kappa score was 0.93 and the intra-examiner kappa score was 0.88.

4.2.2 QUESTIONNAIRE FOR PARENTS (STUDIES I AND III)

The study questionnaire was originally designed for the purpose of studying allergies and lifestyle (a mother-child research questionnaire by the Finnish National Public Health Institute). The parents answered the questionnaire in advance, and it was returned at the dental examination, along with the participation consent. The examiner was blind to the questionnaire

information. Among 72 questions included in the questionnaire, the following questions related to socio-economic background and living environment were selected for analysis:

- It was asked whether the family had a farm during the child's first year.
- The gross annual family income classified into six classes, from the lowest, less than 13,500€, to the greatest, more than 50,400€. When analyzing the results, the lowest three classes were combined, resulting in four categories.
- Education of the mother classified into four classes: primary and secondary school, vocational school or equivalent, high school or higher vocational school and college/university graduate. The first level also included obsolete forms of the 9-year-long Finnish basic education.
- Smoking: whether the mother had ever smoked regularly and whether the child had been exposed to tobacco smoke (from mother or someone in the household) during the child's first year of life.
- The child's day-care attendance during the first two years of life in a day-care center.
- Duration of breastfeeding.

4.2.3 MEDICAL RECORDS (STUDY II)

The medical history of the children from Lammi and Jalasjärvi was investigated using patient records (documents written by medical doctors which include a reason for the visit, examination methods, diagnosis, treatment and prescribed medicines) from the first four years of life. The documents were obtained from the public health centers in Lammi and Jalasjärvi, as well as from a private doctor, whose services some of the children from Jalasjärvi had used (n = 16). In most of the cases when a patient had been sent to the central hospital, medical records from the hospital visit were also included in the health center records.

The data collection was conducted in two parts. First, medication history from the first four years of life for children from Lammi was recorded and analyzed and the results were published in 2009 (Laisi et al. 2009). Second, to increase the power of the study and to include the illness history, the patient records for children from Jalasjärvi were also screened and data collected. Analysis of the illness and medication history were limited to the first three years of life, since this is when the enamel development of FPMs is completed on average. Since the mechanism of the hypomineralization is unclear, the possible etiological factors were studied in two different age periods: during the first year and during the first three years of life.

The records were screened for episodes of common childhood illnesses including acute otitis media (AOM) and upper and lower respiratory tract infections. In addition, more rare infections, such as gastroenteritis, urinary tract infections, and chickenpox were recorded. Because some illnesses may require several visits to a doctor, a new episode of an illness was considered to begin if there was a minimum time period of 21 days between separate events, unless the patient's disease was judged as cured by a physician at an earlier date (Fireman et al. 2003). A single visit may have resulted in more than one illness being reported (for example AOM and upper respiratory illness). Prescriptions for antibiotics were recorded and the classification was conducted according to their active agent as follows: penicillin, amoxicillin, cephalosporin, sulphonamide-trimethoprim, macrolide, and other agents. Moreover, prescriptions for following other medications were recorded: antitussives, bronchodilators, and antihistamines. Authors were blind to the MIH status of the children when screening the records.

The study II hypothesis assumes that childhood illnesses or their medications interfere with enamel formation at a certain developmental stage. To confirm the systemic nature of the disorder, an additional category of "MIH2" was set when a child had hypomineralization defects in 1–4 FPMs and 1–8 permanent incisors. The same definition was used in the etiological study by Kühnisch et al. (2014b).

4.2.4 QUESTIONNAIRE FOR DENTISTS (STUDY IV)

Study IV was part of a collaborative questionnaire study of Norwegian and Finnish dentists. The survey was first conducted among Norwegian dentists and then translated into Finnish (Uhlen et al. 2019). To ensure equivalent content, the questionnaire was also translated into English. A pilot study was conducted among ten Finnish dentists to test the suitability in local circumstances. The questionnaire consisted of the following:

- Background information: graduation year and country, age, gender, residency region divided into five areas (European Commission Eurostat, 2018), specialization status.
- How often the respondent recognizes DDE in patients, categorized as MIH, dental fluorosis or other: the options were "often (weekly or monthly)" or "seldom / never".
- A patient case was presented with a tooth photograph: a nine-year-old child with symptomatic enamel hypomineralization and post-eruptive breakdown in the mandibular FPM (Figure 6). No radiographs were presented. Treatment practices were evaluated by asking the respondent to choose from several treatment options. The alternatives were "no treatment", "treatment", or "referral to another dentist /

specialist”. The respondent was to further specify treatment by selecting from different material options [RC, conventional glass ionomer cement (CGIC), resin modified glass ionomer cement (RMGIC), polyacid-modified resin composite or compomer (PAMRC), zinc oxide eugenol (ZOE) and SSC] or tooth extraction. Furthermore, the respondent was to assess the relevance of the following factors that may affect the treatment decision with a 1- (not important) to 7- (very important) Likert scale: esthetics, patient co-operation, experience, available time, available materials, tooth prognosis, and the number of affected teeth.

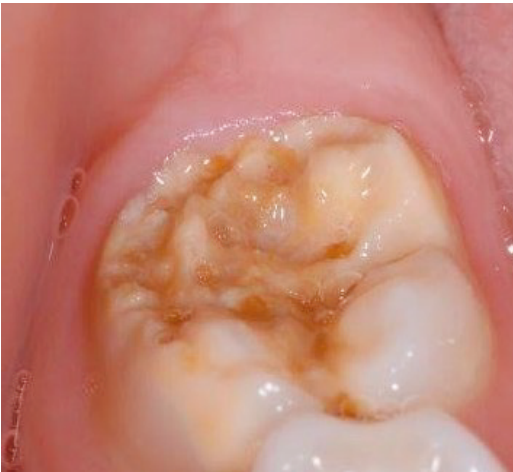

Figure 6: “A 9-year-old girl with hypomineralization and post-eruptive breakdown on tooth 46. She complains about discomfort and hypersensitivity. Good oral hygiene, normal occlusion. How would you like to treat this tooth?” The photograph was first published in Uhlen et al. 2019 and is reproduced under the terms of the Creative Commons Attribution 4.0 International License (<http://creativecommons.org/licenses/by/4.0/>).

4.2.5 STATISTICAL METHODS

The statistical analyses were conducted using IBM SPSS versions 18–24.0 (IBM Corp., Armonk, NY, USA). Statistical significance level of 0.05 was used.

In Study I, depending on the variable characteristics, the Pearson Chi-Square test, Fisher’s Exact test and Mann-Whitney U-test were used to test the statistical significance of the associations between MIH and study variables. A binary logistic regression was used to perform multivariable analysis between MIH and associated factors ($p < 0.05$).

In Study II, the effect of illnesses and medications on the risks of MIH and MIH2 were calculated using binary logistic regression analyses. In addition, the increase in the risks of MIH and MIH2 with every extra episode of illness or course of medications were calculated using binary logistic regression. In the adjusted analyses, age and region were used as possible confounders.

The statistical analysis in Study III included descriptive statistics of MIH on the tooth level, caries rates and SES factors, including normality tests and Chi-Square tests of independence. Pairwise comparisons using z-test with Bonferroni method for adjusted p-values were conducted in cases of significant associations. To test the Study III hypothesis, the outcome was determined by the following variables: the DMFT value in FPMs, ranging from 0 to 4, and the caries experience in FPMs (DMFT = 0 vs. DMFT > 0). MIH was an exposure variable. The possible confounding factors were two variables that define SES (family income and mother's education level) as well as age and region. The difference in the DMFT value in FPMs between children with and without MIH was evaluated statistically using the Kruskal-Wallis 1-way ANOVA test. The statistical significance of the association between SES and caries experience in FPMs (DMFT > 0) was assessed using the Pearson Chi-Square test. The generalized linear mixed model analysis with logit link was conducted to find out the association between the outcome (caries experience in FPMs) and the exposure variable (MIH) considering the confounding factors. Different models were created attempting to alternately include one of the SES variables, but a model including both SES variables was found to fit best. Adjusted odds ratios (ORs) and 95% confidence intervals (CI) were calculated.

In Study IV, the statistical significance of the associations between respondents' background variables and their treatment choices were evaluated using the Pearson Chi-Square test or the Fisher's Exact test. The Mann-Whitney U-test was used in case of ordinal variables. The relevance of the factors which may affect the treatment choice was calculated using Likert scale median and interquartile range (IQR).

4.2.6 ETHICAL CONSIDERATIONS

Parents of the children approved the participation of the children in the clinical examination. Caries diagnostics did not include radiography. The Ethics Committee at South Karelia Hospital District, Lappeenranta, Finland, approved the study (A02/03), as well as the basic service public utility federation of municipalities JIK (Jalasjärvi, Ilmajoki, Kurikka), the Lammi-Tuulos federation of municipalities who provided permission to obtain medication and illness data from the health centers. The permission to screen

the patient records of the private doctor was obtained from those who had used his services.

In Study IV, participation was voluntary, and the respondents did not receive any compensation. The questionnaire was anonymous. The Norwegian Social Science Data Services approved the original study design.

5 RESULTS

5.1 BACKGROUND FACTORS OF MIH (STUDY I)

The study sample consisted of 818 children. The children were 7–13 years old and the mean age was 10.0 years (SD 1.5). There were 140 children with MIH (17.1%). Of them, 56% (n = 78) had at least two affected FPMs. Age or birth year did not differ between the children with and without MIH (p = 0.499 and 0.336).

Table 3 shows the background characteristics of the study population in regard to the diagnosis of MIH. In the univariate analysis, the study location was associated with MIH. In Lappeenranta, the prevalence of MIH was 25.2%, which was higher than in other locations, 8.0% in Jalasjärvi, 16.5% in Lammi and 14.5% in Oulu / Helsinki districts. In addition, there were more children with MIH in the highest income group than in the lowest income group. Day-care attendance during the first two years of life was associated with MIH (OR 1.86, 95% CI 1.19–2.90).

Table 3. *Background factors of the children with Molar-Incisor Hypomineralization (MIH) or without (Non-MIH)*

Characteristic	Non-MIH	MIH	Total	p
Number of children	678	140	818	
Gender				.625
Boys	343 (50.6)	74 (52.9)	417 (51.0)	
Girls	335 (49.4)	66 (47.1)	401 (49.0)	
Location				< .001
Jalasjärvi	172 (25.4)	15 (10.7)	187 (22.9)	
Lammi	162 (23.9)	32 (22.9)	194 (23.7)	
Lappeenranta	208 (30.7)	70 (50.0)	278 (34.0)	
Oulu/Helsinki districts	136 (20.1)	23 (16.4)	159 (19.4)	
Farming				.116
No	580 (86.3)	125 (91.2)	705 (87.1)	
Yes	92 (13.7)	12 (8.8)	104 (12.9)	

Table 3 cont'd. Background factors of the children with Molar-Incisor Hypomineralization (MIH) or without (Non-MIH)

Characteristic	Non-MIH	MIH	Total	p
Mother's education				.752
Prim. & second. school	88 (13.2)	22 (15.8)	110 (13.7)	
Vocational school	166 (24.9)	33 (23.7)	199 (24.7)	
High school/ higher vocational school	310 (46.5)	60 (43.2)	370 (46.0)	
University	102 (15.3)	24 (17.3)	126 (15.7)	
Family income, €				.032
< 25,200	138 (24.3)	19 (16.0)	157 (22.9)	
25,200-33,600	111 (19.6)	16 (13.4)	127 (18.5)	
33,600-50,400	153 (27.0)	38 (31.9)	191 (27.8)	
> 50,400	165 (29.1)	46 (38.7)	211 (30.8)	
Mother ever smoked regularly				.651
No	414 (61.3)	83 (59.3)	497 (61.0)	
Yes	261 (38.7)	57 (40.7)	318 (39.0)	
Exposure to tobacco smoke < 1-year-old (from the mother smoking)				.897
No	560 (85.1)	116 (84.7)	676 (85.0)	
Yes	98 (14.9)	21 (15.3)	119 (15.0)	
Exposure to tobacco smoke < 1-year-old (from someone smoking in the family)				.590
No	388 (58.7)	77 (56.2)	465 (58.3)	
Yes	273 (41.3)	60 (43.8)	333 (41.7)	
Day-care attendance during the first 2 years of life				.006
No	562 (85.3)	103 (75.7)	665 (83.6)	
Yes	97 (14.7)	33 (24.3)	130 (16.4)	
Breastfeeding, mo.	7.5 (5.4)	6.5 (4.3)	7.3 (5.2)	.092 ^a
Breastfeeding only, mo.	3.1 (2.0)	3.2 (2.0)	3.1 (2.0)	.881 ^a
Data are presented as the mean (SD) or n (%). P-values were obtained by using the Pearson Chi-Square/Fisher's Exact or Mann-Whitney U-test ^a (refers to differences in mean rank instead of reported means).				

In the binary logistic regression analysis, study location was the only factor to remain significantly associated with MIH (Table 4).

Table 4. Analysis of Molar-Incisor Hypomineralization as a dependent variable and background factors as independent variables in a binary logistic regression.

Variable	Categories	B	P	OR	95% CI
Location	Lappeenranta (ref.)		.001	1	
	Lammi	-.72	.010	.48	.28-.84
	Jalasjärvi	-1.07	.001	.34	.18-.66
	Helsinki / Oulu districts	-.70	.014	.50	.29-.87
Family income, €	< 25,200		.200	1	
	25,200-33,600	.18	.623	1.21	.58-2.50
	33,600-50,400	.51	.112	1.66	.89-3.09
	> 50,400	.61	.052	1.84	.99-3.39
Day care attendance during the first 2 years	Yes	.34	.134	1.47	.89-2.45
No of cases included in the analysis: 667. Nagelkerke R Square 0.068.					

5.2 THE ASSOCIATION BETWEEN MIH AND CHILDHOOD ILLNESSES AND MEDICATIONS (STUDY II)

The Study II sample consisted of 140 children from Lammi and 147 children from Jalasjärvi, whose patient records from the first three years of life were obtained. Figure 7 shows the number of children with certain illnesses and medications during the first three years of life. There were 33 children with MIH (11.5%), and the prevalence of MIH was significantly higher in Lammi (16.4%) than in Jalasjärvi (6.8%, $p = 0.011$). The prevalence of MIH₂ was 7.9% in Lammi and 4.8% in Jalasjärvi, and the difference was not statistically significant ($p = 0.280$).

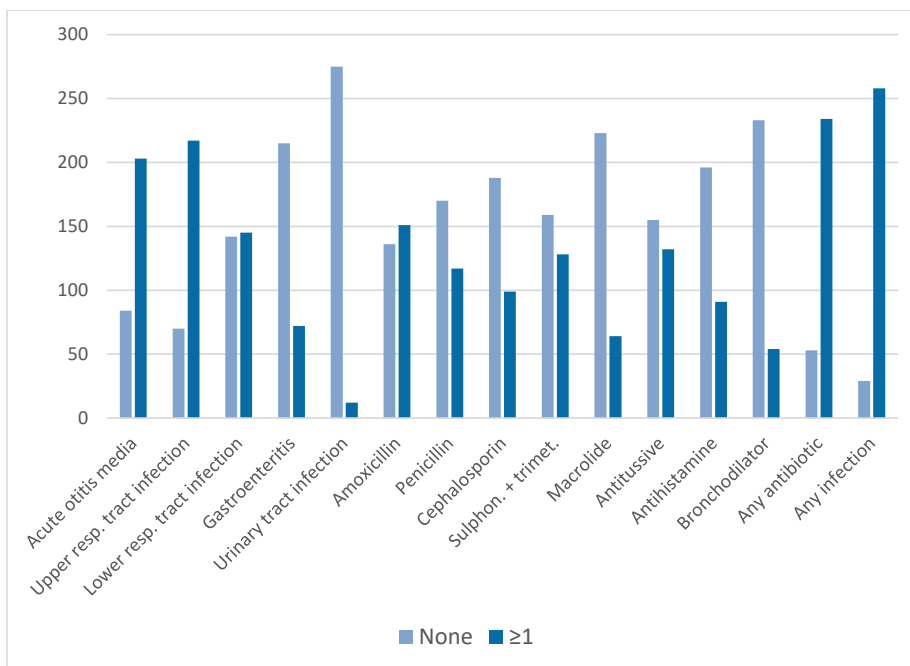


Figure 7. The number of children with certain illnesses and medications during the first three years of life, recorded from their patient files. Sulphon. + trimet.: sulphonamide and trimetoprim.

5.2.1 CHILDHOOD ILLNESSES

In binary logistic regression analysis, age- and location-adjusted associations showed that children who had suffered from at least one episode of AOM within the first year of life had a 2.28 times higher risk for MIH compared to the children who had not suffered from AOM during their first year ($p = 0.035$). Children who had received penicillin also had a 2.62 times higher risk for MIH₂, but this was not statistically significant ($p = 0.056$). The risk of MIH was increased by 42% ($p = 0.023$) and the risk of MIH₂ by 50% ($p = 0.023$) with every extra episode of AOM within the first year of life. Within the first three years of life, every extra episode of AOM increased the risk of MIH by 19% ($p = 0.009$) and MIH₂ by 18% ($p = 0.039$). Other illnesses did not increase the risk of MIH or MIH₂, but when considering all illnesses together, every extra episode of any illness within the first year of life increased the risk of MIH by 8% ($p = 0.025$).

5.2.2 MEDICATIONS

Age- and location-adjusted associations in the binary logistic regression analysis showed, that children who had received at least one course of penicillin within the first year of life had a 2.61 times higher risk for MIH ($p = 0.019$) and a 3.16 times higher risk for MIH2 ($p = 0.029$) compared to the children who had not received penicillin within the first year of life. The risk of MIH was increased by 92% ($p = 0.039$) and the risk of MIH2 by 120% ($p = 0.049$) with every extra course of penicillin during the first year of life. Children who had received at least one course of amoxicillin within the first three years of life had a 2.58 times higher risk for MIH ($p = 0.022$) and a 3.16 times higher risk for MIH2 ($p = 0.048$). The risk of MIH was increased by 35% ($p = 0.008$) and the risk of MIH2 by 32% ($p = 0.042$) with every extra course of amoxicillin during the first three years of life. The use of macrolides (at least one course) within the first year of life increased the risk of MIH 4.07 times compared to those who had not received any macrolide antibiotic during their first year ($p = 0.011$). The risk of MIH was increased by 210% ($p = 0.012$) with every extra course of macrolide antibiotic during the first year of life. In addition, the exposure to macrolides (at least one course) during the first three years of life increased the risk of MIH by 2.57 times compared to those who had not received macrolide antibiotic during that time ($p = 0.027$). Every extra course of macrolides during the first three years increased the risk of MIH by 92% ($p = 0.011$). The risk of MIH2 was also increased, but the association was not statistically significant.

Other antibiotics did not increase the risk of MIH or MIH2 significantly, but when all antibiotics were grouped together, every extra course of any antibiotic within the first year of life increased the risk of MIH by 28% ($p = 0.024$) and within the first three years by 14% ($p = 0.007$). Similar statistically significant risk was not found for MIH2.

Of other medications, antitussives within the first year of life were associated with MIH in univariate analysis, but the association was not significant in the adjusted analysis. Every extra course of antihistamines during the first three years of life increased the risk of MIH by 57% ($p = 0.011$).

5.3 THE ASSOCIATION BETWEEN MIH AND DENTAL CARIES, SES AS A CONFOUNDING FACTOR (STUDY III)

The sample consisted of 636 children. They were 8–13 years old, and the mean age was 10.5 years (SD 1.4). There were 115 children with MIH (18.1%). The

Results

mean age did not differ between children with and without MIH ($p = 0.848$). Table 5 shows the distribution of the study variables between children with and without MIH.

The number of MIH-affected FPMs was 225, of which 63.6% ($n = 143$) were maxillary and 36.4% were mandibular FPMs ($n = 82$). The mean number of affected FPMs among children with MIH was 2.0 (SD 1.1).

Table 5. *Distribution of study variables between children with and without Molar-Incisor Hypomineralization (MIH).*

Variable	non-MIH	MIH	Total	<i>p</i>
Children	521	115	636	
DMFT value	0.46 (1.12)	1.17 (1.39)	0.59 (1.21)	< .001 ^a
DMFT in FPMs	0.32 (0.80)	1.03 (1.25)	0.45 (0.94)	< .001 ^a
Region				< .001
Lammi	156 (29.9)	32 (27.8)	188 (29.6)	
Jalasjärvi	172 (33.0)	15 (13.0) *	187 (29.4)	
Lappeenranta	193 (37.0)	68 (59.1) *	261 (41.0)	
Family income, €				.037
< 25,200	117 (27.0)	16 (16.7) *	133 (25.1)	
25,200–33,600	90 (20.8)	15 (15.6)	105 (19.8)	
33,600–50,400	123 (28.4)	32 (33.3)	155 (29.3)	
> 50,400	103 (23.8)	33 (34.4) *	136 (25.7)	
Mother's education				.357
Prim. & second. school	74 (14.5)	20 (17.5)	94 (15.0)	
Vocational school	146 (28.5)	29 (25.4)	175 (28.0)	
High school/ higher vocational school	232 (45.3)	46 (40.4)	278 (44.4)	
University	60 (11.7)	19 (16.7)	79 (12.6)	
Data are presented as n (%) or mean (SD). * a subset of MIH category whose column proportions differ significantly from each other (z-test with Bonferroni method). P-values from Pearson Chi-Square test or Kruskal Wallis 1-way ANOVA test ^a (refer to differences in mean rank instead of reported means).				

The overall caries prevalence (DMFT > 0) in the sample was 27.8% ($n = 177$ children). The prevalence of caries in FPMs was significantly higher among the children with MIH than among children without MIH (52.2% vs. 17.9%, OR 5.02, 95% CI 3.27–7.71). Also, the mean DMFT value in permanent dentition and the DMFT value in FPMs were significantly higher among children with MIH than among children without MIH (Table 5).

Of the 225 FPMs with MIH, 55 had atypical restorations or demarcated opacities with caries and were deduced to be affected by caries (24.4%). This was more prevalent in the mandibular (27 out of 82) than in the maxillary (28 out of 143) FPMs with MIH (32.9% vs. 19.6%, $p = 0.026$, z -test). However, among the 115 children with MIH, the likelihood of an FPM with an MIH defect to be affected by caries was not higher than that of an FPM without an MIH defect ($p = 0.562$, Chi-Square test).

In a generalized linear mixed model analysis, where caries in FPMs was an outcome variable and location, age, and both SES variables were taken into account as confounders, MIH was associated with caries with the OR of 6.6 compared to the children without MIH. Other significant caries risk indicators were age, location and family income (Table 6).

Table 6. *The generalized linear mixed model analysis of caries in FPMs (DMFT = 0 / DMFT > 0) as a dependent variable and its risk indicators as covariates.*

Variable	Categories	Coefficient	OR (95% CI)	p-Value
MIH	MIH	1.88	6.60 (3.83–11.39) **	0.000
Age	Years	0.25	1.29 (1.08–1.53) **	0.004
Region	Lammi (reference)	0	1	
	Jalasjärvi	1.29	3.62 (1.67–7.87) **	0.001
	Lappeenranta	0.88	2.41 (1.16–4.99) *	0.018
Family income, €	<25,200 (ref)	0	1	
	25,200–33,600	–0.50	0.61 (0.30–1.25)	0.177
	33,600–50,400	–0.93	0.39 (0.20–0.78) **	0.008
	>50,400	–0.47	0.63 (0.30–1.32)	0.217
Mother's education	Prim. & second. school (ref)	0	1	
	Vocational school	0.58	1.79 (0.79–4.07)	0.166
	High school / Higher vocational school	–0.0.3	0.97 (0.42–2.22)	0.944
	University	0.06	1.06 (0.38–2.96)	0.909

The generalized linear mixed model with logit link. The model has its own random slopes socioeconomic status (SES) variables in relation to locality, as well as its own intercept for each subject. The exponential coefficient is presented as ORs. No. of cases included in the analysis: 525. Information criterion, Akaike Corrected was 2,530.765. * $p < 0.05$, ** $p < 0.01$. MIH: Molar-Incisor Hypomineralization.

Reproduced and adapted from Wuollet E, Laisi S, Alaluusua S, Waltimo-Sirén J. The association between Molar-Incisor Hypomineralization and dental caries with socioeconomic status as an explanatory variable in a group of Finnish children. *Int J Environ Res Public Health* 2018, 15: 1324, under the terms of the Creative Commons Attribution 4.0 International License (<http://creativecommons.org/licenses/by/4.0/>).

5.4 QUESTIONNAIRE SURVEY FOR DENTISTS (STUDY IV)

Of the participating 765 dentists, 80.8% were women (n = 618). Three of four dentists mainly worked in the public sector (75.6%, n = 578). A minority treated children full-time (13.2%, n = 101) and half of the respondents (48.9%, n = 374) weekly, whereas the rest (37.9%, n = 290) treated children only occasionally. Nearly all (92.4%, n = 707) had graduated from Finland. A specialized degree was held by 57 dentists (7.4%), and the main specialization fields were the following: prosthodontics 21.1% (n = 12), pediatric dentistry 17.5% (n = 10), orthodontics 17.5% (n = 10), periodontics 15.8% (n = 9) and cariology / endodontics 12.3% (n = 7).

Two-thirds of the participating dentists (69.4%, n = 531) reported they recognize MIH frequently (weekly, monthly). Dental fluorosis and other mineralization defects were less frequently encountered, since those were recognized frequently by 32.4% (n = 248) and 39.5% (n = 302) of the respondents, respectively. MIH was recognized frequently significantly more likely among public sector workers, than among private sector workers (74.2% vs. 54.5%, $p < 0.001$). Additionally, a significantly higher proportion of women in comparison to men reported to recognize MIH frequently (72.2% vs. 57.8%, $p = 0.001$). It is also noteworthy, that a higher proportion of women (80.3%) than of men (55.8%) were employed in the public sector ($p < 0.001$). Moreover, the older and earlier graduated dentists recognized MIH frequently more likely than the younger and most recently graduated dentists ($p < 0.001$, both). This association was not explained by the working sector.

The figure 8 shows treatment decisions for a symptomatic, hypomineralized FPM with PEB. Of the 765 respondents, 550 (71.9%) chose to restore the symptomatic, severely hypomineralized FPM. RC was the most preferred material, covering 62.5% of the material choices (n = 344). SSC was chosen by 80 respondents (14.5% of the material choices). Of those who chose SSC, 56.3% (n = 45) would prepare the tooth before placing the SSC. Less than one third (28.8%, n = 23) would not prepare the tooth and 15.0% (n = 12) reported they don't know how to use SSC in this case. SSC as a material choice was associated with the education level, since pediatric dentists and other specialized dentists had a clear preference for SSC compared to general dentists (75.0% and 45.2% vs 11.7% respectively, $p < 0.001$). The younger dentists chose SSC more likely than the older dentists ($p = 0.003$). As far as regional differences regarding treatment decisions, in the Helsinki-Uusimaa area, 34.8% of the dentists would have referred the patient forward, compared to 15.9%–17.4% of the dentists from other areas in mainland Finland ($p < 0.001$). Moreover, women were more likely to refer the patient forward than men (24.3% of women vs. 12.9% of men, $p = 0.006$).

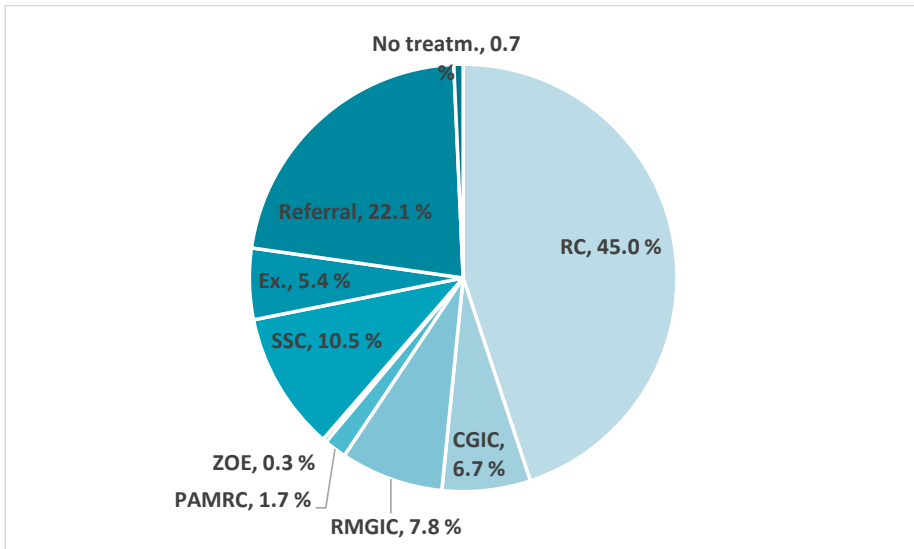


Figure 8: The respondents' treatment choices for a symptomatic, hypomineralized FPM with PEB, n=765. RC: resin composite, CGIC: conventional glass-ionomer cement, RMGIC: resin-modified glass-ionomer cement, PAMRC: polyacid-modified resin composite or compomer, ZOE: zinc oxide eugenol, SSC: stainless-steel crown, Ex.: Extraction, Referral: Referral to another dentist or specialized dentist, No treatm.: No treatment.

The respondents rated esthetics and available time as the least important factors affecting treatment decisions (median 4, IQR 3, both, Figure 9). Tooth prognosis was ranked as the most important factor (median 6, IQR 1).

Results

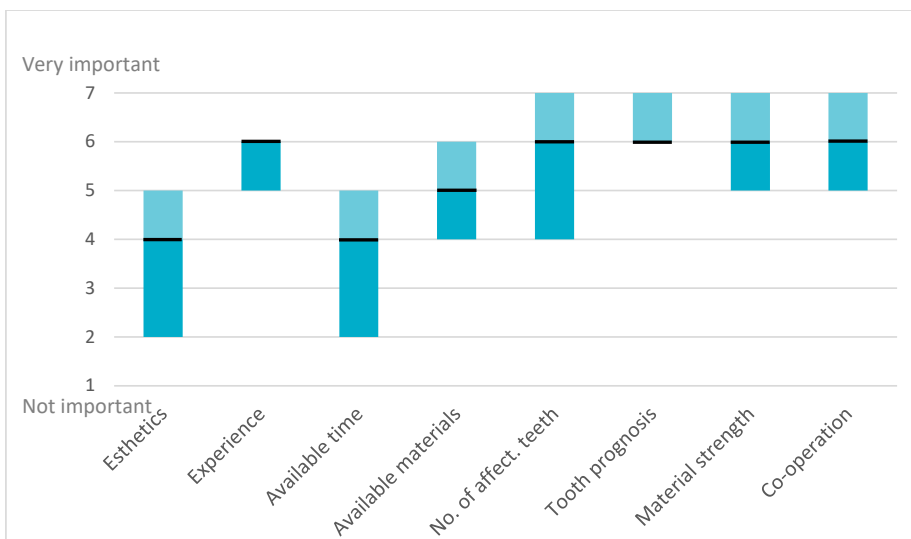


Figure 9: Relevance of the factors affecting the treatment decision, reported as a median value (black line) of the answers in the Likert scale from 1 (not important) to 7 (very important). Boxes show interquartile ranges (IQR), Q1 (25th percentile) in darker color, Q3 (75th percentile) in lighter color. If either box is missing, its value is the same as the median.

6 DISCUSSION

6.1 BACKGROUND FACTORS OF MIH

The original Study I hypothesis arose from the clinical observation that MIH seemed to be more common among families from higher socioeconomic background. This was supported by a British study, where MIH prevalence was lower in the areas with more deprivation (Balmer et al. 2012). However, the results of the present study did not support the original hypothesis. Prevalence of MIH differed between the study locations, but this was not explained by SES. Similarly, in New Zealand, two groups of children, from central Wellington and the nearby Wainuomata area, were examined for MIH and a small difference in MIH prevalence was found, but it was concluded that SES, measured through school decile, was not associated with MIH (Mahoney & Morrison 2011). As in our study, family income or parental education or both have been used to measure SES in a few other studies with no significant association between them and MIH (Jeremias et al. 2013a; Kühnisch et al. 2014b; Oyedele et al. 2015; Davenport et al. 2019) with one exception where MIH was more prevalent on the tooth level among families with higher incomes (Teixeira et al. 2018).

The overall prevalence of MIH in the Study I population was 17.1%, which is close to the earlier found prevalence of 19.3% among Helsinki school children (Leppäniemi et al. 2001). Interestingly, this study found a significantly higher prevalence of MIH in Lappeenranta than in other locations. The greatest prevalence difference was observed between Jalasjärvi and Lappeenranta, with 8.0% in Jalasjärvi and 25.2% in Lappeenranta. The study locations differed also in other aspects: in Jalasjärvi, more families belonged to the lower income and less educated groups than in other regions. However, since the study locations were not randomly chosen, the findings cannot be generalized to the Finnish population or to any particular area. Nevertheless, one dentist conducted all examinations, and the prevalence differences are comparable between the study locations.

Regional differences in MIH prevalence have also been reported in other studies from different countries. In Bosnia-Herzegovina, MIH prevalence differed between nine study locations (Muratbegovic et al. 2007). Examiner calibration status was not reported, however. A German study found prevalence differences between four regions ranging from 4.3% to 14.6% (Petrou et al. 2014). In Greece, the prevalence of MIH was lower in one region compared to two other regions (16% vs. 23%) (Kevrekidou et al. 2015). In Japan, MIH was more prevalent in southwestern areas than in northeastern areas (Saitoh et al. 2018). The prevalence figures ranged from 11.7% to 28.1%.

Moreover, a Brazilian study detected differences in MIH prevalence between children from rural and urban areas of the city of Botelhos (Da Costa-Silva et al. 2010). The prevalence of MIH was smaller in the fluoridated urban area (fluoride content 0.7 ppm/F) than in the non-fluoridated rural area (natural fluoride level below 0.1 ppm/F) (17.6% vs. 24.3%). Fluoride levels in drinking water also varied between the locations of this study: in Jalasjärvi, fluoride levels in drinking water were naturally high, 0.5–1.0 mg/L, whereas in other regions it was reported by local waterworks to be below 0.3 mg/L in the communal pipe water. However, the interpretation of water fluoride levels should be done with caution, since the source of drinking water for individuals may not be communal pipe water but, for example, private wells with different or unknown levels of fluoride. Currently, a general perception is that MIH prevalence is not associated with the water fluoride content (Koch 2003; Weerheijm et al. 2003), but the prevalence of diffuse opacities does increase with the higher fluoride content (Ekanayake & van der Hoek 2002).

Originally, it was speculated that one possible link between MIH and high SES could be the exposure to environmental toxicants through mother's milk, since more educated mothers breastfeed longer than less educated mothers (Uusitalo et al. 2012). Although an association between hypomineralized FPMs and long breastfeeding was previously observed in Finland (Alaluusua et al. 1996a), it has not been repeated elsewhere, except for Fagrell et al. (2011) who suggested that long breastfeeding results in the lack of nutrients and therefore could interfere with enamel development. In the present study, the duration of breastfeeding was not associated with MIH.

One nutrition-related factor that could be associated with enamel development is vitamin D, which controls the serum calcium and phosphate levels. In Finland, the exposure to UVB radiation from sunlight is insufficient for cutaneous vitamin D synthesis during the winter, from October to March (O'Neill et al. 2016). Therefore, vitamin D supplements are recommended (10 mcg/day for children under two years old as well as pregnant and lactating women, 7.5 mcg/day for children 2–18 yrs and for those who do not eat fish or products fortified with vitamin D) (Finnish Food Authority, 2010). In addition, starting in 2003, fluid milk and spreadable fats have been supplemented with vitamin D, but this began after the children participating in this study were born. However, vitamin D supplementation compliance in Finland is very high (86% of the one-year-olds and 70% of the two-year-olds (Kyttälä et al. 2010). A recent study indicates that a higher dose of vitamin D during the third trimester of pregnancy could be a protective factor against MIH (Nørrisgaard et al. 2019). Possible differences in dietary habits and the use of vitamin D supplementation may explain the regional MIH prevalence differences detected in other studies as well (Saitoh et al. 2018).

Genetic factors should be considered when regional prevalence differences are detected. Finland has historically been not only an isolated country, but also a country with isolated areas, and therefore genetic differences between areas in Finland exist (Kerminen et al. 2017). Since it is likely that the genetic differences play a role in enamel development and susceptibility to developmental defects, regional differences in the prevalence of MIH could also be due to genetic reasons. However, it is assumed that current living conditions or medications are associated with the development of MIH, as in anthropological dental specimens, MIH was nearly absent but linear enamel hypoplasia was common (Kühnisch et al. 2016).

6.2 THE ASSOCIATION BETWEEN MIH AND CHILDHOOD ILLNESSES AND ANTIBIOTICS

The results of this study strengthen the hypothesis that childhood illnesses and antibiotics increase the risk of MIH. However, due to the high correlation between antibiotics and illnesses and the low number of subjects, it is not possible to distinguish whether the association is due to antibiotics or due to illnesses. Further prospective studies are needed to draw conclusions. Somewhat supportive findings were found by Kühnisch et al. (2014b), where at least one course of bronchial asthma, bronchitis, pneumonia or croup during the first four years of life registered prospectively, increased the risk of MIH₂ by nearly 2.5 times. In that study, enamel hypomineralization lesions were recorded for all permanent teeth, and a wide variation in the distribution pattern was found. Authors point out that for etiological studies on MIH, more research is needed to accurately determine the clinical phenotype of the outcome. This, along with the retrospective study setting, may be a reason for the conflicting results on the etiology of MIH in this study as well as in other studies. The results, however, agree with the concept of the multifactorial nature of DDE (Figure 2).

6.3 THE ASSOCIATION BETWEEN MIH AND DENTAL CARIES

Caries prevalence is higher among individuals with DDE (Vargas-Ferreira et al. 2015; Opydo-Szymaczeka et al. 2018). This study further supports the association between MIH and caries experience in a group of Finnish children. MIH was associated with caries in FPMs with adjusted odds ratio of 6.6-fold compared to children without MIH. A similar association was found in a Brazilian case-control study (Grossi et al. 2017), where the cases had a remarkably higher prevalence of caries in permanent dentition, even though the caries prevalence in primary dentition was the same between the groups. In addition, they reported that the teeth clinically affected by MIH are more

susceptible to caries than are non-affected teeth of the same patient. In MIH patients of this study, the FPMs without clinically visible hypomineralization were restored or decayed as likely as the hypomineralized FPMs. The retrospective nature of the study must be considered, but this suggests that caries risk in MIH patients is increased not only because of the altered properties of hypomineralized enamel, but possibly also because increased sensitivity of hypomineralized teeth causes difficulties in maintaining the proper level of dental hygiene. Without going further into the etiology of caries, it may be suggested that if the hypomineralized FPM is not properly brushed and plaque composition becomes more cariogenic, it can contribute to caries progression in other teeth. Moreover, a genetic predisposition, which would increase both the risk of DDE and dental caries can be hypothesized and requires more research. Notably, this study shows that MIH is a greater risk indicator for caries in FPMs than SES, even though low SES, measured using both family income and parental education level, is known to correlate with higher caries rates (Kumar et al. 2016). A child with enamel hypomineralization in FPMs should be treated as a high caries risk patient and offered caries-preventive measures as well as frequent follow-up visits to dental care. This is in line with the Finnish Current Care guideline (2018), which instructs to apply fluoride varnish every three months and seal mild hypomineralization lesions.

6.4 DENTISTS' PERCEPTIONS ON THE TREATMENT OF HYPOMINERALIZED MOLAR

According to this survey, Finnish dentists who take care of children or adolescents, especially those who work in the public sector, encounter MIH frequently. The survey participants preferred mostly RC for the restoration of the hypomineralized, symptomatic MIH molar. In the Norwegian study, dentists were more heterogenous in their treatment options, but RC was the most popular material there as well (Uhlen et al. 2019). RC restorations may survive well in FPMs affected by MIH (Lygidakis et al. 2003; Mejàre et al. 2005). However, the preparation technique may affect the longevity of the RC restoration (Sönmez & Saat 2017; De Souza et al. 2017). In this survey, preparation techniques were not evaluated. The Finnish Current Care Guidelines instructs that when preparing a hypomineralized tooth, the hard, colored tissue does not have to be removed, but the adhesion should be made on sound enamel and dentine. Unclear instructions reflect a situation where the evidence is not sufficient for more specific guidelines. The respondents of this survey were also confused about how much tissue should be removed, which emerged in the open comments on the questionnaire. Presumably, the use of 5% sodium hypochlorite could further improve the prognosis of RC restoration on MIH-affected teeth (Ekambaram & Yiu 2016 ; Sönmez & Saat 2017).

While the Finnish Current Care guideline lists SSCs as the primary choice for treating FPMs severely affected by MIH along with other indirect crowns, in the present study, SSC was not a common treatment choice among Finnish dentists. However, specialized dentists were more likely to choose SSC than general dentists. This is not surprising considering the similar tendency with managing primary molars extensively affected by caries (Tseveenjav et al. 2018). Similarly, in questionnaire surveys from the US and the UK, SSCs were the most preferred restorative options for MIH affected teeth among pediatric dentists (Tagelsir et al. 2018; Taylor et al. 2019). Due to the material thinness, SSCs are well suited for newly erupted FPMs, but it has also been calculated that optimally scheduled extraction may be a more cost-effective option, especially if the occlusion is favorable for the spontaneous space closure (Elhennawy et al. 2017a). However, those estimates are based on the German healthcare system and a similar analysis is lacking for the Finnish health care system.

Moreover, treatment decisions varied between different regions. In the urban Helsinki-Uusimaa area, a significantly greater proportion of dentists would have referred a patient forward than in other areas in mainland Finland. According to a few open comments, it is easy to refer a patient with MIH if a specialist is located in the same municipality. It is possible that in regions other than the Helsinki-Uusimaa area, long distances between basic and specialized dental care affect the decision to refer a patient. It can also be presumed that a reason for referral is an estimated need of treatment under nitrous oxide sedation or general anesthesia due to MIH-associated severe hypersensitivity, although this aspect did not arise in the open comments. Overall, specialized dentists are divided rather equally based on population, according to the statistics from the Finnish Dental Association (The Finnish Dental Association 2018a). However, there are only twenty-some pediatric dentists in Finland. The number of pediatric dentists varies between hospital districtis, and half of the hospital districts have no pediatric dentist at all (The Finnish Dental Association 2018a). It is documented that in Finland, regional differences exist, for instance, in the proportion of children receiving orthodontic care (National Institute for Health and Welfare 2019). Another regional feature in the metropolitan area is that for the treatment of more demanding patients there is a special unit for specialist dental care (Capital region and Kirkkonummi unit for special dental care) maintained by the municipalities and therefore the patient is not committed to the hospital for pediatric dentist.

6.5 LIMITATIONS OF THE STUDY MATERIAL

The Study I sample was gathered from two sources using different methods, as one sample was a cohort and the other was a case-control study, although not originally intended to study MIH, but rather, cleft lip and cleft palate. Nevertheless, the original case-control setting did not affect the status of MIH. Also, one dentist conducted the dental examinations for both groups.

In Study II, one limitation is that the recording of the exposure variables was not calibrated but based on the retrospective analysis of the patient records. Therefore, the occurrence of illnesses in particular can contain gaps since many childhood illnesses are mild and do not require visit to a doctor and hence were not included in this data leading to possible under-reportance of such illnesses. Moreover, there may be variation between families in how readily a child is brought to a doctor. The exposure to antibiotics, however, ought to be more reliable. In small towns like Jalasjärvi and Lammi, the use of private health services is limited, and most families visit the doctor at the public health center. The data were obtained also from the private doctor whose services some of the children in Jalasjärvi had used. However, because of the unexpectedly low prevalence of MIH in Jalasjärvi, the power of the study may have been too low to detect all significant associations between MIH and illnesses or antibiotics.

In Study III, caries experience was observed using the DMFT index, even though the F component could have been due to enamel breakdown and not caries. Moreover, the observer bias cannot be ruled out since both MIH and DMFT are examined by visual inspection. Separate charts were used, however, to record caries/fillings and DDE. Another limitation to note is that some of the children already had full permanent dentition and the caries status in primary teeth remained unknown. The caries status of primary dentition would have added value to the study results. Finally, it must be noted that the true exposure to fluoride was not assessed. In Jalasjärvi, where fluoride content in drinking water was relatively high, the children were informed not to use any fluoride supplements other than toothpaste. This may have had an impact on their caries experience.

In Study IV, the response rate was small. It was therefore of particular interest to compare basic data of the group of respondents with information on the background population, Finnish dentists. Such information was best obtained from the Finnish Dental Association (2018b) with approximately 95% of Finnish dentists being members. The result of the comparison was that the sample resembled the background population. Differences between the groups can be considered relatively small even in the following aspects that showed the most pronounced differences: proportion of respondents from North and East Finland (28.8% in the survey vs. 23.4% in the background population, p

= 0.001, z-test), dentists younger than 30 years (10.6% vs. 6.4%, respectively, $p < 0.001$, z-test), as well as dentists older than 60 years (16.2% vs. 20.4%, $p = 0.008$, z-test). A limitation is that the study did not assess the preventive methods or treatment practices regarding FPMs with mild hypomineralization. The case descriptions were short and did not include radiographs or information about the other dentition. The main limitation of the study is the use of a self-filled questionnaire. The results may not reflect the actual material choices but rather the respondents attitudes toward the optimal treatment. However, the significance of this study may be beyond the study purposes, since, according to the open comments of the survey, the respondents appreciated the opportunity to consider their own expertise and the possibilities to expand it.

6.6 FUTURE PERSPECTIVES

Despite the extensive amount of research on MIH, several questions remain unsolved, from the mechanism and timing of the hypomineralization to the definition of the outcome. What Goodman & Rose wrote in 1990 is still valid: "... it is difficult to ascertain the age of an individual at the time of development of a hypocalcification defect" and "we do not know the length of time that maturation phases follow matrix formation" (Goodman & Rose 1990). Although imaging techniques, computer modeling, and genetic engineering have advanced, there are clear limitations to studying the development of hard tissues in living humans. Animal experiments can be used to form theories, but how well they are applicable to the development of human enamel is unclear.

The first report of specific "extensive and severe" hypomineralization of FPMs was published because clinicians encountered it frequently and it seemed to be a considerable clinical problem (Koch et al. 1987). Enamel opacities were not an unknown phenomenon and their etiology had been considered (Small & Murray 1978). However, the first judgement criteria included all demarcated defects of FPMs in the MIH diagnosis (Weerheijm et al. 2003). Although the more recent index sets a minimum size limit of more than 1 mm in diameter for MIH defects, it clearly defines opacities in FPMs to be distinct from enamel defects in other teeth (Ghanim et al. 2015). This is interesting, since demarcated opacities, as well as diffuse defects or hypoplasia, can affect any tooth (Jälevik et al. 2019). A question worthy of further study is whether severe enamel hypomineralization with the loss of tissue which requires treatment is mainly limited to FPMs. As it is known that yellow-brown opacities develop PEB more often than creamy white opacities (Cabral et al. 2019), individuals with only white opacities in FPMs may not suffer from the clinical implications which are often linked to MIH. A combined use of the MIH Index (Ghanim et al. 2015) and the MIH-SSS (Cabral et al. 2019) could be useful for assessing

the defect distribution pattern and the etiological factors. Also, longitudinal research is recommended to find the prevalence of enamel defects in all permanent teeth. The claim that MIH is unique for FPMs and incisors is not credible if the research is conducted in children for whom all permanent teeth have not yet erupted. Moreover, the prevalence studies should be conducted with large enough data and using methods that are repeatable, and so that the results could be generalized to the background population. This would also allow the comparison between different populations and within different time periods of a single population.

7 CONCLUSIONS

Based on the findings of this thesis, the following conclusions can be made:

- The children with diagnosed AOM or who have received penicillin, amoxicillin or macrolides in early childhood have an increased risk for demarcated hypomineralization in FPMs and incisors.
- The results did not support the hypothesis that the prevalence of MIH is higher among children from higher SES background.
- MIH is a greater risk indicator for caries in FPMs than SES.
- Among Finnish dentists, restoration with SSC is not the main treatment choice for symptomatic, severely affected MIH molars. However, pediatric dentists have a stronger preference for SSC than do general dentists. Moreover, the decision to refer a MIH patient forward varies regionally.

ACKNOWLEDGEMENTS

This study was conducted in the Department of Oral and Maxillofacial Diseases, University of Helsinki. The clinical examinations were performed between 2003 and 2006 in dental clinics at local health centers and in university dental clinics in Helsinki and Oulu. The conduct of clinical examinations was funded by the Academy of Finland. I started working on the study as a preclinical dental student in 2010. I have received funding from the Finnish Dental Society Apollonia sponsored by Planmeca Group and Colgate, the University of Helsinki, the Finnish Association of Women Dentists, and the Minerva Foundation. The financial help has been greatly appreciated.

I have received enormous help and support from all quarters. Specific acknowledgements are owed to the following contributions:

I deeply thank my supervisors, Professor Emerita Satu Alaluusua and Docent Janna Waltimo-Sirén. The confidence that Satu had in me as a young student helped me to grow as a scientist as well as a person. I am thankful for the opportunities you have provided me to advance in my research career. Your wide expertise and long-time work have impacted the development of pediatric dentistry in Finland - you set an inspiring example to us young scientists. I am profoundly grateful to Janna for your contribution on this study. My thesis has been immeasurably improved by your powers of observation and scientific writing skills. I admire your perseverance and patience when facing challenges. You both have been very well available which I am thankful for.

The thesis reviewers, Professor Emeritus Hannu Hausen and Professor Emerita Vuokko Anttonen are greatly acknowledged for your critical appraisal and constructive correction suggestions, which further improved this work. I appreciate the opportunity to discuss with such great minds. I also thank the thesis Committee Members, Docent Eeva Salo and Docent Pekka Nieminen, for encouragement and valuable advice.

I warmly thank all my co-authors. Special thanks to Sakari Laisi, DDS; without your enormous work with the dental examinations I could not have accomplished this thesis. I also greatly appreciate the help of Eija Salmela, PhD, and Anneli Ess, DDS, for your careful notes and contribution to the articles. Thank you to all the great scientists from the Finnish-Norwegian study group: Battsetseg Tseveenjav, PhD, Jussi Furuholm, PhD, Håkon Valen, PhD, Aida Mulic, PhD, Vibeke Ansteinsson, PhD, and Marte-Mari Uhlen, PhD. I am grateful for the opportunity to work with an international research group. I also thank Nordic Institute for Dental Materials (NIOM) for providing the questionnaire tools for the survey.

The statistical help of Janne Pitkäniemi, Director of Statistics from the Finnish Cancer Registry, and biostatistician Paula Bergman, from Biostatistic consulting, University of Helsinki, is gratefully acknowledged.

The organizational help of the head dentists in the health centers is acknowledged. Especially the contribution of the former head dentist Pekka Arvio from Lammi and Raija Lehto, DDS, from Jalasjärvi was significant to the conduct of the clinical study. I wish to thank all who participated in the studies, both the children in the clinical studies and their families, as well as the colleagues who used their time to respond to the survey. I thank the Finnish Dental Society Apollonia for forwarding the survey to the dentists.

I express my gratitude to my colleagues and coworkers in Oral Health Care, City of Lohja, Finland, for your enjoyable company and encouragement, and especially our former Chief Dentist Helena Salusjärvi-Juopperi, for letting me pilot the survey among the city dentists. Your encouraging attitude towards research motivated me.

Thank you to all my friends and extended family. I have been able to trust in your support and encouragement. This project would also have been much more challenging without our great babysitters during these years.

My parents Jaana and Pekka: You have provided me with unparalleled love and support. You have not set any expectations or pressure on me but have always believed in me. I am so thankful for having you as my parents.

I am deeply grateful to my dear children, Johan, Ellen, Aada, Vilma and Eeva, who remind me of the most important things in life. Your unconditional love is empowering. Thank you for your patience during my physical and mental absence. I owe my deepest thanks to my husband Joonas. You are my best support and coach in every aspect of life. Not only have you patiently revised the language of my scientific texts but also frequently provided an opportunity to mirror my thoughts and ideas. I am blessed to have you.

Lohja, June 2020

Emma Wuollet

REFERENCES

- Al-Alousi, W., Jackson, D., Crompton, G. & Jenkins, O.C. 1975, Enamel mottling in a fluoride and non-fluoride community, parts I and II. *British Dental Journal* 138: 56-60.
- Alaluusua, S., Calderara, P., Gerthoux, P.M., Lukinmaa, P.L., Kovero, O., Needham, L., Patterson, D.G.Jr. Tuomisto, J. & Mocarelli, P. 2004, Developmental dental aberrations after the dioxin accident in Seveso. *Environmental Health Perspectives* 112: 1313-8.
- Alaluusua, S. & Lukinmaa, P.L. 2006, Developmental dental toxicity of dioxin and related compounds - a review. *International Dental Journal* 56: 323-31.
- Alaluusua, S., Lukinmaa, P.L., Koskimies, M., Pirinen, S., Hölttä, P., Kallio, M., Holttinen, T. & Salmenpera, L. 1996a, Developmental dental defects associated with long breast feeding. *European Journal of Oral Sciences* 104: 493-7.
- Alaluusua, S., Lukinmaa, P.L., Vartiainen, T., Partanen, M., Torppa, J. & Tuomisto, J. 1996b, Polychlorinated dibenzo-p-dioxins and dibenzofurans via mother's milk may cause developmental defects in the child's teeth. *Environmental Toxicology and Pharmacology* 1: 193-7.
- Alanzi, A., Alkheder, M. & Qudeimat, M. 2019, Oral health status of kuwaiti children with a history of chronic liver disease. *Medical Principles and Practice* 28: 341-6.
- Allazzam, S.M., Alaki, S.M. & El Meligy, O.A. 2014, Molar incisor hypomineralization, prevalence, and etiology. *International Journal of Dentistry* 234508: 1-8.
- Altun, C., Cehreli, Z.C., Guven, G. & Acikel, C. 2009, Traumatic intrusion of primary teeth and its effects on the permanent successors: A clinical follow-up study. *Oral Surgery, Oral Medicine, Oral Pathology, Oral Radiology, and Endodontics* 107: 493-8.
- Andreasen, J.O. & Ravn, J.J. 1971, The effect of traumatic injuries to primary teeth on their permanent successors. II. A clinical and radiographic follow-up study of 213 teeth. *Scandinavian Journal of Dental Research* 79: 284-94.
- Antoine, D., Hillson, S. & Dean, M.C. 2009, The developmental clock of dental enamel: A test for the periodicity of prism cross-striations in modern humans and an evaluation of the most likely sources of error in histological studies of this kind. *Journal of Anatomy* 214: 45-55.
- Arrow, P. 2008, Prevalence of developmental enamel defects of the first permanent molars among school children in Western Australia. *Australian Dental Journal* 53: 250-9.
- Arrow, P. 2009, Risk factors in the occurrence of enamel defects of the first permanent molars among schoolchildren in Western Australia. *Community Dentistry and Oral Epidemiology* 37: 405-15.
- Balmer, R., Toumba, J., Godson, J. & Duggal, M. 2012, The prevalence of molar incisor hypomineralisation in Northern England and its

- relationship to socioeconomic status and water fluoridation. *International Journal of Paediatric Dentistry* 22: 250-7.
- Bartlett, J.D., Beniash, E., Lee, D.H. & Smith, C.E. 2004, Decreased mineral content in MMP-20 null mouse enamel is prominent during the maturation stage. *Journal of Dental Research* 83: 909-13.
- Bartlett, J.D., Skobe, Z., Nanci, A. & Smith, C.E. 2011, Matrix metalloproteinase 20 promotes a smooth enamel surface, a strong dentino–enamel junction, and a decussating enamel rod pattern. *European Journal of Oral Sciences* 119: 199-205.
- Beentjes, V.E., Weerheijm, K.L. & Groen, H.J. 2002, Factors involved in the aetiology of molar-incisor hypomineralisation (MIH). *European Journal of Paediatr Dentistry* 3: 9-13.
- Bekes, K., Heinzelmann, K., Lettner, S. & Schaller, H.G. 2017, Efficacy of desensitizing products containing 8% arginine and calcium carbonate for hypersensitivity relief in MIH-affected molars: An 8-week clinical study. *Clinical Oral Investigations* 21: 2311-7.
- Bhaskar, S. & Hedge, S. 2014, Molar-incisor hypomineralization: Prevalence, severity and clinical characteristics in 8- to 13-year-old children of Udaipur, India. *Journal of Indian Society of Pedodontics and Preventive Dentistry* 32: 322-9.
- Brogårdh-Roth, S., Matsson, L. & Klingberg, G. 2011, Molar-incisor hypomineralization and oral hygiene in 10- to-12-yr-old Swedish children born preterm. *European Journal of Oral Sciences* 119: 33-9.
- Bussaneli, D.G., Restrepo, M., Fragelli, C.M.B., Santos-Pinto, L., Jeremias, F., Cordeiro, R.C.L., Bezamat, M., Vieira, A.R. & Scarel-Caminaga, R.M. 2019, Genes regulating immune response and amelogenesis interact in increasing the susceptibility to molar-incisor hypomineralization. *Caries Research* 53: 217-27.
- Butler, P.M. 1967, The prenatal development of the human first upper permanent molar. *Archives of Oral Biology* 12: 551-63.
- Cabral, R.N., Nyvad, B., Soviero, V.L.V.M., Freitas, E. & Leal, S.C. 2019, Reliability and validity of a new classification of MIH based on severity. *Clinical Oral Investigations* Epub ahead of print: 1-9.
- Caterina, J.J., Skobe, Z., Shi, J., Ding, Y., Simmer, J.P., Birkedal-Hansen, H. & Bartlett, J.D. 2002, Enamelysin (matrix metalloproteinase 20)-deficient mice display an amelogenesis imperfecta phenotype. *The Journal of Biological Chemistry* 277: 49598-604.
- Chan, Y.L., Ngan, A.H. & King, N.M. 2010, Degraded prism sheaths in the transition region of hypomineralized teeth. *Journal of Dentistry* 38: 237-44.
- Cho, A., Haruyama, N., Hall, B., Danton, M.J., Zhang, L., Arany, P., Mooney, D.J., Harichane, Y., Goldberg, M., Gibson, C.W. & Kulkarni, A.B. 2013, TGF- β regulates enamel mineralization and maturation through KLK4 expression. *PLoS One* 8: e82267.
- Clarkson, J. O'Mullane, D. 1989, A modified DDE index for use in epidemiological studies of enamel defects. *Journal of Dental Research* 68: 445-50.
- Cobourne, M.T., Williams, A. & Harrison, M. 2014, National clinical guidelines for the extraction of first permanent molars in children. *British Dental Journal* 217: 643-8.

- Committee on essays, 1892. Preliminary communication from the committee on essays, The World's Columbian Dental Congress, 1893. Philadelphia, Pa. Retrieved from <https://digitalhub.northwestern.edu/collections/05741r77z>
- Crombie, F.A., Manton, D.J., Palamara, J.E., Zalizniak, I., Cochrane, N.J. & Reynolds, E.C. 2013, Characterisation of developmentally hypomineralised human enamel. *Journal of Dentistry* 41: 611-8.
- Cutress, T.W. & Suckling, G.W. 1990, Differential diagnosis of dental fluorosis. *Journal of Dental Research* 69: 714-20.
- Da Costa-Silva, C.M., Ambrosano, G.M., Jeremias, F., De Souza, J.F. & Mialhe, F.L. 2011, Increase in severity of molar-incisor hypomineralization and its relationship with the colour of enamel opacity: A prospective cohort study. *International Journal of Paediatric Dentistry* 21: 333-41.
- Da Costa-Silva, C.M., Jeremias, F., De Souza, J.F., Cordeiro Rde, C., Santos-Pinto, L. & Zuanon, A.C. 2010, Molar incisor hypomineralization: Prevalence, severity and clinical consequences in Brazilian children. *International Journal of Paediatric Dentistry* 20: 426-34.
- Da Silva Figueiredo Se, M.J., Ribeiro, A.P.D., Dos Santos-Pinto, L.A.M., de Cassia Loiola Cordeiro, R., Cabral, R.N. & Leal, S.C. 2017, Are hypomineralized primary molars and canines associated with molar-incisor hypomineralization? *Pediatric Dentistry* 39: 445-9.
- Davenport, M., Welles, A.D., Angelopoulou, M.V., Gonzalez, C., Okunseri, C., Barbeau, L., Bansal, N.K., Vergotine, R.J. & Hodgson, B.D. 2019, Prevalence of molar-incisor hypomineralization in Milwaukee, Wisconsin, USA: A pilot study. *Clinical, Cosmetic and Investigational Dentistry* 11: 109-17.
- Davidovich, E., Schwarz, Z., Davidovitch, M., Eidelman, E. & Bimstein, E. 2005, Oral findings and periodontal status in children, adolescents and young adults suffering from renal failure. *Journal of Clinical Periodontology* 32: 1076-82.
- Davies, P.A., Little, K., Aherne, W. 1962, Tetracyclines and yellow teeth. *Lancet* 279: 743-743.
- De Souza, J.F., Fragelli, C.B., Jeremias, F., Paschoal, M.A.B., Santos-Pinto, L. & de Cassia Loiola Cordeiro, R. 2017, Eighteen-month clinical performance of composite resin restorations with two different adhesive systems for molars affected by molar incisor hypomineralization. *Clinical Oral Investigations* 21: 1725-33.
- Dean, H.T. 1934, Classification of mottled enamel diagnosis. *Journal of American Dental Association* 21: 1421-6.
- Demirijan, A., Goldstein, H. & Tanner, J.M. 1973, A new system of dental age assessment. *Human Biology* 45: 211-27.
- Dhareula, A., Goyal, A., Gauba, K., Bhatia, S.K., Kapur, A. & Bhandari, S. 2019, A clinical and radiographic investigation comparing the efficacy of cast metal and indirect resin onlays in rehabilitation of permanent first molars affected with severe molar incisor hypomineralisation (MIH): A 36-month randomised controlled clinical trial. *European Archives of Paediatric Dentistry* Epub ahead of print

- Dietrich, G., Sperling, S. & Hetzer, G. 2003, Molar incisor hypomineralisation in a group of children and adolescents living in Dresden (Germany). *European Journal of Paediatric Dentistry* 4: 133-7.
- Ekambaram, M. & Yiu, C.K.Y. 2016, Bonding to hypomineralized enamel - A systematic review. *Internatiol Journal of Adhesion and Adhesives* 69: 27-32.
- Ekanayake, L. & van der Hoek, W. 2002, Dental caries and developmental defects of enamel in relation to fluoride levels in drinking water in an arid area of Sri Lanka. *Caries Research* 36: 398-404.
- Elfrink, M.E., Schuller, A.A., Weerheijm, K.L., Veerkamp, J.S. 2008, Hypomineralized second primary molars: prevalence data in Dutch 5-year-olds. *Caries Research* 42: 282-285.
- Elfrink, M.E., Veerkamp, J.S., Aartman, I.H., Moll, H.A. & Ten Cate, J.M. 2009, Validity of scoring caries and primary molar hypomineralization (DMH) on intraoral photographs. *European Archives of Paediatric Dentistry* 10: 5-10.
- Elfrink, M.E., Ten Cate, J.M., Jaddoe, V.W., Hofman, A., Moll, H.A. & Veerkamp, J.S. 2012, Deciduous molar hypomineralization and molar incisor hypomineralization. *Journal of Dental Research* 91: 551-5.
- Elhennawy, K., Jost-Brinkmann, P.G., Manton, D.J., Paris, S. & Schwendicke, F. 2017a, Managing molars with severe molar-incisor hypomineralization: A cost-effectiveness analysis within German healthcare. *Journal of Dentistry* 63: 65-71.
- Elhennawy, K., Manton, D.J., Crombie, F., Zaslansky, P., Radlanski, R.J., Jost-Brinkmann, P.G. & Schwendicke, F. 2017b, Structural, mechanical and chemical evaluation of molar-incisor hypomineralization-affected enamel: A systematic review. *Archives of Oral Biology* 83: 272-81.
- Elhennawy, K. & Schwendicke, F. 2016, Managing molar-incisor hypomineralization: A systematic review. *Journal of Dentistry* 55: 16-24.
- Ellwood, R.P. & O'Mullane, D.M. 1994, The demographic and social variation in the prevalence of dental enamel opacities in North Wales. *Community Dental Health* 11: 192-6.
- European Commission Eurostat, 2018. *Nomenclature of territorial units for statistics NUTS level 2 Suomi/Finland*. Retrieved from <https://ec.europa.eu/eurostat/documents/345175/7451602/2016-NUTS-2-map-FI.pdf>
- Fagrell, T.G., Dietz, W., Jälevik, B. & Norén, J.G. 2010, Chemical, mechanical and morphological properties of hypomineralized enamel of permanent first molars. *Acta Odontologica Scandinavica* 68: 215-22
- Fagrell, T.G., Ludvigsson, J., Ullbro, C., Lundin, S.A. & Koch, G. 2011, Aetiology of severe demarcated enamel opacities--an evaluation based on prospective medical and social data from 17,000 children. *Swedish Dental Journal* 35: 57-67.
- Fagrell, T.G., Salmon, P., Melin, L. & Norén, J.G. 2013, Onset of molar incisor hypomineralization (MIH). *Swedish Dental Journal* 37: 61-70.
- Farah, R., Drummond, B., Swain, M. & Williams, S. 2010a, Linking the clinical presentation of molar-incisor hypomineralisation to its mineral density. *International Journal of Paediatric* 20: 353-60.

- Farah, R.A., Monk, B.C., Swain, M.V. & Drummond, B.K. 2010b, Protein content of molar-incisor hypomineralisation enamel. *Journal of Dentistry* 38: 591-6.
- FDI Commission on Oral Health, Research and Epidemiology 1982, An epidemiological index of developmental defects of dental enamel (D.D.E. index). *International Dental Journal* 32: 159-67.
- FDI Working Group 1992, A review of the developmental defects of enamel index (DDE index). Commission on oral health, research & epidemiology. Report of an FDI working group. *International Dental Journal* 42: 411-26.
- Ferrazzano, G.F., Sangianantoni, G., Cantile, T., Iorio, R. & Ingenito, A. 2013, Oral health status in liver transplant italian children. *European Journal of Paediatric Dentistry* 14: 323-7.
- Finnish Food Authority. 2010, *Elintarvikkeiden täydentäminen D-vitamiinilla*. Retrieved from <https://www.ruokavirasto.fi/teemat/terveytta-edistava-ruokavalio/vrn/toimenpide-esitykset-ja-kannanotot/toimenpide-esitykset-elintarvikkeiden-taydentamisesta/elintarvikkeiden-taydentaminen-d-vitamiinilla/>
- Fireman, B., Black, S. & Shinefield, H. 2003, Impact of the pneumococcal conjugate vaccine on otitis media. *Pediatric Infectious Disease Journal* 22: 10-6.
- FitzGerald, C.M. 1998, Do enamel microstructures have regular time dependency? conclusions from the literature and a large-scale study. *Journal of Human Evolution* 35: 371-86.
- Foster, B.L., Nociti, F.H.Jr. & Somerman, M.J. 2014, The rachitic tooth. *Endocrine Reviews* 35: 1-34.
- Fragelli, C.M., Souza, J.F., Jeremias, F., Cordeiro Rde, C. & Santos-Pinto, L. 2015, Molar incisor hypomineralization (MIH): Conservative treatment management to restore affected teeth. *Brazilian Oral Research* 29:1-7.
- Fragelli, C.M.B., Souza, J.F., Bussaneli, D.G., Jeremias, F., Santos-Pinto, L.D. & Cordeiro, R.C.L. 2017, Survival of sealants in molars affected by molar-incisor hypomineralization: 18-month follow-up. *Brazilian Oral Research* 31: e30
- Fütterer, J., Ebel, M., Bekes, K., Klode, C., Hirsch, C. 2020 Influence of customized therapy for molar incisor hypomineralization on children's oral hygiene and quality of life. *Clinical and Experimental Dental Research* 6: 33-43
- Gaardmand, E., Poulsen, S. & Haubek, D. 2013, Pilot study of minimally invasive cast adhesive copings for early restoration of hypomineralised first permanent molars with post-eruptive breakdown. *European Archives of Paediatric Dentistry* 14: 35-9.
- Gatón-Hernández, P., Serrano, C.R., da Silva, L.A.B., de Castañeda E.R., da Silva R.A.B., Pucinelli, C.M., Manton, D., Ustrell-Torrent, J.M., Nelson-Filho P. 2020, Minimally interventive restorative care of teeth with molar incisor hypomineralization and open apex-A 24-month longitudinal study. *International Journal of Paediatric Dentistry* 30: 4-10.
- Ghanim, A., Manton, D., Bailey, D., Mariño, R., and Morgan, M. 2013. Risk factors in the occurrence of molar-incisor hypomineralization amongst a

- group of iraqi children. *International Journal of Paediatric Dentistry* 23 (3): 197-206.
- Ghanim, A., Elfrink, M., Weerheijm, K., Mariño, R. & Manton, D. 2015, A practical method for use in epidemiological studies on enamel hypomineralisation. *European Archives of Paediatric Dentistry* 16: 235-46.
- Ghanim, A., Mariño, R. & Manton, D. 2019, Validity and reproducibility testing of the molar incisor hypomineralisation (MIH) index. *International Journal of Paediatric Dentistry* 29: 6-13.
- Goodman, A.H. & Rose, J.C. 1990, Assessment of systemic physiological perturbations from dental enamel hypoplasias and associated histological structures. *Yearbook of Physiology and Anthropology*. 33: 59-110.
- Goward, P.E. 1976, Enamel mottling in a non-fluoride community in england. *Community Dentistry and Oral Epidemiology* 4: 111-4.
- Grossi, J.A., Cabral, R.N. & Leal, S.C. 2017, Caries experience in children with and without molar-incisor hypomineralisation: A case-control study. *Caries Research*. 51: 419-24.
- Grossi, J.A., Cabral, R.N., Ribeiro, A.P.D. & Leal, S.C. 2018, Glass hybrid restorations as an alternative for restoring hypomineralized molars in the ART model. *BMC Oral Health* 18: 65
- Heitmüller, D., Thiering, E., Hoffmann, U., Heinrich, J., Manton, D., Kühnisch, J., Neumann, C., Bauer, C.P., Heinrich-Weltzien, R., Hickel, R. & GINIplus Study Group 2013, Is there a positive relationship between molar incisor hypomineralisations and the presence of dental caries? *International Journal of Paediatric Dentistry* 23: 116-24.
- Hong, L., Levy, S.M., Warren, J.J. & Broffitt, B. 2011, Amoxicillin use during early childhood and fluorosis of later developing tooth zones. *Journal of Public Health Dentistry* 71: 229-35.
- Hong, L., Levy, S.M., Warren, J.J., Dawson, D.V., Bergus, G.R. & Wefel, J.S. 2005, Association of amoxicillin use during early childhood with developmental tooth enamel defects. *Archives of Pediatrics & Adolescent Medicine* 159: 943-8.
- Honkanen, M., Jousimaa, J., Komulainen, J., Kunnamo, I. & Sipilä, R. 2016, *Duodecimin hoitosuositustöryhmien käsikirja*. Helsinki: Finnish Medical Society Duodecim.
- Horowitz, H., Driscoll, W.S., Meyers, R., Heifetz, S. & Kingman, A. 1984, A new method of assessing the prevalence of fluorosis - the tooth surface index of fluorosis. *Journal of American Dental Association* 109: 37-41.
- Jacobsen, P.E., Haubek, D., Henriksen, T.B., Ostergaard, J.R. & Poulsen, S. 2014, Developmental enamel defects in children born preterm: A systematic review. *European Journal of Oral Sciences* 122: 7-14.
- Jan, J. & Vrbic, V. 2000, Polychlorinated biphenyls cause developmental enamel defects in children. *Caries Research* 34: 469-73.
- Jedeon, K., De la Dure-Molla, M., Brookes, S.J., Loiodice, S., Marciano, C., Kirkham, J., Canivenc-Lavier, M.C., Boudalia, S., Berges, R., Harada, H., Berdal, A. & Babajko, S. 2013, Enamel defects reflect perinatal exposure to bisphenol A. *The American Journal of Pathology* 183: 108-18.
- Jedeon, K., Loiodice, S., Marciano, C., Vinel, A., Canivenc Lavier, M.C., Berdal, A. & Babajko, S. 2014, Estrogen and bisphenol A affect male rat

- enamel formation and promote ameloblast proliferation. *Endocrinology* 155: 3365-75.
- Jedeon, K., Loiodice, S., Salhi, K., Le Normand, M., Houari, S., Chaloyard, J., Berdal, A. & Babajko, S. 2016, Androgen receptor involvement in rat amelogenesis: An additional way for endocrine-disrupting chemicals to affect enamel synthesis. *Endocrinology* 157: 4287-96.
- Jeremias, F., De Souza, J.F., Silva, C.M., Cordeiro Rde, C., Zuanon, A.C. & Santos-Pinto, L. 2013a, Dental caries experience and molar-incisor hypomineralization. *Acta Odontologica Scandinavica* 71: 870-6.
- Jeremias, F., Koruyucu, M., Kuchler, E.C., Bayram, M., Tuna, E.B., Deeley, K., Pierri, R.A., Souza, J.F., Fragelli, C.M., Paschoal, M.A., Gencay, K., Seymen, F., Caminaga, R.M., dos Santos-Pinto, L. & Vieira, A.R. 2013b, Genes expressed in dental enamel development are associated with molar-incisor hypomineralization. *Archives of Oral Biology* 58: 1434-42.
- Jeremias, F., Pierri, R.A., Souza, J.F., Fragelli, C.M., Restrepo, M., Finoti, L.S., Bussaneli, D.G., Cordeiro, R.C., Secolin, R., Maurer-Morelli, C.V., Scarel-Caminaga, R.M. & Santos-Pinto, L. 2016, Family-based genetic association for molar-incisor hypomineralization. *Caries Research* 50:310-8.
- Jernvall, J., Kettunen, P., Karavanova, I., Martin L.B., and Thesleff, I. 1994. Evidence for the role of the enamel knot as a control center in mammalian tooth cusp formation: Non-dividing cells express growth stimulating Fgf-4 gene. *International Journal of Developmental Biology* 38:463-9.
- Jussila, M. & Thesleff, I. 2012. Signaling networks regulating tooth organogenesis and regeneration, and the specification of dental mesenchymal and epithelial cell lineages. *Cold Spring Harbor Perspectives in Biology* 4:a008425.
- Jälevik, B., Dietz, W. & Norén, J.G. 2005, Scanning electron micrograph analysis of hypomineralized enamel in permanent first molars. *International Journal of Paediatric Dentistry* 15: 233-40.
- Jälevik, B. & Klingberg, G. 2012, Treatment outcomes and dental anxiety in 18-year-olds with MIH, comparisons with healthy controls - a longitudinal study. *International Journal of Paediatric Dentistry* 22: 85-91.
- Jälevik, B., Klingberg, G., Barregård, L. & Norén, J.G. 2001a, The prevalence of demarcated opacities in permanent first molars in a group of Swedish children. *Acta Odontologica Scandinavica* 59: 255-60.
- Jälevik, B. & Klingberg, G.A. 2002, Dental treatment, dental fear and behaviour management problems in children with severe enamel hypomineralization of their permanent first molars. *International Journal of Paediatric Dentistry* 12: 24-32.
- Jälevik, B. & Norén, J.G. 2000, Enamel hypomineralization of permanent first molars: A morphological study and survey of possible aetiological factors. *International Journal of Paediatric Dentistry* 10: 278-89.
- Jälevik, B., Szigyarto-Matei, A. & Robertson, A. 2019, Difficulties in identifying developmental defects of the enamel: A BITA study. *European Archives of Paediatric Dentistry* Epub ahead of print.
- Jälevik, B., Szigyarto-Matei, A. & Robertson, A. 2018, The prevalence of developmental defects of enamel, a prospective cohort study of

- adolescents in Western Sweden: A barn I TANadvarden (BITA, children in dental care) study. *European Archives of Paediatric Dentistry* 19:187-95.
- Jälevik, B., Norén, J.G., Klingberg, G. & Barregård, L. 2001b, Etiologic factors influencing the prevalence of demarcated opacities in permanent first molars in a group of Swedish children. *European Journal of Oral Sciences* 109: 230-4.
- Kerminen, S., Havulinna, A.S., Hellenthal, G., Martin, A.R., Sarin, A.P., Perola, M., Palotie, A., Salomaa, V., Daly, M.J., Ripatti, S. & Pirinen, M. 2017, Fine-scale genetic structure in Finland. *G3 (Bethesda, Md.)* 7: 3459-68.
- Kevrekidou, A., Kosma, I., Arapostathis, K. & Kotsanos, N. 2015, Molar incisor hypomineralization of eight- and 14-year-old children: Prevalence, severity, and defect characteristics. *Pediatric Dentistry* 37: 455-61.
- Kim, Y.J., Kang, J., Seymen, F., Koruyucu, M., Zhang, H., Kasimoglu, Y., Bayram, M., Tuna-Ince, E.B., Bayrak, S., Tuloglu, N., Hu, J.C.C., Simmer, J.P., Kim, J.W. 2020, Alteration of exon definition causes Amelogenesis Imperfecta. *Journal of Dental Research* Epub ahead of print: 1-9.
- Kisand, K. & Peterson, P. 2015, Autoimmune polyendocrinopathy candidiasis ectodermal dystrophy. *Journal of Clinical Immunology* 35: 463-78.
- Koch, G. 2003, Prevalence of enamel mineralisation disturbances in an area with 1-1.2 ppm F in drinking water. review and summary of a report published in Sweden in 1981. *European Journal of Paediatric Dentistry* 4: 127-8.
- Koch, G., Hallonsten, A.L., Ludvigsson, N., Hansson, B.O., Holst, A. & Ullbro, C. 1987, Epidemiologic study of idiopathic enamel hypomineralization in permanent teeth of Swedish children. *Community Dentistry and Oral Epidemiology* 15: 279-85.
- Kosma, I., Kevrekidou, A., Boka, V., Arapostathis, K. & Kotsanos, N. 2016, Molar incisor hypomineralisation (MIH): Correlation with dental caries and dental fear. *European Archives of Paediatric Dentistry* 17: 123-9.
- Kotsanos, N., Kaklamanos, E. & Arapostathis, K. 2005, Treatment management of first permanent molars in children with molar-incisor hypomineralisation. *European Journal of Paediatric Dentistry* 6: 179-84.
- Kühnisch, J., Kabary, L., Malyk, Y., Rothmaier, K., Metz, I., Hickel, R., Heinrich, J., Manton, D. & Standl, M. 2018, Relationship between caries experience and demarcated hypomineralised lesions (including MIH) in the permanent dentition of 15-year-olds. *Clinical Oral Investigations* 22: 2013-9.
- Kühnisch, J., Lauenstein, A., Pitchika, V., McGlynn, G., Staskiewicz, A., Hickel, R. & Grupe, G. 2016, Was molar incisor hypomineralisation (MIH) present in archaeological case series? *Clinical Oral Investigations* 20:2387-93.
- Kühnisch, J., Thiering, E., Heitmüller, D., Tiesler, C.M., Grallert, H., Heinrich-Weltzien, R., Hickel, R., Heinrich, J., GINI-10 Plus Study Group & LISA-10Plus Study Group. 2014a, Genome-wide association study (GWAS) for molar-incisor hypomineralization (MIH). *Clinical Oral Investigations* 18: 677-82.

- Kühnisch, J., Mach, D., Thiering, E., Brockow, I., Hoffmann, U., Neumann, C., Heinrich-Weltzien, R., Bauer, C.P., Berdel, D., von Berg, A., Koletzko, S., Garcia-Godoy, F., Hickel, R., Heinrich, J. & GINI Plus 10 Study Group. 2014b, Respiratory diseases are associated with molar-incisor hypomineralizations. *Swiss Dental Journal* 124: 286-93.
- Kühnisch, J., Thiering, E., Heinrich-Weltzien, R., Hellwig, E., Hickel, R. & Heinrich, J. 2017, Fluoride/vitamin D tablet supplementation in infants-effects on dental health after 10 years. *Clinical Oral Investigations* 21: 2283-90.
- Kumar, S., Tadakamadla, J., Kroon, J. & Johnson, N.W. 2016, Impact of parent-related factors on dental caries in the permanent dentition of 6-12-year-old children: A systematic review. *Journal of Dentistry* 46: 1-11.
- Kuscu, O.O., Caglar, E., Aslan, S., Durmusogly, E., Karademir, A. & Sandalli, N. 2009, The prevalence of molar incisor hypomineralization (MIH) in a group of children in a highly polluted urban region and a windfarm-green energy island. *International Journal of Paediatric Dentistry* 19: 176-85.
- Kuscu, O.O., Caglar, E. & Sandalli, N. 2008, The prevalence and aetiology of molar-incisor hypomineralisation in a group of children in Istanbul. *European Journal of Paediatric Dentistry* 9: 139-44.
- Kuscu, O.O., Sandalli, N., Dikmen, S., Ersoy, O., Tatar, I., Turkmen, I. & Caglar, E. 2013, Association of amoxicillin use and molar incisor hypomineralization in piglets: Visual and mineral density evaluation. *Archives of Oral Biology* 58: 1422-1433.
- Kyttälä, P., Erkkola, M., Kronberg-Kippila, C., Tapanainen, H., Veijola, R., Simell, O., Knip, M. & Virtanen, S.M. 2010, Food consumption and nutrient intake in Finnish 1-6-year-old children. *Public Health Nutrition* 13: 947-56.
- Laisi, S., Ess, A., Sahlberg, C., Arvio, P., Lukinmaa, P.L., Alaluusua, S. 2009, Amoxicillin may cause Molar Incisor Hypomineralization. *Journal of Dental Research* 88: 132-6
- Laisi, S., Kiviranta, H., Lukinmaa, P., Vartiainen, T. & Alaluusua, S. 2008, Molar-incisor-hypomineralisation and dioxins: New findings. *European Archives of Paediatric Dentistry* 9: 224-7.
- Leppäniemi, A., Lukinmaa, P.L. & Alaluusua, S. 2001, Nonfluoride hypomineralizations in the permanent first molars and their impact on the treatment need. *Caries Research* 35: 36-40.
- Logan, W.H.G. & Kronfeld, R. 1933, Development of the human jaws and surrounding structures from birth to the age of fifteen years. *Journal of American Dental Association* 20: 379-427.
- Lygidakis, N.A., Chaliasou, A. & Siounas, G. 2003, Evaluation of composite restorations in hypomineralised permanent molars: A four-year clinical study. *European Journal of Paediatric Dentistry* 4: 143-8.
- Lygidakis, N.A., Dimou, G. & Stamataki, E. 2009, Retention of fissure sealants using two different methods of application in teeth with hypomineralised molars (MIH): A 4-year clinical study. *European Archives of Paediatric Dentistry* 10: 223-6.
- Lygidakis, N.A., Wong, F., Jälevik, B., Vierrou, A.M., Alaluusua, S., Espelid, I. 2010. Best clinical practice guidance for clinicians dealing with children

- presenting with Molar-Incisor Hypomineralisation (MIH). *European Archives of Paediatric Dentistry* 11: 75-81.
- Mahoney, E.K. & Morrison, D.G. 2011, Further examination of the prevalence of MIH in the Wellington region. *The New Zealand Dental Journal* 107: 79-84.
- Mahoney, E.K., Rohanizadeh, R., Ismail, F.S., Kilpatrick, N.M. & Swain, M.V. 2004, Mechanical properties and microstructure of hypomineralised enamel of permanent teeth. *Biomaterials* 25: 5091-100.
- Malmberg, P., Norén, J.G. & Bernin, D. 2019, Molecular insights into hypomineralized enamel. *European Journal of Oral Sciences* 127: 340-6.
- Magnum, J.E., Crombie, F.A., Kilpatrick, N., Manton, D.J. & Hubbard, M.J. 2010, Surface integrity governs the proteome of hypomineralized enamel. *Journal of Dental Research* 89: 1160-5.
- Mejàre, I., Bergman, E. & Grindejord, M. 2005, Hypomineralized molars and incisors of unknown origin: Treatment outcome at age 18 years. *International Journal of Paediatric Dentistry* 15: 20-8.
- Menoncin, B.L.V., Portella, P.D., Ramos, B.L.M., Assuncao, L.R.D.S., De Souza, J.F. & Menezes, J.V.N.B. 2019, Dental anxiety in schoolchildren with molar incisor hypomineralization-A population-based cross-sectional study. *International Journal of Paediatric Dentistry* 29: 615-23.
- Mesbah, M., Nemere, I., Papagerakis, P., Nefussi, J.R., Orestes-Cardoso, S., Nessmann, C. & Berdal, A. 2002, Expression of a 1,25-dihydroxyvitamin D3 membrane-associated rapid-response steroid binding protein during human tooth and bone development and biomineralization. *Journal of Bone and Mineral Research* 17: 1588-96.
- Mihalas, E., Matricala, L., Chelms, A., Ghetu, N., Petcu, A., Pasca, S. 2016, The Role of Chronic Exposure to Amoxicillin/Clavulanic Acid on the Developmental Enamel Defects in Mice. *Toxicologic Pathology* 44: 61-70.
- Mittal, R., Chandak, S., Chandwani, M., Singh, P. & Pimpale, J. 2016, Assessment of association between molar incisor hypomineralization and hypomineralized second primary molar. *Journal of International Society of Preventive & Community Dentistry* 6: 34-9.
- Muratbegovic, A., Markovic, N. & Ganibegovic Selimovic, M. 2007, Molar incisor hypomineralisation in Bosnia and Herzegovina: Aetiology and clinical consequences in medium caries activity population. *European Archives of Paediatric Dentistry* 8: 189-94.
- Murray, J.J. & Shaw, L. 1979, Classification and prevalence of enamel opacities in the human deciduous and permanent dentitions. *Archives of Oral Biology* 24: 7-13.
- Nakayama, Y., Holcroft, J. & Ganss, B. 2015, Enamel hypomineralization and structural defects in amelotin-deficient mice. *Journal of Dental Research* 94: 697-705.
- Nanci, A. 2018. *Ten Cate's oral histology*. 9th ed. St. Louis: Elsevier.
- National Institute for Health and Welfare. 2019. Oral healthcare. In *Social and Health-Care Services in Finland. Expert evaluation – Autumn 2018.*, ed. Pekka Rissanen, 24-25. Finland: National Institute for Health and Welfare.

- Nikiforuk, G. & Fraser, D. 1979, Chemical determinants of enamel hypoplasia in children with disorders of calcium and phosphate homeostasis. *Journal of Dental Research* 58: 1014-5.
- Nissanka-Jayasuriya, E.H., Odell, E.W. & Phillips, C. 2016, Dental stigmata of congenital syphilis: A historic review with present day relevance. *Head and Neck Pathology* 10: 327-31.
- Nørrisgaard, P.E., Haubek, D., Kühnisch, J., Chawes, B.L., Stokholm, J., Bønnelykke, K. & Bisgaard, H. 2019, Association of high-dose vitamin D supplementation during pregnancy with the risk of enamel defects in offspring: A 6-year follow-up of a randomized clinical trial. *JAMA Pediatrics* Epub ahead of print.
- Nunn, J.H., Murray, J.J., Reynolds, P., Tabari, D. & Breckon, J. 1992, The prevalence of developmental defects of enamel in 15-16-year-old children residing in three districts (natural fluoride, adjusted fluoride, low fluoride) in the North East of England. *Community Dent Health* 9: 235-47.
- Nyström, M. & Ranta, H. 2003, Tooth formation and the mandibular symphysis during the first five postnatal months. *Journal of Forensic Sciences* 48: 373-8.
- Nyström, M.E., Ranta, H.M., Peltola, J.S. & Kataja, J.M. 2007, Timing of developmental stages in permanent mandibular teeth of finns from birth to age 25. *Acta Odontologica Scandinavica* 65: 36-43.
- Närhi, M., Yamamoto, H., Ngassapa, D. & Hirvonen, T. 1994, The neurophysiological basis and the role of inflammatory reactions in dentine hypersensitivity. *Archives of Oral Biology* 39 Suppl: 23S-30S.
- O'Neill, C.M., Kazantzidis, A., Ryan, M.J., Barber, N., Sempos, C.T., Durazo-Arvizu, R.A., Jorde, R., Grimnes, G., Eiriksdottir, G., Gudnason, V., Cotch, M.F., Kiely, M., Webb, A.R. & Cashman, K.D. 2016, Seasonal changes in vitamin D-effective UVB availability in Europe and associations with population serum 25-hydroxyvitamin D. *Nutrients* 8: 10.3390/nu8090533.
- Opydo-Szymaczek, J. & Gerreth, K. 2015, Developmental enamel defects of the permanent first molars and incisors and their association with dental caries in the region of Wielkopolska, Western Poland. *Oral Health & Preventive Dentistry* 13: 461-9.
- Opydo-Szymaczeka, J., Gerreth, K., Borysewicz-Lewicka, M., Pawlaczyk-Kamienska, T., Torlinska-Walkowiak, N. & Sniatala, R. 2018, Enamel defects and dental caries among children attending primary schools in Poznan, Poland. *Advances in Clinical and Experimental Medicine* 27: 1535-40.
- Oyedele, T.A., Folayan, M.O., Adekoya-Sofowora, C.A., Oziegbe, E.O. & Esan, T.A. 2015, Prevalence, pattern and severity of molar incisor hypomineralisation in 8- to 10-year-old school children in Ile-Ife, Nigeria. *European Archives of Paediatric Dentistry* 16: 277-82.
- Ozgül, B.M., Saat, S., Sönmez, H. & Oz, F.T. 2013, Clinical evaluation of desensitizing treatment for incisor teeth affected by molar-incisor hypomineralization. *The Journal of Clinical Pediatric Dentistry* 38: 101-5.
- Petrou, M.A., Giraki, M., Bissar, A.R., Basner, R., Wempe, C., Altarabulsi, M.B., Schafer, M., Schiffner, U., Beikler, T., Schulte, A.G. & Splieth, C.H.

- 2014, Prevalence of molar-incisor-hypomineralisation among school children in four German cities. *International Journal of Paediatric Dentistry* 24: 434-40.
- Petrou, M.A., Giraki, M., Bissar, A.R., Wempe, C., Schafer, M., Schiffner, U., Beikler, T., Schulte, A.G. & Splieth, C.H. 2015, Severity of MIH findings at tooth surface level among German school children. *European Archives of Paediatric Dentistry* 16: 271-6.
- Pitiphat, W., Luangchaichaweng, S., Pungchanchaikul, P., Angwaravong, O. & Chansamak, N. 2014, Factors associated with molar incisor hypomineralization in Thai children. *European Journal of Oral Sciences* 122: 265-70.
- Prasad, M.K., Laouina, S., El Alloussi, M., Dollfus, H., Bloch-Zupan, A. 2016, Amelogenesis Imperfecta: 1 Family, 2 Phenotypes, and 2 Mutated Genes. *Journal of Dental Research* 95: 1457-63
- Price, J.A., Wright, J.T., Walker, S.J., Crawford, P.J., Aldred, M.J. & Hart, T.C. 1999, Tricho-dento-osseous syndrome and amelogenesis imperfecta with taurodontism are genetically distinct conditions. *Clinical Genetics* 56: 35-40.
- Pöyhönen, H., Nurmi, M., Peltola, V., Alaluusua, S., Ruuskanen, O. & Lahdesmaki, T. 2017, Dental staining after doxycycline use in children. *The Journal of Antimicrobial Chemotherapy* 72: 2887-90.
- Raposo, F., de Carvalho Rodrigues, A.C., Lia, E.N. & Leal, S.C. 2019, Prevalence of hypersensitivity in teeth affected by molar-incisor hypomineralization (MIH). *Caries Research* 52: 424-30.
- Ravindran, R. & Saji, A.M. 2016, Prevalence of the developmental defects of the enamel in children aged 12-15 years in kollam district. *Journal of International Society of Preventive & Community Dentistry* 6: 28-33.
- Reid, D.J. & Dean, M.C. 2006, Variation in modern human enamel formation times. *Journal of Human Evolution* 50: 329-46.
- Robinson, C. 2014, Enamel maturation: A brief background with implications for some enamel dysplasias. *Frontiers in Physiology* 5: 388.
- Robinson, C., Kirkham, J., Brookes, S.J., Bonass, W.A. & Shore, R.C. 1995, The chemistry of enamel development. *International Journal of Developmental Biology* 39: 145-52.
- Rodd, H.D., Boissonade, F.M. & Day, P.F. 2007a, Pulpal status of hypomineralized permanent molars. *Pediatric Dentistry* 29 (6) (Nov-Dec): 514-20.
- Rodd, H.D., Morgan, C.R., Day, P.F. & Boissonade, F.M. 2007b, Pulpal expression of TRPV1 in molar incisor hypomineralisation. *European Archives of Paediatric Dentistry* 8: 184-8.
- Rodrigues, F.C.N., Ribeiro, P.H.B., Thomaz, E.B.A.F., Lima, G.Q.T., Neves, P.A.M. & Ribeiro, C.C.C. 2015, Molar-incisor hypomineralization in schoolchildren of Sao Luis, Brazil Maranhao: Prevalence and associated factors. *Brazilian Research in Pediatric Dentistry and Integrated Clinic* 15: 271-8.
- Rugg-Gunn, A.J., Al-Mohammadi, S.M. & Butler, T.J. 1998, Malnutrition and developmental defects of enamel in 2- to 6-year-old Saudi boys. *Caries Research* 32: 181-92.
- Rugg-Gunn, A.J., al-Mohammadi, S.M. & Butler, T.J. 1997, Effects of fluoride level in drinking water, nutritional status, and socio-economic status on

- the prevalence of developmental defects of dental enamel in permanent teeth in Saudi 14-year-old boys. *Caries Research* 31: 259-67.
- Saber, A.M., Altoukhi, D.H., Horaib, M.F., El-Housseiny, A.A., Alamoudi, N.M. & Sabbagh, H.J. 2018, Consequences of early extraction of compromised first permanent molar: A systematic review. *BMC Oral Health* 18: 59,018-0516-4.
- Sahlberg, C., Pavlic, A., Ess, A., Lukinmaa, P.L., Salmela, E., Alaluusua, S. 2013, Combined effect of amoxicillin and sodium fluoride on the structure of developing mouse enamel in vitro. *Archives of Oral Biology* 58: 1155-64.
- Saitoh, M., Nakamura, Y., Hanasaki, M., Saitoh, I., Murai, Y., Kurashige, Y., Fukumoto, S., Asaka, Y., Yamada, M., Sekine, M., Hayasaki, H. & Kimoto, S. 2018, Prevalence of molar incisor hypomineralization and regional differences throughout Japan. *Environmental Health and Preventive Medicine* 23: 55,018-0748-6.
- Sanchez, A.R., Rogers, R.S., & Sheridan, P.J. 2004, Tetracycline and other tetracycline-derivative staining of the teeth and oral cavity. *International Journal of Dermatology* 43: 709-15.
- Schmalzfuss, A., Stenhagen, K.R., Tveit, A.B., Crossner, C.G. & Espelid, I. 2016, Canines are affected in 16-year-olds with molar-incisor hypomineralisation (MIH): An epidemiological study based on the Tromso study: "fit futures". *European Archives of Paediatric Dentistry* 17: 107-13.
- Schwendicke, F., Elhennawy, K., Reda, S., Bekes, K., Manton, D.J. & Krois, J. 2019, Corrigendum to "global burden of molar incisor hypomineralization" [J. dent. 68C (2018) 10-18]. *Journal of Dentistry* 80: 89-92.
- Schwendicke, F., Elhennawy, K., Reda, S., Bekes, K., Manton, D.J. & Krois, J. 2018, Global burden of molar incisor hypomineralization. *Journal of Dentistry* 68: 10-8.
- Seow, W.K., Ford, D., Kazoullis, S., Newman, B. & Holcombe, T. 2011, Comparison of enamel defects in the primary and permanent dentitions of children from a low-fluoride district in Australia. *Pediatric Dentistry* 33: 207-12.
- Serna Munoz, C., Perez Silva, A., Solano, F., Castells, M., Vicente, A., Ortiz Ruiz, A. 2018, Effect of antibiotics and NSAIDs on cyclooxygenase-2 in the enamel mineralization. *Scientific Reports* 8:4132-4132.
- Sheoran, N., Garg, S., Damle, S.G., Dhindsa, A., Opal, S. & Gupta, S. 2014, Esthetic management of developmental enamel opacities in young permanent maxillary incisors with two microabrasion techniques--a split mouth study. *Journal of Esthetic and Restorative Dentistry* 26: 345-52.
- Sidaly, R., Schmalzfuss, A., Skaare, A.B., Sehic, A., Stiris, T. & Espelid, I. 2016, Five-minute apgar score ≤ 5 and molar incisor hypomineralisation (MIH) - a case control study. *BMC Oral Health* 17: 25,016-0253-5.
- Silva, M.J., Scurrah, K.J., Craig, J.M., Manton, D.J. & Kilpatrick, N. 2016, Etiology of molar incisor hypomineralization - A systematic review. *Community Dentistry and Oral Epidemiology* 44: 342-53.
- Simmer, J.P. & Fincham, A.G. 1995, Molecular mechanisms of dental enamel formation. *Critical Reviews in Oral Biology & Medicine* 2: 84-108.

- Simmer, J.P. & Hu, J.C. 2002, Expression, structure, and function of enamel proteinases. *Connective Tissue Research* 43: 441-9.
- Simmer, J.P., Hu, Y., Lertlam, R., Yamakoshi, Y. & Hu, J.C. 2009, Hypomaturation enamel defects in *Klk4* knockout/*LacZ* knockin mice. *The Journal of Biological Chemistry* 284: 19110-21.
- Small, B.W. & Murray, J.J. 1978, Enamel opacities: Prevalence, classifications and aetiological considerations. *Journal of Dentistry* 6: 33-42.
- Souto-Souza, D., da Consolacao Soares, M.E., Rezende, V.S., de Lacerda Dantas, P.C., Galvao, E.L. & Falci, S.G.M. 2018, Association between developmental defects of enamel and celiac disease: A meta-analysis. *Archives of Oral Biology* 87: 180-90.
- Souza, J.F., Costa-Silva, C.M., Jeremias, F., Santos-Pinto, L., Zuanon, A.C. & Cordeiro, R.C. 2012, Molar incisor hypomineralisation: Possible aetiological factors in children from urban and rural areas. *European Archives of Paediatric Dentistry* 13: 164-70.
- Soviero, V., Haubek, D., Trindade, C., Da Matta, T. & Poulsen, S. 2009, Prevalence and distribution of demarcated opacities and their sequelae in permanent 1st molars and incisors in 7 to 13-year-old Brazilian children. *Acta Odontologica Scandinavica* 67: 170-5.
- Sönmez, H. & Saat, S. 2017, A clinical evaluation of deproteinization and different cavity designs on resin restoration performance in MIH-affected molars: Two-year results. *The Journal of Clinical Pediatric Dentistry* 41: 336-42.
- Sönmez, H., Yildirim, G. & Bezgin, T. 2013, Putative factors associated with molar incisor hypomineralisation: An epidemiological study. *European Archives of Paediatric Dentistry* 14: 375-80.
- Suckling, G.W., Herbison, G.P. & Brown, R.H. 1987, Etiological factors influencing the prevalence of developmental defects of dental enamel in nine-year-old New Zealand children participating in a health and development study. *Journal of Dental Research* 66: 1466-9.
- Suckling, G.W., Pearce, E.I. & Cutress, T.W. 1976, Developmental defects of enamel in New Zealand school children. *New Zealand Dental Journal* 72: 201-10.
- Suga, S. 1989, Enamel hypomineralization viewed from the pattern of progressive mineralization of human and monkey developing enamel. *Advances in Dental Research* 3: 188-98.
- Tagelsir, A., Dean, J.A., Eckert, G.J. & Martinez-Mier, E.A. 2018, U.S. pediatric dentists' perception of molar incisor hypomineralization. *Pediatric Dentistry* 40: 272-8.
- Taylor, G.D., Pearce, K.F. & Vernazza, C.R. 2019, Management of compromised first permanent molars in children: Cross-sectional analysis of attitudes of UK general dental practitioners and specialists in paediatric dentistry. *International Journal of Paediatric Dentistry* 29:267-80.
- Teixeira, R.J.P.B., Andrade, N.S., Queiroz, L.C.C., Mendes, F.M., Moura, M.S., Moura, L.F.A.D. & Lima, M.D.M. 2018, Exploring the association between genetic and environmental factors and molar incisor hypomineralization: Evidence from a twin study. *International Journal of Paediatric Dentistry* 28: 198-206.

- The Finnish Dental Association, 2018a. *Statistics of specialized dentists*. Available from <https://www.hammaslaakariliitto.fi/fi/liiton-toiminta/tutkimukset-ja-tilastot/tilastot/erikoishammaslaakaritilasto#.XMgUrugzbIV>
- The Finnish Dental Association, 2018b. *Statistics of dentists by hospital district*. Available from <https://www.hammaslaakariliitto.fi/fi/liiton-toiminta/tutkimukset-ja-tilastot/tilastot/hammaslaakarit-sairaanhoitopiireittain#.XqRrrnVKjIU>
- Thesleff, I. & Nieminen, P. 2005, Tooth induction. In *Encyclopedia of life sciences*. John Wiley & Sons, Ltd.
- Thylstrup, A. & Fejerskov, O. 1978, Clinical appearance and surface distribution of dental fluorosis in permanent teeth in relation to histological changes. *Community Dentistry and Oral Epidemiology* 6: 315-28.
- Todd, S.R., Dahlgren, F.S., Traeger, M.S., Beltran-Aguilar, E.D., Marianos, D.W., Hamilton, C., McQuiston, J.H. & Regan, J.J. 2015, No visible dental staining in children treated with doxycycline for suspected rocky mountain spotted fever. *The Journal of Pediatrics* 166: 1246-51.
- Tourino, L.F., Correa-Faria, P., Ferreira, R.C., Bendo, C.B., Zarzar, P.M. & Vale, M.P. 2016, Association between molar incisor hypomineralization in schoolchildren and both prenatal and postnatal factors: A population-based study. *PLoS One* 11: e0156332.
- Tseveenjav, B., Furuholm, J., Mulic, A., Valen, H., Maisala, T., Turunen, S., Varsio, S., Auero, M. & Tjäderhane, L. 2018, Survival of extensive restorations in primary molars: 15-year practice-based study. *International Journal of Paediatric Dentistry* 28: 249-56.
- Turner, J.G. 1912, *Two Cases of Hypoplasia of Enamel* 73-76.
- Uhlen, M.M., Valen, H., Karlsen, L.S., Skaare, A.B., Bletsa, A., Ansteinsson, V. & Mulic, A. 2019, Treatment decisions regarding caries and dental developmental defects in children - a questionnaire-based study among Norwegian dentists. *BMC Oral Health* 19: 80,019-0744-2.
- Uusitalo, L., Nyberg, H., Pelkonen, M., Sarlio-Lähteenkorva, S., Hakulinen-Viitanen, T. & Virtanen, S. 2012, *Imeväisikäisten ruokinta Suomessa vuonna 2010*. National Institute for Health and Welfare, Helsinki.
- Van Amerongen, W.E. & Kreulen, C.M. 1995, Cheese molars - a pilot study of the etiology of the hypocalcifications in first permanent molars. *Journal of Dentistry for Children* 62: 266-9.
- Van der Tas, J.T., Elfrink, M.E., Vucic, S., Heppe, D.H., Veerkamp, J.S., Jaddoe, V.W., Rivadeneira, F., Hofman, A., Moll, H.A. & Wolvius, E.B. 2016, Association between bone mass and dental hypomineralization. *Journal of Dental Research* 95: 395-401.
- Vargas-Ferreira, F., Salas, M.M., Nascimento, G.G., Tarquinio, S.B., Faggion, C.M.Jr., Peres, M.A., Thomson, W.M. & Demarco, F.F. 2015, Association between developmental defects of enamel and dental caries: A systematic review and meta-analysis. *Journal of Dentistry* 43: 619-28.
- Vargas-Ferreira, F., Zeng, J., Thomson, W.M., Peres, M.A. & Demarco, F.F. 2014, Association between developmental defects of enamel and dental caries in schoolchildren. *Journal of Dentistry* 42: 540-6.

- Vieira, A.R. 2019, On the genetics contribution to molar incisor hypomineralization. *International Journal of Paediatric Dentistry* 29: 2-3.
- Vieira, A.R. & Manton, D.J. 2019, On the variable clinical presentation of molar-incisor hypomineralization. *Caries Research* 53: 482-8.
- Volovitz, B., Shkap, R., Amir, J., Calderon, S., Varsano, I. & Nussinovitch, M. 2007, Absence of tooth staining with doxycycline treatment in young children. *Clinical Pediatrics* 46: 121-6.
- Walshaw, E., Noble, F., Conville, R., Anne Lawson, J., Hasmun, N., Rodd, H. 2019, Molar incisor hypomineralisation and dental anomalies: A random or real association? *International Journal of Paediatric Dentistry* Epub ahead of print.
- Wang, S.L., Chen, T.T., Hsu, J.F., Hsu, C.C., Chang, L.W., Ryan, J.J., Guo, Y.L. & Lambert, G.H. 2003, Neonatal and childhood teeth in relation to perinatal exposure to polychlorinated biphenyls and dibenzofurans: Observations of the Yucheng children in Taiwan. *Environmental Research* 93: 131-7.
- Weerheijm, K.L., Duggal, M., Mejäre, I., Papagiannoulis, L., Koch, G., Martens, L.C. & Hallonsten, A.L. 2003, Judgement criteria for molar incisor hypomineralisation (MIH) in epidemiologic studies: A summary of the european meeting on MIH held in Athens, 2003. *European Journal of Paediatric Dentistry* 4: 110-3.
- Weerheijm, K.L., Groen, H.J., Beentjes, V.E. & Poorterman, J.H. 2001a, Prevalence of cheese molars in eleven-year-old Dutch children. *ASDC Journal of Dentistry for Children* 68: 259-62.
- Weerheijm, K.L., Jälevik, B. & Alaluusua, S. 2001b, Molar-incisor hypomineralisation. *Caries Research* 35: 390-1.
- Welbury, R., Duggal, M.S. & Hosey, M.T. 2012, *Pediatric Dentistry*. 12th ed. Oxford, United Kingdom: Oxford University Press.
- Whatling, R. & Fearne, J.M. 2008, Molar incisor hypomineralization: A study of aetiological factors in a group of UK children. *International Journal of Paediatric Dentistry* 18: 155-62,
- Wong, F.S. & Winter, G.B. 2002, Effectiveness of microabrasion technique for improvement of dental aesthetics. *British Dental Journal* 193: 155-8.
- Wong, H.M., McGrath, C., Lo, E.C. & King, N.M. 2006, Association between developmental defects of enamel and different concentrations of fluoride in the public water supply. *Caries Research* 40: 481-6.
- Wong, H.M., Peng, S.M., Wen, Y.F., King, N.M. & McGrath, C.P. 2014, Risk factors of developmental defects of enamel - a prospective cohort study. *PloS One* 9: e109351.
- Wong, H.M., Wen, Y.F., King, N.M. & McGrath, C.P. 2016, Longitudinal changes in developmental defects of enamel. *Community Dentistry and Oral Epidemiology* 44: 255-62.
- Working group set up by the Finnish Medical Society Duodecim and the Finnish Dental Society Apollonia. *Tooth restoration: Current Care Guidelines*. Helsinki; The Finnish Medical Society Duodecim, 2018.
- World Health Organization 1997, *Oral health surveys basic methods*. 4th ed. Geneva: World Health Organization.
- Wright, J.T., Carrion, I.A., Morris, C. 2015, The molecular basis of hereditary enamel defects in humans. *Journal of Dental Research* 96:52-61.

- Wright, J.T., Hall, K.I. & Yamauchi, M. 1997, The enamel proteins in human amelogenesis imperfecta. *Archives of Oral Biology* 42: 149-59.
- Wright, J.T., Johnson, L.B. & Fine, J.D. 1993, Development defects of enamel in humans with hereditary epidermolysis bullosa. *Archives of Oral Biology* 38: 945-55.
- Xie, Z., Kilpatrick, N.M., Swain, M.V., Munroe, P.R. & Hoffman, M. 2008, Transmission electron microscope characterisation of molar-incisor-hypomineralisation. *Journal of Materials Science. Materials in Medicine* 19: 3187-92.
- Zagdwon, A.M., Fayle, S.A. & Pollard, M.A. 2003, A prospective clinical trial comparing preformed metal crowns and cast restorations for defective first permanent molars. *European Journal of Paediatric Dentistry* 4: 138-42.
- Zhao, D., Dong, B., Yu, D., Ren, Q. & Sun, Y. 2018, The prevalence of molar incisor hypomineralization: Evidence from 70 studies. *International Journal of Paediatric Dentistry* 28: 170-9.
- Zhou, L. & Corruccini, R.S. 1998, Enamel hypoplasias related to famine stress in living chinese. *American Journal of Human Biology* 10: 723-33.