










**ESC**European Society
of CardiologyEuropean Heart Journal (2020) **41**, 1932–1940
doi:10.1093/eurheartj/ehz614**CLINICAL REVIEW***Controversies in cardiovascular medicine*

Uncertainties and challenges in surgical and transcatheter tricuspid valve therapy: a state-of-the-art expert review

Chun Chin Chang^{1†}, Kevin M. Veen^{2†}, Rebecca T. Hahn ³, Ad J.J.C. Bogers², Azeem Latib ⁴, Frans B.S. Oei², Mohammad Abdelghani^{5,6}, Rodrigo Modolo ^{6,7}, Siew Yen Ho⁸, Mohamed Abdel-Wahab⁹, Khalil Fattouch^{10,11}, Johan Bosmans¹², Kadir Caliskan ¹, Maurizio Taramasso ¹³, Patrick W. Serruys ¹⁴, Jeroen J. Bax ¹⁵, Nicolas M.D.A. van Mieghem¹, Johanna J.M. Takkenberg ², Philip Lurz⁹, Thomas Modine¹⁶, and Osama Soliman ^{1*}

¹Department of Cardiology, Thoraxcenter, Erasmus University Medical Center, Doctor Molewaterplein 40, 3015 GD Rotterdam, Netherlands; ²Department of Cardiothoracic Surgery, Thoraxcenter, Erasmus University Medical Center, Doctor Molewaterplein 40, 3015 GD Rotterdam, Netherlands; ³Structural Heart & Valve Center, New York Presbyterian Hospital, Columbia University Medical Center, 161 Fort Washington Avenue, New York, NY 10032, USA; ⁴Department of Cardiology, Montefiore Medical Center, 3400 Bainbridge Ave, The Bronx, New York, NY, USA; ⁵Heart Center, Segeberger Kliniken, Am Kurpark 1, 23795, Bad Segeberg, Germany; ⁶Department of Cardiology, Academic Medical Center, University of Amsterdam, Meibergdreef 9, 1105 AZ Amsterdam, the Netherlands; ⁷Cardiology Division, Department of Internal Medicine, University of Campinas (UNICAMP), Campinas- SP, 13083-970, Brazil; ⁸Brompton Cardiac Morphology Unit, Royal Brompton Hospital, Imperial College London, London, SW7 2AZ UK; ⁹Cardiology Department, Heart Center Leipzig, University Hospital, Strümpellstraße 39, 04289 Leipzig, Germany; ¹⁰Department of Cardiovascular Surgery, GVM Care and Research, Maria Eleonora Hospital, Viale Regione Siciliana 1571, 90100 Palermo, Italy; ¹¹GVM Care and Research, Maria Cecilia Hospital, Via Madonna di Genova, 1, 48033, Cotignola, Italy; ¹²Department of Cardiology, University Hospital Antwerp, Wilrijkstraat 10, 2650 Edegem, Belgium; ¹³Department of Cardiovascular Surgery, University Hospital of Zürich, University of Zürich, Rämistrasse 100, 8091 Zürich, Switzerland; National Heart and Lung Institute; ¹⁴National Heart and Lung Institute, Imperial College London, Guy Scadding Building, Dovehouse St, Chelsea, London SW3 6LY, UK; ¹⁵Department of Cardiology, Heart Lung Center, Leiden University Medical Center, Albinusdreef 2, 2333 ZA Leiden, Netherlands; and ¹⁶Department of Cardiovascular Surgery, Hôpital Cardiologique CHRU de Lille, 2 Avenue Oscar Lambret, 59000 Lille, France

Received 18 January 2019; revised 4 April 2019; editorial decision 9 August 2019; accepted 9 August 2019; online publish-ahead-of-print 11 September 2019

Tricuspid regurgitation (TR) is a frequent and complex problem, commonly combined with left-sided heart disease, such as mitral regurgitation. Significant TR is associated with increased mortality if left untreated or recurrent after therapy. Tricuspid regurgitation was historically often disregarded and remained undertreated. Surgery is currently the only Class I Guideline recommended therapy for TR, in the form of annuloplasty, leaflet repair, or valve replacement. As growing experience of transcatheter therapy in structural heart disease, many dedicated transcatheter tricuspid repair or replacement devices, which mimic well-established surgical techniques, are currently under development. Nevertheless, many aspects of TR are little understood, including the disease process, surgical or interventional risk stratification, and predictors of successful therapy. The optimal treatment timing and the choice of proper surgical or interventional technique for significant TR remain to be elucidated. In this context, we aim to highlight the current evidence, underline major controversial issues in this field and present a future roadmap for TR therapy.

Keywords

Tricuspid valve • Tricuspid regurgitation • Imaging • Treatment • Outcome • Risk • Heart failure

Introduction

Tricuspid regurgitation (TR) is commonly detected on echocardiography.¹ Moderate/severe TR is associated with an increased risk for cardiac and all-cause mortality.^{2,3} A recent meta-analysis

demonstrated that moderate/severe TR is associated with a two-fold increased mortality risk compared with no/mild TR, which seems to be independent of pulmonary pressures and right heart failure (HF).⁴ Topilsky *et al.*⁵ reported that quantitative measures of TR were associated with increased mortality in patients with left ventricular (LV)

* Corresponding author. Email: o.i.soliman@gmail.com

† These authors contributed equally to this work.

Published on behalf of the European Society of Cardiology. All rights reserved. © The Author(s) 2019. For permissions, please email: journals.permissions@oup.com.

systolic dysfunction. These evidences may push towards an earlier indication of correction of TR.

Tricuspid regurgitation remains undertreated as a result of our limited understanding of the disease and how to quantify it.^{6–8} Surgery is currently the only Class I Guideline Recommended therapy for TR,^{9,10} which is most often performed during left-sided heart surgery. Previous estimates indicate that <1% of patients undergo tricuspid valve (TV) surgery.¹¹ The operative mortality of isolated TV surgery could be high due to the late referral, multiple comorbidities, and right ventricle (RV) remodelling.^{12,13} Due to the paucity of evidence, American and European guideline recommendations for the management of TR are limited, and the timing for surgical intervention is still debated.^{9,10} As the management of valvular heart disease moves towards less invasive surgical and transcatheter therapies, several techniques and devices are applied to the TV.^{14,15} Nevertheless, many aspects of TR are little understood. In this context, we aim to highlight controversial issues and present a future roadmap for TR therapy.

Pathophysiology of tricuspid regurgitation and rationale for therapy

With the growing incidence of atrial fibrillation,¹⁶ the use of intracardiac devices,¹⁷ and the global epidemic of valvular heart disease, the prevalence of TR is likely to increase.¹⁸ Recently, Topilsky *et al.*¹⁹ reported the prevalence of TR (0.55%) in a community setting which was about one-fourth of all left-sided valve disease and similar to the prevalence of aortic stenosis. The distribution pattern of TR was primary in 14.6% and secondary in 85.4% of patients.¹⁹ Primary TR results from primary abnormalities of the TV apparatus and can be divided into congenital and acquired disease. The latter may include rheumatic disease, carcinoid disease, infective endocarditis, degenerative, or iatrogenic disease from implantable device lead-induced TV injury/dysfunction or RV endomyocardial biopsy.²⁰ Secondary TR is due to annular dilatation (with or without leaflet tethering) or RV dilatation (typically associated with leaflet tethering), with left-sided heart disease and/or pulmonary hypertension being the most frequent aetiologies.^{20,21} The disease process of TR is not fully understood and is likely influenced by the underlying aetiology, concomitant heart disease, and haemodynamic abnormalities.²² Age, presence of device leads, mild TR at baseline, and receiving left-sided valvular surgery (without concomitant TV surgery) have been shown as predictors of development of significant TR.²³

Currently, long-term data on the beneficial effect of isolated surgical TV therapy compared to medical therapy remains scarce.²⁴ According to data from the National Inpatient Sample files from 2004 to 2013 in the USA, isolated TV surgery was performed in 15% of all patients who underwent TV surgery, with high in-hospital mortality rate (8–10%) that has remained unchanged over the 10-year period.^{12,13} This suboptimal outcome is likely related to comorbidities and referral timing rather than to the risk of isolated TV surgery.^{25,26} Furthermore, residual or late significant TR after mitral valve replacement is independently associated with poor outcome.²⁷ Adding TV repair during left-sided heart surgery did not increase

surgical risk and could result in reverse RV remodelling with reduction of symptoms.^{28–30} Therefore, a more aggressive approach to correct concomitant TR in the presence of annular dilatation may reduce the chance of late TR progression after left-sided valve surgery.

Specific anatomical considerations interfering with tricuspid valve

The TV is a complex apparatus consisting of leaflets, tricuspid annulus, tendinous cords, papillary muscles, and the associated RV. The normal tricuspid annulus is a saddle-shaped ellipsoid surrounded by several critical anatomical structures, including the atrioventricular node, right coronary artery, coronary sinus ostium, and non-coronary sinus of Valsalva (*Figure 1A*). Multiple TV structural abnormalities may be encountered as a result of different aetiologies with various morphological changes. Tricuspid annulus dilation, right atrium/RV dilation, and leaflet malcoaptation are the most common changes in secondary TR. When tricuspid annulus dilation occurs, its shape becomes more circular and planar (*Figure 1B*).^{31,32} It is usually observed in the anatomical location of anterolateral free wall and posterior border. Leaflet malcoaptation may occur due to inadequate leaflet length to cover the dilated annulus, or in the absence of adequate chordal redundancy resulting in leaflet tethering. The region of malcoaptation occurs often centrally or extends from the antero-septal commissure towards the posteroseptal commissure.^{32,33}

Guideline recommendations for tricuspid regurgitation therapy

Tricuspid regurgitation often presents as a component of a complex heart disease and its clinical manifestations range from subtle symptoms to advanced HF with multiorgan involvement. At the far end of the disease spectrum, there may be a point of no return where irreversible RV dysfunction persists regardless of therapy. Therefore, a timely therapy is essential to avoid worsening of causative pathology and the onset of complications caused by TR. However, the indication and optimal timing of surgery remain controversial due to insufficient evidence.

The comparison of the American³² and the European guidelines⁹ for the management of TR is provided in the [Supplementary material online, Table S1](#). In both guidelines, most of the Classes I and IIa indications for intervening on significant TR require concomitant left-sided valve surgery. Isolated TV surgery is recommended in patients with severe TR who are either symptomatic or are developing progressive RV dilatation/dysfunction.⁹ Nevertheless, patients with severe TR are often asymptomatic for a long period of time and symptoms are not specific, contributing to late referral for surgery.³⁴ Recently, an extended five-stage classification of secondary TR was proposed to help categorize the severity of disease presenting late in the disease process.¹⁵ Symptoms, severity of TR, leaflet coaptation, tethering, annular remodelling, and RV function need to be evaluated to determine the timing and options of treatment.

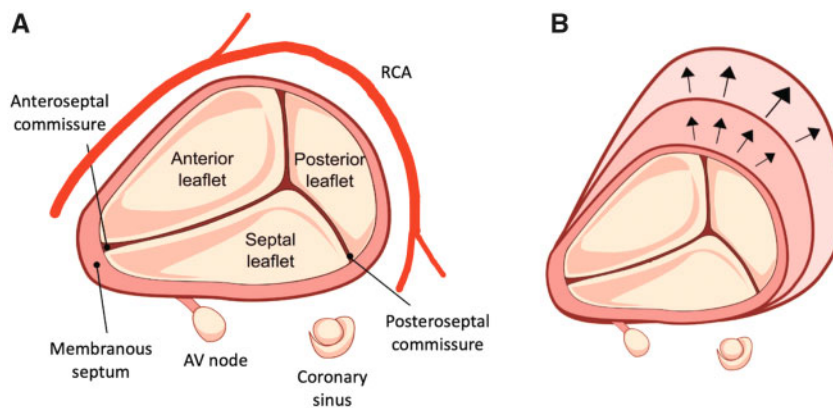


Figure 1 Anatomical structure of the tricuspid valve. (A) Normal and (B) dilated tricuspid annulus.

On the other hand, the 'optimal medical treatment' has not yet been defined for right-sided HF. Recently, the American Heart Association released a scientific statement on evaluation and management of right-sided HF.³⁵ Based on the document, medical treatment of right-sided HF should focus on volume management (diuretics and renal replacement therapies), afterload reduction (pulmonary vasodilators) and, if needed, mechanical circulatory support.

Risk stratification and heart team decision-making

In the past decades several models were developed to predict outcome in cardiac surgery.³⁶ Nevertheless, until recently, no specific risk model addressed isolated TV surgery. LaPar *et al.*³⁷ used the Society of Thoracic Surgeons (STS) database to develop a risk score for patients undergoing TV surgery. They included age, sex, stroke, haemodialysis, LV ejection fraction, chronic lung disease, New York Heart Association functional class, reoperation, and operative characteristics in their models. Although the authors developed well-discriminated and calibrated models, they could not include indices of RV dysfunction and liver dysfunction, because these data were simply not collected. Testing these models will require large clinical datasets, however, datasets like the STS database are currently designed for the majority of patients (with left-sided valve surgery) and do not specifically address the right heart.³⁸ Therefore, we propose a standardized approach and risk stratification process for heart team decision-making. Our proposed stepwise assessment is as follows (*Take home figure*):

- Step 1: Patient demographics (age and sex).
- Step 2: Clinical symptoms (New York Heart Association functional class).
- Step 3: Comorbidities [stroke, major organ dysfunction (lung, kidney, and liver)].
- Step 4: Cardiac pathological remodelling (TR severity, local remodelling of TV, RV remodelling, pulmonary vascular resistance, and left-sided heart disease).

Step 5: Surgical or interventional characteristics (isolated, combined, elective, or emergent).

Step 6: Combining 3R's (Risk, Reversibility, and Recurrence) information to allocate patient profiles.

Step 7: Decision-making by the multidisciplinary heart team to provide appropriate treatment (surgical, minimal invasive surgical, transcatheter, pharmacological, or palliative).

Imaging assessment for tricuspid regurgitation treatment

Imaging assessment for TR treatment runs in three phases: (i) patient assessment for decision-making; (ii) peri-operative/peri-interventional planning and guidance; and (iii) assessing therapeutic efficacy and durability during follow-up.

Imaging for decision-making in patients with tricuspid regurgitation

A stepwise approach using multimodality imaging to assessment of TR is shown in *Table 1*. First, determining the presence of TR, as well as the TV morphology and aetiology. Second is to evaluate TR severity. Third is to assess the haemodynamic impact in terms of regurgitant volume and coexisting pressure overload. Fourth is to identify the presence (and severity) of associated left-sided heart disease. Finally, to assess the presence (and severity) of RV remodelling. Two-dimensional echocardiography, including tissue Doppler imaging and RV strain, is currently the most widely used imaging modality (*Table 2*). Three-dimensional techniques such as three-dimensional echocardiography, cardiovascular magnetic resonance, or multislice computed tomography are powerful tools for assessing the TV annulus, as well as the RV and LV size and global function.³⁹

The current echocardiographic criteria for grading TR only consider three grades of severity: mild, moderate, and severe.⁴⁰ In the SCOUT trial,⁴¹ despite the severity of TR reduced from 'severe' to 'severe', the equivalent quantitative reduction of a 'grade' of TR was associated with an increase in stroke volume and improved quality of

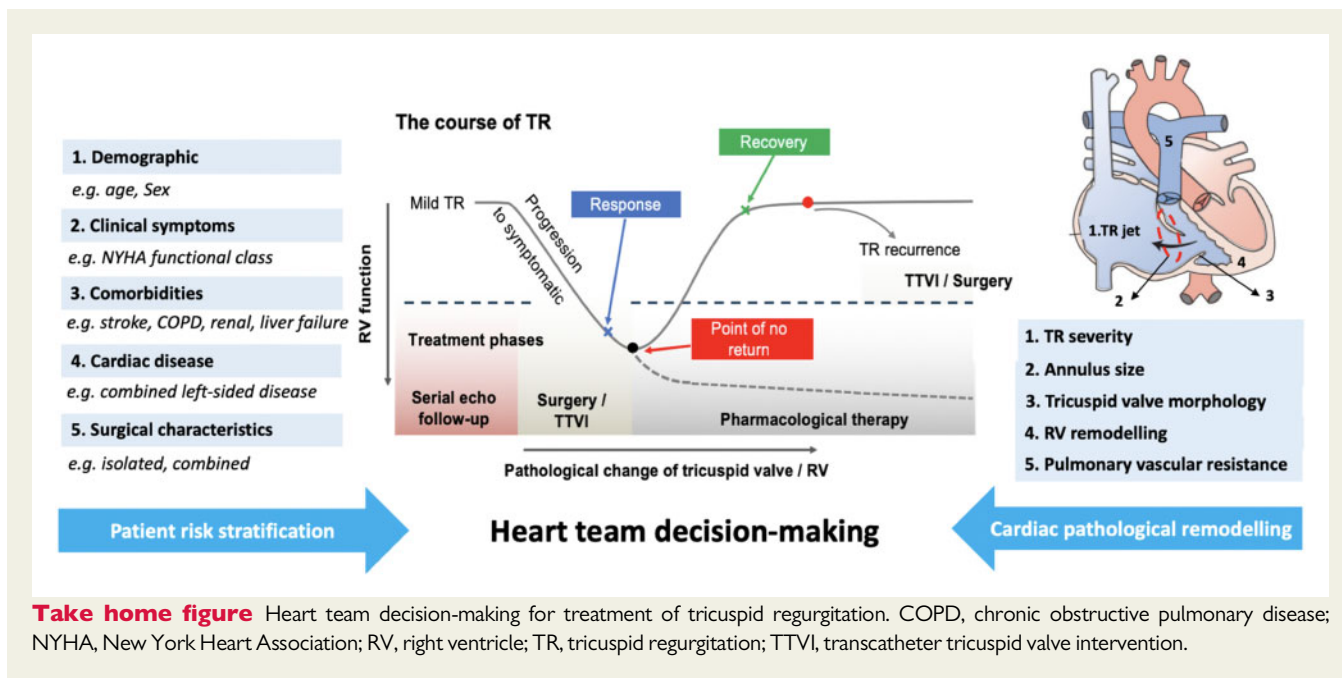


Table 1 Five-stepwise approach for evaluations of patients with suspected or established tricuspid regurgitation

Target	Imaging modalities needed to evaluate
Tricuspid valve morphology (TV annulus dilatation and leaflet tethering)	TTE and TOE (2DE and 3DE)
TR severity	2DE/3DE with Doppler, CMR if unclear
Haemodynamic impact	2DE with Doppler
Preload (RV filling)	2DE and M-mode for longitudinal function
Afterload (pulmonary atrial pressure and pulmonary vascular resistance)	3DE for RV volumes
RV size and function	
Left-sided heart disease	2DE/3DE
Right heart remodelling and function	Ideally 3D modality for RV size and function CMR or 4D MSCT or 3DE > 2DE 3DE >> 2DE For preclinical studies and first-in-man studies or small efficacy studies, CMR and 4D CT may be appropriate. For Large studies and routine care, 3DE is good alternative

2DE, two-dimensional echocardiography; 3DE, three-dimensional echocardiography; CMR, cardiovascular magnetic resonance; MSCT, multislice computed tomography; RV, right ventricle; TOE, transoesophageal echocardiography; TR, tricuspid regurgitation; TTE, transthoracic echocardiogram.

life. Therefore, an extended five-grade scale of 'mild, moderate, severe, massive, and torrential' has been proposed to accommodate the large variability amongst patients with severe TR.⁴² Moreover, recent publications have shown that the current cut-off values for quantitative parameters used to assess TR severity are inadequate to quantify the burden on the RV and it is likely that lower threshold values of effective regurgitant orifice area (EROA) and regurgitant volume define severe TR.⁴³ This finding was also supported by the study of Bartko *et al.*⁴⁴ showing a significant increase in mortality and morbidity for EROA ≥ 0.2 cm² and regurgitant volume ≥ 20 mL in HF patients with reduced ejection fraction. This may potentially impact the therapeutic decision-making, particularly timing for intervention.

Imaging for peri-operative/peri-interventional planning and guidance

Transthoracic echocardiography (TTE) supported by transoesophageal echocardiography (TOE) is the main tool for preplanning. For transcatheter therapy targeting the leaflets such as edge-to-edge repair, TOE, particularly using transgastric views is essential for assessment of leaflet morphology, coaptation gap, device landing zones and location of main TR jet. Transoesophageal echocardiography guides procedural planning and allows for outcome prediction.⁴⁵ For annuloplasty devices, intracardiac echocardiography may be an alternative,⁴⁶ especially when TOE images are suboptimal.

Multislice computed tomography could aid in TV preplanning for transcatheter therapies mimicking surgical annuloplasty, spacer devices, and transcatheter TV replacement.⁴⁷ It allows for accurate measurement of the TV annulus, device landing zone, relationship between the annulus and right coronary artery, annular tissue quantity and quality, and access selection and guidance.⁴⁸

Table 2 Advantages and limitations of imaging modalities in TR assessment

Imaging technique	Main advantages	Main limitations
2DE	Real-time, versatile, high frame rate	Insufficient for 3D complex structures such as TV annulus, LV, and RV size and function
3DE	Both simultaneous multi-plane imaging and real-time 3D imaging. 3DE is an excellent tool for quantification of ventricular volume and function	Lower frame rate than in 2DE, currently less spatial resolution compared to 2DE, inability to assess tissue characterization such as calcifications or fibrosis
TOE (2DE and 3DE)	Real-time intra-procedural planning and guidance	Four levels of imaging allow a comprehensive evaluation of the valve: mid-oesophageal, deep-oesophageal, transgastric, and deep-transgastric
CMR	TV severity, perfusion, fibrosis, tissue characterization, and chamber quantification	Less versatile
MSCT	Superb resolution, calcification, excellent tool for TV annulus and preplanning, best to assess radiopaque surgical, and percutaneous implants	Radiation and less versatile

2DE, two-dimensional echocardiography; 3DE, three-dimensional echocardiography; CMR, cardiovascular magnetic resonance; LV, left ventricle; MSCT, multislice computed tomography; RV, right ventricle; TOE, transoesophageal echocardiography; TV, tricuspid valve.

Imaging of therapeutic efficacy and durability

Surgical success of TV repair is defined, by imaging in the immediate post-operative period as reduction in TR severity to mild or less and reduction of TV annulus diameter. In the long run, reverse RV remodelling, if present, as well as reduction of the RV afterload, are important imaging endpoints. These are correlated to patients' symptomatic and functional improvement. In contrast, the need for reintervention or mortality is the main clinical endpoints reflecting failure of repair. Ideally, the imaging results of successful transcatheter repair should match those of surgical repair. However, most candidates for transcatheter TV repair are currently patients with advanced RV dysfunction and are often beyond the point of complete repair.

Tricuspid regurgitation therapy—surgical perspective

Tricuspid valve repair (annulus, leaflets, and sub-valvular apparatus)

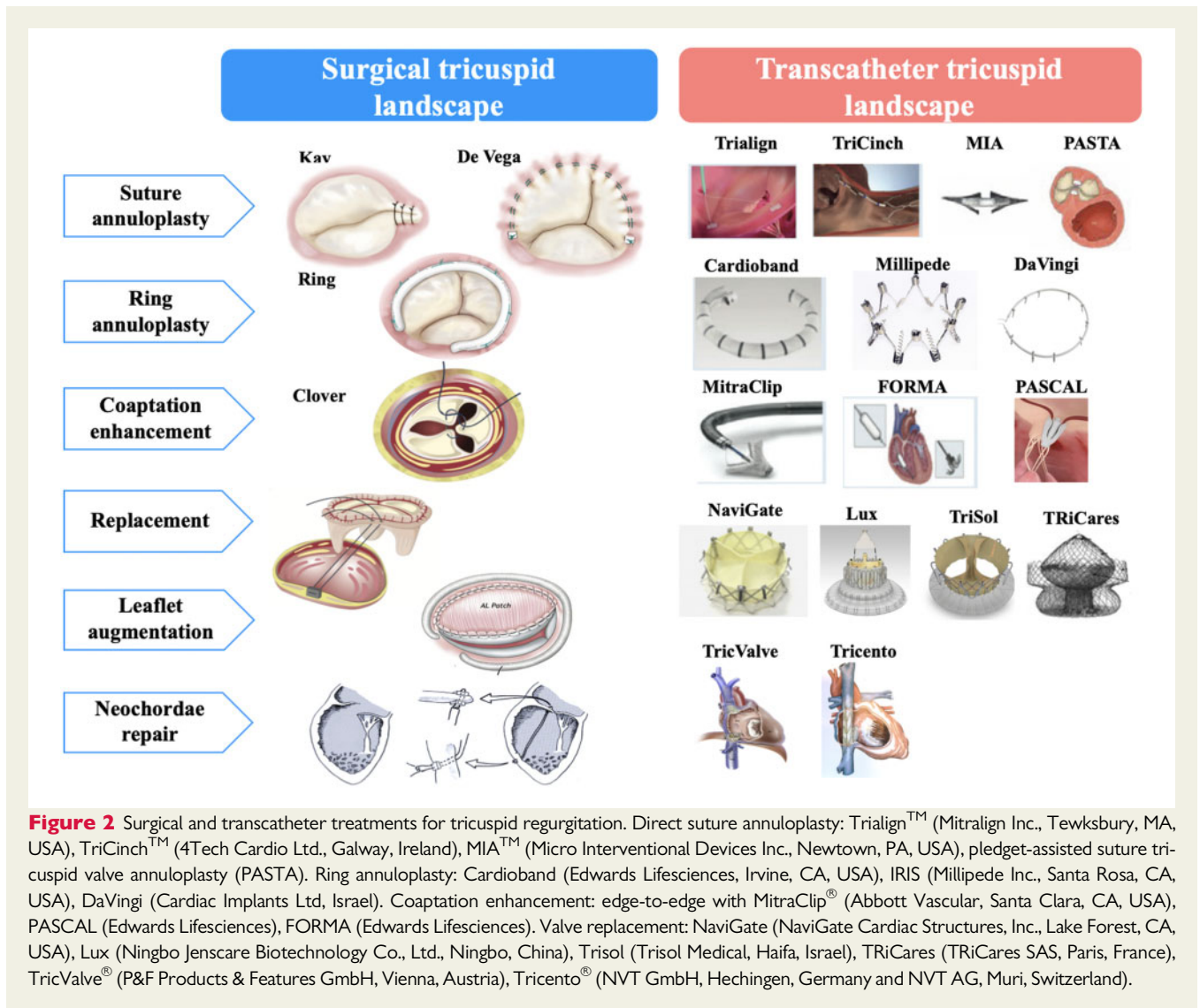
In the setting of secondary TR with primarily annular dilation, a reduction annuloplasty is the most commonly used surgical approach. Now, almost abandoned, the first suture annuloplasty was described by Kay *et al.*⁴⁹ This 'bicuspidization' technique is done by tightening a suture from the anteroposterior commissure to the posteroseptal commissure (Figure 2).⁴⁹ The second technique was described by De Vega *et al.*⁵⁰ It consists of two parallel lines of running sutures starting at the posteroseptal commissure at the annulus level. The suture follows the annulus with a stitch approximately every 5 mm to the fibrous trigone. Thereafter, a pledget is placed and the suture is reversed.⁵⁰ Nowadays, TV annuloplasty using a rigid ring is the most often

applied technique, which provides a lower recurrent rate of significant TR compared to suture or flexible ring annuloplasty.^{51,52} However, the use of a rigid ring was associated with an increased risk of early ring dehiscence.⁵³ Ideally, a ring annuloplasty should meet the following criteria: (i) restoring the three-dimensional shape of the annulus to reduce leaflet stress and tethering; (ii) addressing the remodelling along the RV free wall and also be 'open' at the septal leaflet sector to protect the conduction system; and (iii) being flexible to maintain annular dynamicity and prevent ring dehiscence.^{54,55}

In case of severe leaflet tethering, an annuloplasty alone is usually not sufficient to ensure adequate repair.⁵⁶ Dreyfus *et al.*⁵⁷ described an anterior leaflet augmentation technique to address the tethering. An edge-to-edge technique similar to the Alfieri stitch in mitral valve repair has been performed resulting in a triple 'clover-like' orifice.⁵⁸ In addition, several case reports exist on neochordae repair of the TV.^{59,60} Various other repair techniques specifically addressing a primary cause (e.g. Ebstein anomaly or endocarditis) are reported in literature.^{61,62}

Tricuspid valve replacement

Tricuspid valve replacement is usually reserved for patients with primary TV disease. Nevertheless, the latest consensus is that patients with severe RV dysfunction, very large annulus, or severe tethering may be better served with TV replacement.⁶³ A recent meta-analysis showed comparable outcomes in terms of survival, reoperation, and prosthetic valve failure after TV replacement between biological and mechanical valves. Nonetheless, mechanical prostheses had a higher risk of thrombosis.⁶⁴ These results were derived from observational and retrospective studies. Randomized studies are needed to determine which type of valve is better for TV replacement. Currently, biological prostheses are preferred and offer an option for future transcatheter valve-in-valve implantation.



Surgical controversies

The best timing of surgery in patients with TR remains in question. Repairing the TV in patients with a dilated tricuspid annulus (intraoperative ≥ 70 mm, TTE ≥ 40 mm) without significant TR during left-sided heart surgery has been debated⁶⁵ since 2005 when this concept was initially presented by Dreyfus *et al.*²⁸ This debate is partly fuelled by the lack of evidence for the validity of the conversion of 70 mm as measured intraoperatively to 40 mm on TTE.⁶⁶ Furthermore, since the TV annulus is not planar, even small variations in the ultrasound beam plane may result in substantial differences in the measurement.⁶⁷ The question as to whether repairing a TV with dilated annulus in patients with trace or mild TR at the time of planned mitral valve surgery could improve clinical outcomes will be explored in an ongoing randomized trial (ClinicalTrials.gov identifier: NCT02675244).

As for patients with late or recurrent significant TR after previous left-sided surgery, current guidelines consider this is a Class IIa indication for TV surgery. Yet it has been shown that reoperation on the

TV may be associated with a high mortality.^{68,69} In combination with multiple co-existing comorbidities or old age, many surgeons are reluctant to operate on these patients, especially if pulmonary hypertension or RV failure is present.²⁷

Predictors of a successful surgical tricuspid valve repair

From the surgical perspectives, a successful TV repair is mild or less TR after surgery. Several studies aimed to identify predictors for recurrent TR after surgery (Table 3). Most studies found severe TR and suture annuloplasty are risk factors of recurrent TR after TV repair. Nevertheless, these studies use survival analyses in the context of repeated measures, which is not the preferred approach.⁷⁸ Navia *et al.*⁷⁹ used advanced statistical modelling for repeated echocardiography and showed a higher grade of TR, larger TV annuloplasty ring, presence of pacemaker leads, mitral valve replacement rather than repair, depressed LV function, and advanced LV remodelling to predict TR recurrence. As far as TV morphology is concerned, the

Table 3 Risk factors of recurrent tricuspid regurgitation

Study	Risk factors				
	De Vega vs. ring annuloplasty HR (95% CI)	Severe TR at baseline HR (95% CI)	Higher PASP HR (95% CI)	Female gender HR (95% CI)	Atrial fibrillation HR (95% CI)
Ren (2015) ⁷⁰	1.47 (1.0–1.9)	NS	1.54 (1.1–2.0)	NS	—
Lin (2014) ⁷¹	7.2 (2.7–15.4)	3.6 (1.7–12.1)	NS	NS	9.4 (2.3–94.0)
Ratschiller (2015) ⁷²	—	3.0 (1.2–7.8)	—	2.5 (1.0–5.9)	4.3 (1.0–18.3)
Gatti (2016) ⁷³	2.2 (1.1–4.3)	1.2 (0.6–2.4)	1.3 (0.6–2.9)	—	—
Yoda (2011) ⁷⁴	—	8.23 ^a	NS	—	NS
Jung (2010) ⁷⁵	—	—	—	—	NS
Murashita (2014) ⁷⁶	10.7 (3.7–31.0) ^b	2.8 (1.4–5.7) ^b	—	—	—
Ghanta (2007) ⁷⁷	0.64 (0.1–1.2) ^c	4.0 (3.4–4.7)	1.0 (0.9–1.0)	—	—

—, not reported; CI, confidence interval; HR, hazard ratio; NS, not significant upon univariate analyses; PASP, pulmonary arterial systolic pressure; TR, tricuspid regurgitation.

^aNo confidence interval reported.

^bOnly univariable cox regression model.

^cKay vs. Ring annuloplasty.

tethering distance was found to predict recurrent TR after annuloplasty.⁵⁶ As tethering is usually present among inoperable patients who might be the first target population of transcatheter therapy, the question whether a transcatheter annuloplasty alone will be sufficient need to be answered.

Tricuspid regurgitation therapy—interventional perspective

Following the success of transcatheter aortic valve therapy, there is a large interest in developing transcatheter TV devices. Multiple novel technologies are currently invented for transcatheter TV therapy. Most of these devices are yet in the preclinical or early clinical assessment.¹⁴

Patient selection

The number of patients treated within these transcatheter TV therapy pilot studies is still limited, and most enrolled patients are inoperable or at 'high surgical risk' with chronic secondary TR (Supplementary material online, Table S2). Considering the heterogeneous nature of TR, patient selection by a multidisciplinary heart team is paramount to optimize clinical results and effectiveness of transcatheter TV therapy. We summarized potential target population for future studies investigating whether those patients would benefit from TV interventions (Supplementary material online, Table S3).⁸⁰ As to patients with primary TR, there are only few case reports and some patients with primary TR within TriValve registry.⁸¹ There is insufficient evidence regarding feasibility of transcatheter intervention in this heterogeneous population. An individualized approach is mandatory.

Anatomical challenges

The most common anatomical changes in significant TR are annulus dilatation and leaflet tethering. Specific anatomical considerations should be assessed according to different therapeutic targets. We

summarize the potential anatomical and pathophysiological constraints of transcatheter TV interventions.

- (1) Challenges during catheter navigation
 - a. The angulation between the annular plane and the superior and inferior venae cava complicates the transvenous access.
 - b. The loss of anatomical landmarks under pathologic conditions (right atrial and ventricular dilation) complicates catheter navigation and interferes with proper positioning of repair/replacement devices.
 - c. Pre-existing device leads could interfere with device delivery and deployment.
 - d. Imaging views and quality, which depends on numerous patient characteristics (i.e. mechanical valves in place, chest deformation, oesophageal anatomy/pathologies) but also on the device used for repair.
- (2) Difficulty in proper sizing
 - a. Tricuspid annulus is significantly larger than other valves and is influenced by volume status which might preclude appropriate sizing and device selection.
 - b. Flexibility and fragility of the annulus and the surrounding myocardium counteracts fixation and long-term stability of transcatheter TV replacement devices.
- (3) Increased risk of thrombosis
 - a. The low pressure and slow flow in the right heart chambers might provoke device thrombosis.

Approaches for transcatheter tricuspid valve interventions

As shown in Figure 2, most of devices for transcatheter TV therapy are designed to mimic surgical techniques. Currently, the most widely used technique is the edge-to-edge repair using the MitraClip device (Abbott, Santa Clara, CA, USA) in TV position to improve leaflet coaptation.⁸² Nevertheless, transcatheter repair cannot replace all the types of surgical repair, and several vendors are currently developing transcatheter heart valves for TV replacement. Despite the growing experience in transcatheter TV interventions, we would like to

emphasize that clinical data on most of the devices are not sufficient to conclude on their safety and efficacy. When evaluating these early clinical data, the following issues should be addressed:

- (1) Patients enrolled in first-in-man studies differ markedly in terms of TR severity, EROA, vena contracta area, with some studies focusing on severe TR as compared to torrential TR. This has to be considered when efficacy in TR reduction and potential for clinical improvements of different devices/approaches are assessed.
- (2) General application and comparison between studies are hindered by the differences in study design.
- (3) Clinical and echocardiographic endpoints, device and procedural success, and optimal TR reduction should be clearly defined.
- (4) Most of the surgical data on the TV are derived from patients who underwent left-sided heart surgery which is not fully transferable to dedicated transcatheter interventions.

Lessons learnt from transcatheter left-sided valve therapy

Aortic valve

Transcatheter aortic valve replacement has been an established first-line therapy for high-risk and could be an alternative therapy for surgery in patients with aortic stenosis and intermediate and more recently low risk.^{83,84} With the progress of transcatheter valve therapy, balloon-expandable transcatheter heart valves, which were designed for the aortic position are now being applied for degenerated bioprostheses in TV position.^{85,86} Off-label heterotopic heart valve implantation in the superior/inferior vena cava (preferred is one valve in the inferior vena cava) is currently being tested in patients who are inoperable or at very high surgical risk for TV replacement.^{87,88} Furthermore, dedicated orthotopic/heterotopic devices for TR are in development.⁸⁹ Navia *et al.*⁹⁰ reported the first-in-man results of the NaviGate valve. Several patients received this bioprosthesis with excellent TR reduction.⁹¹ Conduction disturbances requiring pacemaker implantation has been reported in one patient.¹⁴ Tricuspid valve surgery carries a significant risk of conduction disorders requiring permanent pacemaker implantation.⁹² Whether transcatheter TV therapy, particular annuloplasty, and valve replacement, would encounter similar issues is yet unknown.

Mitral valve

Transcatheter therapy for severe functional mitral regurgitation (FMR) associated with HF has increased rapidly recently. Results of two clinical outcome trials, MITRA-FR and COAPT were published.^{93,94} Both trials randomly assigned patients with FMR to MitraClip plus guideline-directed optimal medical treatment (GDMT) or GDMT only. MITRA-FR failed to demonstrate the benefit of MitraClip procedure in terms of a composite endpoint (all-cause death or unplanned hospitalization for HF). Conversely, the COAPT trial showed that the MitraClip procedure significantly reduced HF rehospitalizations and all-cause death during 2-year follow-up. The COAPT trial applied a prespecified approach by a group of HF specialists to evaluate GDMT prior to randomization, and therefore, this trial had a long enrolment period. The conflicting results of the two studies reflect the importance of patient selection before irreversible HF ensues, optimization of medical therapy and the role of a

multidisciplinary heart team. The MitraClip device has been applied to the tricuspid position. The feasibility and safety of edge-to-edge TV repair using the MitraClip device has been reported.^{45,81}

The Cardioband system (Edwards Lifesciences, Irvine, CA, USA) is a transcatheter direct annuloplasty device that mimics surgical repair. The feasibility study in symptomatic patients with FMR demonstrated that Cardioband implantation was effective in reducing mitral regurgitation and was associated with improvement in HF symptoms.⁹⁵ The ACTIVE randomized trial is ongoing to compare Cardioband implantation plus GDMT to GDMT alone in patients with significant FMR (ClinicalTrials.gov identifier: NCT03016975). The tricuspid Cardioband device has CE mark approval and is the first commercially available transcatheter device for the treatment of significant TR. In the TRI-REPAIR study, Cardioband implantation provided favourable clinical and functional outcomes at 6 months.⁹⁶

Nevertheless, how to define an optimal repair is still an unsolved issue. In the recent published mid-term outcomes of TriValve registry including 312 patients with severe TR,⁸² procedural success (defined as patient alive at the end of the procedure, with the device successfully implanted and delivery system retrieved, with a residual TR grade ≤ 2 by the investigators) was achieved in 72.8% of patients and was independently associated with increased mortality. The definition of successful repair remains discrepant across studies investigating transcatheter devices (Supplementary material online, Table S4). In order to adequately compare clinical outcomes after surgical or transcatheter therapy, definitions of clinical endpoints including technical, device, procedural as well as patient success should be refined and standardized in future studies.

Conclusions

With the development of transcatheter therapy, there has been an increasing focus on the treatment of significant TR. Although early safety and efficacy results of transcatheter TV therapy are encouraging, remaining uncertainties including grade of TR severity (quantitative and qualitative), patient selection, risk stratification, timing of intervention, and definition of successful repair warrant further investigations. Due to the complex nature and interaction between TR and HF, the question as to whether a timely transcatheter TV therapy, a minimal invasive intervention, may change the disease process and improve clinical outcomes remains to be answered in prospective studies. This manuscript uses a novel heart-team approach via a comprehensive and a balanced focus on uncertainties, controversies, step-by-step recommendations, and endpoints definitions in TR therapy. Therefore, it provides a framework for randomized clinical trials and registries in the field of transcatheter TV therapy. Since there is no document on the Tricuspid Valve Academic Research Consortium yet, we believe that this work will pave the road as the foundation for such a needed document.

Supplementary material

Supplementary material is available at *European Heart Journal* online.

Funding

This work is supported by The Euro Heart Foundation.

Conflict of interest: R.T.H. is a speaker for Boston Scientific and Bayliss; a speaker and consultant for Abbott Vascular, Edwards Lifescience, Philips Healthcare, and Siemens Healthineers; a consultant for 3Mensio, Medtronic, and Navigate; and is the Chief Scientific Officer for the Echocardiography Core Laboratory at the Cardiovascular Research Foundation for multiple industry-sponsored trials, for which she receives no direct industry compensation. A.L. reports and Advisory Board for Medtronic, Millipede, and Abbott. Consultant for Edwards Lifesciences and Mitralign. R.M. received personal fee from Biosensors not related to the present work. M.T. reports personal fees from Abbott Vascular, Boston Scientific, 4tech, and CoreMedic, outside the submitted work. P.W.S. reports personal fees from Abbott Laboratories, AstraZeneca, Biotronik, Cardialysis, GLG Research, Medtronic, Sino Medical Sciences Technology, Société Europa Digital Publishing, Stentys France, Svelte Medical Systems, Philips/Volcano, St. Jude Medical, Qualimed, and Xeltis, outside the submitted work. J.J.B. reports speaker fees from Abbott and Boehringer Ingelheim. O.S. is the Chairman of the Imaging Core laboratory for numerous Clinical Trials Sponsored by Industry for which he receives no direct financial compensation. And the other authors have no conflict of interest to declare.

References

- Singh JP, Evans JC, Levy D, Larson MG, Freed LA, Fuller DL, Lehman B, Benjamin EJ. Prevalence and clinical determinants of mitral, tricuspid, and aortic regurgitation (the Framingham Heart Study). *Am J Cardiol* 1999;**83**:897–902.
- Nath J, Foster E, Heidenreich PA. Impact of tricuspid regurgitation on long-term survival. *J Am Coll Cardiol* 2004;**43**:405–409.
- Bar N, Schwartz LA, Biner S, Aviram G, Ingbir M, Nachmany I, Margolis G, Sadeh B, Barashi R, Keren G, Topilsky Y. Clinical outcome of isolated tricuspid regurgitation in patients with preserved left ventricular ejection fraction and pulmonary hypertension. *J Am Soc Echocardiogr* 2018;**31**:34–41.
- Wang N, Fulcher J, Abeysuriya N, McGrady M, Wilcox I, Celermaier D, Lal S. Tricuspid regurgitation is associated with increased mortality independent of pulmonary pressures and right heart failure: a systematic review and meta-analysis. *Eur Heart J* 2019;**40**:476–484.
- Topilsky Y, Inojosa JM, Benfari G, Vaturi O, Maltais S, Michelena H, Mankad S, Enriquez-Sarano M. Clinical presentation and outcome of tricuspid regurgitation in patients with systolic dysfunction. *Eur Heart J* 2018;**39**:3584–3592.
- Hahn RT. State-of-the-art review of echocardiographic imaging in the evaluation and treatment of functional tricuspid regurgitation. *Circ Cardiovasc Imaging* 2016;**9**:e005332.
- Dreyfus GD, Martin RP, Chan KM, Dulguerov F, Alexandrescu C. Functional tricuspid regurgitation: a need to revise our understanding. *J Am Coll Cardiol* 2015;**65**:2331–2336.
- Rodes-Cabau J, Hahn RT, Latib A, Laule M, Lauten A, Maisano F, Schofer J, Campelo-Parada F, Puri R, Vahanian A. Transcatheter therapies for treating tricuspid regurgitation. *J Am Coll Cardiol* 2016;**67**:1829–1845.
- Baumgartner H, Falk V, Bax JJ, De Bonis M, Hamm C, Holm PJ, lung B, Lancellotti P, Lansac E, Rodriguez Muñoz D, Rosenhek R, Sjögren J, Tornos Mas P, Vahanian A, Walther T, Wendler O, Windecker S, Zamorano JL, Roffi M, Alfieri O, Agewall S, Ahlsson A, Barbato E, Bueno H, Collet J-P, Coman IM, Czerny J, Delgado V, Fitzsimons D, Folliguet T, Gaemperli O, Habib G, Harringer W, Haude M, Hindricks G, Katus HA, Knuuti J, Kolh P, Leclercq C, McDonagh TA, Piepoli MF, Pierard LA, Ponikowski P, Rosano GMC, Ruschitzka F, Shlyakhto E, Simpson IA, Sousa-Uva M, Stepinska J, Tarantini G, Tchétché D, Aboyans V, Windecker S, Aboyans V, Agewall S, Barbato E, Bueno H, Coca A, Collet J-P, Coman IM, Dean V, Delgado V, Fitzsimons D, Gaemperli O, Hindricks G, lung B, Jüni P, Katus HA, Knuuti J, Lancellotti P, Leclercq C, McDonagh T, Piepoli MF, Ponikowski P, Richter DJ, Roffi M, Shlyakhto E, Simpson IA, Zamorano JL, Kzhdryan HK, Mascherbauer J, Samadov F, Shumavets V, Camp GV, Lončar D, Lovric D, Georgiou GM, Linhartova K, Ihlemann N, Abdelhamid M, Pern T, Turpeinen A, Srbinovska-Kostovska E, Cohen A, Bakhtashvili Z, Ince H, Vavuranakis M, Temesvári A, Gudnason T, Mylotte D, Kuperstein R, Indolfi C, Pya Y, Bajraktari G, Kerimkulova A, Rudzitis A, Mizariene V, Lebrun F, Demarco DC, Oukerraj L, Bouma BJ, Steiger TK, Komar M, De Moura Branco LM, Popescu BA, Uspenskiy V, Foscoli M, Jovicic L, Simkova I, Bunc M, de Prada JAV, Stagmo M, Kaufmann BA, Mahdhaoui A, Bozkurt E, Nesukay E, Brecker SJD, 2017 ESC/EACTS Guidelines for the management of valvular heart disease. *Eur Heart J* 2017;**38**:2739–2791.
- Nishimura RA, Otto CM, Bonow RO, Carabello BA, Erwin JP, Fleisher LA, Jneid H, Mack MJ, McLeod CJ, O'Gara PT, Rigolin VH, Sundt TM, Thompson A. 2017 AHA/ACC Focused Update of the 2014 AHA/ACC Guideline for the management of patients with valvular heart disease: a report of the American College of Cardiology/American Heart Association task force on clinical practice guidelines. *Circulation* 2017;**135**:e1159–e1195.
- Stuge O, Liddicoat J. Emerging opportunities for cardiac surgeons within structural heart disease. *J Thorac Cardiovasc Surg* 2006;**132**:1258–1261.
- Alqahtani F, Berzingi CO, Aljohani S, Hijazi M, Al-Hallak A, Alkhouli M. Contemporary trends in the use and outcomes of surgical treatment of tricuspid regurgitation. *J Am Heart Assoc* 2017;**6**:e007597.
- Zack CJ, Fender EA, Chandrashekar P, Reddy YNV, Bennett CE, Stulak JM, Miller VM, Nishimura RA. National trends and outcomes in isolated tricuspid valve surgery. *J Am Coll Cardiol* 2017;**70**:2953–2960.
- Asmarats L, Puri R, Latib A, Navia JL, Rodes-Cabau J. Transcatheter tricuspid valve interventions: landscape, challenges, and future directions. *J Am Coll Cardiol* 2018;**71**:2935–2956.
- Latib A, Grigioni F, Hahn RT. Tricuspid regurgitation: what is the real clinical impact and how often should it be treated? *EuroIntervention* 2018;**14**:AB101–AB111.
- Lane DA, Skjoth F, Lip GYH, Larsen TB, Kotecha D. Temporal trends in incidence, prevalence, and mortality of atrial fibrillation in primary care. *J Am Heart Assoc* 2017;**6**:e005155.
- Chang JD, Manning WJ, Ebrille E, Zimetbaum PJ. Tricuspid valve dysfunction following pacemaker or cardioverter-defibrillator implantation. *J Am Coll Cardiol* 2017;**69**:2331–2341.
- d'Arcy JL, Coffey S, Loudon MA, Kennedy A, Pearson-Stuttard J, Birks J, Frangou E, Farmer AJ, Mant D, Wilson J, Myerson SG, Prendergast BD. Large-scale community echocardiographic screening reveals a major burden of undiagnosed valvular heart disease in older people: the OxVALVE Population Cohort Study. *Eur Heart J* 2016;**37**:3515–3522.
- Topilsky Y, Maltais S, Medina Inojosa J, Oguz D, Michelena H, Maalouf J, Mahoney DW, Enriquez-Sarano M. Burden of tricuspid regurgitation in patients diagnosed in the community setting. *JACC Cardiovasc Imaging* 2019;**12**:433–442.
- Anwar AM, ten Cate FJ, Soliman OI. Clinical recognition of tricuspid valve disease. In: OI Soliman, FJ ten Cate, eds. *Practical Manual of Tricuspid Valve Disease*. Cham: Springer International Publishing; 2018. p32–40.
- Lancellotti P, Tribouilloy C, Hagendorff A, Popescu BA, Edvardsen T, Pierard LA, Badano L, Zamorano JL; Scientific Document Committee of the European Association of Cardiovascular Imaging. Recommendations for the echocardiographic assessment of native valvular regurgitation: an executive summary from the European Association of Cardiovascular Imaging. *Eur Heart J Cardiovasc Imaging* 2013;**14**:611–644.
- Shiran A, Najjar R, Adawi S, Aronson D. Risk factors for progression of functional tricuspid regurgitation. *Am J Cardiol* 2014;**113**:995–1000.
- Prihadi EA, van der Bijl P, Gursoy E, Abou R, Mara Vollema E, Hahn RT, Stone GVV, Leon MB, Ajmone Marsan N, Delgado V, Bax JJ. Development of significant tricuspid regurgitation over time and prognostic implications: new insights into natural history. *Eur Heart J* 2018;**39**:3574–3581.
- Lee JW, Song JM, Park JP, Lee JW, Kang DH, Song JK. Long-term prognosis of isolated significant tricuspid regurgitation. *Circ J* 2010;**74**:375–380.
- Raikhelkar J, Lin HM, Neckman D, Afonso A, Scurlock C. Isolated tricuspid valve surgery: predictors of adverse outcome and survival. *Heart Lung Circ* 2013;**22**:211–220.
- Kundi H, Popma JJ, Cohen DJ, Liu DC, Laham RJ, Pinto DS, Chu LM, Strom JB, Shen C, Yeh RW. Prevalence and outcomes of isolated tricuspid valve surgery among Medicare beneficiaries. *Am J Cardiol* 2019;**123**:132–138.
- Shiran A, Sagie A. Tricuspid regurgitation in mitral valve disease incidence, prognostic implications, mechanism, and management. *J Am Coll Cardiol* 2009;**53**:401–408.
- Dreyfus GD, Corbi PJ, Chan KM, Bahrami T. Secondary tricuspid regurgitation or dilatation: which should be the criteria for surgical repair? *Ann Thorac Surg* 2005;**79**:127–132.
- Van de Veire NR, Braun J, Delgado V, Versteegh MI, Dion RA, Klautz RJ, Bax JJ. Tricuspid annuloplasty prevents right ventricular dilatation and progression of tricuspid regurgitation in patients with tricuspid annular dilatation undergoing mitral valve repair. *J Thorac Cardiovasc Surg* 2011;**141**:1431–1439.
- Chikwe J, Itagaki S, Anyanwu A, Adams DH. Impact of concomitant tricuspid annuloplasty on tricuspid regurgitation, right ventricular function, and pulmonary artery hypertension after repair of mitral valve prolapse. *J Am Coll Cardiol* 2015;**65**:1931–1938.
- Utsunomiya H, Itabashi Y, Mihara H, Berdejo J, Kobayashi S, Siegel RJ, Shiota T. Functional tricuspid regurgitation caused by chronic atrial fibrillation: a real-time

- 3-dimensional transesophageal echocardiography study. *Circ Cardiovasc Imaging* 2017;**10**:e004897.
32. Ton-Nu TT, Levine RA, Handschumacher MD, Dorer DJ, Yosefy C, Fan D, Hua L, Jiang L, Hung J. Geometric determinants of functional tricuspid regurgitation: insights from 3-dimensional echocardiography. *Circulation* 2006;**114**:143–149.
 33. Fukuda S, Saracino G, Matsumura Y, Daimon M, Tran H, Greenberg NL, Hozumi T, Yoshikawa J, Thomas JD, Shiota T. Three-dimensional geometry of the tricuspid annulus in healthy subjects and in patients with functional tricuspid regurgitation: a real-time, 3-dimensional echocardiographic study. *Circulation* 2006;**114**(1 Suppl):I492–I498.
 34. Dreyfus J, Ghalem N, Garbarz E, Cimadevilla C, Nataf P, Vahanian A, Caranhac G, Messika-Zeitoun D. Timing of referral of patients with severe isolated tricuspid valve regurgitation to surgeons (from a French Nationwide Database). *Am J Cardiol* 2018;**122**:323–326.
 35. Konstam MA, Kiernan MS, Bernstein D, Bozkurt B, Jacob M, Kapur NK, Kociol RD, Lewis EF, Mehra MR, Pagani FD, Raval AN, Ward C. Evaluation and management of right-sided heart failure: a scientific statement from the American Heart Association. *Circulation* 2018;**137**:e578–e622.
 36. van Gameren M, Piazza N, Bogers A, Takkenberg JJM, Kappetein AP. How to assess risks of valve surgery: quality, implementation and future of risk models. *Heart* 2009;**95**:1958–1963.
 37. LaPar DJ, Likosky DS, Zhang M, Theurer P, Fonner CE, Kern JA, Bolling SF, Drake DH, Speir AM, Rich JB, Kron IL, Prager RL, Ailawadi G. Development of a risk prediction model and clinical risk score for isolated tricuspid valve surgery. *Ann Thorac Surg* 2018;**106**:129–136.
 38. Yates MT, Anyanwu AC. Invited commentary. *Ann Thorac Surg* 2018;**106**:136–137.
 39. Khalique OK, Cavalcante JL, Shah D, Guta AC, Zhan Y, Piazza N, Muraru D. Multimodality imaging of the tricuspid valve and right heart anatomy. *JACC Cardiovasc Imaging* 2019;**12**:516–531.
 40. Zoghbi WA, Adams D, Bonow RO, Enriquez-Sarano M, Foster E, Grayburn PA, Hahn RT, Han Y, Hung J, Lang RM, Little SH, Shah DJ, Shernan S, Thavendiranathan P, Thomas JD, Weissman NJ. Recommendations for noninvasive evaluation of native valvular regurgitation: a report from the American Society of Echocardiography developed in collaboration with the Society for Cardiovascular Magnetic Resonance. *J Am Soc Echocardiogr* 2017;**30**:303–371.
 41. Hahn RT, Meduri CU, Davidson CJ, Lim S, Nazif TM, Ricciardi MJ, Rajagopal V, Ailawadi G, Vannan MA, Thomas JD, Fowler D, Rich S, Martin R, Ong G, Grootuis A, Kodali S. Early feasibility study of a transcatheter tricuspid valve annuloplasty: SCOUT trial 30-day results. *J Am Coll Cardiol* 2017;**69**:1795–1806.
 42. Hahn RT, Zamorano JL. The need for a new tricuspid regurgitation grading scheme. *Eur Heart J Cardiovasc Imaging* 2017;**18**:1342–1343.
 43. Dahou A, Ong G, Hamid N, Avenatti E, Yao J, Hahn RT. Quantifying tricuspid regurgitation severity: a comparison of proximal isovelocity surface area and novel quantitative Doppler methods. *JACC Cardiovasc Imaging* 2019;**12**:560–562.
 44. Bartko PE, Arfsten H, Frey MK, Heitzinger G, Pavo N, Cho A, Neuhold S, Tan TC, Strunk G, Hengstenberg C, Hulsmann M, Goliash G. Natural history of functional tricuspid regurgitation: implications of quantitative Doppler assessment. *JACC Cardiovasc Imaging* 2019;**12**:389–397.
 45. Besler C, Orban M, Rommel KP, Braun D, Patel M, Hagl C, Borger M, Nabauer M, Massberg S, Thiele H, Hausleiter J, Lurz P. Predictors of procedural and clinical outcomes in patients with symptomatic tricuspid regurgitation undergoing transcatheter edge-to-edge repair. *JACC Cardiovasc Interv* 2018;**11**:1119–1128.
 46. Latib A, Mangieri A, Vicentini L, Ferri L, Montorfano M, Ismeno G, Regazzoli D, Ancona MB, Giglio M, Denti P, Colombo A, Agricola E. Percutaneous tricuspid valve annuloplasty under conscious sedation (with only fluoroscopic and intracardiac echocardiography monitoring). *JACC Cardiovasc Interv* 2017;**10**:620–621.
 47. Naoum C, Blanke P, Cavalcante JL, Leipsic J. Cardiac computed tomography and magnetic resonance imaging in the evaluation of mitral and tricuspid valve disease: implications for transcatheter interventions. *Circ Cardiovasc Imaging* 2017;**10**:e005331.
 48. van Rosendaal PJ, Kamperidis V, Kong WK, van Rosendaal AR, van der Kley F, Ajmone Marsan N, Delgado V, Bax JJ. Computed tomography for planning transcatheter tricuspid valve therapy. *Eur Heart J* 2017;**38**:665–674.
 49. Kay JH, Maselli-Campagna G, Tsuji KK. Surgical treatment of tricuspid insufficiency. *Ann Surg* 1965;**162**:53–58.
 50. De Vega NG. Selective, adjustable and permanent annuloplasty. An original technique for the treatment of tricuspid insufficiency. *Rev Esp Cardiol* 1972;**25**:555–556.
 51. Parolari A, Barili F, Piloizzi A, Pacini D. Ring or suture annuloplasty for tricuspid regurgitation? A meta-analysis review. *Ann Thorac Surg* 2014;**98**:2255–2263.
 52. Wang N, Phan S, Tian DH, Yan TD, Phan K. Flexible band versus rigid ring annuloplasty for tricuspid regurgitation: a systematic review and meta-analysis. *Ann Cardiothorac Surg* 2017;**6**:194–203.
 53. Pfanmuller B, Doenst T, Eberhardt K, Seeburger J, Borger MA, Mohr FW. Increased risk of dehiscence after tricuspid valve repair with rigid annuloplasty rings. *J Thorac Cardiovasc Surg* 2012;**143**:1050–1055.
 54. Wang H, Liu X, Wang X, Lv Z, Liu X, Xu P. Comparison of outcomes of tricuspid annuloplasty with 3D-rigid versus flexible prosthetic ring for functional tricuspid regurgitation secondary to rheumatic mitral valve disease. *J Thorac Dis* 2016;**8**:3087–3095.
 55. Nishi H, Toda K, Miyagawa S, Yoshikawa Y, Fukushima S, Yoshioka D, Sawa Y. Annular dynamics of memo3D annuloplasty ring evaluated by 3D transesophageal echocardiography. *Gen Thorac Cardiovasc Surg* 2018;**66**:214–219.
 56. Fukuda S, Song JM, Gillinov AM, McCarthy PM, Daimon M, Kongsarepong V, Thomas JD, Shiota T. Tricuspid valve tethering predicts residual tricuspid regurgitation after tricuspid annuloplasty. *Circulation* 2005;**111**:975–979.
 57. Dreyfus GD, Raja SG, John Chan KM. Tricuspid leaflet augmentation to address severe tethering in functional tricuspid regurgitation. *Eur J Cardiothorac Surg* 2008;**34**:908–910.
 58. Alfieri O, De Bonis M, Lapenna E, Agricola E, Quarti A, Maisano F. The “clover technique” as a novel approach for correction of post-traumatic tricuspid regurgitation. *J Thorac Cardiovasc Surg* 2003;**126**:75–79.
 59. Marin D, Ramadan K, Hamilton C, Schuetz A. Tricuspid valve repair with artificial chordae in a 72-year-old woman. *Thorac Cardiovasc Surg* 2011;**59**:495–497.
 60. Honjo O, Ishino K, Yoshizumi K, Kawada M, Ohtsuki S, Akagi T, Sano S. Repair of a dysplastic tricuspid valve using artificial chordae: case report. *J Heart Valve Dis* 2006;**15**:392–393.
 61. Carpentier A, Chauvaud S, Mace L, Relland J, Mihaileanu S, Marino JP, Abry B, Guibourt P. A new reconstructive operation for Ebstein's anomaly of the tricuspid valve. *J Thorac Cardiovasc Surg* 1988;**96**:92–101.
 62. Kim JH, Kim YS, Yoon YH, Kim JT, Kim KH, Baek WK. Quadrangular resection of the tricuspid valve. *Korean J Thorac Cardiovasc Surg* 2013;**46**:60–62.
 63. Antunes MJ, Rodriguez-Palomares J, Prendergast B, De Bonis M, Rosenhek R, Al-Attar N, Barili F, Casselman F, Folliguet T, Jung B, Lancellotti P, Muneretto C, Obadia JF, Pierard L, SuwalSKI P, Zamorano P. Management of tricuspid valve regurgitation: position statement of the European Society of Cardiology Working Groups of cardiovascular surgery and valvular heart disease. *Eur J Cardiothorac Surg* 2017;**52**:1022–1030.
 64. Liu P, Qiao WH, Sun FQ, Ruan XL, Al Shirbini M, Hu D, Chen S, Dong NG. Should a mechanical or biological prosthesis be used for a tricuspid valve replacement? A meta-analysis. *J Card Surg* 2016;**31**:294–302.
 65. David TE, David CM, Manlihot C. Tricuspid annulus diameter does not predict the development of tricuspid regurgitation after mitral valve repair for mitral regurgitation due to degenerative diseases. *J Thorac Cardiovasc Surg* 2018;**155**:2429–2436.
 66. Muraru D, Badano LP. Tricuspid Annulus Measurements: dynamic Changes in Health and Disease. In: Ol Soliman, FJ ten Cate, eds. *Practical Manual of Tricuspid Valve Diseases*. Cham: Springer International Publishing; 2018. p205–220.
 67. Miglioranza MH, Mihailă S, Muraru D, Cucchini U, Iliceto S, Badano LP. Dynamic changes in tricuspid annular diameter measurement in relation to the echocardiographic view and timing during the cardiac cycle. *J Am Soc Echocardiogr* 2015;**28**:226–235.
 68. Hwang HY, Kim KH, Kim KB, Ahn H. Reoperations after tricuspid valve repair: re-repair versus replacement. *J Thorac Dis* 2016;**8**:133–139.
 69. Fukunaga N, Okada Y, Koyama T. Re-repair of tricuspid valve after tricuspid suture annuloplasty: an analysis of the causes for reoperation and its durability. *J Heart Valve Dis* 2016;**25**:341–348.
 70. Ren WJ, Zhang BG, Liu JS, Qian YJ, Guo YQ. Outcomes of tricuspid annuloplasty with and without prosthetic rings: a retrospective follow-up study. *J Cardiothorac Surg* 2015;**10**:81.
 71. Lin Y, Wang Z, He J, Xu Z, Xiao J, Zhang Y, Peng H. Efficiency of different annuloplasty in treating functional tricuspid regurgitation and risk factors for recurrence. *Int J Cardiol Heart Vasc* 2014;**5**:15–19.
 72. Ratschiller T, Guenther T, Knappich C, Guenzinger R, Kehl V, Voss B, Lange R. Do transvalvular pacemaker leads influence functional outcome after tricuspid ring annuloplasty? *Eur J Cardiothorac Surg* 2015;**48**:363–369.
 73. Gatti G, Dell'Angela L, Morosin M, Maschietto L, Pinamonti B, Forti G, Benussi B, Nicolosi GL, Sinagra G, Pappalardo A. Tricuspid annuloplasty for tricuspid regurgitation secondary to left-sided heart valve disease: immediate outcomes and risk factors for late failure. *Can J Cardiol* 2016;**32**:760–766.
 74. Yoda M, Tanabe H, Kadoma Y, Suma H. Mid-term results of tricuspid annuloplasty using the MC3 ring for secondary tricuspid valve regurgitation. *Interact Cardiovasc Thorac Surg* 2011;**13**:7–10.
 75. Jung SH, Je HG, Song JM, Choo SJ, Chung CH, Yun SC, Lee JW. Outcomes following use of a modified Duran ring tricuspid valve reconstruction procedure for secondary tricuspid regurgitation. *Circ J* 2010;**74**:925–930.
 76. Murashita T, Okada Y, Kanemitsu H, Fukunaga N, Konishi Y, Nakamura K, Koyama T. Long-term outcomes of tricuspid annuloplasty for functional tricuspid regurgitation associated with degenerative mitral regurgitation: suture

- annuloplasty versus ring annuloplasty using a flexible band. *Ann Thorac Cardiovasc Surg* 2014;**20**:1026–1033.
77. Ghanta RK, Chen R, Narayanasamy N, McGurk S, Lipsitz S, Chen FY, Cohn LH. Suture bicuspidization of the tricuspid valve versus ring annuloplasty for repair of functional tricuspid regurgitation: midterm results of 237 consecutive patients. *J Thorac Cardiovasc Surg* 2007;**133**:117–126.
 78. Akins CW, Miller DC, Turina MI, Kouchokos NT, Blackstone EH, Grunkemeier GL, Takkenberg JJ, David TE, Butchart EG, Adams DH, Shahian DM, Hagl S, Mayer JE, Lytle BW; Councils of the American Association for Thoracic Surgery; Society of Thoracic Surgeons; European Association for Cardio-Thoracic Surgery; Ad Hoc Liaison Committee for Standardizing Definitions of Prosthetic Heart Valve Morbidity. Guidelines for reporting mortality and morbidity after cardiac valve interventions. *J Thorac Cardiovasc Surg* 2008;**135**:732–738.
 79. Navia JL, Nowicki ER, Blackstone EH, Brozzi NA, Nento DE, Atik FA, Rajeswaran J, Gillinov AM, Svensson LG, Lytle BW. Surgical management of secondary tricuspid valve regurgitation: annulus, commissure, or leaflet procedure? *J Thorac Cardiovasc Surg* 2010;**139**:1473–1482.e5.
 80. Abdelghani M, Schofer J, Soliman OI. Transcatheter interventions for tricuspid regurgitation: rationale, overview of current technologies, and future perspectives. In: OI Soliman, FJ ten Cate, eds. *Practical Manual of Tricuspid Valve Diseases*. Cham, Switzerland: Springer International Publishing; 2018. p.353–373.
 81. Taramasso M, Hahn RT, Alessandrini H, Latib A, Attinger-Toller A, Braun D, Brochet E, Connelly KA, Denti P, Deuschl F, Englmaier A, Fam N, Frerker C, Hausleiter J, Juliard JM, Kaple R, Kreidel F, Kuck KH, Kuwata S, Ancona M, Malasa M, Nazif T, Nickenig G, Nietlispach F, Pozzoli A, Schafer U, Schofer J, Schueler R, Tang G, Vahanian A, Webb JG, Yzeiraj E, Maisano F, Leon MB. The international multicenter tricuspid registry: which patients are undergoing transcatheter tricuspid repair? *JACC Cardiovasc Interv* 2017;**10**:1982–1990.
 82. Taramasso M, Alessandrini H, Latib A, Asami M, Attinger-Toller A, Biasco L, Braun D, Brochet E, Connelly KA, Denti P, Deuschl F, Englmaier A, Fam N, Frerker C, Hausleiter J, Himbert D, Ho E, Juliard JM, Kaple R, Kreidel F, Kuck KH, Ancona M, Lauten A, Lurz P, Mehr M, Nazif T, Nickenig G, Pedrazzini G, Pozzoli A, Praz F, Puri R, Rodes-Cabau J, Schafer U, Schofer J, Sievert H, Sievert K, Tang GHL, Tanner FC, Vahanian A, Webb JG, Windecker S, Yzeiraj E, Zuber M, Maisano F, Leon MB, Hahn RT. Outcomes after current transcatheter tricuspid valve intervention: mid-term results from the international TriValve registry. *JACC Cardiovasc Interv* 2019;**12**:155–165.
 83. Mack MJ, Leon MB, Thourani VH, Makkari R, Kodali SK, Russo M, Kapadia SR, Malaisrie SC, Cohen DJ, Pibarot P, Leipsic J, Hahn RT, Blanke P, Williams MR, McCabe JM, Brown DL, Babaliaros V, Goldman S, Szeto WY, Genereux P, Pershad A, Pocock SJ, Alu MC, Webb JG, Smith CR, Investigators P. Transcatheter aortic-valve replacement with a balloon-expandable valve in low-risk patients. *N Engl J Med* 2019;**380**:1695.
 84. Popma JJ, Deeb GM, Yakubov SJ, Mumtaz M, Gada H, O'Hair D, Bajwa T, Heiser JC, Merhi W, Kleiman NS, Askew J, Sorajja P, Rovin J, Chetcuti SJ, Adams DH, Teirstein PS, Zorn GL, Forrester JK, Tchétché D, Resar J, Walton A, Piazza N, Ramlawi B, Robinson N, Petrossian G, Gleason TG, Oh JK, Boulware MJ, Qiao H, Mugglin AS, Reardon MJ; Evolut Low Risk Trial Investigators. Transcatheter aortic-valve replacement with a self-expanding valve in low-risk patients. *N Engl J Med* 2019;**380**:1706.
 85. Ruparelina N, Mangieri A, Ancona M, Giannini F, Agricola E, Montorfano M, De Bonis M, Alfieri O, Colombo A, Latib A. Percutaneous transcatheter treatment for tricuspid bioprosthesis failure. *Catheter Cardiovasc Interv* 2016;**88**:994–1001.
 86. Aboulhosn J, Cabalka AK, Levi DS, Himbert D, Testa L, Latib A, Makkari RR, Boudjemline Y, Kim DW, Kefer J, Bleiziffer S, Kerst G, Dvir D, McElhinney DB. Transcatheter valve-in-ring implantation for the treatment of residual or recurrent tricuspid valve dysfunction after prior surgical repair. *JACC Cardiovasc Interv* 2017;**10**:53–63.
 87. O'Neill BP, Wheatley G, Bashir R, Edmundowicz D, O'Murchu B, O'Neill WW, Patil P, Chen A, Forfia P, Cohen HA. Study design and rationale of the heterotopic implantation of the Edwards-Sapien XT transcatheter valve in the inferior Vena cava for the treatment of severe tricuspid regurgitation (HOVER) trial. *Catheter Cardiovasc Interv* 2016;**88**:287–293.
 88. Lauten A, Ferrari M, Hekmat K, Pfeifer R, Dannberg G, Ragoschke-Schumm A, Figulla HR. Heterotopic transcatheter tricuspid valve implantation: first-in-man application of a novel approach to tricuspid regurgitation. *Eur Heart J* 2011;**32**:1207–1213.
 89. Navia JL, Kapadia S, Elgharably H, Maluenda G, Bartus K, Baeza C, Nair RK, Rodés-Cabau J, Beghi C, Quijano RC. Transcatheter tricuspid valve implantation of NaviGate bioprosthesis in a preclinical model. *JACC Basic Transl Sci* 2018;**3**:67–79.
 90. Navia JL, Kapadia S, Elgharably H, Harb SC, Krishnaswamy A, Unai S, Mick S, Rodriguez L, Hammer D, Gillinov AM, Svensson LG. First-in-human implantations of the NaviGate bioprosthesis in a severely dilated tricuspid annulus and in a failed tricuspid annuloplasty ring. *Circ Cardiovasc Interv* 2017;**10**:e005840.
 91. Hahn RT, George I, Kodali SK, Nazif T, Khaliq OK, Akkoc D, Kantor A, Vahl TP, Patel A, Elias E, Ng V, Spina R, Bartus K, Velagapudi P, Wu I, Leon M, Bapat V. Early single-site experience with transcatheter tricuspid valve replacement. *JACC Cardiovasc Imaging* 2019;**12**:416–429.
 92. Jouan J, Mele A, Florens E, Chatellier G, Carpentier A, Achouh P, Fabiani JN. Conduction disorders after tricuspid annuloplasty with mitral valve surgery: implications for earlier tricuspid intervention. *J Thorac Cardiovasc Surg* 2016;**151**:99–103.
 93. Obadia JF, Messika-Zeitoun D, Leurent G, lung B, Bonnet G, Piriou N, Lefevre T, Piot C, Rouleau F, Carrie D, Nejari M, Ohlmann P, Leclercq F, Saint Etienne C, Teiger E, Leroux L, Karam N, Michel N, Gilard M, Donal E, Trochu JN, Cormier B, Armoiry X, Boutitie F, Maucort-Boulch D, Barnel C, Samson G, Guerin P, Vahanian A, Mewton N; MITRA-FR Investigators. Percutaneous repair or medical treatment for secondary mitral regurgitation. *N Engl J Med* 2018;**379**:2297–2306.
 94. Stone GW, Lindenfeld J, Abraham WT, Kar S, Lim DS, Mishell JM, Whisenant B, Grayburn PA, Rinaldi M, Kapadia SR, Rajagopal V, Sarembock IJ, Brieke A, Marx SO, Cohen DJ, Weissman NJ, Mack MJ; COAPT Investigators. Transcatheter mitral-valve repair in patients with heart failure. *N Engl J Med* 2018;**379**:2307–2318.
 95. Nickenig G, Hammerstingl C, Schueler R, Topilsky Y, Grayburn PA, Vahanian A, Messika-Zeitoun D, Urena Alcazar M, Baldus S, Volker R, Huntgeburth M, Alfieri O, Latib A, La Canna G, Agricola E, Colombo A, Kuck KH, Kreidel F, Frerker C, Tanner FC, Ben-Yehuda O, Maisano F. Transcatheter mitral annuloplasty in chronic functional mitral regurgitation: 6-month results with the cardioband percutaneous mitral repair system. *JACC Cardiovasc Interv* 2016;**9**:2039–2047.
 96. Nickenig G, Weber M, Schueler R, Hausleiter J, Nabauer M, von Bardeleben RS, Sotiriou E, Schafer U, Deuschl F, Kuck KH, Kreidel F, Juliard JM, Brochet E, Latib A, Agricola E, Baldus S, Friedrichs K, Vandrangi P, Verta P, Hahn RT, Maisano F. 6-month outcomes of tricuspid valve reconstruction for patients with severe tricuspid regurgitation. *J Am Coll Cardiol* 2019;**73**:1905–1915.