

A Possible Protective Effect of the ‘Cam Deformity’ on Femoral Neck Fracture: The Relationship between Hip Morphology and the Types of Hip Fracture

Takuma Yagura^a, Kenichi Oe^{a*}, Masaaki Paku^b, Takeshi Tajima^c,
Masaya Nakamura^d, Hirokazu Iida^a, and Takanori Saito^a

^aDepartment of Orthopaedic Surgery, Kansai Medical University, Osaka 573-1010, Japan,

^bDepartment of Orthopaedic Surgery, Osaka Saiseikai Izu Hospital, Osaka 551-0032, Japan,

^cDepartment of Orthopaedic Surgery, Meisei Hospital, Osaka 534-0024, Japan,

^dDepartment of Orthopaedic Surgery, McSYL Tatsumi Hospital, Osaka 563-0031, Japan

We retrospectively evaluated the cases of 169 hip fracture patients, their previous fractures, and the contralateral hip joint's morphology. A history of contralateral hip fracture was present in 23 patients (Contra group). The other patients had a unilateral hip fracture: a trochanteric fracture (Troch group, n=73) or a femoral neck fracture (Neck group, n=73). In the Troch and Neck groups, we used anteroposterior and cross-table axial-view radiographs of the contralateral hip to evaluate the proximal femur's anatomy. In the Contra group, the concordance rate between the first and second types of hip fracture was 65.2%, and the second hip fracture's morphology indicated that the trochanteric fracture had a cam deformity in terms of the femoral head-neck ratio. The average alpha angle and femoral head-neck offset in the Troch group were significantly larger than those in the Neck group. In the Neck group, pistol-grip deformities of Arbeitsgemeinschaft für Osteosynthesefragen types B1 (subcapital), B2 (transcervical), and B3 (displaced) were observed in 42.1%, 75%, and 6% of cases, respectively. There was a smaller alpha angle and a larger femoral head-neck offset in the contralateral hip of femoral neck fractures; thus, the “cam deformity” may protect against femoral neck fractures.

Key words: cam deformity, femoral neck fracture, trochanteric fracture, bilateral hip fractures

Hip fractures are a public health concern. It is estimated that the annual number of hip fractures worldwide will be 2.6 million by the year 2025, and the number could be between 7.3 and 21.3 million by 2050 [1]. According to the World Health Organization, the risk factors for hip fractures include low bone mineral density (BMD), history of fracture, age, family history of fragile fracture, cigarette smoking, alcohol consumption, glucocorticosteroid use, and rheumatoid

arthritis [2]. Of these factors, low BMD is the most strongly associated with hip fractures. Vertebral fractures, which are the most common osteoporotic fractures, typically occur in women around 50 years of age, while the average age at which hip fractures occur is approx. 80 years in both sexes [3]. Therefore, factors other than BMD are likely to influence the incidence of hip fractures.

Hip fractures are classified into 2 types: femoral neck fractures and trochanteric fractures, and there are

different risk factors for both types. The hip axis length, impacts on the greater trochanter, decreased BMD of the femoral neck, falls with force, and decreased soft tissue thickness have been associated with hip fractures [4-6]. Of all of these factors, the BMD is likely to be the most important intrinsic factor for trochanteric fractures, with the average age of patients with these fractures higher than that of patients with femoral neck fractures [2,3]. Regional factors and race also differentially affect the type of hip fracture [7-10]. For example, trochanteric fractures are more common than femoral neck fractures in both Japan and the U.S. [7,9], whereas the opposite trend was observed in Norway [8]. The morphology of the hip itself may influence the type of fracture, as several research groups have reported a tendency for the second hip fracture to be of the same type as the first contralateral fracture [11-14].

We conducted the present study to determine whether second hip fractures are similar to the same patients' first contralateral hip fractures and to assess the relationship between hip morphology and the type of hip fractures. We hypothesized that a cam deformity may be protective against femoral neck fractures.

Patients and Methods

This multicenter cross-sectional non-randomized observational cohort study was approved by our institutional review board (H160738), and it adhered to the Declaration of Helsinki. All patients provided informed consent for participation and the publication of findings.

Patients. We reviewed 169 consecutive cases of patients who underwent surgical treatment for a hip fracture between April 2013 and March 2014 at three local hospitals in Japan. Twenty-three patients had a past history of contralateral hip fracture (the Contra group), including 10 trochanteric and 13 femoral neck fractures. The other 146 patients had sustained only a unilateral hip fracture: 73 with a trochanteric fracture (the Troch group) and 73 with a femoral neck fracture (the Neck group). Hip fractures were classified based on the Arbeitsgemeinschaft für Osteosynthesefragen (AO) classification [15]. In Group T, 39 cases were classified as type A1 (a pertrochanteric simple trochanteric fracture), 31 cases as type A2 (a pertrochanteric multifragmentary trochanteric fracture), and 3 cases as type A3 (an intertrochanteric fracture). In the Neck group, 19

cases were classified as type B1 (a subcapital neck fracture with slight displacement), 4 cases as type B2 (a transcervical fracture), and 50 cases as type B3 (a subcapital, displaced, nonimpacted neck fracture).

Ten patients with a trochanteric fracture in the Contra group, all 73 patients in the Troch group, and 10 patients in the Neck group were treated using open reduction and internal fixation. Thirteen patients with a femoral neck fracture in the Contra group and 63 patients in the Neck group underwent unilateral hip arthroplasties. Patient demographic data were obtained from the medical records (Table 1).

Measurements. A retrospective analysis of radiographs was performed by 2 blinded orthopedic surgeons (T.Y. and K.O.). In the Contra group, the concordance between the first and second types of hip fractures was radiologically confirmed. In both the Troch and Neck groups, the anatomy of the proximal femur was evaluated in the anteroposterior (AP) pelvic radiographs and cross-table axial-view radiographs of the uninvolved hip using a ruler (Carestream Health Japan Co., Tokyo) [16]. The femoral head-neck ratio and pistol-grip deformity were measured on AP pelvic radiographs, with the alpha angle and femoral head-neck offset assessed from cross-table axial views [14,17-19].

We defined the femoral head-neck ratio as the ratio of the maximum femoral head diameter divided by the minimum parallel femoral neck diameter. A positive pistol-grip deformity was defined by a triangular index (R) \geq ($r + 2$ mm). The alpha angle was defined as the angle between the axis of the femoral neck and a line connecting the center of the femoral head with the asphericity starting point of the contour of the femoral head-and-neck. The femoral head-neck offset was defined as the difference in the radius between the anterior femoral head and the anterior femoral neck (Fig. 1). In 15 patients in the Contra group, we also assessed the morphology of the second hip fracture as the contralateral morphology of the first hip fracture. In the other eight patients in the Contra group, the radiographs prior to the second fracture could not be assessed.

Statistical analyses. McNemar's test was used for the concordance analysis between the first and second types of hip fractures. Student's *t*-test and Fisher's exact test were used to assess the differences in the femoral head-neck ratio and alpha angle as well as the prevalence of a pistol-grip deformity. A *p*-value < 0.05 was considered significant. Data were analyzed using SAS

Table 1 Pre-operative patient characteristics

	Contra group	Troch group	Neck group
Number of hips	23	73	73
Age (years), mean	81 ± 13	80 ± 12	78 ± 12
Gender, male: female	6 : 17	26 : 47	29 : 44
Side, right: left	Bilateral	27 : 46	34 : 39
Height (cm), mean	153 ± 8.3	153 ± 9.6	156 ± 11.5
Weight (kg), mean	47 ± 11.6	47 ± 11.2	50 ± 11.4
AO classification, hips	A1 : 3 A2 : 6 A3 : 1 B1 : 1 B2 : 0 B3 : 12	A1 : 39 A2 : 31 A3 : 3	B1 : 19 B2 : 4 B3 : 50
Operation	ORIF : 10 Arthroplasty : 13	ORIF : 73	ORIF : 10 Arthroplasty : 63
Follow-up period (years), mean	2.2 ± 1.8	1.9 ± 1.2	1.7 ± 1.5
Duration from the first to the second fracture (years), mean	5.6 ± 6.7	(-)	(-)

AO, Arbeitsgemeinschaft für Osteosynthesefragen; ORIF, open reduction and internal fixation. Values are expressed as mean ± standard deviation or number.

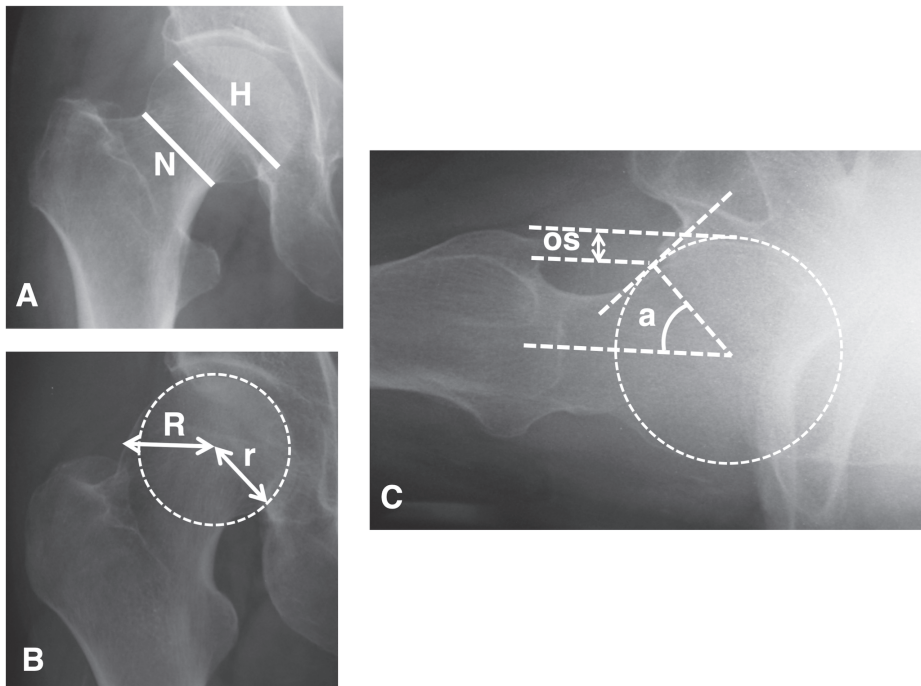


Fig. 1 A typical radiological assessment. **A**, The femoral head-neck ratio on an anteroposterior pelvic radiograph, defined as the ratio of the maximal femoral head diameter (H) divided by the minimum parallel femoral neck diameter (N); **B**, A positive pistol-grip deformity on an anteroposterior pelvic radiograph, identified by calculating the triangular index, which is considered pathological when the R is $\geq (r+2 \text{ mm})$; **C**, The alpha angle (a) on a cross-table axial radiograph, defined as the angle between the femoral neck axis and the line connecting the head center with the starting point of asphericity of the head-neck contour. The femoral head-neck offset (OS) was defined as the difference in the radius between the anterior femoral head and the anterior femoral neck.

9.2 software (SAS, Cary, NC, USA).

Results

In the Contra group, 7 patients had sustained bilateral trochanter fractures and eight had bilateral neck fractures (Fig.2). There was no significant difference between the first and the second types of fractures ($p=0.479$), but the concordance rate was 65.2% (15/23).

The average femoral head-neck ratios in the Troch group and Neck group were 1.46 (range 1.26-1.79) and 1.44 (1.23-1.67), respectively ($p=0.177$). A pistol-grip deformity was identified in 11 hips (15.1%) in the Troch group and 14 hips (19.2%) in the Neck group ($p=0.661$). The average alpha angle in the Troch group (61.4° ; 40° - 88°) was significantly larger than that in the Neck group (50.8° ; 34° - 89° ; $p<0.0001$, Fig.3). The average femoral head-neck offset in the Troch group (7.1; 5.9-9.6) was significantly smaller than that in the Neck group (10.2; 6.2-11.0; $p<0.0001$, Table 2).

In the Contra group (15 patients, 63%), the average femoral head-neck ratios in the second trochanteric and femoral neck fracture subgroups were 1.49 (1.28-1.68) and 1.35 (1.22-1.55), respectively ($p<0.05$). A pistol-grip deformity was identified in 2 hips (33%) in the second trochanteric fracture subgroup and in one hip (13%) in the second femoral neck fracture subgroup ($p=0.525$, Table 3). The average alpha angle and femoral head-neck offset could not be assessed because of cross-table axial-view radiographs prior to the second fracture were not available.

In the Neck group, a pistol-grip deformity of types B1, B2, and B3 was observed in 8/19 hips (42.1%), 3/4

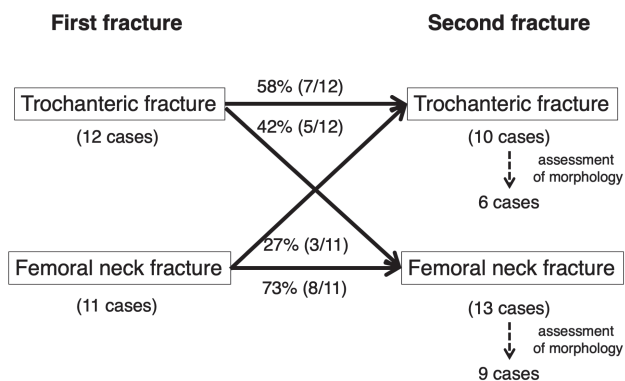


Fig. 2 Classification of the first and second hip fractures in the Contra group.

hips (75.0%), and 3/50 hips (6.0%), respectively. Significant differences in the distribution were identified between types B1 and B3 ($p<0.001$) and between types B2 and B3 ($p<0.001$; Table 4).

Discussion

Although hip fractures are classified as femoral neck and trochanteric fractures, it has been unknown which factors influence the development of each fracture. Some authors have reported a tendency for the second hip fracture to be of the same type as the previous fracture [11-14]. Pierre *et al.* [20] and Young *et al.* [21] described a tendency for bilateral symmetry of the proximal femurs. Based on this knowledge, we hypothesized that the hip morphology could be a decisive factor between femoral neck and trochanteric fractures; we suspected that a cam deformity may offer some protection against femoral neck fractures.

Cam impingement is one of the femoroacetabular impingements (FAIs), which are defined as an impinge-

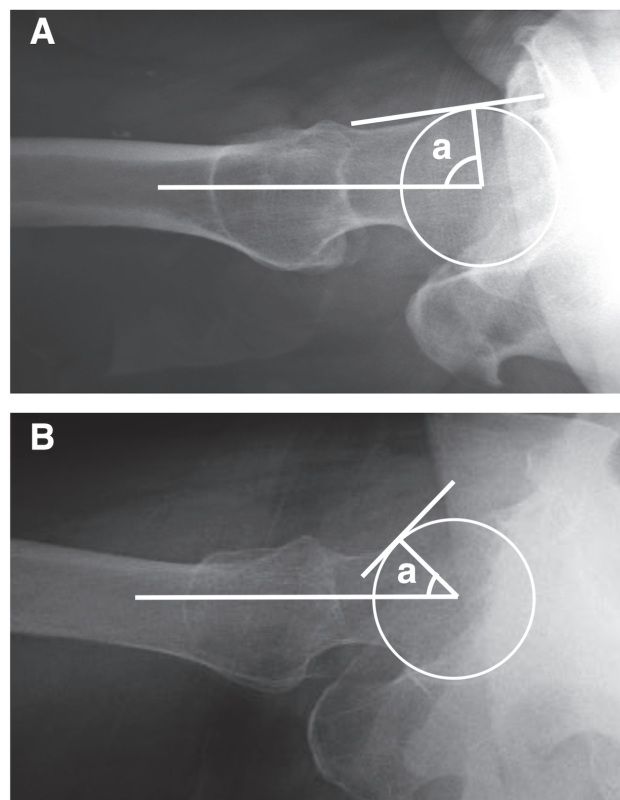


Fig. 3 The alpha angle measured on cross-table axial radiographs. A, A 76-year-old woman in the Troch group (alpha angle, 86°); B, A 74-year-old woman in the Neck group (alpha angle, 43°).

Table 2 Radiological results in Troch and Neck groups

	Troch group	Neck group	<i>p</i> -value
Number of hips	73	73	
Femoral head-neck ratio, mean	1.46 ± 0.10	1.44 ± 0.09	0.177*
Positive pistol-grip deformity, number (%)	11 (15%)	14 (19%)	0.661**
Alpha angle (degree), mean	61 ± 12.5	51 ± 13.9	< 0.0001*
Femoral head-neck offset (mm), mean	7.1 ± 1.0	10.2 ± 1.2	< 0.0001*

Values are expressed as mean ± standard deviation or number. *Student's *t*-test. **Fisher's exact test.

Table 3 Morphology of the second hip fracture in Contra group

	Trochanteric fracture subgroup	Femoral neck fracture subgroup	<i>p</i> -value
Number of hips	6	9	
Femoral head-neck ratio, mean	1.49 ± 0.14	1.34 ± 0.10	< 0.05*
Positive pistol-grip deformity, number (%)	2 (33%)	1 (13%)	0.525**

Values are expressed as mean ± standard deviation or number. *Student's *t*-test. **Fisher's exact test.

Table 4 Pistol-grip deformity in Neck group

AO classification	Positive pistol-grip deformity, number (%)	<i>p</i> -value
B1	8 (42%)	< 0.001*
B2	3 (75%)	< 0.001*
B3	3 (6%)	

AO, Arbeitsgemeinschaft für Osteosynthesefragen

*Fisher's exact test: versus B3.

ment between the head-neck junction of the femur and the rim of the acetabulum [16]. A cam deformity is the osseous bump in a cam-type FAI, and it has been described as a "tilt deformity" and a "pistol-grip deformity" of the proximal femur. Clinically, a cam-type FAI is diagnosed on the basis of the quantification of the asphericity, including pistol-grip deformity, the alpha angle (> 50°), or the femoral head-neck offset (< 8 mm) [17, 18]. However, the relationship between radiological FAI-related findings and actual impingement remains unclear. In an international consensus statement, a panel of experts was unable to recommend precise diagnostic values for the common radiographic measures used to define a cam-type or pincer-type morphology in routine clinical practice [22].

Yamasaki *et al.* [23] reported the following frequencies for the usage of radiographic parameters for a cam-type FAI diagnosis: the alpha angle in 88% of cases, femoral head-neck offset in 22% of cases, and pistol-grip deformity in 16% of cases. The definition of a cam-type FAI is inherently obscure, and the somewhat open

term "cam deformity" is used. In our present investigation, the presence of a cam deformity was assessed using the femoral head-neck ratio, pistol-grip deformity, the alpha angle, and the femoral head-neck offset, and consequently, there was a significant difference between the Troch group and the Neck group in terms of the average alpha angle and femoral head-neck offset (Table 2). In the Contra group, the actual morphology of the second hip fracture indicated that the trochanteric fracture had a cam deformity in terms of the femoral head-neck ratio (Table 3). In addition, the prevalence of a pistol-grip deformity in the AO type B3 fractures in the Neck group (which are displaced femoral neck fractures) was significantly lower than the prevalence of a pistol-grip deformity in the AO type B1 or B2 fractures (Table 4). Therefore, the presence of a pistol-grip deformity may prevent an AO type B3 fracture.

The prevalence of cam deformity in the asymptomatic general population was reported to be influenced by regional or racial differences [24, 25]. Mineta *et al.* [26]

reviewed the computed tomography (CT) scans of 1,178 hips in a general Japanese population who had undergone CT imaging for matters unrelated to their hip symptoms. They identified a cam deformity prevalence of 45.3%, where a cam deformity was defined as an alpha angle $> 55^\circ$ or a femoral head-neck offset ratio < 0.15 . Mimura *et al.* [27] also reviewed 128 Japanese hips with pelvic CT scans conducted for reasons unrelated to the patients' hip symptoms and reported that 34.4% showed the cam-type and a combined deformity (alpha angle $\geq 55^\circ$).

In Japan, the incidence rate of trochanteric fractures is higher than that of femoral neck fractures [7], and it is possible that the cam deformity may offer some protection against a femoral neck fracture. A similar association has been reported in the U.S. [9,28]. Although sufficient high-quality data are required to determine the true prevalence of cam deformity in general populations, our present findings indicate that a cam deformity could be associated with the incidence of femoral neck fractures.

The limitations of our study should be acknowledged. First, the study sample size was small; we reviewed only 169 patients with hip fractures. In particular, in the Contra group, the morphology of the second hip fracture was assessed in only 15 patients. It was difficult to obtain radiographs prior to the fracture. Second, we evaluated the type of past contralateral fractures as well as the anatomy of the contralateral hip retrospectively because the second hip fracture was of the same type as the first contralateral fracture [11-14]. The concordance rate was relatively high in the present study, although there was no significant difference between the first and second types of fractures. In the Contra group, the contralateral morphology of the first hip fracture influenced the type of the second hip fracture. A large prospective study is required to full test this concept. A third study limitation is that we assessed the presence of a cam deformity by using the femoral head-neck ratio and pistol-grip deformity (which were both measured on AP radiographs) and the alpha angle and femoral head-neck offset (measured on cross-table axial-view radiographs). We did not identify a significant difference in the average femoral head-neck ratio or pistol-grip deformity between the Troch group and Neck group, although there was a significant difference in terms of the average alpha angle and femoral head-neck offset. Siebenrock *et al.* [17] demonstrated

that an abnormal extension of the anterosuperior aspect of the femoral head epiphysis is a causative factor of cam impingement, and we identified a lower cam deformity prevalence in the Neck group. In addition, we assessed the morphology of the second hip fracture only in AP radiographs because cross-table axial-view radiographs prior to the second fracture were not available. Lastly, many factors other than the morphology of the hip may be involved in the development of femoral neck or trochanteric fractures [4-6]. It is also possible that undisplaced fractures at the time of injury became displaced during the patient's transport.

In conclusion, we observed that the concordance rate between the first and second hip fractures was 65.2%, with a lower prevalence of a cam deformity of the contralateral hip among the patients who sustained femoral neck fractures, suggesting that a cam deformity may offer some protection against femoral neck fractures. The verification of our findings in a larger study is warranted to clarify the relationship between the presence of a cam deformity and the types of hip fracture.

Acknowledgments. We thank H. Ohno, H. Nakao, N. Matsuoka, and Y. Nakai for their conceptual guidance and performance of the surgeries.

References

1. Gullberg B, Johnell O and Kanis JA: World-wide projections for hip fracture. *Osteoporos Int* (1997) 7: 407-413.
2. WHO Scientific Group: Prevention and management of osteoporosis. WHO Technical Report Series (2003) 921.
3. Riggs BL and Melton LJ 3rd: Involutional osteoporosis. *N Engl J Med* (1986) 314: 1676-1686.
4. Duboeuf F, Hans D, Schott AM, Kotzki PO, Favier F, Marcelli C, Meunier PJ and Delmas PD: Different morphometric and densitometric parameters predict cervical and trochanteric hip fracture: the EPIDOS Study. *J Bone Miner Res* (1997) 12: 1895-1902.
5. Parkkari J, Kannus P, Palvanen M, Natri A, Vainio J, Aho H, Vuori I and Järvinen M: Majority of hip fractures occur as a result of a fall and impact on the greater trochanter of the femur: a prospective controlled hip fracture study with 206 consecutive patients. *Calcif Tissue Int* (1999) 65: 183-187.
6. Black DM, Bouxsein ML, Marshall LM, Cummings SR, Lang TF, Cauley JA, Ensrud KE, Nielson CM and Orwoll ES: Proximal femoral structure and the prediction of hip fracture in men: a large prospective study using QCT. *J Bone Miner Res* (2008) 23: 1326-1333.
7. Hagino H, Sakamoto K, Harada A, Nakamura T, Mutoh Y, Mori S, Endo N, Nakano T, Itoi E, Kita K, Yamamoto N, Aoyagi K and Yamazaki K: Committee on Osteoporosis of The Japanese Orthopaedic Association: Nationwide one-decade survey of hip

- fractures in Japan. *J Orthop Sci* (2010) 15: 737–745.
8. Bjørgul K and Reikerås O: Incidence of hip fracture in southeastern Norway: a study of 1,730 cervical and trochanteric fractures. *Int Orthop* (2007) 31: 665–669.
 9. Kim SH, Meehan JP and Lee MA: Surgical treatment of trochanteric and cervical hip fractures in the United States: 2000–2009. *J Arthroplasty* (2013) 28: 1386–1390.
 10. Requena G, Abbing-Karahagopian V, Huerta C, De Bruin ML, Alvarez Y, Requena G, Abbing-Karahagopian V, Huerta C, De Bruin ML and Alvarez Y: Incidence rates and trends of hip/femur fractures in five European countries: comparison using e-health-care records databases. *Calcif Tissue Int* (2014) 94: 580–589.
 11. Schröder HM, Petersen KK and Erlandsen M: Occurrence and incidence of the second hip fracture. *Clin Orthop Relat Res* (1993) 289: 166–169.
 12. Dretakis KE, Dretakis EK, Papakitsou EF, Psarakis S and Steriopoulos K: Possible predisposing factors for the second hip fracture. *Calcif Tissue Int* (1998) 62: 366–369.
 13. Shabat S, Gepstein R, Mann G, Kish B, Fredman B and Nyska M: The second hip fracture—an analysis of 84 elderly patients. *J Orthop Trauma* (2003) 17: 613–617.
 14. Doherty M, Courtney P, Doherty S, Jenkins W, Maciewicz RA, Muir K and Zhang W: Nonspherical femoral head shape (pistol grip deformity), neck shaft angle, and risk of hip osteoarthritis: a case-control study. *Arthritis Rheum* (2008) 58: 3172–3182.
 15. Müller ME, Nazarian S, Koch P, Nazarian S and Schatzker J: The comprehensive classification for fracture of long bones. 1st Ed, Springer-Verlag, Berlin (1990).
 16. Ganz R, Parvizi J, Beck M, Leunig M, Nötzli H and Siebenrock KA: Femoroacetabular impingement: a cause for osteoarthritis of the hip. *Clin Orthop Relat Res* (2003) 417: 112–120.
 17. Siebenrock KA, Wahab KH, Werlen S, Kalhor M, Leunig M and Ganz R: Abnormal extension of the femoral head epiphysis as a cause of cam impingement. *Clin Orthop Relat Res* (2004) 418: 54–60.
 18. Nötzli HP, Wyss TF, Stoecklin CH, Schmid MR, Treiber K and Hodler J: The contour of the femoral head-neck junction as a predictor for the risk of anterior impingement. *J Bone Joint Surg Br* (2002) 84: 556–560.
 19. Gosvig KK, Jacobsen S, Palm H, Sonne-Holm S and Magnusson E: A new radiological index for assessing asphericity of the femoral head in cam impingement. *J Bone Joint Surg Br* (2007) 89: 1309–1316.
 20. Pierre MA, Zurakowski D, Nazarian A, Hauser-Kara DA and Snyder BD: Assessment of the bilateral asymmetry of human femurs based on physical, densitometric, and structural rigidity characteristics. *J Biomech* (2010) 43: 2228–2236.
 21. Young EY, Gebhart J, Cooperman D and Ahn NU: Are the left and right proximal femurs symmetric? *Clin Orthop Relat Res* (2013) 471: 1593–1601.
 22. Griffin DR, Dickenson EJ, O'Donnell J, Agricola R, Awan T, Beck M, Clohisey JC, Dijkstra HP, Falvey E, Gimpel M, Hinman RS, Hölmich P, Kassarian A, Martin HD, Martin R, Mather RC, Philippon MJ, Reiman MP, Takla A, Thorborg K, Walker S, Weir A and Bennell KL: The Warwick Agreement on femoroacetabular impingement syndrome (FAI syndrome): an international consensus statement. *Br J Sports Med* (2016) 50: 1169–1176.
 23. Yamasaki T, Yasunaga Y, Shoji T, Izumi S, Hachisuka S and Ochi M: Inclusion and exclusion criteria in the diagnosis of femoroacetabular impingement. *Arthroscopy* (2015) 31: 1403–1410.
 24. Frank JM, Harris JD, Erickson BJ, Slikker W 3rd, Bush-Joseph CA, Salata MJ and Nho SJ: Prevalence of femoroacetabular impingement imaging findings in asymptomatic volunteers: a systematic review. *Arthroscopy* (2015) 31: 1199–1204.
 25. Dickenson E, Wall PD, Robinson B, Fernandez M, Parsons H, Buchbinder R and Griffin DR: Prevalence of cam hip shape morphology: a systematic review. *Osteoarthr Cartil* (2016) 24: 949–961.
 26. Mineta K, Goto T, Wada K, Tamaki Y, Hamada D, Tonogai I, Higashino K and Sairyo K: CT-based morphological assessment of the hip joint in Japanese patients: association with radiographic predictors of femoroacetabular impingement. *Bone Joint J* (2016) 98: 1167–1174.
 27. Mimura T, Mori K, Itakura S, Furuya Y, Kawasaki T and Imai S: Prevalence of pincer, cam, and combined deformities in Japanese hip joints evaluated with the Japanese Hip Society diagnostic guideline for femoroacetabular impingement: a CT-based study. *J Orthop Sci* (2017) 22: 105–111.
 28. Jung KA, Restrepo C, Hellman M, AbdelSalam H, Morrison W and Parvizi J: The prevalence of cam-type femoroacetabular deformity in asymptomatic adults. *J Bone Joint Surg Br* (2011) 93: 1303–1307.