

Received: 2017.02.03
Accepted: 2017.04.08
Published: 2017.06.07

ISSN 1941-5923
© Am J Case Rep, 2017; 18: 637-640
DOI: 10.12659/AJCR.903608

Gastric Dilatation and Abdominal Compartment Syndrome in a Child with Prader-Willi Syndrome

Authors' Contribution:
Study Design A
Data Collection B
Statistical Analysis C
Data Interpretation D
Manuscript Preparation E
Literature Search F
Funds Collection G

ABCDEF 1 **Clara Blat**
ABDEF 2 **Elisenda Busquets**
CDE 3 **Teresa Gili**
ABF 4 **Assumpta Caixàs**
ABF 5 **Elisabeth Gabau**
ABCDEFG 1 **Raquel Corripio**

1 Department of Paediatric Endocrinology, Parc Tauli Sabadell, Hospital Universitari, Universitat Autònoma de Barcelona, Sabadell, Spain
2 Department of Paediatric Gastroenterology, Parc Tauli Sabadell, Hospital Universitari, Universitat Autònoma de Barcelona, Sabadell, Spain
3 Department of Paediatric Intensive Care, Parc Tauli Sabadell, Hospital Universitari, Universitat Autònoma de Barcelona, Sabadell, Spain
4 Department of Endocrine, Parc Tauli Sabadell, Hospital Universitari, Universitat Autònoma de Barcelona, Sabadell, Spain
5 Department of Paediatric Genetics, Parc Tauli Sabadell, Hospital Universitari, Universitat Autònoma de Barcelona, Sabadell, Spain

Corresponding Author: Raquel Corripio, e-mail: raquelcorripio@gmail.com, rcorripio@tauli.cat
Conflict of interest: None declared

Patient: Male, 5
Final Diagnosis: Abdominal compartment
Symptoms: Abdominal distension • vomiting
Medication: —
Clinical Procedure: —
Specialty: Pediatrics and Neonatology

Objective: Rare disease





Background: Prader-Willi syndrome (PWS) is a genetic disorder characterized by initial muscular hypotonia and feeding difficulties, and later an insatiable appetite, hyperphagia and obesity along with mild to moderate intellectual impairment. Affected individuals' food-seeking behavior and suspected delayed gastric emptying can lead to gastric dilatation with subsequent necrosis and perforation.

Case Report: We present the case of a 5-year-old boy diagnosed with Prader-Willi syndrome at neonatal age due to muscular hypotonia, who started growth hormone therapy at 20 months. He presented with two episodes of a rapidly progressing gastric dilatation that led to abdominal hypertension and secondary shock at the age of 2 and 5. No large amount of food was eaten before any of the episodes, and he had abdominal pain and vomiting on both occasions. On arrival at the emergency room, a nasogastric tube was placed and aspiration of food material was performed. Abdominal X-ray and CT scan revealed massive gastric dilatation. He was admitted at the Pediatric Intensive Care Unit and after a variable period of fasting, tolerated oral intake and could be discharged.

Conclusions: Gastric dilatation due to gastroparesis in PWS is a rare complication. However, it is a life-threatening situation and physicians should therefore maintain a high level of suspicion for gastric dilatation when patients present with warning symptoms such as abdominal pain or discomfort and vomiting.

MeSH Keywords: Gastric Dilatation • Gastroparesis • Intra-Abdominal Hypertension • Prader-Willi Syndrome

Full-text PDF: <http://www.amjcaserep.com/abstract/index/idArt/903608>

 1256   5  12



Background

Prader-Willi syndrome (PWS) is a genetic disorder caused by the lack of expression of the paternally active genes in a region on the long arm of chromosome 15, either due to deletion of the paternal chromosome or maternal disomy [1].

It is characterized by muscular hypotonia, feeding difficulties and global developmental delay in infancy. During early childhood, especially between 4 and 8 years of age, affected individuals develop an insatiable appetite, hyperphagia and obesity [2] as well as mild to moderate intellectual impairment and learning disabilities. During adulthood, obesity and its complications, including cardiovascular problems, diabetes mellitus and sleep apnea are the most prevalent problems [1].

However, early growth hormone (GH) treatment, dietary recommendations and behavioral therapy have improved body composition in individuals affected with PWS [3,4].

In spite of this treatment, their food-seeking behavior and suspected delayed gastric emptying [5] can lead to episodes of gastric dilatation that may rapidly progress to gastric necrosis and perforation [6, 7]. Data collected by a support organization of people affected with PWS reported that 3% of deaths were demonstrated to be due to gastric perforation (with autopsy evidence) and 3% were suspected to be due to this cause, although no autopsy was performed [8].

Case Report

We present the case of a 5-year-old boy diagnosed with Prader-Willi syndrome at neonatal age due to muscular hypotonia. He was treated with non-invasive domiciliary ventilation for 3 months due to obstructive sleep apnea and initiated GH therapy at age 20 months. In addition, a week before the first consultation, he started treatment with inhaled budesonide and salbutamol for recurrent acute bronchitis, which is why his parents also administered homeopathic treatment. We describe the 2 episodes of gastric dilatation that led to abdominal hypertension, abdominal compartment syndrome, and secondary shock.

The boy was admitted to the emergency room (ER) at age 2 years. At arrival, he was unconscious, with emission of feculent material through the mouth, abdominal dilatation, and poor perfusion (Figure 1).

His parents explained that it had started immediately after eating, 30 min before the consultation, with a rapid worsening. No large amount of food had been ingested that day.

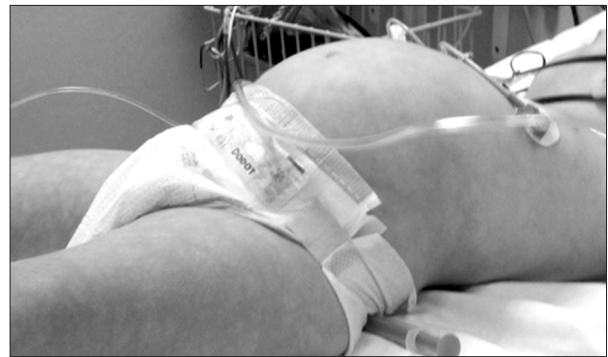

Figure 1. Photograph of patient on arrival at the ER with abdominal dilatation and poor perfusion.

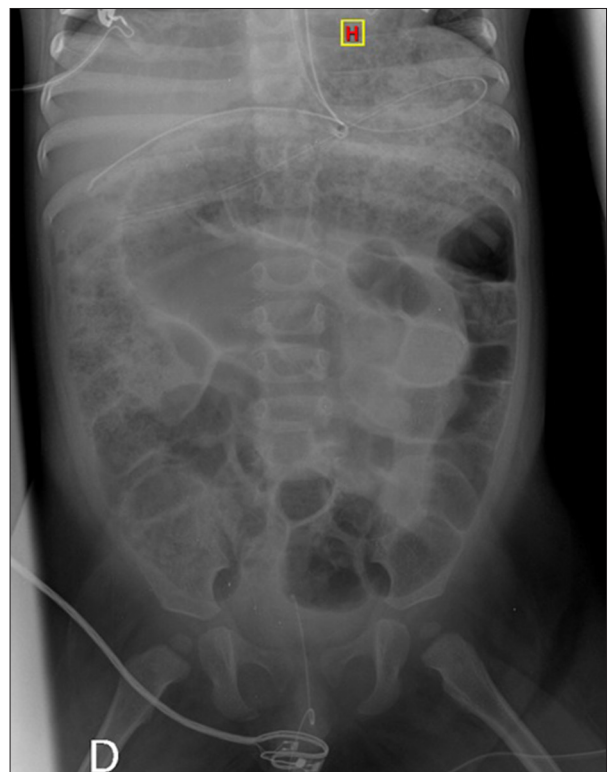

Figure 2. Abdominal x-ray with gastric and intestinal dilatation.

Hypovolemic shock secondary to abdominal hypertension was diagnosed on arrival, and initial fluid resuscitation was performed with normal saline and continuous infusion of dopamine via peripheral vascular access. A nasogastric tube and an orogastric tube were placed and active aspiration of food material was performed. A rectal tube and vesical catheter were also inserted. Orotracheal intubation was used due to unconsciousness and the risk of bronchoaspiration. Antibiotic, proton pump inhibitor, and prokinetic agent (domperidone) were administered. After initial stabilization, abdominal x-ray (Figure 2) and abdominal CT showed an important gastric dilatation with material inside and without signs of necrosis or perforation, and intestinal distension (Figures 3, 4). In addition, an emergency

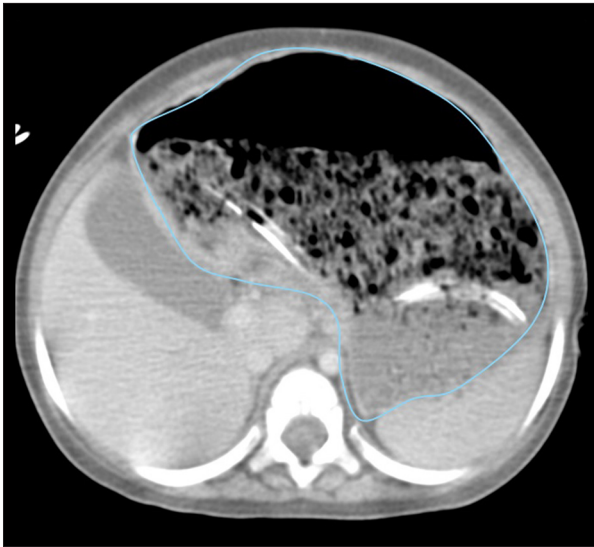


Figure 3. Abdominal CT with gastric dilatation with material inside.

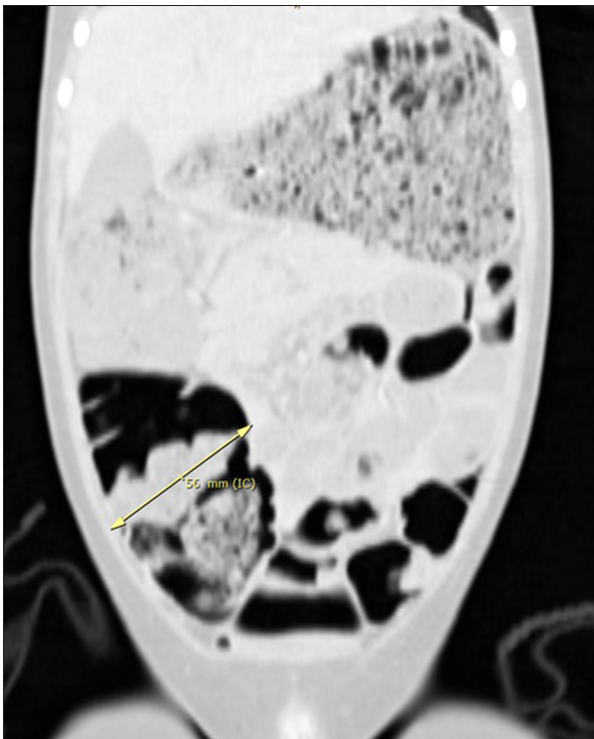


Figure 4. Abdominal CT with important gastric dilatation with material inside and intestinal distension.

gastroscopy was done and gastric necrosis was ruled out. The patient was admitted to the Pediatric Intensive Care Unit (PICU), where he remained stable. The inotropic agent was stopped 3 h after initiation and elective extubation was performed 17 h later. Enemas were administered when the patient's condition had stabilized. After a 24-h fasting period, the initiation of oral intake was tolerated and the patient was discharged 7 days later.

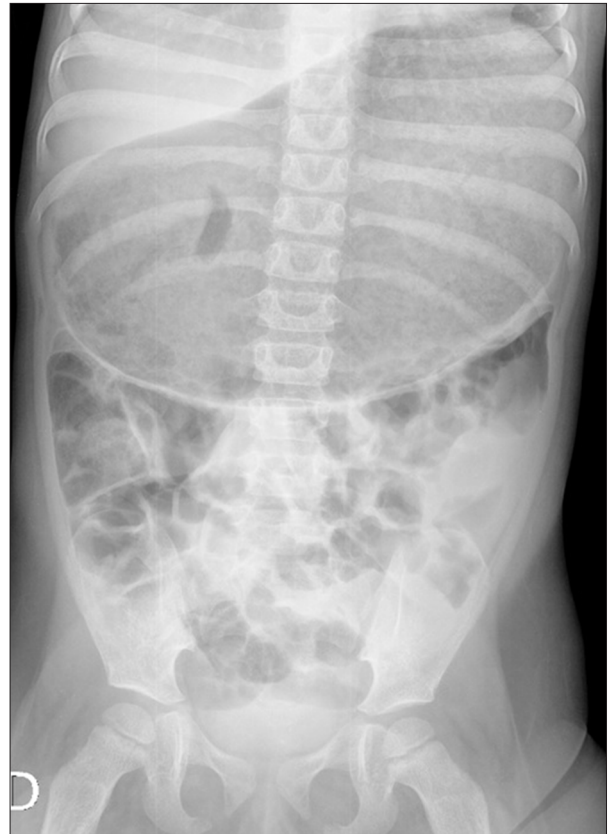

Figure 5. Abdominal x-ray with gastric dilatation.

At the age of 5 years and 7 months, the boy was readmitted to the ER for abdominal dilatation and malaise. Mild abdominal pain was referred the day before. On arrival, he was hypoactive, pale, and presented with *cutis marmorata* in the lower extremities. His abdomen was distended and tympanic. First, fluid was replaced with normal saline and a nasogastric tube was inserted to perform aspiration of gastric contents. Proton pump inhibitor and fasting were prescribed. An abdominal x-ray showed an important gastric dilatation (Figure 5). He was admitted to the PICU, where the abdominal tension was 12 mmHg, confirming the diagnosis of shock secondary to abdominal compartment syndrome due to gastric dilatation. The patient remained stable and after fasting for 24 h, tolerated oral intake and was discharged 3 days after.

Discussion

To our knowledge, this is the first case of repetitive gastric dilatation and abdominal compartment syndrome in a child with Prader-Willi syndrome.

Episodes of gastric dilatation have also been reported to be due to the ingestion of a large amount of food in a short period of time [9], as occurs in bulimia nervosa. In patients with

anorexia nervosa, who can spend long periods of time without eating and restrict their food intake, which leads to rapid weight loss, delayed gastric emptying has also been described and the possible mechanisms proposed are muscular atrophy and gastric atony or neurogenic gastric paresis [10].

Several mechanisms have been proposed to explain gastric dilatation and necrosis and why their incidence is so high in PWS patients. One of the possible causes may be hyperphagia, which is a central feature of PWS; affected individuals are able to consume large amounts of food in a short period of time in spite of environmental control. In addition, delayed gastric emptying, which is suspected in these patients in comparison to normal values, may cause gastric dilatation [5]. All these risk factors can lead to gastric dilatation and subsequent necrosis and perforation. However, in our case, the patient was under strict environmental control and no large amount of food was consumed before the episode. Furthermore, one of the pillars of the treatment of PWS is a restrictive diet and we are unaware whether this may have produced delayed gastric emptying in our patient, as occurs in anorexia nervosa.

As the etiology of gastric dilatation in PWS patients is currently unknown, new episodes are difficult to prevent. Several possible mechanisms have been proposed, and, as delayed gastric emptying is suspected, eating slowly may help prevent these episodes. It is also recommended to control and avoid the consumption of large amounts of food in short periods of times and to avoid rapid weight loss or gain in these patients.

Nevertheless, physicians should be aware of symptoms that can suggest the presence of gastric dilatation. Abdominal discomfort or vomiting is unusual in these patients. In fact, an inability to vomit and an increased threshold of pain are clinical signs supporting the diagnosis of PWS [1]. The presence of these symptoms should raise suspicion of gastric dilatation and necrosis. Early gastric decompression with a nasogastric

tube and aspiration of gastric contents should be performed. If repeated severe episodes occur, a possible solution is the use of a venting percutaneous gastrostomy to decompress the stomach [11].

In addition, we wonder whether any of the previously administered treatments (budesonide, salbutamol, or the homeopathic medicine) may have triggered gastric dilatation, although to our knowledge, little has been published on this topic to date. A possible explanation is that salbutamol may prolong gastric emptying [12]. Furthermore, the boy had received salbutamol on other occasions without presenting complications and he was not being treated with homeopathic remedies when the second episode occurred. We do not think that gastric dilatation was caused by the previous drugs administered to our patient, but their role as a trigger in predisposed patients remains unclear.

Conclusions

Gastric dilatation due to gastroparesis in PWS is a rare complication. However, it is a life-threatening situation. Physicians should consequently have a high level of suspicion in the presence of warning signs such as vomiting and abdominal pain. The cause for the higher incidence of gastric dilatation in patients with Prader-Willi syndrome deserves more investigation.

Acknowledgements

We thank Sylva-Astriak Torossian for her assistance in language editing.

Conflict of interest

Nothing to disclose.

References:

1. Cassidy SB, Schwartz S, Miller JL, Driscoll DJ: Prader-Willi syndrome. *Genet Med*, 2012; 14(1): 10–26
2. Miller JL, Lynn CH, Driscoll DC et al: Nutritional phases in Prader-Willi syndrome. *Am J Med Genet A*, 2011; 155A(5): 1040–49
3. Deal CL, Tony M, Höybye C et al: GrowthHormone Research Society workshop summary: Consensus guidelines for recombinant human growth hormone therapy in Prader-Willi syndrome. *J Clin Endocrinol Metab*, 2013; 98(6): E1072–87
4. Grugni G, Sartorio A, Crinò A: Growth hormone therapy for Prader-Willi syndrome: Challenges and solutions. *Ther Clin Risk Manag*, 2016; 12: 873–81
5. Arenz T, Schwarzer A, Pfluger T et al: Delayed gastric emptying in patients with Prader-Willi syndrome. *J Pediatr Endocrinol Metab*, 2010; 23(9): 867–71
6. Wharton RH, Wang T, Graeme-Cook F et al: Acute idiopathic gastric dilatation with gastric necrosis in individuals with Prader-Willi syndrome. *Am J Med Genet*, 1997; 73(4): 437–41
7. Stevenson DA, Heinemann J, Angulo M et al: Gastric rupture and necrosis in Prader-Willi syndrome. *J Pediatr Gastroenterol Nutr*, 2007; 45(2): 272–74
8. Schrandner-Stumpel CT, Curfs LM, Sastrowijoto P et al: Prader-Willi syndrome: Causes of death in an international series of 27 cases. *Am J Med Genet A*, 2004; 124A(4): 333–38
9. Nakao A, Isozaki H, Iwagaki H et al: Gastric perforation caused by a bulimic attack in an anorexia nervosa patient: Report of a case. *Surg Today*, 2000; 30(5): 435–37
10. Sato Y, Fukudo S: Gastrointestinal symptoms and disorders in patients with eating disorders. *Clin J Gastroenterol*, 2015; 8(5): 255–63
11. Mohammed AM, Dennis RJ: Use of a venting PEG tube in the management of recurrent acute gastric dilatation associated with Prader-Willi syndrome. *J Surg Case Rep*, 2016; 2016(1): pii: rjv174
12. Rees MR, Clark RA, Holdsworth CD et al: The effect of beta-adrenoceptor agonists and antagonists on gastric emptying in man. *Br J Clin Pharmacol*, 1980; 10(6): 551–54