

ORIGINAL ARTICLE

Surface Marker-Assisted for Orbital Navigation Surgery: A Dry Skull Study

NAZIMI AJ¹, NURAUDI ZAFIRAH AR², NUR SYAIRA I³, IZHAR AA⁴, MUHD FAZLYNIZAM R⁵

¹Department of Oral & Maxillofacial Surgery, Faculty of Dentistry, Universiti Kebangsaan Malaysia, Jalan Raja Muda Abdul Aziz, 50300, Kuala Lumpur, Malaysia

²Klinik Pergigian Parit Raja, Ministry of Health Malaysia, Jalan Kluang, 86400 Parit Raja, Batu Pahat, Johor

³Klinik Pergigian Taman Selasih, Ministry of Health Malaysia, 09000 Kulim, Kedah

⁴3D-Gens (M) Sdn Bhd., 18, Jalan Kerawang U8/108, 40150 Shah Alam, Selangor

⁵Oral & Maxillofacial Surgery Unit, Universiti Kebangsaan Malaysia Medical Centre, Jalan Yaacob Latif, Bandar Tun Razak, 56000 Cheras, Kuala Lumpur, Malaysia

ABSTRAK

Tujuan kajian ini adalah untuk menerokai kaedah pembantu penanda permukaan terhadap implan orbital untuk pembedahan tulang orbit. Enam tengkorak manusia dewasa kering telah digunakan dalam kajian ini. Implan orbital aluminium yang disediakan secara individu, dengan ketebalan 0.4 mm disediakan untuk lantai orbit secara bilateral. Empat penanda permukaan implan fizikal dari aspek anterior dan posterior implan yang disediakan dan diimbis secara optik. Pemeriksaan pra-pembedahan tomografi berkomputer 'cone-beam' (CBCT) diperolehi untuk semua lantai orbit. Data 'Digital Imaging and Communications in Medicine' (DICOM) tengkorak diambil, diimport dan direka bentuk dengan format data stereolithografi (STL) implan orbital masing-masing menggunakan iPlan CMF (Versi 3.0, BrainLab, Jerman). Teknik gabungan imej dilakukan untuk setiap tengkorak selepas pembinaan semula dengan pengambilan pos-pembedahan CBCT. Pengukuran berasaskan daripada data tomografi terhadap posisi implant kemudian dinilai di antara kedudukan implan yang direncanakan dan yang direalisasikan dalam satah sagittal dan coronal. Analisa statistik dijalankan menggunakan Statistik Statistik PASW® 18. Hasil kajian menunjukkan bahawa 38 daripada 48 penanda permukaan yang dinilai menunjukkan peningkatan ketinggian kedudukan dalam skala kecil pasca-pembedahan berbanding dengan kedudukan implan orbital maya. Semakan metrik Euclidean menunjukkan perbezaan yang kurang daripada 1.00 mm dalam semua penanda permukaan kecuali pada kawasan lej posterior dan anterior dalam penilaian satah sagittal. Kajian ini menunjukkan bahawa

Address for correspondence and reprint requests: Nazimi Abd Jabar. Department of Oral & Maxillofacial Surgery, Faculty of Dentistry, Universiti Kebangsaan Malaysia, Jalan Raja Muda Abdul Aziz, 50300 Kuala Lumpur, Malaysia. Tel: +603 9289 7772 Email: mohdnazimi@ukm.edu.my

penempatan penanda permukaan terhadap implant orbit dalam pembedahan navigasi orbit menyumbang kepada kedudukan implan orbital secara konsisten.

Kata kunci: pembedahan berbantu komputer, pembedahan navigasi, pembedahan orbit, penanda permukaan

ABSTRACT

The purpose of this study was to explore a surface marker-assisted method for orbital floor reconstruction. Six adults, dry human skulls were used in this study. First, an individualised, 0.4 mm aluminum orbital implant was prepared for orbital floor bilaterally. Four physical implant surface markers in the anterior and posterior aspects of the implant were created and subjected for an optical scan. Preoperative cone beam computed tomography (CBCT) scans were obtained for all orbital floors. The Digital Imaging and Communications in Medicine (DICOM) data were retrieved, imported and virtually reconstructed with its respective orbital implant stereolithography (STL) data by using iPlan CMF (Version 3.0, BrainLab, Germany). Navigation image-fusion technique was performed for each skull following navigation-assisted reconstruction and postoperative CBCT. Computed tomography (CT)-assisted measurements of the implant positions were evaluated between the virtually planned and realized implant positions in its translational differences sagittal and coronal planes. All statistical analysis was performed using PASW® Statistics Version 18. Results showed that 38 out of the 48 surface markers evaluated showed a small elevation in realized compared to the virtual orbital implant position. Translation for the Euclidean metric showed differences of less than 1.00 mm in all surface markers except at the posterior ledge and anterior when assessed in the sagittal plane. The study showed that the placement of surface marker-assisted in orbital navigation surgery provides a consistent orbital implant position.

Keywords: computer-assisted surgery, navigation surgery, orbital surgery, surface marker

INTRODUCTION

Trauma, tumor and developmental malformation could lead to debilitating deformity or defects in the oral and craniomaxillofacial region. In mid-facial maxillofacial trauma, the etiology of the injuries could be

attributed to motor vehicle accidents, industrial accidents, sports or an assault. Our previous study showed that midfacial fractures predominated all other facial fractures (Nordin et al. 2015). Accurate and definite surgical repair of an orbital fracture that occurs in concurrent midfacial fractures

poses significant surgical challenges to the surgeon. Anatomy of the orbit serves as one of the most complex regions for reconstruction, secondary to its contour and disrupted orbital landmarks (Dubois et al. 2015a). Both anatomical and function-related sequelae from complex orbital reconstructions are not uncommon and have been widely reported. In perfecting surgical outcomes, orbital surgery requires surgical strategy and the use of digital technology (Dai et al. 2016). Technology-based computer-assisted surgery (CAS) for more accurate and optimized treatment outcomes has also been described previously (Dubois et al. 2015a).

For a fail-safe orbital fracture reconstruction, adequate preoperative evaluation, computerised-surgical planning and accurate implant placement are crucial for successful reconstruction. Although craniofacial titanium implants may guarantee secure and reliable retention of the prosthesis, successful orbital implant surgery has long been attributed largely to the surgeon's clinical experience and performance. In a less experienced hand, the lack of training or even lack of exposure or the management of less cases by one surgeon in certain stipulated duration, does create surgical risks. "Cumulative" surgical errors may also occur in every step of the process (Varley et al. 2016). An error may occur during the preoperative and/or intraoperative stage which could be unique to the merit in which the stage is managed. Intraoperative errors may lead to improper placement of implants, resulting in poor clinical

outcomes (Dubois et al. 2015a, 2015b).

Following the development of modern digital surgical technology that began more than decades ago, computer-assisted simulation and navigation (CASN) has been reported as a useful strategy for clinical application (Nazimi et al. 2017). Improvements have been shown in the safety and outcomes of surgical procedure as it provides a consistent and more predictable approach or is regarded as target surgery compared to traditional methods (Dubois et al. 2015a). In addition, it is now well understood that the use of computed tomography for orbital reconstructive surgery has become a gold standard of care, in which the "raw" scan data may be granted with an extended task beyond diagnostic imaging alone. By using advanced diagnostic software modalities such as iPlan CMF software (Version 3.0.5; Brainlab®, Feldkirchen, Germany), injury analysis, and the need and "ideal" location of predefined implants, either preformed or patient-specific, can be assessed preoperatively.

Within the navigation-assisted surgical setting, preoperative planning provides the surgeon with direct translation from the office surgical plan to the operating table and serves as a guide map to the predetermined and ideal implant position (Schreurs et al. 2016). As it is direct and happening in real time, CASN provides the surgeon with a target location for the preformed implant to provide the best possible anatomical reconstruction of the orbital wall. The use of these specific applications and surgical

armamentariums allows continuous intraoperative coordination of the implantation phase and the virtual planning phase. This optimises the accuracy of implant position for satisfactory surgical results (He et al. 2020) and yields better titanium implant control in the posterior region of the orbit (Ellis & Tan 2003)

Orbital implant navigation not only contributes to an accurate orbital reconstruction, it also potentially reduces the rates of repeat procedures (Dubois et al. 2015b). This study demonstrates that navigation-assisted orbital reconstruction significantly improves implant positioning and enables a more accurate reconstruction than a conventional approach. Since a target location can be provided in CASN, the actual implant location could be located intraoperatively to simulate its respective virtually-planned position.

As such, if the shape of the individualized, preformed orbital implant is known, the reference frame can be created to quantify rotational and translational deviations, providing a “true” three-dimensional evaluation of the implant position (Schreurs et al. 2016). The reference frame could provide a “real-time” accuracy assessment and intuitive feedback to the surgeon with regard to necessary adjustments to reposition the implant close to the planned position.

In addition, by using navigational markers for implant orientation, the surgeon could increase their ability to focus on the implant location at critical points during the surgery to optimize surgical outcomes. Confirmation of

final implant position can be made possible with the use of a navigation pointer or probe. Using this technique, implantation procedures can be augmented with exact intra-operative positioning of the implant material.

The aim of this study was to explore a surface marker-assisted method for orbital surgery, aiming for a fail-safe reconstruction. Six adult human dry skulls were studied and the differences between virtually-planned and realised orbital implant position was quantitatively analysed. An image-fusion assessment was made to evaluate whether these additional pre-surgical steps are valuable in locating the final orbital implant position.

MATERIALS AND METHODS

The present study received approval from the Local Research Ethics Committee (PPI/111/8/JEP-2017-271) prior to its start. Six adult dry skulls were obtained, providing a total of twelve orbital floors for this study.

Using iCat Next Generation computed tomography (CT) (Imaging Sciences International Hartfield, PA, USA), 2 sets of cone-beam CT scans were acquired for each skull. The first scan served as a baseline scan with intact orbits (preoperative scan), and the second scan was taken after the physical reconstruction of the orbital floor bilaterally with a 0.4 mm, customized, aluminum-based implant (postoperative scan). The high-resolution bone scan algorithm was standardised as follows: Collimation, 10x0.3 mm; FOV 10x20 mm; matrix, 536x536; 120 kV, 5 mA; pixel, 0.3x0.3;




Figure 1: Optical scan (EinScan-Pro Scan, 3D Systems) of right orbital implant in stereolithographic (STL) data

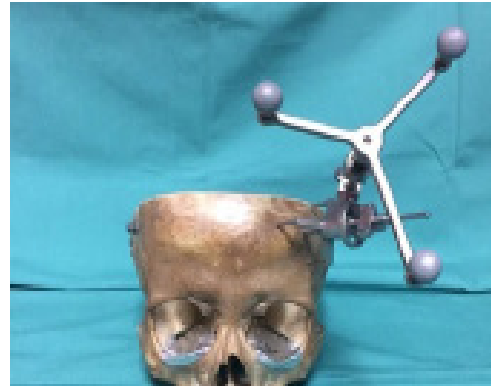

Figure 2: Dry skull with bilateral orbital floor custom implant in place during image-guided method

bit/pixel, 16; slice thickness, 0.3 mm. Both pre and postoperative scan data were retrieved and saved as Digital Imaging and Communications in Medicine (DICOM) format prior to importing into the navigation for analysis.

The customised orbital implant was prepared using a non-precious, 0.4 mm thick aluminum implant based on each orbital floor anatomy (author NZAR and NSI), adapted onto the

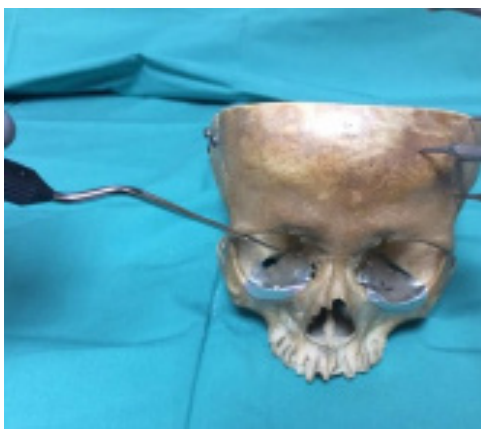

Figure 3: Dry skull with a custom implant on right orbital floor and navigation probing of the right posterior ledge

orbital floor bilaterally. This serves later as the realised implant position. In total, four physical surface markers were embedded in the planning design, divided into the anterior and posterior regions. All orbital implants underwent an optical scan (EinScan-Pro Scan, 3D Systems), saved as stereolithographic (STL) data (Figure 1). The implant data, comprising of its converted physical-to-digital surface markers, were imported along with their respective DICOM data for the virtual reconstruction by iPlan CMF (Version 3.0, BrainLab, Germany). The navigation procedure was completed using the Brainlab Kick navigation platform (BrainLab, Germany) (Figure 2 & 3). CASN was used to enable understanding of all chosen surface markers and provide real-time positional feedback of the implant positions from all axial, coronal and sagittal views (Figure 4).

Both the virtual and realised implant position were assessed for implant placement accuracy via the automatic image fusion module in iPlan CMF (Version 3.0, BrainLab, Germany). All

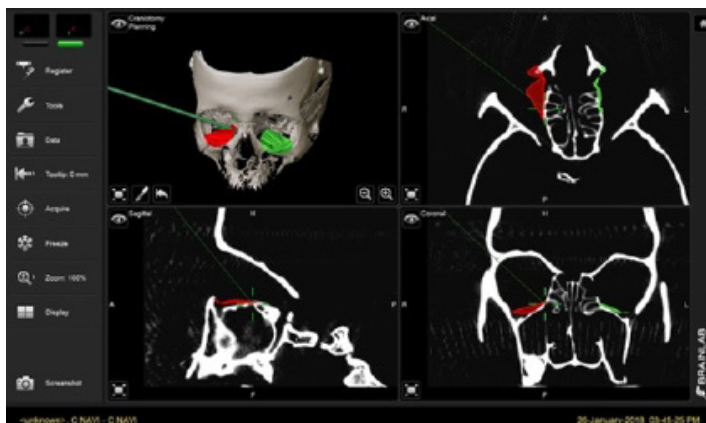


Figure 4: Navigation images at the posterior ledge, simultaneously viewed from an axial, coronal and sagittal plane

four surface markers were marked and assessed for translational differences between planned and realised implant positions. Image fusion was performed automatically by the software using routine, intact surrounding bone architectural parameters. The 2 anterior points along the intact medial and lateral inferior orbital rim at the level of the infraorbital foramen were assessed from the coronal scan. Another 2 points were each placed on the posterior ledge and anteriorly, just

posterior to the infraorbital foramen, with assessment completed from the sagittal scan (Figure 5). Data from both scans were fused, and surface markers on the planned implant position were measured against the realised implant position to evaluate its accuracy (Figure 6 & 7).

Difference values were calculated on each orbit based on the translational parameter, in millimeters (mm), of the orbital implant dislocation frame. Image magnification was standardised at 100% during the assessment. When the realised implants were positioned accurately according to the planned implants, no difference in value was recorded and the value was stated as zero. Otherwise, if the realised implants were positioned superiorly or in an elevated position compared to the planned implants, the value would be interpreted as positive or elevated. However, if the realised implants were placed inferiorly to the planned position, the value would be negative and defined as correct. All the 12-orbital data were entered

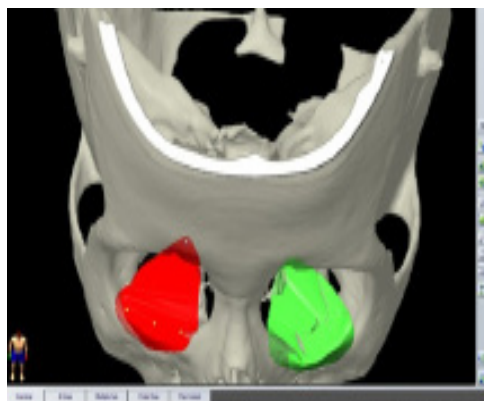


Figure 5: Imported STL bilateral orbit (with the surface marker on right orbit), seen in iPlan navigation prior to image fusion

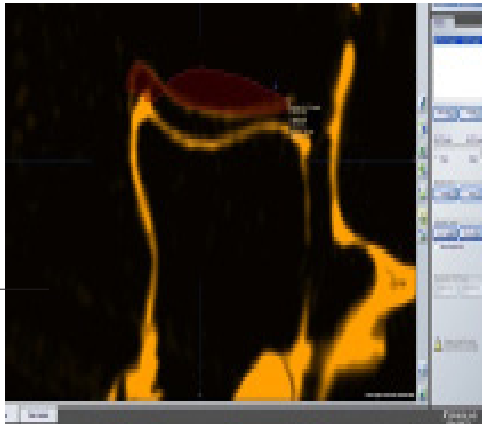


Figure 6: Sagittal view of fused CT scan images of realized (in yellow) and planned (in red) implant position at the anterior and posterior ledge position of the orbital floor

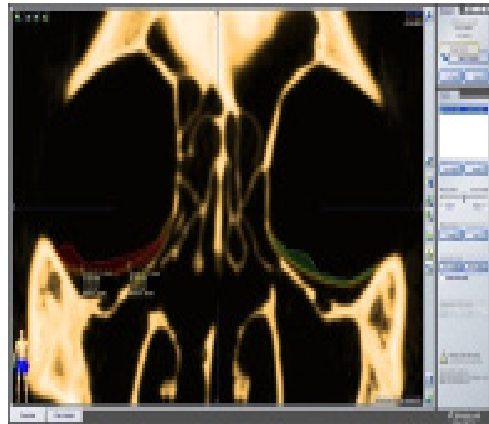


Figure 7: Coronal view of fused CT scan images of realized (in yellow) and planned (in red and green) implant position at the medial and lateral position of the orbital floor at the level of the inferior orbital foramen

into PASW® Statistics Version 18 and analyzed in two different groups, sagittal and coronal. The data were evaluated for mean and standard deviation, and the maximum and minimum values of the differences between realized and planned implant position.

RESULTS

The translational differences between the realised and planned implant

position in our study showed that 77.10% of the total surface markers created on the 12 individualised orbital implants were found in an elevated realised position. Overall, 21 elevated positions were observed in the coronal assessment compared to 16 in the sagittal assessment. From all orbital implant positioning, discrepancies were noted to be maximal at 1.70 mm, which occurred in the medial and lateral coronal assessment. Overall, only minor differences were seen in the

Table 1: Elevated and under correction position between realized and planned implant in sagittal assessment

Difference between Realized and Planned Implant position	SAGITTAL, N (%)			
	ANTERIOR 12 (100)		POSTERIOR LEDGE 12 (100)	
	Elevated Position 8 (66.7)	Under-Correct Position 4 (33.3)	Elevated Position 8 (66.7)	Under-Correct Position 4 (33.3)
Mean ± Standard Deviation	0.60 ± 0.50	1.10 ± 0.25	0.73 ± 0.51	1.40 ± 0.42
Minimum	0.000	0.900	0.000	0.900
Maximum	1.300	1.400	1.400	1.800

Table 2: Elevated and under correction position between realized and planned implant in coronal assessment

Difference between Realized and Planned Implant position	CORONAL, N (%)			
	MEDIAL 12 (100)		LATERAL 12 (100)	
	Elevated Position 10 (83.3)	Under-Correct Position 2 (16.7)	Elevated Position 11 (91.7)	Under-Correct Position 1 (8.3)
Mean ± Standard Deviation	0.63 ± 0.56	0.60 ± 0.14	0.86 ± 0.54	NA
Minimum	0.000	0.500	0.000	NA
Maximum	1.700	0.700	1.700	NA

mean plus-minus standard deviation value of elevated data, both in the sagittal and coronal sections. Similarly, only minor differences (range 1.30 to 1.70 mm) were seen in the maximal elevation when both coronal and sagittal image fusions were compared together. A small number of under correct orbital implants with better displacement consistency was seen in both sagittal and coronal assessments (Table 1 & 2).

When assessed from sagittal image fusion, the Euclidean metric yielded the highest translation of 1.40 mm, located on the posterior ledge with a standard deviation of 0.51 mm. Although half in number compared to the elevated posterior ledges, the under correct posterior ledge showed slight increments in their maximal discrepancies in the actual and realised orbital implant position (n=4, 1.80 mm). Although low in its frequency, we found that the anterior orbit assessed in the sagittal section showed a similar number of under correct realised plates. Calculation yielded an average distance of 1.10 mm with a standard deviation of 0.25 mm.

For the coronal view group, as depicted in Table 1.2, a total number of 12 orbital floors were assessed, both in medial and lateral position. The coronal image fusion assessment showed almost the same number of elevated translations, seen both in the medial and lateral orbit (elevation mean 0.63 mm and 0.9 mm, respectively) (Table 2). Overall, less under correct realized implant positions occurred in the coronal section, with almost perfect results seen on the lateral orbit. Plate elevation was noted to be highest in the coronal assessment (n=10, medial orbit; n=11, lateral orbit) as compared to the findings of the sagittal assessment.

Specifically, for the posterior ledge, the mean ± standard deviation value of the elevated plate position was recorded as 0.73 ± 0.51 mm. Meanwhile, the mean for under correction was noted to be almost double the distance at 1.40 mm ± 0.42 mm. For the elevated data, the minimum value was 0.00 mm and the maximum value was 1.40 mm, whereas the minimum and maximum values for the under correct implant data were 0.90 mm and 1.80

mm, respectively.

DISCUSSION

A previous study emphasised on the accuracy of final orbital implant placement with the aim to reconstruct the bony anatomy and restore orbital volume to its true original condition (Schreurs et al. 2016). Although recent analysis has suggested that the influence of accurate mechanical reconstruction on the clinical outcomes may be less predictable than previously believed, with the suggestion that consideration should also be given to the role of soft-tissue related factors (Zimmerer et al. 2018), accurate orbital implant placement is still a crucial factor, especially when it is just based on clinician expertise or experience. Without the use of technology, the decision/indecision of the final orbital implant position was among the most common clinical problems encountered intraoperatively and may have unnecessarily increased operating times. This could lead to orbital implant malposition and further increase the risk of debilitated orbital surgery complications such as enophthalmos, binocular diplopia and motility disturbances.

Good preoperative evaluations, careful surgical planning and preparation, and accurate conduct of surgery are mandatory for successful reconstruction. With the rapid advancement of computer technology, it is now well accepted that the use of CT data has gone beyond its role as a diagnostic tool alone, especially in complex defects

such as orbital fractures (Dubois et al. 2015a). Advanced diagnostic software modalities, such as iPlan CMF software (Version 3.0.5; Brainlab®, Feldkirchen, Germany) and many others that are commercially available, augment the surgeon's decision on the ideal location of the preformed, customised or patient-specific implant. These surgical methods could assist the surgeon as an invaluable intraoperative guide map to a predetermined implant location (Schreurs et al. 2016).

The use of CAS provides the surgeon with an intraoperative target location so that the orbital implant can be placed to provide the best possible anatomical reconstruction of the affected orbit. Being part of CAS, the navigation system can be implemented by utilising the preoperative CT scan DICOM® data for virtual planning and export for intraoperative use. Navigation orbital surgery allows for continuous intraoperative coordination of both the reduction and implantation phase and was regarded as a valuable treatment option in this potentially complicated procedure (Yu et al. 2010). It was also suggested that the application of navigation guidance orbital surgery yielded the accurate orbital reconstruction and reduced the rates of repeat procedures (Dubois et al. 2015b). Navigation-assisted orbital reconstruction significantly improves implant positioning, enabling an accurate final implant position (Dubois et al. 2015c). In addition, with an implant-oriented navigation approach, the surgeon will be able to focus on the actual implant position and further determine the exact intra-operative

positioning of the similar implant used during its virtual planning (Dubois et al. 2015c).

In this study, we explored a surface marker-assisted method for orbital navigation surgery, aiming for a fail-safe orbital reconstruction by using a dry, adult human skull. The planned position of the implant, based on the created physical surface markers, was transferred into the planning system to ensure optimal placement of the implant. As previously mentioned, it serves as the target in positioning the implant. Since the planned position sets the target for implant positioning during surgery, it is simply understandable that the same planned position could be used to evaluate the surgical target or position so that a postoperative assessment can be made if the reconstruction has been performed according to its plan. However, this could only happen when computer-assisted surgery is used from the beginning, as the method provides individual measures for translational parameters in the implant position. This is now possible in our center as we have started implementing this surgical technology since July 2015. However, based on a recent study that concluded that final surgical outcomes were possibly determined by more than implant final resting position alone, we simplify the method based on the original description of the orbital implant dislocation frame (Schreurs et al. 2016). However, how much implant parameter malposition could occur and possibly introduce clinical problems were not within the scope of this study. Taking other factors

together, we believe that the closer the final resting position of the implant to the pre-injury position of the bony orbit is one of the most important prognostic factors or predictors for successful orbital fracture surgery. In this study, four translational (Euclidean metric) reference points were selected both at the anterior, posterior, medial, and lateral points, with the assessment done within sagittal and coronal planes.

The automatic image fusion of both preoperative and postoperative scans within the iPlan CMF (Version 3.0, BrainLab, Germany) provides the possibility of comparing the realised position to its virtual surgical planning position for postoperative accuracy assessment. By using this automated method, in which the sequences are performed automatically by the software using routine, intact surrounding bone architectural parameters, robust and accurate analysis can be achieved, comparing the realised position to the planned virtual position. This technique was well-described earlier (Dubois et al. 2015c).

Additionally, it is also worth mentioning that since the operative plan is also subjected to inaccuracies during planning, due to the extremely complex orbital structures (Cai et al. 2012), the contralateral unaffected orbit can be mirrored following determination of the reference frame to reduce bias and may inadvertently help in better positioning of the implant. However, these measurements are reported to be interfering with the assumption of symmetry between

affected and unaffected orbits and errors originating from the choice of measurement points. Additionally, slice thickness and implant scatter are scan-related factors that could also affect the accuracy of linear measurements. We did not employ this in our study: firstly, mainly due to its complex study methodology and secondly, the limited number of dry skulls available in which the study plan needs to use both orbits as to have a better number of subjects. It is also worth mentioning that the accuracy of the realised implant position technique in relation to the planned implant position could be well appreciated compared to the mirrored orbit technique which indirectly abolishes the error associated with the mirroring processes. However, it is unknown if the result would be different if the mirroring technique is employed, since the sample size could simply be doubled with this technique. Additionally, the potential role of orbital soft tissue components in orbital reconstructive surgery is also beyond the scope of this study.

From this study, we learned that the posterior ledge point has the maximum value of the difference between the realized and planned implant position. The complexity of assessing this area could well explain these findings and remained more so during the surgery (Ellis & Tan 2003). The study proves the clinical problems commonly encountered by the surgeon, in which most orbital surgeons acknowledge the difficulties in placement or in deciding the end-direction of the orbital implant in this most posterior aspect of the orbital cavity. Albeit that less than

1.00 mm of inaccuracy was found in this region, most of the feedback data favors the elevated realised implant position in comparison to the planned implant position. This could pose a real clinical risk, especially in an oedematous and anatomically confined posterior orbit during surgery that goes beyond the scope of this study. Similarly, under correct implant was also observed, which could implicate the overall orbital surgery outcomes, especially the risk of enophthalmos. Plate elevation found in the anterior region in this study was rather unexpected since the area was the most accessible and surgically amenable. However, whether the slight elevation correlates overall with either good or worsening clinical outcomes could not be determined with this study alone, taking into consideration the non-quantifiable soft tissue trauma or damage that may occur because of the nature of the surgery and its invasiveness (Zimmerer et al. 2018).

The study also supports the concept of orbital pre-bend, individualised implants that could render the practice of intraoperative bending of the implant obsolete or mean that it was no longer viewed as an acceptable practice. As seen from both coronal and sagittal aspects, the almost perfect implant position was observed throughout, within a millimeter of accuracy. Similarly, under correct positioning occurred within the same limits. The mean and respective standard deviation values between realized and planned positions were also small. Therefore, our data further verified previous Caucasian cadaveric

studies which indicated that there would be a near accurate placement of realised implants following planned implant position with the use of a custom orbital implant solution. However, it is worth mentioning that even the choice of the trajectory or reference points may affect the results differently. The method used in this study was simplified by only assessing the translation parameters. Other parameters, especially volumetric assessment to the orbital cavity, herniated volume and even the size of defects are not a straightforward assessment method. Clinically, this method could potentially be used for routine, quick and accurate evaluation of surgical results and could address immediate clinical decisions if re-operations were needed.

CONCLUSION

Surface marker-assisted orbital navigation surgery provides a consistent orbital implant position for a fail-safe orbital reconstruction. It provides direct intraoperative feedback to the clinicians, giving more insight into the final implant position. Despite several key factors that may unequivocally be responsible for the outcomes of orbital reconstruction, the study highlights the importance in achieving accurate final resting positions of orbital implants.

ACKNOWLEDGEMENT

The authors would like to express their gratitude to the Brainlab Malaysia for providing the computer-assisted platform and to Mr Badrul Hafiz

Ghazali, Design Engineer from 3D Gen Malaysia, for his assistance with the EinScan-Pro optical scan.

REFERENCES

- Cai, E.Z, Koh, Y.P., Hing, E.C.H., Low, J.R., Shen, J.Y., Wong, H.C., Sundar, G., Lim, T.C. 2012. Computer-assisted navigational surgery improves outcomes in orbital reconstructive surgery. *J Craniofac Surg* 23(5): 1567-73.
- Dai, J., Wu, J., Wang, X., Yang, X., Wu, Y., Xu, B., Shi, J., Yu, H., Cai, M., Zhang, W., Zhang, L., Sun, H., Shen, G., Zhang, S. 2016. An excellent navigation system and experience in craniomaxillofacial navigation surgery: a double-centre study. *Sci Rep* 16(6): 28242.
- Dubois, L., Schreurs, R., Jansen, J., Maal, T.J.J., Essig, H., Gooris, P.J.J., Becking, A.G. 2015a. Predictability in orbital reconstruction: a human cadaver study. Part II: navigation-assisted orbital reconstruction. *J Craniofac Surg* 43(10): 2042-9.
- Dubois, L., Steenen, S.A., Gooris, P.J., Mourits, M.P., Becking, A.G. 2015b. Controversies in orbital reconstruction-I. Defect-driven orbital reconstruction: A systematic review. *Int J Oral Maxillofac Surg* 44(3): 308-15.
- Dubois, L., Essig, H., Schreurs, R., Jansen, J., Maal, T.J., Gooris, P.J.J., Becking, A.G. 2015c. Predictability in orbital reconstruction. A human cadaver study, part III: Implant-oriented navigation for optimized reconstruction. *J Cranio-Maxillofacial Surg* 43(10): 2050-6.
- He, Y., Zhang, Y., Yu, G.Y., Guo, C.B., Shen, G.F., Peng, X., Liu, X.J., Wang, J., Zhang, W.B., Liu, Y.P., Gu, X.M., Tian, W.D., Lu, L., Li, Z.B., Zhang, S.L. 2020. Expert Consensus on Navigation-guided Unilateral Orbital Fracture and Orbital Floor Reconstruction Techniques. *Chin J Dent Res* 23(1): 51-5.
- Ellis, E., Tan, Y. 2003. Assessment of internal orbital reconstructions for pure blowout fractures: Cranial bone grafts versus titanium mesh. *J Oral Maxillofac Surg* 61(4): 442-53.
- Nazimi, A.J., Nordin, R., Nabil, S., Mohd Yunus, S.S., Tan, H.L., Rajandram, R.K., Ramli, R., Yu, Y., Peng, X., Zhang, Y. 2017. Application of digital techniques in oral and maxillofacial surgery at UKM Medical Centre - a case series [abstract]. *Int J Oral Maxillofac Surg* 46(1): 372.
- Nordin, R., Rahman, N.A., Rashdi, M.F., Yusoff, A., Rahman, R.A., Saperi, B.S., Nur, A.M., Razak, N.A., Nazimi, A.J., Ibrahim, M.I., Mohamed, N., Raja Ahmad, S.H., Ramli, R. 2015. Oral and maxillofacial trauma caused by road traffic accident in two university hospitals in Malaysia:

- A cross-sectional study. *J Oral Maxillofac Surg Med Pathol* 27(2): 166-71.
- Schreurs, R., Dubois, L., Becking, A.G., Maal, T.J.J. 2016. Quantitative assessment of orbital implant position-a proof of concept. *PLoS One* 11(3): 1–14.
- Varley, I., White, L., Salvi, S.M., Lee, N. 2016. Digital import of orbital implants to enhance navigation in reconstruction of the deep orbit. *Orbit* 35(1):20-3.
- Yu, H., Shen, G., Wang, X., Zhang, S. 2010. Navigation-guided reduction and orbital floor reconstruction in the treatment of zygomatic-orbital-maxillary complex fractures. *J Oral Maxillofac Surg* 68(1): 28–34.
- Zimmerer, R.M., Gellrich, N.C., von Bülow, S., Brad, S., Ellis, E., Wagner, M.E.H., Sanchez Aniceto, G., Schramm, A., Grant, M.P., Thiam Chye, L., Rivero Calle, A., Wilde, F., Perez, D., Bittermann, G., Mahoney, N.R., Redondo Alamillos, M., Ba i, J., Metzger, M., Rasse, M., Dittman, J., Rometsch, E., Espinoza, K., Hesse, R., Cornelius, C.P. 2018. Is there more to the clinical outcome in posttraumatic reconstruction of the inferior and medial orbital walls than accuracy of implant placement and implant surface contouring? A prospective multicenter study to identify predictors of clinical outcome. *J Cranio-Maxillofaci Surg* 46(4): 578-87.

Received: 21 Feb 2020

Accepted: 2 Jun 2020