

University of Dundee

**A marking of the cricothyroid membrane with extended neck returns to correct position after neck manipulation and repositioning**

Bowness, James; Teoh, Wendy H.; Kristensen, Michael S.; Dalton, Andrew; L. Saint-Grant, Alexander; Taylor, Alasdair

*Published in:*  
Acta Anaesthesiologica Scandinavica

*DOI:*  
[10.1111/aas.13680](https://doi.org/10.1111/aas.13680)

*Publication date:*  
2020

*Document Version*  
Peer reviewed version

[Link to publication in Discovery Research Portal](#)

*Citation for published version (APA):*

Bowness, J., Teoh, W. H., Kristensen, M. S., Dalton, A., L. Saint-Grant, A., Taylor, A., Crawley, S., Chisholm, F., Varsou, O., & McGuire, B. (2020). A marking of the cricothyroid membrane with extended neck returns to correct position after neck manipulation and repositioning. *Acta Anaesthesiologica Scandinavica*, 64(10), 1422-1425. <https://doi.org/10.1111/aas.13680>

**General rights**

Copyright and moral rights for the publications made accessible in Discovery Research Portal are retained by the authors and/or other copyright owners and it is a condition of accessing publications that users recognise and abide by the legal requirements associated with these rights.

- Users may download and print one copy of any publication from Discovery Research Portal for the purpose of private study or research.
- You may not further distribute the material or use it for any profit-making activity or commercial gain.
- You may freely distribute the URL identifying the publication in the public portal.

**Take down policy**

If you believe that this document breaches copyright please contact us providing details, and we will remove access to the work immediately and investigate your claim.



DR JAMES BOWNESS (Orcid ID : 0000-0002-8665-1984)

DR MICHAEL SELTZ KRISTENSEN (Orcid ID : 0000-0001-9462-1665)

Article type : Clinical investigation

## A marking of the cricothyroid membrane with extended neck returns to correct position after neck manipulation and repositioning

James Bowness, Wendy H Teoh, Michael Seltz Kristensen, Andrew Dalton, Alexander Le Saint-Grant, Alasdair Taylor, Simon Crawley, Fraser Chisholm, Ourania Varsou, Barry McGuire

Corresponding author:

Michael Seltz Kristensen

Department of Anaesthesia, Centre of Head and Orthopaedics,

Rigshospitalet, University of Copenhagen,

Blegdamsvej 9, DK-2100 Copenhagen Ø,

Denmark

Email: Michael.seltz.kristensen@regionh.dk

Conflicts of interest: None

This article has been accepted for publication and undergone full peer review but has not been through the copyediting, typesetting, pagination and proofreading process, which may lead to differences between this version and the Version of Record. Please cite this article as doi: [10.1111/AAS.13680](https://doi.org/10.1111/AAS.13680). This article may be used for non-commercial purposes in accordance with Wiley Terms and Conditions for Self-Archiving.

This article is protected by copyright. All rights reserved

## **Abstract:** Background

Emergency front of neck airway access by anaesthetists carries a high failure rate and it is recommended to identify the cricothyroid membrane before induction of anaesthesia in patients with a predicted difficult airway. We have investigated whether a marking of the cricothyroid membrane done in the extended neck position remains correct after the patient's neck has been manipulated and subsequently repositioned

## Methods

The subject was first placed in the extended head and neck position and had the cricothyroid membrane identified and marked with three methods, palpation, 'laryngeal handshake' and ultrasonography and the distance from the suprasternal notch to the cricothyroid membrane was measured.

The subject then moved off the table and sat on a chair and subsequently returned to the extended neck position and examinations were repeated.

## Results

Skin markings of all 11 subjects lay within the boundaries of the cricothyroid membrane when the subject was repositioned back to the extended neck position and the median difference between the two measurements of the distance from the suprasternal notch was 0 mm (range 0-2 mm).

## Conclusion

The cricothyroid membrane can be identified and marked with the subject in the extended neck position.

Then the patient's position can be changed as needed, for example to the 'sniffing' neck position for conventional intubation. If a front of neck airway access is required during subsequent airway management, the patient can be returned expediently to the extended-neck position, and the marking of the centre of the membrane will still be in the correct place.

Editorial Comment:

If landmarks in the front of the neck are difficult to identify, there would be difficulty in performing an emergent cricothyroidotomy if needed. This study assesses head and neck position and marking for skin over the cricothyroid membrane particularly in females, using ultrasound as a reference.

Emergency front of neck airway (eFONA) access by anaesthetists carries a high failure rate, partially due to inability to identify the cricothyroid membrane<sup>1</sup> in the emergency situation. Therefore, it is recommended to identify the cricothyroid membrane *before* induction of anaesthesia in patients with a predicted difficult airway,<sup>2</sup> if necessary by using ultrasonography.<sup>3,4</sup>

Emergency front of neck airway (eFONA) access should be performed with the patient placed in the extended head and neck position as recommended by the Difficult Airway Society.<sup>5</sup>

A change in the position of the patients' neck will often lead to a change in the position of a marking on the skin in relation to the location of the cricothyroid membrane, so that a marking made in the neutral position will no longer be on the cricothyroid membrane when the patient's neck is subsequently extended.<sup>6</sup> We have investigated whether a marking of the cricothyroid membrane (CTM) done in the extended neck position remains correct over time and after the patient's neck has been manipulated and subsequently repositioned *back* to the extended neck position.

## Methods:

After informed written consent and ethical committee approval eleven female subjects (Table 1) were studied.

The subject was first placed in the extended head and neck position on the operation table and two anaesthesiologist investigators, both having extensive experience of using the three methods of identification in both the clinical and the experimental setting, identified the CTM with both palpation, 'laryngeal handshake'<sup>7</sup> and ultrasonography.<sup>3</sup> The inferior and superior border of the CTM were identified and the central point was marked with a permanent marker pen guided by ultrasonography, using the reference "string of beads/pearls"-technique.<sup>8</sup> The techniques is described in Figure 1 and in this video: [www.airwaymanagement.dk/pearls](http://www.airwaymanagement.dk/pearls).<sup>9</sup>

Figure 1 near here.

Thereafter the superior border of the sternal bone was identified with palpation and the distance from the suprasternal notch to the CTM was measured. The subject then moved off the table and sat on a chair in order to alter the position of the head and neck and underlying laryngeal structures. Subsequently the subject was returned to the operation table and to the extended neck eFONA position, with the accuracy of the position in relation to that used for the first assessment confirmed by eye, as would be the case in clinical practice, and reassessed using the same methods. Two different methods were employed for evaluating whether the marking of the CTM returned to the original correct position after manipulation and subsequent repositioning of the subject.

Method 1: The distance from the suprasternal notch to the centre of the CTM was again measured. The difference in these distances (before and after repositioning) was calculated.

Method 2: Ultrasound was used to determine the upper and lower boundary of the CTM again, to determine whether the initial marking on the skin still lay within these boundaries, after the patient's movement and subsequent repositioning.

The success rate of correct repeated placement of the marking of the CTM is described with 95% confidence intervals (CI) of the binominal distribution.

## Results

The median difference between the two measurements of the distance from the suprasternal notch to the centre of the CTM was 0 mm (range 0-2 mm) and all skin markings, 11/11 = 100 % (72-100%) (95% CI of the binominal distribution), lay within the boundaries of the CTM when reassessed after subject movement and subsequent repositioning back to the extended neck position (Table 1).

Table 1 near here.

## Discussion

Using two different measurement techniques we found that the marking of the CTM in all subjects returned to the original position, within few millimetres, after manipulation and subsequent repositioning of the subject. One study has previously found that after manipulation, the marking of the CTM remained within few millimetres distance from the original position.<sup>10</sup> However, that was in a predominantly (78 %) male population and with only one technique of identification. The present study thus confirms the findings of the abovementioned study, and additionally supports an extrapolation to the female population. The consistency of the findings between these studies allows to combine these results which reveal that the marking of the CTM stays in the correct position, in all 34 of 34 measured cases = 100 % (90-100 %) (95% CI).

Previous studies have shown that *visual inspection of the skin creases* on the neck correctly revealed the position of the CTM in half of the patients in a mixed population. Success rates of identification of the CTM by *palpation* varies with gender, patient positioning and body habitus.<sup>3</sup> In males it was reported to be successful in 72% of non-obese<sup>11</sup> and in 39% of the obese.<sup>11</sup> In females success rates were 24%<sup>11</sup>, 25% (neutral position)<sup>12</sup>, 29% (hyperextended neck)<sup>12</sup> and 71% in the non-obese<sup>13</sup> whereas it was found to be 0% (neutral position)<sup>12</sup>, 6% (hyperextended neck)<sup>12</sup>, 35%<sup>11</sup>, 37%<sup>14</sup> and 39%<sup>15</sup> in obese females. It is thus clear from the literature that clinical identification of the CTM is on average considerably more difficult in the female gender, thus making it even more important to perform the identification *before* the need for at surgical airway could arise. We therefore decided to perform the present study in female subjects.

Ultrasonography carries a high success rate in identification of the CTM, reaching close to hundred percent in experienced hands,<sup>3</sup> and is thus used as the reference-method in most studies on CTM-identification, but it takes longer time to perform and should thus be used *before* induction of anaesthesia.

The findings in the present study reinforce the recommendation to identify the CTM before managing the airway,<sup>2</sup> especially in patients with predictors of difficulties in airway management. The marking can be guided by visual inspection or palpation if possible, otherwise it should be guided by ultrasonography. Following the marking of the CTM, the patient's position can be changed as needed, for example to the 'sniffing' neck position for conventional intubation. In the scenario of a front of neck airway being required during subsequent airway management, the patient can be returned expediently to the extended-neck position, and the marking of the centre of the CTM will still be in the correct place.

## References

1. Hamaekers AE, Henderson JJ. Equipment and strategies for emergency tracheal access in the adult patient. *Anaesthesia* 2011; 66 Suppl 2: 65-80.
2. Kristensen MS, Teoh WH, Baker PA. Percutaneous emergency airway access; prevention, preparation, technique and training. *British journal of anaesthesia* 2015; 114: 357-61.
3. Kristensen MS, Teoh WH, Rudolph SS. Ultrasonographic identification of the cricothyroid membrane: best evidence, techniques, and clinical impact. *British journal of anaesthesia* 2016; 117 Suppl 1: i39-i48.
4. Athanassoglou V, Hughes-Jones H, Hadjipavlou G, Teoh WH, Kristensen MS, Vanner R. Depth to the airway lumen at the level of the cricothyroid membrane measured by ultrasound. *Acta anaesthesiologica Scandinavica* 2020; 64: 48-52.
5. Frerk C, Mitchell VS, McNarry AF, Mendonca C, Bhagrath R, Patel A, O'Sullivan EP, Woodall NM, Ahmad I, Difficult Airway Society intubation guidelines working g. Difficult Airway Society 2015 guidelines for management of unanticipated difficult intubation in adults. *British journal of anaesthesia* 2015; 115: 827-48.
6. Dixit A, Ramaswamy KK, Perera S, Sukumar V, Frerk C. Impact of change in head and neck position on ultrasound localisation of the cricothyroid membrane: an observational study. *Anaesthesia* 2019; 74: 29-32.
7. Bair AE, Chima R. The inaccuracy of using landmark techniques for cricothyroid membrane identification: a comparison of three techniques. *Academic emergency medicine : official journal of the Society for Academic Emergency Medicine* 2015; 22: 908-14.
8. Kristensen MS. Ultrasonography in the management of the airway. *Acta anaesthesiologica Scandinavica* 2011; 55: 1155-73.
9. Anaesthesiologists AF. (2016) pearls. [www document] <http://airwaymanagement.dk/pearls> [accessed on June 15th 2020]
10. Mallin M, Curtis K, Dawson M, Ockerse P, Ahern M. Accuracy of ultrasound-guided marking of the cricothyroid membrane before simulated failed intubation. *The American journal of emergency medicine* 2014; 32: 61-3.



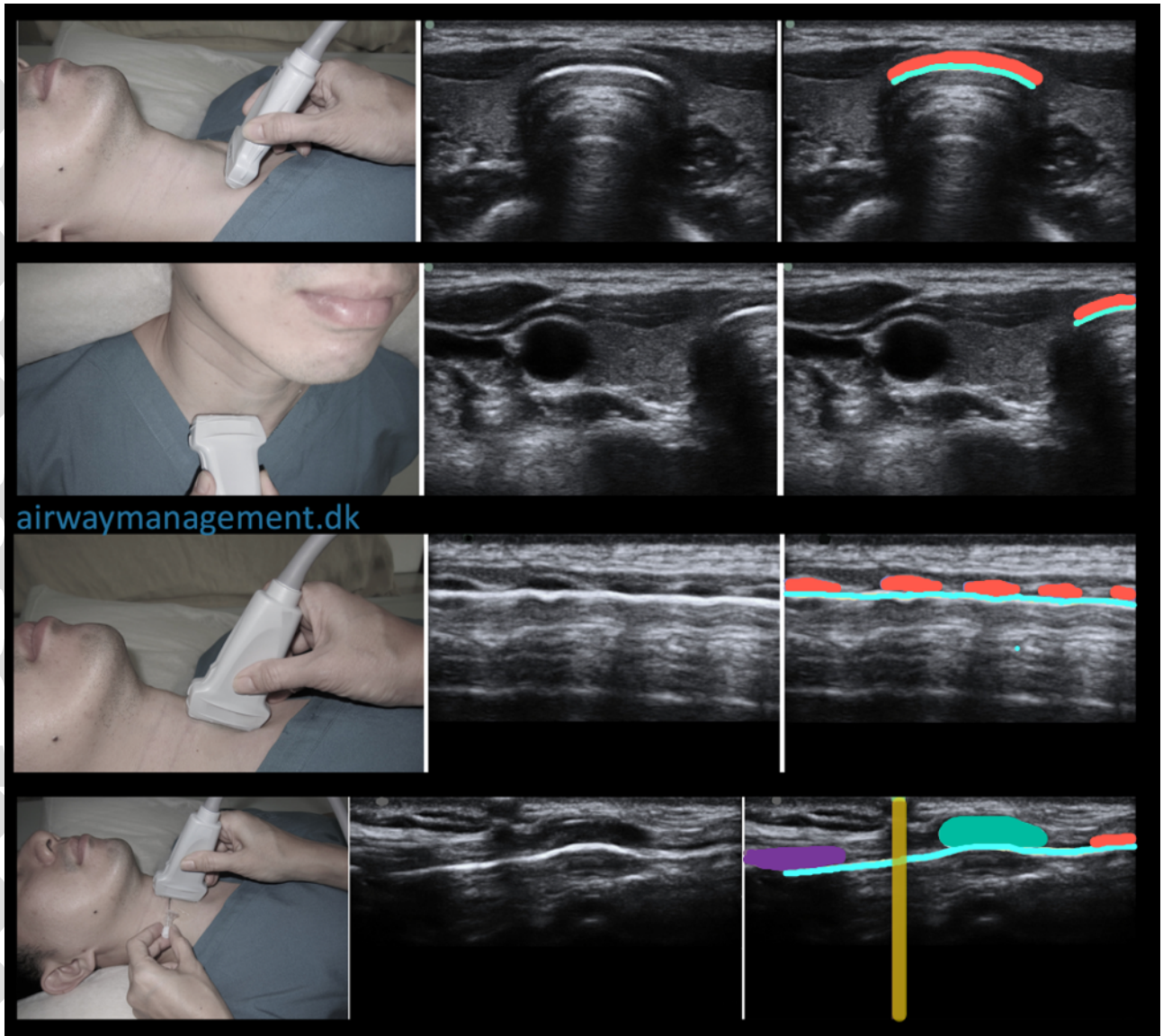
11. Lamb A, Zhang J, Hung O, Flemming B, Mullen T, Bissell MB, Arseneau I. Accuracy of identifying the cricothyroid membrane by anesthesia trainees and staff in a Canadian institution. *Canadian journal of anaesthesia = Journal canadien d'anesthesie* 2015.
12. Aslani A, Ng SC, Hurley M, McCarthy KF, McNicholas M, McCaul CL. Accuracy of identification of the cricothyroid membrane in female subjects using palpation: an observational study. *Anesthesia and analgesia* 2012; 114: 987-92.
13. You-Ten KE, Desai D, Postonogova T, Siddiqui N. Accuracy of conventional digital palpation and ultrasound of the cricothyroid membrane in obese women in labour. *Anaesthesia* 2015; 70: 1230-4.
14. Kristensen MS, Teoh WH, Rudolph SS, Tvede MF, Hesselfeldt R, Borglum J, Lohse T, Hansen LN. Structured approach to ultrasound-guided identification of the cricothyroid membrane: a randomized comparison with the palpation method in the morbidly obese. *British journal of anaesthesia* 2015; 114: 1003-4.
15. Siddiqui N, Arzola C, Friedman Z, Guerina L, You-Ten KE. Ultrasound Improves Cricothyrotomy Success in Cadavers with Poorly Defined Neck Anatomy: A Randomized Control Trial. *Anesthesiology* 2015; 123: 1033-41.

Funding was received from the Scottish Airway Group

**Table 1. Consistency of the identification of the cricothyroid membrane (CTM) *before* and *after* the patient moved and was subsequently returned to the extended neck position**

Subject #	Age	BMI	Method 1			Method 2
			CTM to suprasternal notch <i>before</i> movement, mm	CTM to suprasternal notch <i>after</i> movement and repositioning mm	Difference mm	Marking within CTM boundaries on the repeat assessment? Yes/No
1	65	31.8	62	62	0	Yes
2	74	27.0	65	65	0	Yes
3	80	23.8	62	62	0	Yes
4	67	26.2	55	55	0	Yes
5	53	22.5	105	104	1	Yes
6	81	24.2	69	69	0	Yes
7	64	20.1	89	89	0	Yes
8	74	23.1	77	78	1	Yes
9	66	23.3	77	79	2	Yes
10	77	31.8	59	59	0	Yes
11	64	27.6	68	67	1	Yes
Median	67	24.2	68	67	0	
Range (min-max)	(53-81)	(20.1-31.8)	(55-105)	(55-104)	(0-2)	

CTM = Cricothyroid membrane, BMI = Body mass Index, kg/m<sup>2</sup>



aas\_13680\_f1.png