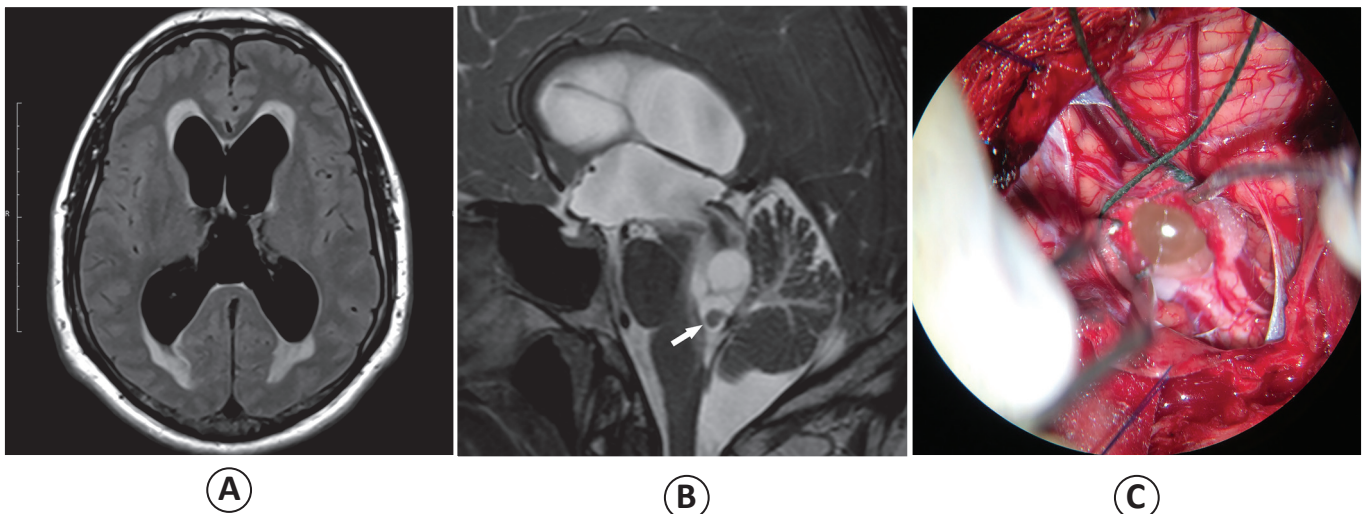


## Cysticerci located in the fourth ventricle causing obstructive hydrocephalus: a radiological emergency requiring prompt diagnosis

Lucas Giansante Abud<sup>[1],[2],[3]</sup>, Tanaka Koji<sup>[4]</sup> and Thiago Giansante Abud<sup>[1],[3],[5]</sup>

[1]. Divisão de Neurorradiologia, Documenta - Hospital São Francisco, Ribeirão Preto, São Paulo, Brasil. [2]. Divisão de Neurorradiologia, Hospital das Clínicas, Faculdade de Medicina de Ribeirão Preto - Universidade de São Paulo, Ribeirão Preto, São Paulo, Brasil. [3]. Divisão de Neurorradiologia, MED - Hospital São Lucas, Ribeirão Preto, São Paulo, Brasil. [4]. Divisão de Neurocirurgia, Hospital Santa Casa, Ribeirão Preto, São Paulo, Brasil. [5]. Divisão de Radiologia, Universidade Federal de São Paulo, São Paulo, São Paulo, Brasil.



An adult man was admitted to our institution complaining of headache and visual loss, which are symptoms of increased intracranial pressure. Axial fluid-attenuated inversion recovery (FLAIR)-weighted magnetic resonance imaging (MRI) showed supratentorial dilatation of the ventricular system accompanied by a halo of hyperintensity surrounding the lateral ventricles, indicative of transependymal edema and characterizing hypertensive hydrocephalus (**Figure A**). Sagittal three-dimensional T2-weighted MRI revealed conglomerate cystic lesions in the fourth ventricle blocking the cerebral spinal fluid flow (**Figure B**). This volumetric sequence also demonstrated a cyst with a mural nodule highly suggestive of scolex within a cysticercus (white arrow), notably in an endemic region. During surgery, it was possible to identify a cystic lesion outcropping from the fourth ventricle (**Figure C**). Anatomopathological examination confirmed the diagnostic hypothesis of neurocysticercosis (NCC).

Cysticercosis is a parasitic infection caused by the larval stage of *Taenia solium* and can involve any tissue in the body<sup>(1)</sup>. NCC refers to central nervous system involvement and develops when cysticerci migrate to the brain parenchyma, ventricles, and subarachnoid space. The intraventricular form of NCC is the less prevalent form and occurs preferentially in the fourth ventricle, which frequently leads to acute obstructive hydrocephalus, intracranial hypertension, and consequent sudden death<sup>(2)</sup>. It is essential to include three-dimensional sequences in the MRI protocol to investigate intraventricular NCC because the cystic lesions and scolex within can be accurately detected<sup>(3)</sup>. In this dangerous form of NCC, the presumptive diagnosis should be suggested using MRI findings, and the patient should be treated promptly to avoid neurological sequelae.

### REFERENCES

1. Del Brutto OH, Garcia HH. Neurocysticercosis. *Handb Clin Neurol* 2013; 114:313-325.
2. Kimura-Hayama ET, Higuera JA, Corona-Cedillo R, Chávez-Macías L, Perochena A, Quiroz-Rojas LY, et al. Neurocysticercosis: radiologic-pathologic correlation. *Radiographics* 2010; 30:1705-1719.
3. Mont'Alverne Filho FE, Machado LR, Lucato LT, Leite CC. The role of 3D volumetric MR sequences in diagnosing intraventricular neurocysticercosis: preliminar results. *Arq Neuropsiquiat* 2011; 69:74-78.

Corresponding author: Dr. Lucas Giansante Abud.

e-mail: [abud.lucas@gmail.com](mailto:abud.lucas@gmail.com)

Received 11 September 2015

Accepted 15 October 2015