

## Antidiarrheal pill in the airway

Viswesvaran Balasubramanian<sup>1</sup>, Hari Kishan Gonuguntla<sup>2</sup>, Nitesh Gupta<sup>3</sup>

<sup>1</sup>Department of Pulmonary Medicine, Yashoda Hospitals, Malakpet, Hyderabad, India

<sup>2</sup>Division of Interventional Pulmonology, Yashoda Hospitals, Secunderabad, Hyderabad, India

<sup>3</sup>Department of Pulmonary, Critical Care & Sleep Medicine, VMMC & Safdarjung Hospital, New Delhi, India

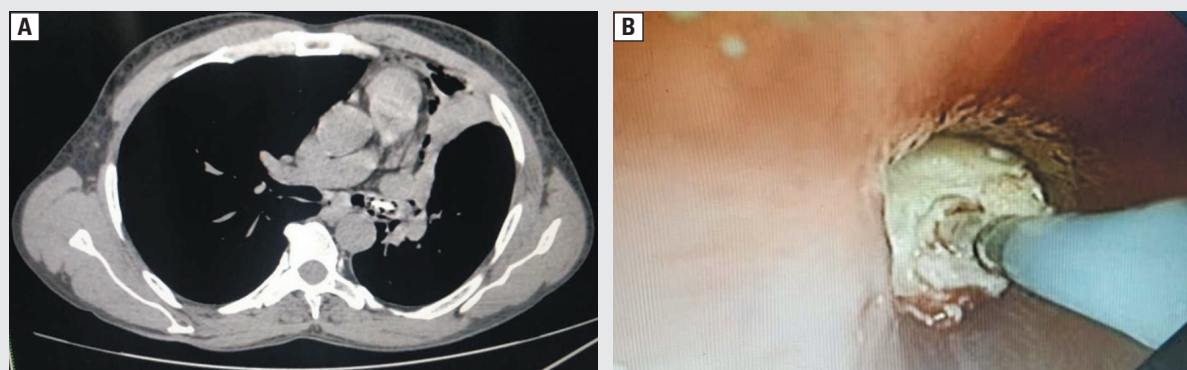
Pill aspiration depicts an unusual type of foreign body aspiration necessitating a discrete diagnostic and therapeutic approach [1]. Some pills may remain intact in the endobronchial tree for many years without causing much harm, whereas others may dissolve [2]. The clinical outcomes vary from an asymptomatic granuloma to severe, life-threatening airway complications, depending upon the chemical properties of the pill. We report a compelling case of pill aspiration in a healthy patient.

A 50-year-old gentleman, non-smoker, presented with respiratory distress after episodes of paroxysmal cough for one day. On clinical examination, palpable crepitus was present in the neck. The chest radiograph revealed a left upper lobe collapse, prompting further assessment. The patient denied history of chest pain, vomiting, weight lifting, rapid ascent, or descent of altitude. Computed tomography (CT) revealed radiopaque foreign body at the bifurcation in the left main bronchus. Also, there were present pneumomediastinum, small apical pneumothorax, and subcutaneous emphysema (Figure 1A). Subsequently, on repeated enquiry, the patient reported paroxysmal coughing episodes while consuming his tablet loperamide.

Endobronchial assessment with flexible bronchoscope through a rigid bronchoscope identified a white powdery foreign body emerging from granulation tissue at the distal opening of the left upper lobe bronchus. Single application of the cryoprobe was unsuccessful in extracting the pill enbloc, so multiple cryoprobe applications were done to remove the disintegrated pill particles (Figure 1B). At the end of the procedure, approximately the 80% patency of the airway was restored. Follow-up bronchoscopy, done 3 weeks later revealed complete patency of the airways without residual scar. On subsequent follow-up, the man remained asymptomatic.

Aspiration of a foreign body into the airways is a potentially fatal situation posing a diagnostic challenge. The symptoms range from asymptomatic to non-resolving pneumonia and respiratory distress of variable degrees, depending on the location of FB. Subcutaneous emphysema is among least common presentations of foreign body bronchus.

The development of subcutaneous emphysema is attributed to a ball-valve mechanism. Alveolar or airway breach allows the escape of air into the perivascular tissue around the pulmonary arteries which communicate with the mediastinum from which air may ascend into the neck and chest wall [3].



**Figure 1.** A. CT thorax confirms left upper lobe collapse due to radiopaque foreign body (arrow); B. Flexible bronchoscopy revealed an airway obstruction in the proximal left upper lobe bronchus. The entire granulation tissue along with the tablet was removed with a cryoprobe

**Address for correspondence:** Nitesh Gupta, Department of Pulmonary, Critical Care & Sleep Medicine, VMMC & Safdarjung Hospital, New Delhi, India;

e-mail: [niteshgupta2107@gmail.com](mailto:niteshgupta2107@gmail.com)

DOI: 10.5603/ARM.2020.0114

Received: 09.01.2020

Copyright © 2020 PTChP

ISSN 2451-4934

**Conflict of interest:** None declared

The diagnosis of FB aspiration requires a detailed history of aspiration and clinical symptoms and signs. The radiographic evaluation reveals either radiopaque FB or indirect signs such as lobar collapse, segmental atelectasis, or innocuous infiltrates [4]. The location of FB is more common on the right side than the left one. The direct visualization of the foreign body by a bronchoscope confirms the diagnosis. The features of tissue reactions to FBs include granulation tissue formation, endobronchial stenosis, strictures, edema, and airway distortion.

The availability of flexible catheters allows the use of cryotherapy through flexible bronchoscopes. The cryotherapy probe is traditionally used for the treatment of endobronchial lesions and parenchymal biopsy. It is also an excellent instrument that can be used to remove foreign airway bodies. The mechanism facilitating the use of cryotherapy probes to remove foreign bodies requires a certain amount of water content in the FB, suggesting that most organic material is appropriate for this approach. Fruchter *et al.*, in an *ex vivo* study involving retrieval of 18 commonly aspirated objects using cryoprobes, demonstrated successful retrieval of inorganic objects (including pill) with low water content [5]. In the present case, a flexible cryoprobe used the slippery properties of the granulation tissue on the foreign body by freezing it onto the probe's tip. To further facilitate removal, one may consider spraying saline over the object and immediate freezing of the foreign body, which then contains water to allow for successful cryoextraction as performed in the current case.

### References:

1. Kinsey CM, Folch E, Majid A, *et al.* Evaluation and management of pill aspiration: case discussion and review of the literature. *Chest*. 2013; 143(6): 1791–1795, doi: [10.1378/chest.12-1571](https://doi.org/10.1378/chest.12-1571), indexed in Pubmed: [23732590](https://pubmed.ncbi.nlm.nih.gov/23732590/).
2. Kupeli E, Khemasuwan D, Tunsupon P, *et al.* “Pills” and the air passages: a continuum. *Chest*. 2015; 147(1): 242–250, doi: [10.1378/chest.14-0531](https://doi.org/10.1378/chest.14-0531), indexed in Pubmed: [25560862](https://pubmed.ncbi.nlm.nih.gov/25560862/).
3. Findlay CA, Morrissey S, Paton JY. Subcutaneous emphysema secondary to foreign-body aspiration. *Pediatr Pulmonol*. 2003; 36(1): 81–82, doi: [10.1002/ppul.10295](https://doi.org/10.1002/ppul.10295), indexed in Pubmed: [12772230](https://pubmed.ncbi.nlm.nih.gov/12772230/).
4. Kupeli E, Khemasuwan D, Tunsupon P, *et al.* “Pills” and the air passages. *Chest*. 2013; 144(2): 651–660, doi: [10.1378/chest.13-0080](https://doi.org/10.1378/chest.13-0080), indexed in Pubmed: [23918109](https://pubmed.ncbi.nlm.nih.gov/23918109/).
5. Fruchter O, Kramer MR. Retrieval of various aspirated foreign bodies by flexible cryoprobe: in vitro feasibility study. *Clin Respir J*. 2015; 9(2): 176–179, doi: [10.1111/crj.12120](https://doi.org/10.1111/crj.12120), indexed in Pubmed: [24521482](https://pubmed.ncbi.nlm.nih.gov/24521482/).