

This is a provisional PDF only. Copyedited and fully formatted version will be made available soon.



ISSN: 0015-5659

e-ISSN: 1644-3284

Effect of genistein and estradiol on the adrenal cortex of the ovariectomized adult female albino rats

Authors: H. D. Yassa, N. M. Safwat, R. M. Ahmed, M. Z. Fathy, H. L. Metry

DOI: 10.5603/FM.a2020.0056

Article type: ORIGINAL ARTICLES

Submitted: 2020-04-03

Accepted: 2020-05-03

Published online: 2020-05-25

This article has been peer reviewed and published immediately upon acceptance. It is an open access article, which means that it can be downloaded, printed, and distributed freely, provided the work is properly cited.

Articles in "Folia Morphologica" are listed in PubMed.

Effect of genistein and estradiol on the adrenal cortex of the ovariectomized adult female albino rats

H.D. Yassa¹, N.M. Safwat², R.M. Ahmed¹, M.Z. Fathy³, H.L. Metry⁴

¹Department of Anatomy and Embryology, Faculty of Medicine, Beni-Suef University, Beni-Suef, Egypt

²Department of Pathology, Faculty of Veterinary Medicine, Beni-Suef University, Beni-Suef, Egypt

³Department of Surgery, Faculty of Veterinary Medicine, Beni-Suef University, Beni-Suef, Egypt

⁴Department of Anatomy and Embryology, Faculty of Medicine, Cairo University, Cairo, Egypt

Address for correspondence: R.M. Ahmed, Department of Anatomy and Embryology, Faculty of Medicine, Beni-Suef University, Beni-Suef, Egypt, tel: 002-01226655590, e-mail: rowayda_g@yahoo.com

Abstract

Genistein, a naturally occurring soy isoflavone, attracts interest as an effective and safe alternative to hormone replacement therapy for menopausal problems. The aim of the current study was to compare between the effect of genistein and estradiol on the adrenal cortex of the ovariectomized adult female albino rats. Twenty rats were used in the current study and divided into 4 groups, five rats in each group; group 1 (control nonovariectomized), group 2 (ovariectomized), group 3 (ovariectomized + genistein) and group 4 (ovariectomized+ estradiol). The rats were sacrificed after 4 weeks. Both adrenal glands were removed for light microscope using Hx & E. stain, ultrastructural study and immunohistochemical examination using PCNA, caspase-3, and ER- β . Ovariectomized rats showed signs of degeneration in all zones of adrenal cortex. On the other hand, Treatment with genistein showed restoration of the adrenal cortex with less proliferative

effect than estradiol. So, genistein can be used as effective therapy to decrease the symptoms of menopause without fear of cancer development.

Key words: adrenal, menopause, genistein, estradiol, rat

INTRODUCTION

The adrenal glands are paired organs lying near the superior poles of both kidneys. They are embedded in the perirenal adipose tissue and their weight and size vary with the age and physiological conditions [20]. Each gland has two distinct components: a yellowish peripheral cortex (80% to 90% of the gland) and a reddish brown central medulla [6, 32]. The adrenal cortex is uniquely formed of three major layers organized into concentric zones. The cells of the different zones are generally distinguished by their characteristic cellular arrangement, their ultrastructure as well as their position within the gland. The three zones of the adrenal cortex are the outermost zona glomerulosa, the middle zona fasciculata and the innermost zona reticularis. These zones are named according to the arrangement of their secretory cells. In human, the limits of these cortical zones are usually not sharply defined [9]. The adrenal Cortical hormones play vital roles in different physiological processes, including: fluid and electrolyte balance, cardiovascular homeostasis, carbohydrate, lipid and protein metabolism, immune and inflammatory reactions, reproductive function and sexual development [11].

Menopause is the period in a woman's life when hormonal alterations cause menstruation to stop permanently and may be followed by psychological and physical symptoms. This is due to ovarian failure and estrogen deficiency which will influence the quality of life. Thus, although menopause appears to be a natural process, it is a period that must be followed and treated. The menopause experiences vary greatly from one female to another [22]. Menopause can occur spontaneously on average around 51 years of age or may be induced by medical intervention (surgery, pelvic radiation therapy or chemotherapy) [19]. It has been reported that bilateral ovariectomy can result in a decrease in the adrenal cortical activity, and estradiol is used for treatment of this condition [25]. Gaete *et al.*, (2012) [10] reported that hormonal therapy with estrogen was related to the induction of proliferation in the uterus and mammary gland cells, increasing the hazard of cancer

development. To prevent these adverse effects, isoflavones are being investigated as alternatives to hormone replacement therapy for menopausal women [7].

Isoflavones are a type of isoflavonoids, which act as phytoestrogens in mammals.

Genistein, a phytoestrogen that belongs to isoflavones, is structurally similar to 17 β -estradiol, and selective estrogen receptor modulator (SERMs). On that account, there has been intense interest in the isoflavones as substitutes for estrogen for postmenopausal women and as preventive therapy for premenopausal women [7].

MATERIAL AND METHODS

Animals and experimental protocols

Twenty adult female albino rats (Sprague-Dawley) weighing 180–200 g were used in the present work. Rats were provided by Faculty of Veterinary Medicine, Beni-Suef University Animal House and bred in specific pathogen free condition. Rats were housed and maintained in an air-conditioned animal house under standard laboratory and environmental conditions, and were subjected to a 12:12 hours daylight/darkness and allowed free access to food and water. Before carrying out the drug administration, rats were acclimatized in the laboratory for two weeks. All the ethical protocols and guidelines for animal handling and treatment were followed and supervised by the animal facilities, Faculty of Veterinary Medicine, Beni-Suef University in compliance with the national standards published in the Guide for the Care and Use of Laboratory Animals.

Rats were divided into four groups; five rats each. (1) The Control group received standard diet only; (2) The Ovariectomized group (OVX), rats were subjected to ovariectomy operation; (3) ovariectomized and treated with genistein group (OVX+ Genistein); (4) ovariectomized and treated with estradiol group (OVX+ Estradiol).

Ovariectomy operation

Rats were anaesthetized with intraperitoneal injection of ketamine (15 mg/kg body weight). The lower abdomen of the rats was shaved and incised to identify the Fallopian tubes and ovaries. The Fallopian tubes below the ovaries were tied using absorbable vicryl sutures. Then, the ovaries were removed [26].

Drugs

1-Genistein: was obtained from Sigma Chemical Company (St. Louis, Missouri, USA). Each 100 mg of genistein was dissolved in 10 ml distilled water (10 mg/ml) and given orally by gastric tube. The dose was adjusted on the basis of a previous work [31].

2-Estradiol: Cyclo-progynova (Estradiol valerate 2mg, Bayer Weimar Pharma, AG, Germany), 1mg/ kg/ day, orally [29].

Drugs were daily ingested by gastric intubation and by the end of application; the gavage tube was left for seconds to avoid regurgitation and to assure supplying the calculated dose completely. All the medications were supplied at a fixed time for the whole period of the experiment.

By the end of the experimental period after 4 weeks, rats were sacrificed by CO₂ narcosis. Both adrenal glands of each rat were collected and used for the following methods. One was used for Hx&E. stain and immunohistochemistry study. The other gland was fixed in glutaraldehyde solution for electron microscopic examination.

A) Hematoxylin and Eosin (Hx & E) [8]: specimens were fixed in 10 % neutral buffered formaline for 48hours and were processed to prepare 5 µm thick paraffin sections.

B) Immunohistochemical stains using:

- Proliferating cell nuclear antigen (PCNA) [24]: using PCNA antibody (Clone PC-10). It is a Mouse anti- Rat Monoclonal Antibody (Santa Cruz Biotechnology, catalogue number sc-56). It was supplied as (7.0 ml) of antibody (200 ug/ml) prediluted 1:2000 using PBS based antibody diluent, PH: 7.4 to reduce background and unspecific staining. It was stored at 2-8°C. No special pretreatment was required for immunohistochemical staining of formalin-fixed tissues

- Caspase-3 [2]: using Caspase-3 (CPP 32) Ab-4. It is a rabbit polyclonal antibody (Lab Vision Corporation Laboratories, USA, RB-1197-R7). It was supplied as prediluted ready-to-use antibody for staining formalin fixed paraffin-embedded tissues. It was stored at 2-8°C.

- Estrogen Receptors (ER-β) [3]: It is a rabbit polyclonal antibody; [catalogue number RB-10658-R7 (Ready to use for immunohistochemical staining)]. This antibody labels estrogen which is detected in human thymus, spleen, ovary and testis and in rat ovary and prostate. It reacts in human and rat and is characterized by nuclear cellular localization. It was supplied as antibody fraction purified from rabbit anti-serum. Prepared as prediluted antibody which is ready to use for staining of formalin-fixed and paraffin embedded

tissues. It's stored at 4°C. When stored at 2-8°C, this antibody is stable for 24 months.

Staining of formalin-fixed tissues requires boiling tissue sections in 10mM citrate buffer, pH 6.0 for 10-20 min followed by cooling at room temperature for 20 min.

C) Electron microscopy [4]: After dissecting the rats, Five–ten small pieces 1X1 mm in size were taken from each specimen and then fixed in 5% cold glutaraldehyd for 24-48 hours. Then, the specimens were washed in cacodylate buffer (PH 7.2) 3-4 times for twenty minutes every time and post fixed in 1% O4 s4 for two hours. After that, specimens were washed in the same buffer four times. Ascending grades of alcohol (30- 50- 70- 90 and 100%) were used dehydrate the sections (2 hours each) and then they were embedded in epon-araldite mixture according to the protocol of E.M. unit Assiut University. Semi thin sections by LKB ultramicrotom in thickness of 0.5–1 micron were prepared from the embedded blocks for orientation of the tissue and photographed by sc30 Olympus camera. Ultrathin section in thickness of 500- 700 A were made using leica AG ultramicrotome and contrasted in uranyl acetate and lead citrate, as usual. Examination was performed by JEM 100 CXII electron microscope at 80 KV and photographed by CCD digital camera Model XR- 41.

D) Morphometric study: measurements of the width of the 3 cortical zones in all groups were performed using image J program at Faculty of Medicine, Beni-Suef University.

E) Statistical analysis: Analysis of variance (ANOVA) was used to compare between the different groups in morphometric results and followed by post hoc Tukey test. The results were expressed as means \pm SD. The differences were considered statistically significant when p-value was <0.05 .

RESULTS

Light microscopy with Hx & E stain

The control group showed the normal histological architecture. The adrenal cortex is covered with thin capsule and an outer layer of adipose connective tissue. It consists of three main zones; the first, zona glomerulosa (ZG) is a narrow zone just under the capsule formed of columnar cells with vacuolated cytoplasm and rounded vesicular nuclei. The cells are arranged in arched groups (Fig. 1A). The second, zona fasciculata (ZF) is the widest zone formed of polyhedral cells having clear cell membranes, vacuolated cytoplasm with lipid droplets and large rounded nuclei. The cells are arranged in narrow straight cords (fascicles) separated by straight capillaries (Fig. 2A). The last one, zona reticularis is

the deepest zone and is formed of polyhedral cells in branching and anastomosing cords separated by blood sinusoids (Fig. 3A).

In the OVX group, most of the cells in ZG are comparable to control with vesicular nuclei and vacuolated cytoplasm. Few cells have hypochromatic or ghost nuclei (Fig. 1B). The nuclei of the affected cells in both ZF and ZR showed different degrees of pathologic lesions, pyknotic with shrunk and darkly stained nuclei, hypochromatic or had ghost figures. The blood capillaries and sinusoids in between the cortical cells were dilated (Fig. 2B, 3B).

In the OVX+ Genistein group, a marked amelioration of the degenerative effects were seen in the majority of rats in the 3 zones with only few degenerated cells having hypochromatic nuclei and few congested blood capillaries were detected (Fig. 1C, 2C, 3C).

In the OVX+ Estradiol group, there was generalized hyperplasia. The cells were pleomorphic with high mitotic activity. Numerous cells were binucleated and others had pyknotic or ghost nuclei. The blood sinusoids in between the cortical cells were dilated and congested (Fig. 1D, 2D, 3D).

Immunohistochemical staining with PCNA

PCNA stained sections of group 1 (Control) and group 2 (OVX) revealed negative immunoreaction (Fig. 4A, B). While, group 3 (OVX + Genistein) revealed positive immunoreaction (Fig. 4C). Group 4 (OVX + Estradiol) revealed strong positive immunoreaction (Fig. 4D).

Immunohistochemical staining with Caspase-3

Caspase-3 stained sections of group 1 (Control), group 3 (OVX + Genistein) and Group 4 (OVX + Estradiol) revealed negative immunoreaction (Fig. 5A, C, D). While, group 2 (OVX) revealed positive immunoreaction (Fig. 5B).

Immunohistochemical staining with ER- β

ER- β stained sections of group 1 (Control), group 3 (OVX + Genistein) and Group 4 (OVX + Estradiol) revealed positive immunoreaction (Fig. 6A, C, D). While, group 2 (OVX) revealed negative immunoreaction (Fig. 6B).

Ultrastructural study of the adrenal cortex

In the control group, ZG cells had rounded or oval nuclei with finely dispersed euchromatin and the nuclear envelope and nuclear pores were easily discerned. The cytoplasm had variable sized numerous lipid globules, Medium-sized, rounded or oval mitochondria (Fig. 7A). The fasciculata cells appeared with rounded or oval euchromatic nuclei with clear nuclear envelope rounded mitochondria and variable amount of lipid globules (Fig. 8A). Cells of zona reticularis had vesicular nucleus and abundant cytoplasm which contains few lipid globules and mitochondria (Fig. 9A).

In the OVX group, the adrenal cortical cells showed signs of degeneration. The ZG cells contained vesicular nucleus and the cytoplasm showed few lipid globules which vary in size and electron density. The cytoplasm of the cells also revealed numerous vacuoles and small electron dense lysosomes (Fig. 7B). The ZF cells showed irregular nucleus with thick and irregular nuclear envelope and indistinguishable pores and the cytoplasm contained numerous vacuoles (Fig. 8B). The ZR cells showed irregular nucleus with thick and irregular nuclear envelope and indistinguishable pores and the cytoplasm contained vacuoles and lipofuscin granules (Fig. 9B).

The OVX+ Genistein group almost regained the normal ultrastructure of cells. The ZG cells showed large amount of electron dense lipid globules, mitochondria, less vacuoles and the nucleus showed normal and regular nuclear membrane, well discerned nuclear pores and finely dispersed euchromatin. Few nuclei became small and condensed (Fig. 7C). The ZF cells showed rounded or oval euchromatic nucleus and the cytoplasm contained variable amount of lipid globules, mitochondria and few lysosomes (Fig. 8C). The cells of ZR appeared of normal structure containing euchromatic nucleus and few lipid globules. Apoptotic cell was seen with loss of its architecture. Some cells showed condensation of the nucleus chromatin (Fig. 9C).

In the OVX+ Estradiol group, the cells forming the ZG had condensed nuclei and the cytoplasm contained large amount of vacuoles with dispersion of the cell organelles (Fig. 7D). The ZF cells had large amount of vacuoles communicating with each other and their nuclei were condensed (Fig. 8D). The zona reticularis cells showed dispersion of the cytoplasmic organelles. The nuclei of the cells were small and electron dense. Also, electron dense apoptotic cells were seen compressed between the cells (Fig. 9D).

Morphometric results

The ZG thickness was significantly decreased after ovariectomy operation ($p < 0.05$) and became comparable to control after treatment with both genistein and estradiol (Table 1). The thicknesses of ZF (Table 2) as well as ZR (Table 3) were significantly decreased after ovariectomy operation and they were comparable to control after treatment with genistein. In contrast, estradiol treatment significantly increased ZF and ZR thicknesses compared to group (1, 2 and 3).

DISCUSSION

In the present study, we examined the effect of ovariectomy on the adult rat adrenal cortex. Additionally, the therapeutic effects of genistein and estradiol on the adrenal cortex of ovariectomized adult female albino rats were compared. In this experimental study, adult female albino rats aged 3 months old were chosen to be in the reproductive period of life. According to Suckow et al., 2005 [27], female rats reach sexual maturity at 2 months of age, their reproductive system is fully functioning and their maximum fertility is reached between 3-10 months of age.

In the present study, specimens taken from rats subjected to ovariectomy operation and stained with Hx & E showed signs of degeneration in the form of irregular zona fasciculata cells and degenerated cortical cells in the form of pyknotic, hypochromatic and ghost nuclei. These findings were in agreement with the findings of Saruhan & Ozdemir, 2005 [25]. The dilated blood capillaries and sinusoids were also detected. These findings usually accompany the vacuolated cells as reported by Laast et al, 2014 [16].

Marked improvement was noticed after treatment with genistein in the degeneration of the cortical cells as they were comparable to control with only few degenerated cells having pyknotic nuclei. On the other hand, treatment with estradiol showed trophic changes in the form of marked increase in the thickness of the cortical adrenal gland layers with proliferation of the cells compared to ovariectomized rats and rats treated with genistein. This was in agreement with previous findings in the uterus [5, 17]. Saruhan & Ozdemir, 2005 [25] determined that ovariectomy resulted in a decrease in the activity of the adrenal cortex. In contrast, they found that estrogen supplementation caused a significant increase in the activity of the adrenal cortex and medulla. LO et al, 2000 [18] indicated that estrogens may enhance corticosterone feedback by stimulating corticosterone production at the adrenal gland or by reducing corticosterone metabolism.

In the current study, immunohistochemistry using PCNA revealed moderate proliferation in group (3), while group (4) showed marked +ve immunoreaction. These findings were in agreement with D. S. Marinho et al, 2017 [7] who used VEGF and ki67 gene expression in the adrenal tissue as proliferative markers and stated that estrogen induced an increase in the expression of both the VEGF and the Ki67 in rat adrenal glands. On the other hand, the results of the current study showed that treatment with genistein was less effective than with 17βestradiol. They emphasized that genistein has an antagonistic effect, thus supporting the decreased gene expression of VEGF and Ki67 and of proliferation-related genes. VEGF is an important regulated angiogenic molecule and is considered a prognostic factor for various tumors. Thus, these results indicate that genistein may cause less stimulation of VEGF expression than does estrogen. In fact, some authors have shown that isoflavone may have a weaker effect on tumor induction compared to estrogen [13, 14, 21]. In the present study, there was a significant decrease in the thickness of the three adrenal cortical zones in group (2) compared to the control group. These changes may be explained by decreased adrenal cortical activity as reported by Saruhan & Ozdemir, 2005 [25]. In contrast, non-significant changes were observed in group (4) compared to the control group. This could be explained by the improvement noticed in the adrenal cortical cells after treatment with genistein. Moreover, treatment with estradiol caused significant increase in the thickness of the adrenal cortical zones compared to group (1, 2 and 3). These findings were going well with the results obtained by D. S. Marinho et al, 2017 [7] who reported that treatment with soy isoflavone extract induces fewer changes in the thickness of all zones of the adrenal cortex than treatment with estrogen compared to ovariectomized rats.

In the current work, immunohistochemistry using caspase-3 revealed that +ve reaction appeared only with the group (2) but were -ve in group (3) and (4). D. S. Marinho et al, 2017 [7] analyzed the expression of caspase-3 gene in order to verify the protective potential of isoflavones. Animals treated with isoflavones showed an expression of caspase-3 more than the group treated with estradiol. This may be related to the proliferative potential of estradiol, which to some extent can prevent cell death by apoptosis.

Data from many experiments indicate that gonadal hormones have a direct effect on the physiology of the adrenal tissue. ER expression had been demonstrated in the adrenal

glands of several species such as rodents [15] and monkeys [12]. In the present study, group (1) exhibited +ve ER- β immuno-staining. On the other hand, group (2) showed down-regulation of ER- β expression, with -ve ER- β immuno-reactivity. After treatment with genistein and estradiol, many cells exhibited strong +ve ER- β immuno-reactivity. Such down regulation of ER- β in group (2) probably explains the degenerative changes induced in the cortical cells. Then, the up-regulation of ER- β in the groups treated with genistein and estradiol clearly indicates that ER- β expressed by the adrenal cortical cells mediate estrogen- induced cell proliferation in these cells. These findings postulate that ER- β isoform plays an essential role in modifying the effect of estrogen and thus, further improvement of the adrenal cortex. This was matching with Teng et al, 2008 [28] who suggested that ER- β isoform plays an important role in modulating the urinary bladder urothelial proliferation.

In the reviewed literature there were no electron microscopic studies observing the ultrastructure of the adrenal cortex in OVX rats and their treatment with either genistein or estradiol.

Comparable to L.M. examination, the E.M. examination of the adrenal cortex of group (2) showed marked signs of degeneration. The lipofuscin pigments were the most obvious finding in ZR. These results were in agreement with the demonstration carried by Rebuffat et al, 1992 [23] and Almeida et al, 1998[1] who observed these findings in aged rats.

Lipofuscin pigments are common structures found in aged ZF and ZR cells and are frequently observed as a classic marker of ageing. Ward and Reznik- Schuller, 1980 [30] stated that lipofuscin pigments may have originated from degradation of lipid droplets of epithelial cells. Almeida et al, 1998[1] demonstrated that lipofuscin does not exert any noticeable damaging effect on cells but it is possible that, at a certain moment, this accumulation may interfere with cellular function.

The genistein treated group almost regained the normal ultrastructure. While, the estradiol treated group showed dispersion of the cytoplasmic organelles and apoptotic cells were detected. Similar data have not been reported in the reviewed literature.

CONCLUSIONS

It could be concluded that ovariectomy decreases the adrenal gland activity due to decreased estrogen levels in blood. On the other hand, administration of genistein

ameliorates the adrenal gland injury without producing trophic effect. Moreover, estradiol treatment induces an intense cell proliferation as proved histologically, immunohistochemically and ultrastructurally. So, genistein found naturally in soy may have less effect on cell proliferation and cancer risk than estradiol.

REFERENCES

1. Almeida A, Magalhaes MC, Magalhaes MM. Age-related changes in lipid peroxidation products in rat adrenal gland. *J. age* 1998; 21(3):119-121. DOI: [10.1007/s11357-998-0018-4](https://doi.org/10.1007/s11357-998-0018-4)
2. Bancroft JD, Gamble M. *Theory and practice of histological techniques*. 6th ed. Churchill Livingstone Elsevier. China 2008; 433-472.
3. Bancroft JD, Cook HC. Immunocytochemistry. In: *Manual of Histological Techniques and Diagnostic Applications*. 1st ed., Churchill Livingstone, Edinburgh, London, Madrid, Melbourne, New York and Tokyo 1994; pp.263-325.
4. Bozzola J, Russell L. *Electron microscopy principles and techniques for biologists*: Jones and Bartlitt publishers 20 park plaza Boston Mao 1991; 2116.
5. Budhathoki S, Iwasaki M, Sawada N, et al. Soy food and isoflavone intake and endometrial cancer risk: the Japan Public Health Centerbased prospective study. *BJOG* 2015; 122(3):304–311. DOI: [10.1111/1471-0528.12853](https://doi.org/10.1111/1471-0528.12853)
6. Chang SP, Mullins JJ, Morley SD, West JD. Transition from organogenesis to stem cell maintenance in the mouse adrenal cortex. *Organogenesis* 2011; 7(4): 267-80. DOI:[10.4161/org.7.4.18060](https://doi.org/10.4161/org.7.4.18060)
7. D S Marinho, M L Calio, M A Santos, G M Ko, C P Teixeira, A F Carbonel, et al. Evaluation of the isoflavones and estrogen effects on the rat adrenal. *Gynecol Endocrinol*, 2017; 33(10): 811–815. DOI:[10.1080/09513590.2017.1318371](https://doi.org/10.1080/09513590.2017.1318371)
8. Drury R, Wallington E. (1980): In Carleton's *Histological techniques* (fifth edition). Oxford 1980; 10: 183-185.
9. Eroschenko, V. P.: *DiFiore's atlas of histology with functional correlations*. Twelfth edition. Lippincott Williams and Wilkins, Philadelphia 2013; 402-407.
10. Gaete L, Tchernitchin AN, Bustamante R, et al. Daidzein-estrogen interaction in the rat uterus and its effect on human breast cancer cell growth. *J Med Food* 2012; 15(12):1081–90. DOI: [10.1089/jmf.2011.0322](https://doi.org/10.1089/jmf.2011.0322)
11. Hart, K.A. and Barton, M.H.: Adrenocortical insufficiency in horses and foals. *J. Vet. Clin. North. Am. Equine Pract* 2011; 27(1):19-34. DOI: [10.1016/j.cveq.2010.12.005](https://doi.org/10.1016/j.cveq.2010.12.005)
12. Hirst JJ, West NB, Brenner RM & Novy MJ. Steroid hormone receptors in the adrenal glands of fetal and adult rhesus monkeys. *Journal of Clinical Endocrinology and Metabolism* 1992; 75(1):308–314. DOI: [10.1210/jcem.75.1.1619023](https://doi.org/10.1210/jcem.75.1.1619023)
13. Hyder SM, Huang JC, Nawaz Z, et al. Regulation of vascular endothelial growth factor expression by estrogens and progestins. *Environ Health Perspect* 2000; 108:785–90. DOI: [10.1289/ehp.00108s5785](https://doi.org/10.1289/ehp.00108s5785)
14. Jarzabek K, Koda M, Walentowicz-Sadlecka M, et al. Altered expression of ERs, aromatase, and COX2 connected to estrogen action in type 1 endometrial cancer biology. *Tumour Biol* 2013; 34: 4007–16. DOI: [10.1007/s13277-013-0991-9](https://doi.org/10.1007/s13277-013-0991-9)
15. Kuiper GG, Carlsson B, Grandien K, Enmark E, Haggblad J, Nilsson S & Gustafsson JA. Comparison of the ligand binding specificity and transcript tissue distribution of estrogen receptors alpha and beta. *Endocrinology* 1997; 138: 863–870. DOI: [10.1210/endo.138.3.4979](https://doi.org/10.1210/endo.138.3.4979)
16. Laast, V.A.; Larsen, T.; Allison, N.; Hoenerhoff, M.J. and Boorman, G.A.: Distinguishing cystic degeneration from other aging lesions in the adrenal cortex of Sprague-Dawley rats. *Toxicologic Pathology* 2014; 42(5): 823-829. DOI: [10.1177/0192623313502258](https://doi.org/10.1177/0192623313502258)
17. Liu J, Yuan F, Gao J, et al. Oral isoflavone supplementation on endometrial thickness: a meta-analysis of randomized placebocontrolled trials. *Oncotarget* 2016; 7: 17369–79. DOI: [10.18632/oncotarget.7959](https://doi.org/10.18632/oncotarget.7959)

18. Lo MJ, Chang LL, Wang PS. Effects of estradiol on corticosterone secretion in ovariectomized rats. *J. Cell. Biochem* 2000; 77: 560-568. DOI: [10.1002/\(sici\)1097-4644\(20000615\)77:4<560::aid-jcb4>3.0.co;2-d](https://doi.org/10.1002/(sici)1097-4644(20000615)77:4<560::aid-jcb4>3.0.co;2-d)
19. Manson, J.E., and Bassuk, S.S.: The menopause transition and postmenopausal hormone therapy. In: Fauci AS, Braunwald E, Kasper DL, et al, eds. *Harrison's Principles of Internal Medicine*, 17th ed. New York: McGrawHill 2008; 2334-2339.
20. Mescher AL. *Adrenal Glands in: Junqueira's Basic Histology: Text and Atlas*. Thirteenth edition, Mcgraw-hill medical, New York 2013; 414-417.
21. Nagata C, Mizoue T, Tanaka K, et al. Soy intake and breast cancer risk: an evaluation based on a systematic review of epidemiologic evidence among the Japanese population. *Jpn J Clin Oncol* 2014; 44:282–95. DOI: [10.1093/jjco/hyt203](https://doi.org/10.1093/jjco/hyt203)
22. Parhizkar, S.; Abdul Latiff, L. and Parsa, A.: Effect of *Nigella sativa* on reproductive system in experimental menopause rat model. *Avicenna J Phytomed* 2016; 6 (1): 95-103.
23. Rebuffat P, Belloni AS, Rocco S, Andreis PG, Neri G, Malendowicz, LK, et al. The effects of aging on the morphology and function of the zonae fasciculata and reticularis of the rat adrenal cortex. *Cell and tissue research* 1992; vol 270(2) 265-272. DOI: [10.1007/bf00328012](https://doi.org/10.1007/bf00328012)
24. Sabry MM, Elkalawy SA, Abo-Elnour RK, Abd-El-Maksod DF. Histological and immunohistochemical study on the effect of stem cell therapy on bleomycin induced pulmonary fibrosis in albino rat. *International Journal of Stem Cells* 2014; 7 (1): 33–42. DOI: [10.15283/ijsc.2014.7.1.33](https://doi.org/10.15283/ijsc.2014.7.1.33)
25. Saruhan BG, Ozdemir N. Effect of ovariectomy and of estrogen treatment on the adrenal gland and body weight in rats. *Saudi Med J*. 2005; 26(11):1705-9. <https://www.researchgate.net/publication/7456623>
26. Seko K, Kagami H, Senga K, Ozeki K, Mizutani H, Ueda M. Effect of ovariectomy and estrogen replacement on rat oral mucosa. *Maturitas* 2005; 50(I): 44-51. DOI: [10.1016/j.maturitas.2004.03.015](https://doi.org/10.1016/j.maturitas.2004.03.015)
27. Suckow M, Weisbroth S, Franklin C. *The laboratory Rat*, Second Edition (American College of Laboratory Animal Medicine), Toronto: Academic Press 2005; P.540.
28. Teng J, Wang ZY, Jarrard DF, Bjorling DE. Roles of estrogen receptor alpha and beta in modulating urothelial cell proliferation. *Endocr. Relat. Cancer* 2008; 15 (1): 351-64. DOI: [10.1677/erc.1.01255](https://doi.org/10.1677/erc.1.01255)
29. Vinicius DCC, Vanessa ÁSS, Renata FP, Yasmin RC. Effect of estrogen therapy, soy isoflavones, and the combination therapy on the submandibular gland of ovariectomized rats. *Pathology-research and practice* 2011; 207: 300-305. DOI: [10.1016/j.prp.2011.01.002](https://doi.org/10.1016/j.prp.2011.01.002)
30. Ward JM, Reznik-Schuller. Morphology and Histochemical characteristics of pigments in aging F344 rats. *Vet. Pathol* 1980; 17: 678-685. DOI: [10.1177/030098588001700604](https://doi.org/10.1177/030098588001700604)
31. Yang W, Wang S, Li L, Liang Z, Wang L. Genistein reduces hyper glycemc and islet cell loss in a high-dosage manner in rats with alloxan-induced pancreatic damage. *Pancreas* 2011; 40(3): 396-402. DOI: [10.1097/MPA.0b013e318204e74d](https://doi.org/10.1097/MPA.0b013e318204e74d)
32. Young B, Woodford P, O'Dowd G. Adrenal Gland. In: *Wheater's functional histology: a text and colour atlas*. Sixth edition. Elsevier Health Sciences, Philadelphia 2013; 328-331.

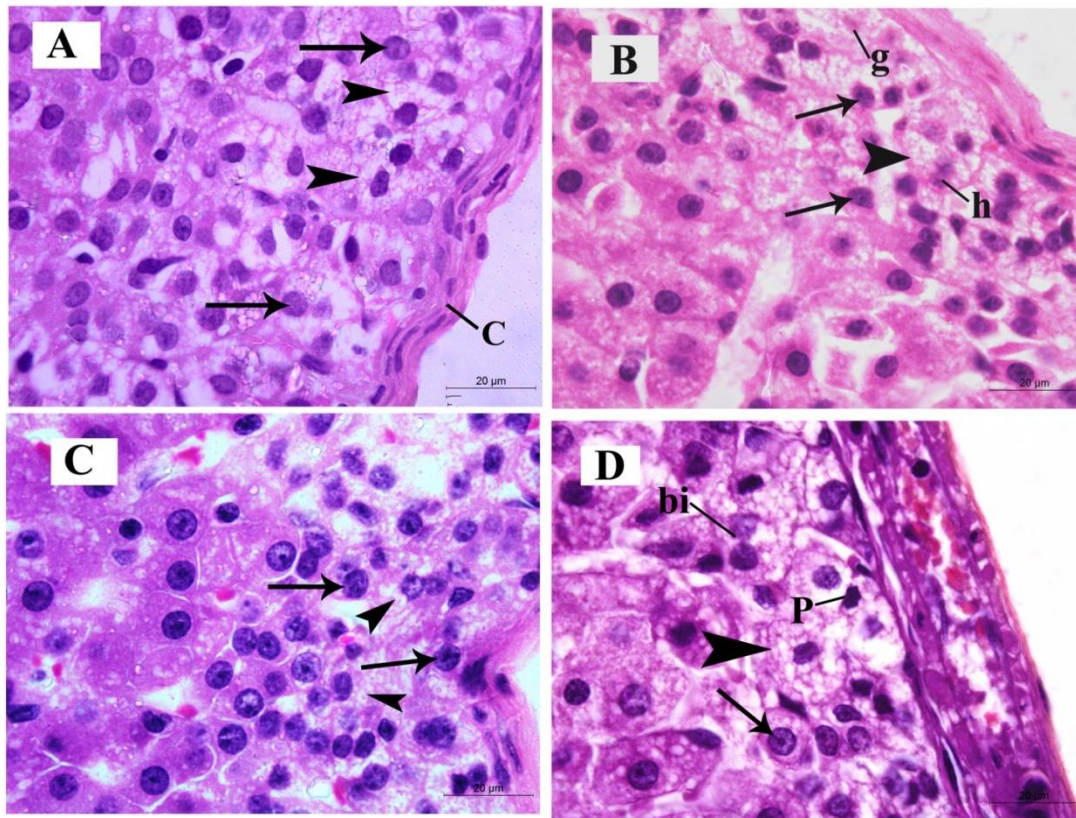


Figure 1. Hx & E. stained sections of ZG of different studied groups. **A**, control group; **B**, OVX group; **C**, OVX+ Genistein group and **D**, OVX+ Estradiol group. **A**, the zona glomerulosa is covered by capsule (C) and the cells are columnar with vesicular nuclei (**arrows**) and vacuolated cytoplasm (**arrow heads**). **B**, glomerulosa cells have vesicular nuclei (**arrows**) and vacuolated cytoplasm (**arrow head**) and some cells have hypochromatic (**h**) or ghost (**g**) nuclei. **C**, the cells became comparable to control with vesicular nuclei (**arrows**) and vacuolated cytoplasm (**arrow heads**). **D**, glomerulosa cells have vesicular nuclei (**arrow**) and vacuolated cytoplasm (**arrow head**) and some cells are pyknotic (**p**) and others are binucleated (**bi**). Scale bar = 20 µm

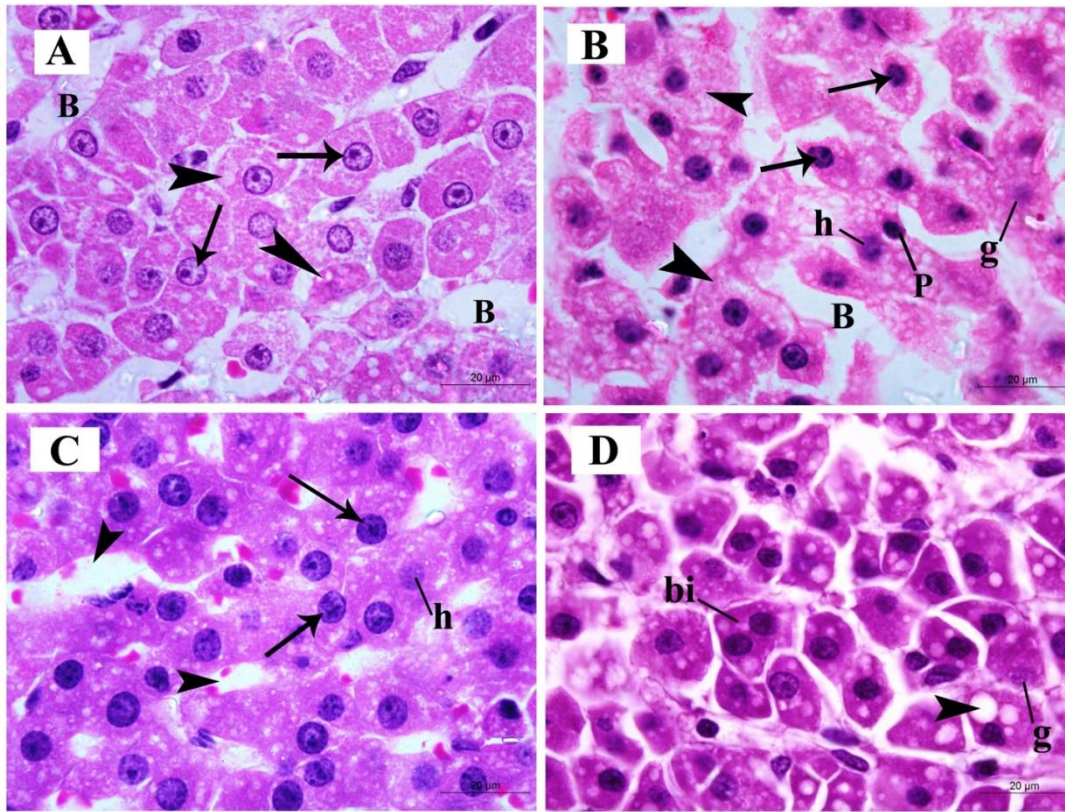


Figure 2. Hx & E. stained sections of ZF of different studied groups. **A**, control group; **B**, OVX group; **C**, OVX+ Genistein group and **D**, OVX+ Estradiol group. **A**, the cells in this zone are polyhedral with vesicular nuclei (**arrows**) and the cytoplasm has few vacuolations (**arrow heads**). The cells are separated by blood capillaries (**B**). **B**, the cells have vesicular nuclei (**arrows**) and vacuolated cytoplasm (**arrow heads**) and some cells have pyknotic (**p**), hypochromatic (**h**) or ghost (**g**) nuclei. Fasciculata cells are separated by dilated blood capillaries (**B**). **C**, fasciculata cells became comparable to control with vesicular nuclei (**arrows**) and few cells have hypochromatic nuclei (**h**). The blood capillaries between the cells are mildly congested (**arrow heads**). **D**, fasciculata cells are pleomorphic having vacuolated cytoplasm (**arrow head**). Some cells have ghost figures (**g**) and others are binucleated (**bi**). Scale bar = 20 µm

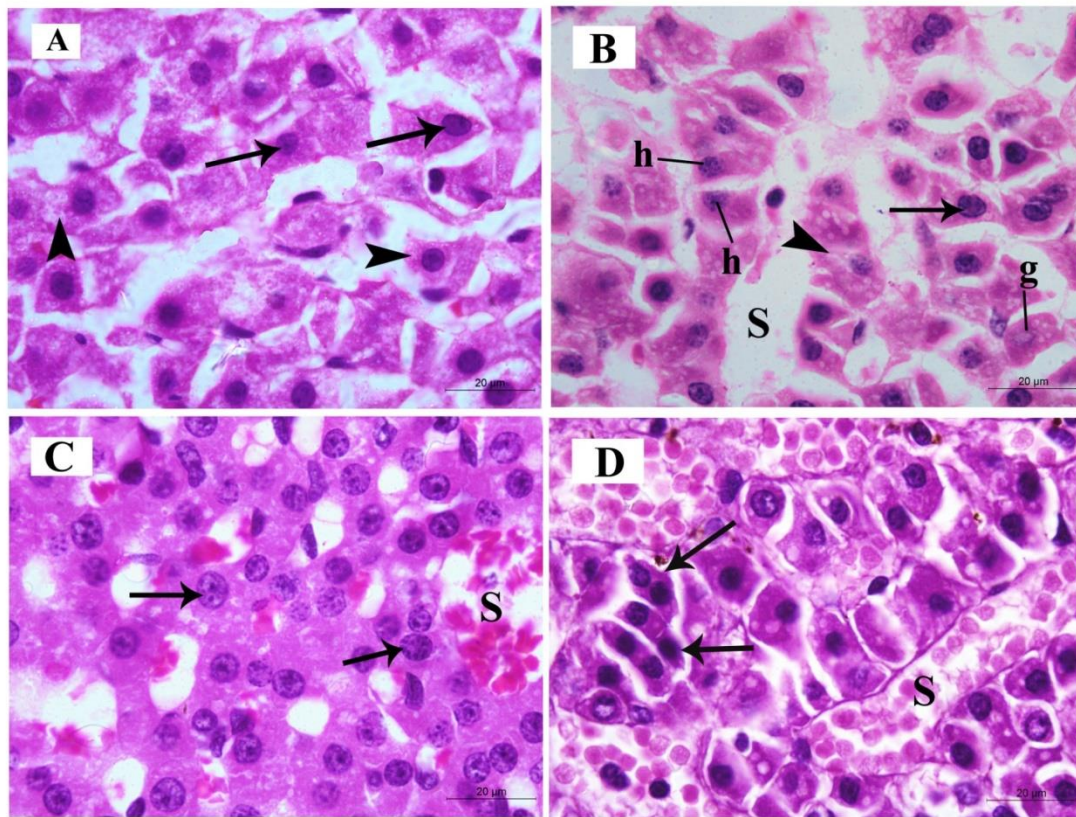


Figure 3. Hx & E. stained sections of ZR of different studied groups. **A**, control group; **B**, OVX group; **C**, OVX+ Genistein group and **D**, OVX+ Estradiol group. **A**, the cells in this zone are polyhedral with vesicular nuclei (**arrows**) and the cytoplasm has few vacuolations (**arrow heads**). **B**, the cells have vesicular nuclei (**arrow**) and vacuolated cytoplasm (**arrow head**) and some cells have hypochromatic (**h**) or ghost (**g**) nuclei. Reticularis sells are separated by dilated blood sinusoids (**S**). **C**, the cells became comparable to control with vesicular nuclei (**arrows**) and the blood sinusoids between the cells are mildly congested (**S**). **D**, reticularis cells are pleomorphic and binucleated (**arrows**). They are separated by congested blood sinusoids. Scale bar = 20 µm

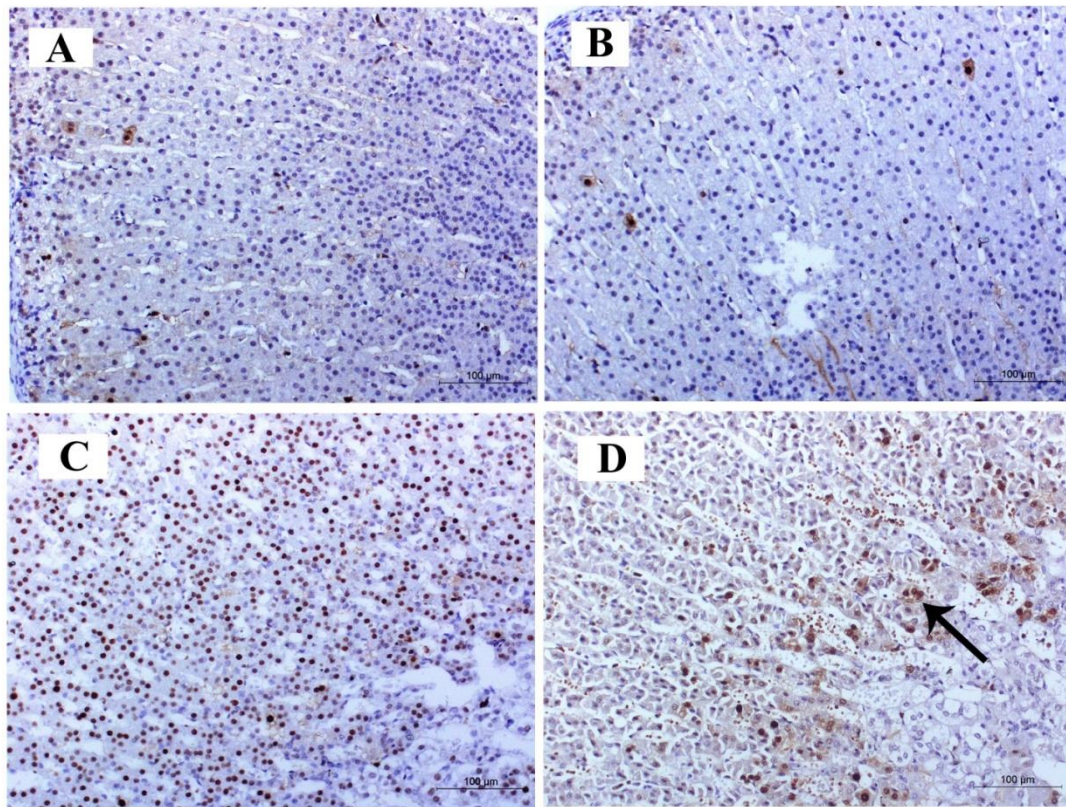


Figure 4. Photomicrograph of PCNA stained sections of different studied groups. A, control group and B, OVX group are showing negative immunoreaction. C, OVX+ Genistein group is revealing positive immunereaction. While, D, OVX+ Estradiol group showing strong positive immunereaction (arrow). Scale bar = 100 µm

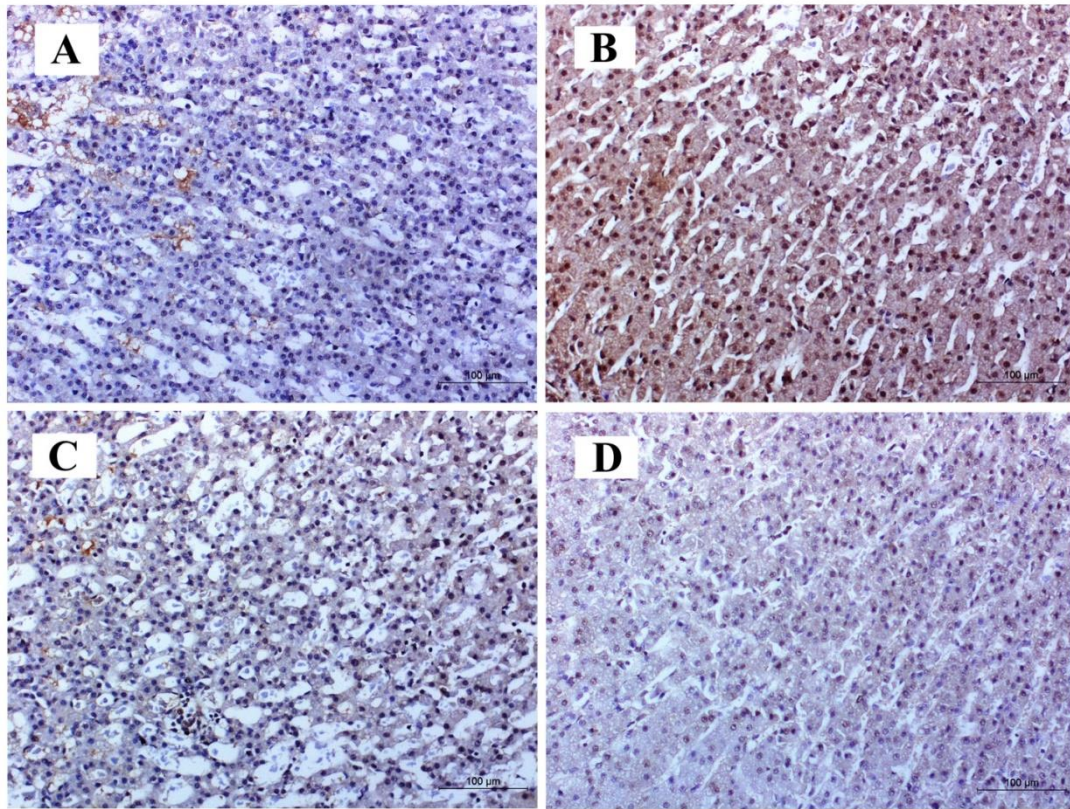


Figure 5. Photomicrograph of Caspase-3 stained sections of different studied groups. A, control group, C, OVX+ Genistein group and D, OVX+ Estradiol group showing negative immunoreaction. On the other hand, B, OVX group showing strong positive immunereaction. Scale bar = 100 µm

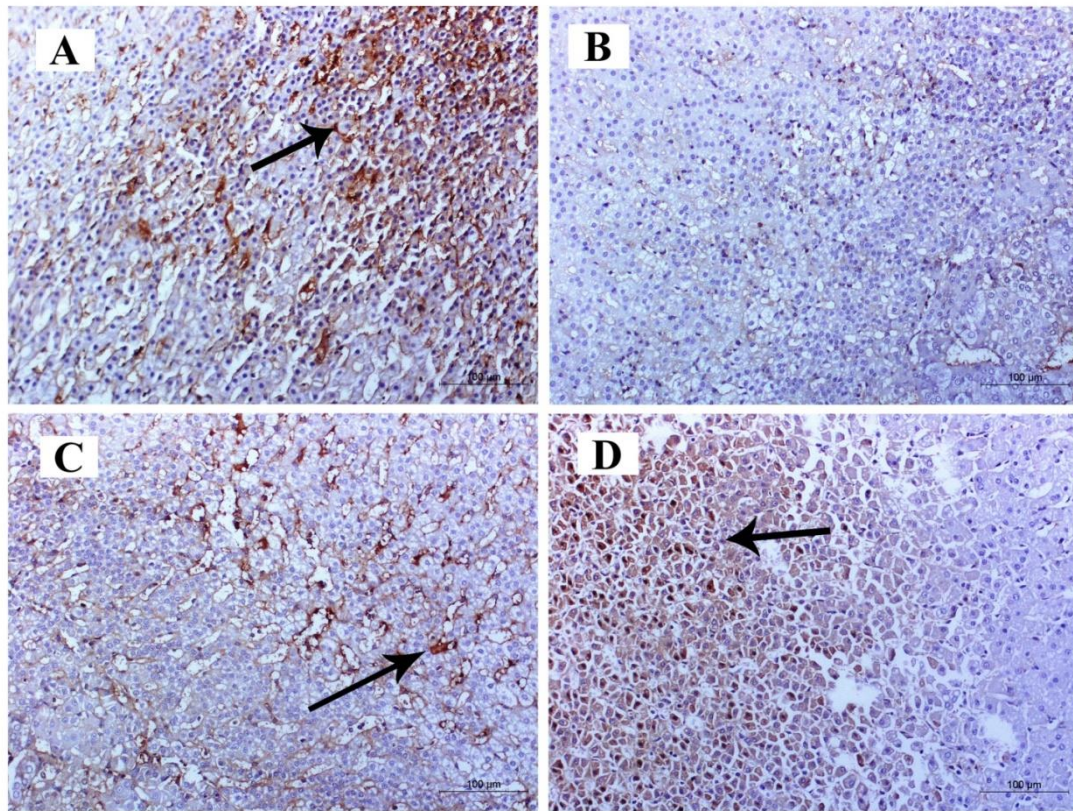


Figure 6. Photomicrograph of ER- β stained sections of different studied groups. A, control group, C, OVX+ genistein group and D, OVX+ estradiol group showing positive immunoreaction (arrows). B, OVX group is showing negative immunereaction. Scale bar = 100 μ m

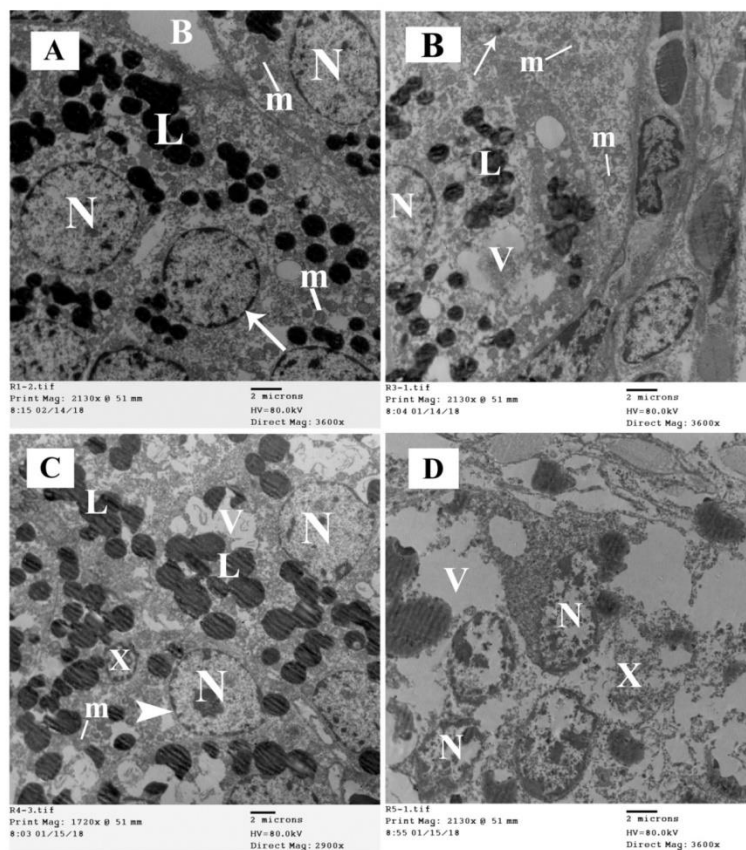


Figure 7. Electron micrographs of the ZG of the adrenal cortex of different studied groups. **A**, control group; **B**, OVX group; **C**, OVX+ Genistein group and **D**, OVX+ Estradiol group. **A**, glomerulosa cells have rounded or oval nuclei (**N**) with finely dispersed euchromatin and the nuclear envelope and nuclear pores are easily discerned (**arrow**) and the cytoplasm contains spherical or rounded mitochondria (**m**) and lipid globules (**L**). The cells are separated by blood capillaries (**B**). **B**, the nuclei of the glomerulosa cells are rounded or oval (**N**) and the cytoplasm contains rounded mitochondria (**m**), less lipid globules compared to the control group (**L**), numerous vacuoles (**V**) and small electron dens lysosomes (**arrow**). **C**, the nuclei (**N**), lipid globules (**L**) and mitochondria (**m**) are comparable to control. few vacuoles (**V**) are detected and few nuclei became small and condensed (**X**). **D**, glomerulosa cells have condensed nuclei (**N**) and the cytoplasm contains vacuoles (**V**) with dispersion of the cell organelles (**X**). Scale bars: E = 2 μ m.

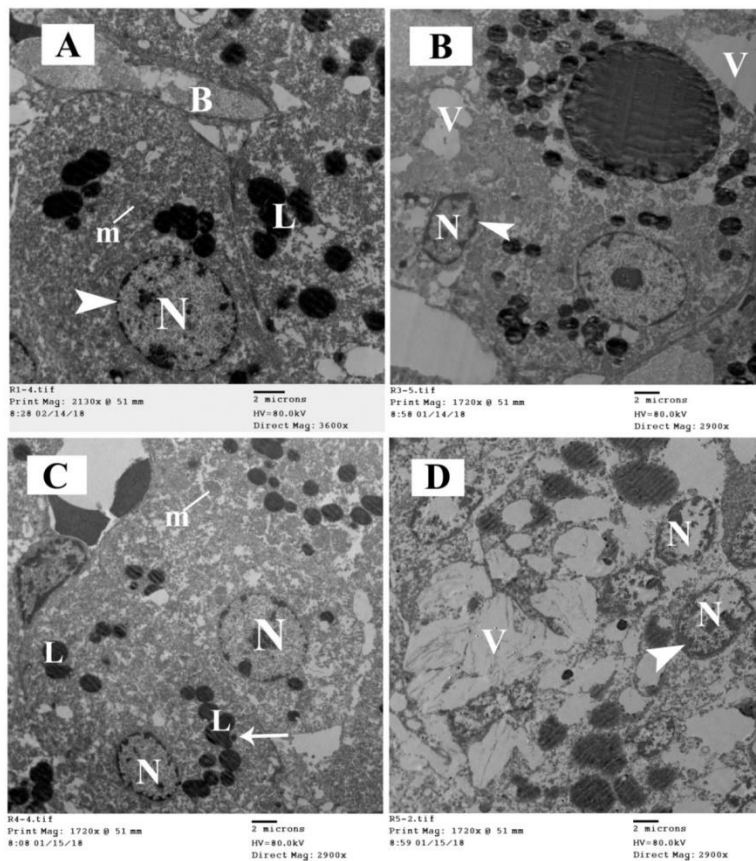


Figure 8. Electron micrographs of the ZF of the adrenal cortex of different studied groups. **A**, control group; **B**, OVX group; **C**, OVX+ Genistein group and **D**, OVX+ Estradiol group. **A**, fasciculata cells have rounded or oval euchromatic nuclei (**N**) with regular nuclear envelope and nuclear pores are easily discerned (**arrow head**) and the cytoplasm contains spherical or rounded mitochondria (**m**) and lipid globules (**L**). The cells are separated by blood capillaries (**B**). **B**, the cells contain irregular nucleus (**N**) with thick and irregular nuclear envelope and indistinguishable pores (**arrow head**) and the cytoplasm contains vacuoles (**V**). **C**, the cells show rounded or oval euchromatic nuclei (**N**) and the cytoplasm contains variable amount of lipid globules (**L**) and rounded mitochondria (**m**). **D**, The nuclei of the fasciculata cells (**N**) are condensed with thick and irregular nuclear envelope and indistinguishable pores (**arrow head**) and the cytoplasm has large amount vacuoles communicating with each other (**V**). Scale bars: E = 2 μ m.

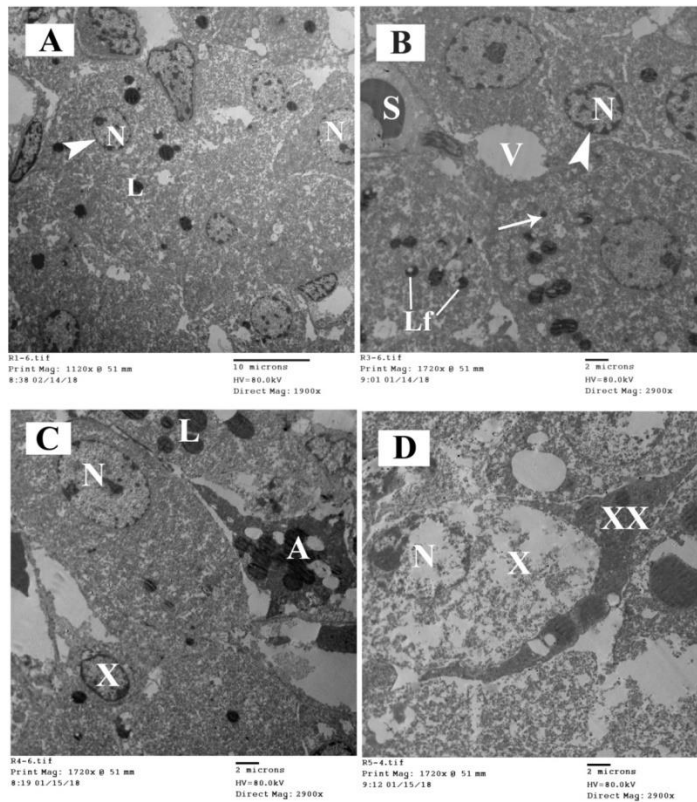


Figure 9. Electron micrographs of the ZR of the adrenal cortex of different studied groups. **A**, control group; **B**, OVX group; **C**, OVX+ Genistein group and **D**, OVX+ Estradiol group. **A**, the zona reticularis cells have rounded or oval euchromatic nuclei (N) with regular nuclear envelope and nuclear pores are easily discerned (**arrow head**) and the cytoplasm contains few lipid globules (L). **B**, reticularis cells contain irregular nucleus (N) with thick and irregular nuclear envelope and indistinguishable pores (**arrow head**) and the cytoplasm of the cells contains vacuoles (V), lysosomes (**arrow**) and lipofuscin granules (Lf). The cells are separated by blood sinusoids (S). **C**, in this zone, the cells contain variable amount of lipid globules (L) and euchromatic nuclei (N). Some cells show condensation of the nucleus chromatin (X) Apoptotic cell (A) is seen with loss of its architecture. **D**, the cells show dispersion of the cytoplasmic cell organelles (X).The nuclei of the cells (N) are small and electron dens. Apoptotic cell appear electron dens and compressed in between the cells (XX).Scale bars: A = 10 μm ; B, C, D = 2 μm .

Table 1. Morphometric data of zona glomerulosa thickness in all groups.

Groups	Mean± SD	Pairwise comparison between groups		
		(I) Cases	(J) Cases	P-value (Significance)
Group (1)	104.45± 12.68	1	2	0.0083
			3	0.4344
			4	0.528
Group (2)	83.80± 3.86	2	1	0.0083
			3	0.0144
			4	0.006
Group (3)	98.53± 9.86	3	1	0.4344
			2	0.0144
			4	0.192
Group (4)	110.45± 15.91	4	1	0.528
			2	0.006
			3	0.192

P < 0.05 is considered significant

Table 2.Morphometric data of zona fasciculata thickness in all groups.

Groups	Mean± SD	Pairwise comparison between groups		
		(I) Cases	(J) Cases	P-value (Significance)
Group (1)	685.09± 41.52	1	2	0.0001
			3	0.0886
			4	0.0001
Group (2)	371.69± 28.30	2	1	0.0001
			3	0.0001
			4	0.0001
Group (3)	752.15± 65.27	3	1	0.0886
			2	0.0001
			4	0.0003
Group (4)	959.52± 39.61	4	1	0.0001
			2	0.0001
			3	0.0003

P < 0.05 is considered significant

Table 3. Morphometric data of zona reticularis thickness in all groups.

Groups	Mean± SD	Pairwise comparison between groups		
		(I) Cases	(J) Cases	P-value (Significance)
Group (1)	317.98± 24.97	1	2	0.0001
			3	0.0510
			4	0.0001
Group (2)	178.15± 13.74	2	1	0.0001
			3	0.0001
			4	0.0001
Group (3)	366.14± 39.76	3	1	0.0510
			2	0.0001
			4	0.0022
Group (4)	481.50± 42.55	4	1	0.0001
			2	0.0001
			3	0.0022

P < 0.05 is considered significant