

# Technetium pertechnetate uptake in parathyroid adenoma

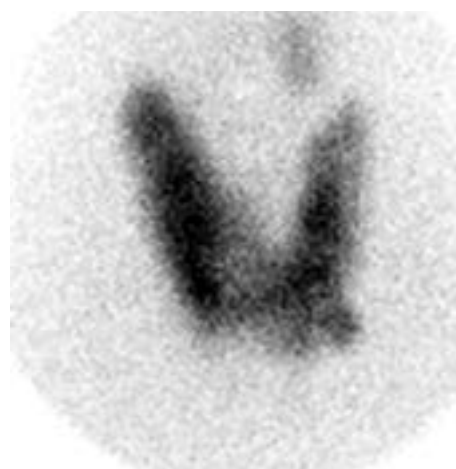Ali Sellem , Wassim Elajmi , Hatem Hammami 

Military Hospital of Tunis, Montfleury, Tunis

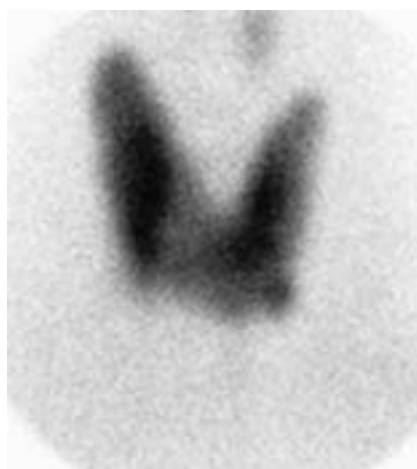[Received 16 I 2020; Accepted 20 VII 2020]

We report the case of a 37-year-old woman newly diagnosed primary hyperparathyroidism with hypercalcemia 16.1 mg/dL (Ref range 8.5–10.1) and an increased parathyroid hormone level 110 pg/mL (reference range 10.0–70.0). She was referred to our department for scintigraphic localization of a parathyroid adenoma. The Tc-99m scintigraphy (Fig. 1) revealed a normal thyroid uptake associated with one focal uptake below the left lobe of the thyroid. A Tc-99m sestamibi parathyroid scan (Fig. 2) was performed showing an accumulation of the tracer in the

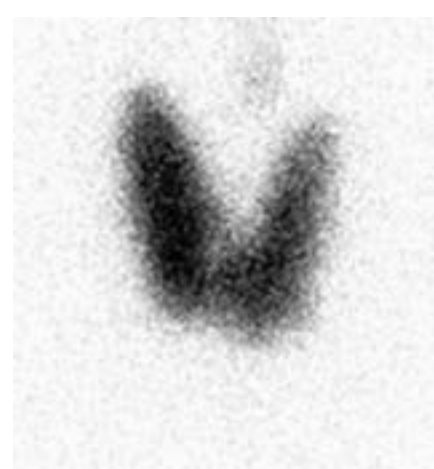
same localization of Tc-99m focal uptake. It was a dilemma: is it an eccentric thyroid tissue that fixes the two radiotracers or a parathyroid adenoma fixing the  $^{99m}\text{Tc}$ . Since we do not have the iodine 123 we realized an image (Fig. 3) with a tracer dose of iodine 131 showing no uptake below the left lobe of thyroid which allowed us to conclude to a parathyroid adenoma. The patient subsequently underwent minimally invasive cervicotomy with the resection of this lesion which was histologically diagnosed as a parathyroid adenoma.



**Figure 1.** Tc-99m scintigraphy showing one focal uptake below the left lobe of thyroid



**Figure 2.** Sestamibi parathyroid scan showing an accumulation of the tracer in the same localization of Tc-99m focal uptake



**Figure 3.** Iodine 131 scintigraphy showing no uptake below the left lobe of thyroid

Correspondence to: Ali Sellem, Military Hospital of Tunis, Montfleury, 1009 Tunis  
e-mail: sellem\_ali@yahoo.fr