

A case of drug-coated balloon treatment for two total occluded lesions in a patient with acute coronary syndrome

Song Lin Yuan^{1,2}, Moo Hyun Kim², Scot Garg³, Eun-Seok Shin¹

¹Division of Cardiology, Department of Internal Medicine, Ulsan Medical Center, Ulsan, South Korea

²Department of Cardiology, Dong-A University Hospital, Busan, South Korea

³East Lancashire Hospitals NHS Trust, Blackburn, Lancashire, United Kingdom

A 51-year-old man was admitted with worsening effort angina over a 1 month period. His only coronary risk factor was hypercholesterolemia. Cardiac enzymes including creatine kinase-MB and troponin I were normal. His electrocardiogram showed Q-waves in V₁ to V₄. The coronary angiograms showed a short left main with complete occlusions in the proximal left anterior descending (LAD) and left circumflex (LCX) artery (Fig. 1A–C). Revascularization options were discussed and the option to treat the lesions with drug-coated balloons (DCB) was decided. He was carefully assessed, and gave informed consent.

A guide wire successfully crossed the total occlusion of the LCX. Pre-dilatation was performed with a 1.5 × 15 mm balloon, followed by a 2.5 × 15 mm non-compliant balloon up to 16 atm and

finally a 2.5 × 30 mm DCB was inflated at 7 atm for 60 s. Then to the LAD lesion, pre-dilatation was performed with 1.5 × 15 mm balloon and a 3.0 × 15 mm scoring balloon at 16 atm, and then finally a 3.5 × 20 mm DCB was inflated at 7 atm for 60 s. The final angiograms showed normal flow in both LAD and LCX with no significant dissection or residual stenoses (Fig. 1D–F).

Three months later, follow-up coronary angiography confirmed adequate patency of the DCB treated lesions and reassuringly the distal LCX and proximal LAD looked better (Fig. 1G–I). He remains symptom free, 13-month post-intervention.

After treatment with a DCB, it is possible that vessels will return to their original size over time, which is one of the greatest advantages of DCB treatment in total occluded lesions.

Conflict of interest: None declared

Address for correspondence: Eun-Seok Shin, MD, PhD, Division of Cardiology, Department of Internal Medicine, Ulsan Medical Center, Ulsan, South Korea, e-mail: sesim1989@gmail.com

Received: 3.04.2020

Accepted: 13.04.2020

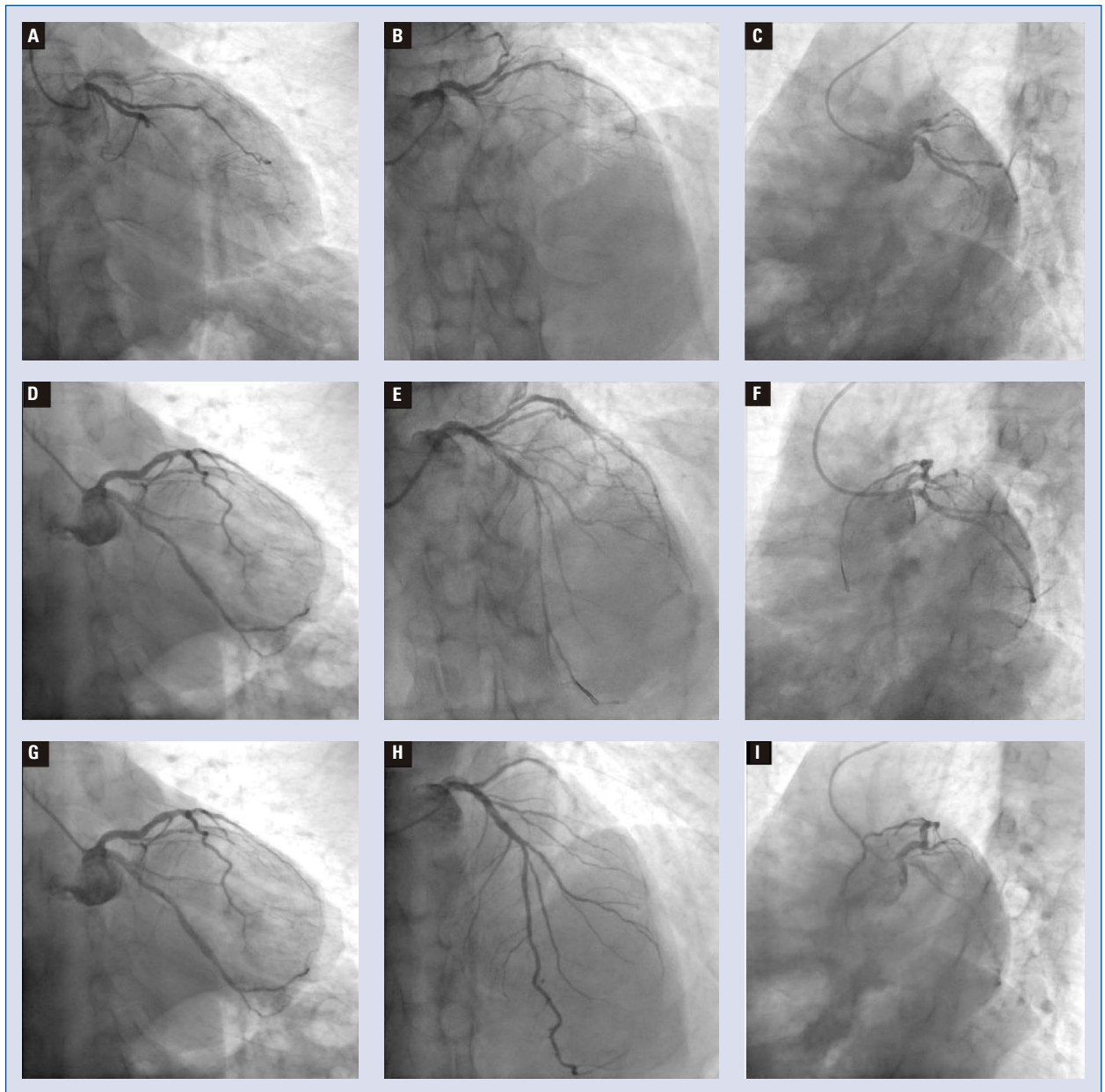


Figure 1. Coronary artery angiography; **A–C.** Before intervention; **D–F.** Right after treatment with a drug-coated balloon; **G–I.** Follow-up angiography at 3 months.