

2019

PDF Research Detection of hiatal hernias: comparison of high-resolution manometry and physician reported in an obese-predominant population

Sardar M. Shah-Khan

Fahad Chaudhary

Abdelhai Abdelqader

Justin T. Kupec

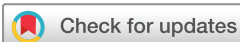Nova Szoka

Detection of hiatal hernias: comparison of high-resolution manometry and physician reported in an obese-predominant population

Sardar Momin Shah-Khan,¹ Fahad Chaudhary,¹ Abdelhai Abdelqader,² Justin T. Kupec,² Nova Szoka³

To cite: Shah-Khan SM, Chaudhary F, Abdelqader A, *et al.* Detection of hiatal hernias: comparison of high-resolution manometry and physician reported in an obese-predominant population. *BMJ Open Gastro* 2019;**6**:e000300. doi:10.1136/bmjgast-2019-000300

Received 12 March 2019
Revised 12 April 2019
Accepted 18 April 2019



© Author(s) (or their employer(s)) 2019. Re-use permitted under CC BY-NC. No commercial re-use. See rights and permissions. Published by BMJ.

¹Department of Internal Medicine, West Virginia University, Morgantown, West Virginia, USA

²Section of Digestive Diseases, West Virginia University, Morgantown, West Virginia, USA

³Department of Surgery, West Virginia University, Morgantown, West Virginia, USA

Correspondence to

Dr Sardar Momin Shah-Khan; sshahkh1@hsc.wvu.edu

ABSTRACT

Background The diagnosis of a hiatal hernia (HH) can be made by barium oesophagram or upper endoscopy. Data regarding the ability of high-resolution manometry (HRM) with oesophageal pressure topography (OPT) to identify HH remains limited. We aim to assess the diagnostic accuracy of the automated localisation on high-resolution manometry compared with physician visual interpretation on the detection of HH.

Methods Patients (n=181) from West Virginia, Pennsylvania, Maryland, Virginia and Ohio, undergoing HRM with OPT from 1 January 2015 to 1 December 2017 were reviewed. The BMIs of this patient population are of the highest in the USA. Demographics, presenting symptoms, laboratory data, endoscopic findings, radiographic findings, and HRM findings were collected. Diagnosis of HH through HRM automated identification of oesophageal landmarks were compared with diagnosis by physician visual interpretation of OPT.

Results Automated identification of HH using HRM had high specificity (99.1%), but low sensitivity (11.4%). Physician visual interpretation of OPT similarly had high specificity (82.9%, 83.8%), but low sensitivity (30.0%, 28.6%). Automated identification of HH had a greater positive predictive value (88.9%) compared with physician visual interpretation (52.5%, 52.6%) but was found to have a similar negative predictive value (63.9%) as physician visual interpretation (65.3%, 65.0%).

Conclusion Compared with physician visual interpretation of OPT, automated identification of HH was more specific, but less sensitive in the diagnosis of HH. Use of automated identification of HH using HRM alone may lead to an increased number of false negatives, and subsequent underdiagnosis of this condition.

INTRODUCTION

A hiatal hernia (HH) occurs when the oesophago-gastric junction (OGJ), normally located at the crural diaphragm (CD), protrudes with gastric tissue above the diaphragm.¹ The protrusion can result in a sliding HH (type I), paraoesophageal HH (type II), mixed type HH (type III), and massive HH (type IV).

Summary box

What is already known about this subject?

- ▶ High-resolution manometry has been demonstrated to be a sensitive tool in the diagnosis of hiatal hernia.
- ▶ Patients with obesity are at greater risk for the development of hiatal hernia.

What are the new findings?

- ▶ High-resolution manometry is specific but not sensitive in the identification of hiatal hernia in an obese population compared with non-surgical reference standards. Additionally, automated identification of hiatal hernia using oesophageal landmarks is more specific but less sensitive compared with identification by physician interpretation.

How might it impact on clinical practice in the foreseeable future?

- ▶ Automated identification of hiatal hernia by high-resolution manometry results in a high rate of false negatives when using non-surgical reference standards. Such a use may lead to the underdiagnosis of this condition in an obese population.

The most common hernia is sliding and puts patients at risk for gastro-oesophageal reflux, development of Barrett's oesophagus, and non-erosive or erosive oesophagitis.

While the gold standard to diagnose HH is direct intraoperative visualisation, it is almost never done solely for the diagnosis. Other methods to diagnose HH can be with a barium swallow oesophagram or upper endoscopy. On oesophagram, gastric rugae can be seen above the CD indicating the presence of an HH. On upper endoscopy, the HH can be seen in multiple views. Unfortunately, these methods can be subjective and indirectly assess the OGJ and the CD location.

Identifying an HH on manometry is based on identifying the lower oesophageal

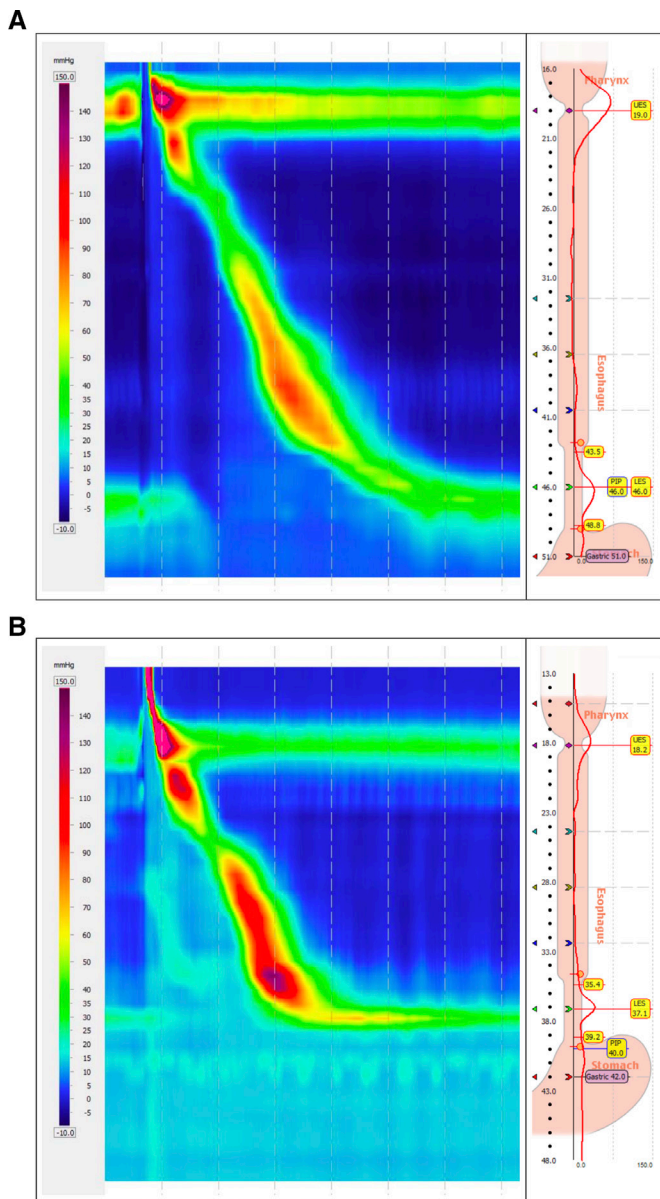


Figure 1 (A) A high-resolution manometry with pressure topography demonstrating the absence of a hiatal hernia with near overlap of the lower oesophageal sphincter and crural diaphragm. (B) A high-resolution manometry with pressure topography demonstrating a hiatal hernia.

sphincter (LOS) and CD, then noting the separation between them (figure 1A, B). High-resolution manometry (HRM) is able to automatically identify the level of the CD in real time by determining pressure inversion point (PIP), or the point at which pressure shifts occur inferior and superior to the diaphragm.² OGJ morphology can be further classified by the Chicago classification into three subtypes based on the degree of separation as either no separation (type I), 1–2 cm of separation (type II) or ≥ 2 cm (type III).³ Prior studies have shown conventional manometry to be of low utility in detecting HH with a sensitivity of 20% and specificity of 99%.⁴ Few studies have shown that HRM can detect HH with sensitivity and specificity of $>90\%$.^{5–7} Studies of HRM detecting HH in

an obese-predominant population remains lacking. The prevalence of HH in obese patient has been estimated at least 40%.⁸ Patients with grade 3 obesity undergoing gastric bypass surgery should have evaluation for presence of HH as it may alter surgical intervention.

Our aim was to analyse the ability of HRM to identify HH in reference to barium oesophagram and oesophagogastroduodenoscopy (OGD) in an obese-predominant population. Furthermore we sought to assess the utility in automated landmark localisation of HRM in detecting HH compared with physician visual interpretation of HRM.

METHODS

After obtaining approval from the West Virginia University Institutional Review Board, a systematic review was performed. Patients from West Virginia, Pennsylvania, Maryland, Virginia and Ohio who underwent HRM with oesophageal pressure topography (OPT) from 1 January 2015 to 1 December 2017 were included. Patient demographics, laboratory data, endoscopic findings, radiographic findings, HRM findings, and descriptive factors such as body mass index (BMI) and presenting symptoms were collected and stored in a secure REDCap database. We excluded patients under 18 years of age, those who had a prior diagnosis of an oesophageal disorder, and those who had history of surgery in the oesophagus and/or stomach. Additionally, patients without a documented OGD or barium oesophagram were excluded.

Radiographically, HH was determined to be present via barium oesophagram by visualisation of the distended oesophagus with an associated displacement of the OGJ. In accordance with diagnostic standards, on barium oesophagram a minimum difference of 2 cm between the B ring and diaphragmatic hiatus was considered diagnostic of an HH. On OGD, HH was diagnosed during endoscopic visualisation of the axial displacement of the OGJ of at least 1 cm.

HRM was performed in the standard manner with patients in a 30° supine position. A solid state HRM catheter probe with 36 circumferential pressure sensors at 1 cm intervals and 19 impedance channels at 2 cm intervals was passed intranasally with patient cooperation to a depth of 60 cm to ensure the probe reached the gastric cardia. After allowing the probe to adapt, the patient was asked to perform 10 wet swallows. OPT reports were generated with the ManoView ESO analysis program V.3.0.1 by Given Imaging (710 Medtronic Parkway, Minneapolis, MN 55432) and identified the presence of HH using an algorithm based on the automatically localised LOS and PIP.

Criteria laid out Kahrilas *et al* in the Chicago Classification was used to assess OGJ morphology.³ In their study, three major subtypes of OGJ pressure morphology were outlined. Topographic plots of normal individuals or type I morphology are demonstrated when the CD is entirely superimposed on the LOS. Type II morphology

is defined by a 1–2 cm separation between the CD and the LOS. Type III is defined as any separation greater than 2 cm as at this degree of separation, the peaks in the spatial pressure variation plots is at or below gastric pressure. For the purposes of this study, OGJ morphology types II and III were considered to be indicative of an HH.

The composite OPT plots of each HRM study (n=181) alone were cropped and randomly arranged in a word processing document. These images were then reviewed by a gastroenterologist and a foregut surgeon to visually interpret whether HH was present or not. At the time of HRM testing interpretation, the examiners were blinded to prior imaging or endoscopic findings. Conversely, the endoscopist also had no knowledge of the HRM with OPT findings during OGD.

Statistical analysis

Results were expressed as means and SD. They were compared using the χ^2 test to test differences in the distribution of diagnosis. A p value of <0.05 was considered significant. Using the diagnosis of HH by either OGD or barium oesophagram as our reference standard, we calculated the sensitivity, specificity, likelihood ratios and predictive values for HRM. To assess for any differences between the tests we chose as our reference standard, we additionally calculated the sensitivity, specificity, likelihood ratios and predictive values of HRM independently to barium oesophagram and OGD, respectively. Fleiss' kappa was used to assess for inter-rater reliability between physician interpretations and automated analysis in determining whether or not an HH was present.⁹ Degree of agreement was interpreted as kappa value: poor (0–0.2), fair (0.21–0.4), moderate (0.41–0.6), good (0.61–0.8), and excellent (0.81–1). All above statistical analysis were performed using SPSS (IBM, Released 2017. IBM SPSS Statistics for Windows, V.25.0).

RESULTS

Of 319 subjects who underwent HRM, 181 met inclusion criteria with either a barium oesophagram or OGD performed (figure 2). Of the 181, the mean age was 56.0 (± 17.3) and 61.3% were female (table 1). The mean BMI was 30.8 (± 7.9).

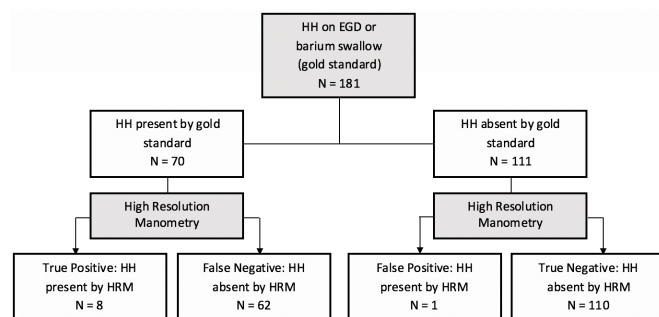


Figure 2 Flow chart demonstrating the results of HRM in the automated diagnosis of HH. HH, hiatal hernia; HRM, high-resolution manometry.

	All patients	Positive HRM	Negative HRM	P value
Age (mean)	56.0 \pm 17.9	62.9 \pm 11.9	55.7 \pm 17.5	ns
BMI	30.8 \pm 7.9	31.9 \pm 4.2	30.7 \pm 8.1	ns
Gender (M:F)	70:111	4:5	66:106	ns

BMI, body mass index; HRM, high-resolution manometry; ns, no significance.

The two most common symptoms for referral to manometry were dysphagia and gastro-oesophageal reflux disease (GORD) (figure 3). Some patients were referred for more than one symptom.

A total of 70 patients were found to have an HH on either barium oesophagram or OGD. A total of 11 patients were found to have an HH by both barium oesophagram and OGD. Of these patients, the mean size of the HH by barium oesophagram was 30 mm compared with 25 mm by OGD. In comparing the detection of HH to diagnosis by either barium-swallow oesophagram and upper endoscopy, automated analysis of HRM was accurately able to identify the presence of 8 HH resulting with a sensitivity of 11.4% and specificity of 99.1%.

In the physician-based detection group, physician# 1 reported 31/181 (17.1%) of patients to have OGJ morphology type II along with 9/181 (4.9%) to have type III. Physician 2 reported 22/181 (12.11%) to have type II and 16/181 (8.8%) to have type III. Physician-based detection of HH had a mean sensitivity of 29.3% (p=0.03) and a mean specificity of 83.4% (p=0.003). Fleiss' kappa assessment for inter-rater reliability in determining whether or not an HH was present demonstrated fair agreement between interpreters with $\kappa=0.379$ (95% CI, 0.233 to 0.525). The likelihood ratio was positive in automated localisation 12.7, while physician-based detection was 1.8 for both groups.

In the automated localisation group, the positive predictive value was 88.9% compared with 52.5% and 52.6% in the physician-based detection group. Negative predictive value was 63.9% in the automated localisation

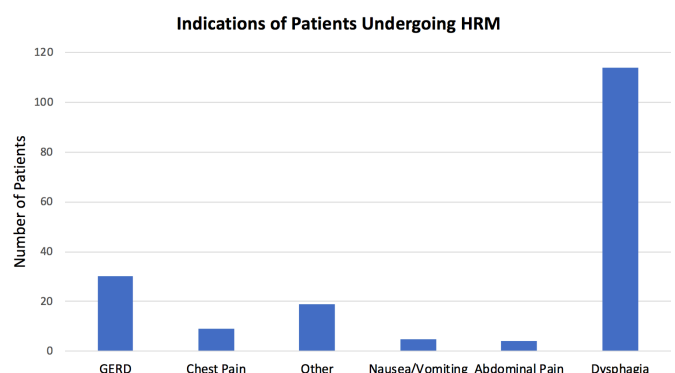


Figure 3 Graph showing the various indications for patients undergoing high-resolution manometry (HRM).



Table 2 HRM identification of HH in comparison with diagnosis of HH by barium oesophagram or OGD

	Automated localisation	Physician 1	Physician 2
Sensitivity	11.4%	30.0%	28.6%
Specificity	99.1%	82.9%	83.8%
Positive likelihood ratio	12.7	1.8	1.8
Negative likelihood ratio	0.89	0.84	0.85
Positive predictive value	88.9%	52.5%	52.6%
Negative predictive value	63.9%	65.3%	65.0%

HH, hiatal hernia; HRM, high-resolution manometry.

group while in the physician-based detection group, was 65.3% and 65.0%, respectively (table 2).

With barium oesophagram, 24 HH were identified with a mean size of 31 mm (range 20–60 mm). In comparing the ability of HRM to identify HH in reference to barium oesophagram alone, automated localisation had a sensitivity of 4.7% compared with 33.3% and 25.0% for physician interpretation, respectively (table 3).

On OGD, 46 patients were found to have HH with 38 patients with a Hill grade II and eight as Hill grade III resulting in a mean size of 17 mm (range 10 mm to 40 mm). In reference to OGD alone, automated localisation had a sensitivity of 17.4% in the detection of HH compared with 37.0% by physician interpretation (table 4).

Table 3 Subgroup analysis assessing the ability of high-resolution manometry using barium oesophagram as the reference standard

	Automated localisation	Physician 1	Physician 2
Sensitivity	4.7%	33.3%	25.0%
Specificity	98.0%	84.9%	82.8%
Positive likelihood ratio	2.1	2.2	1.5
Negative likelihood ratio	0.98	0.79	0.91
Positive predictive value	33.3%	34.8%	26.1%
Negative predictive value	80.8%	74.8%	82.0%

Table 4 Subgroup analysis assessing the ability of high-resolution manometry using OGD as the reference standard

	Automated localisation	Physician 1	Physician 2
Sensitivity	17.4%	37.0%	37.0%
Specificity	99.0%	84.6%	84.6%
Positive likelihood ratio	18.1	2.4	2.4
Negative likelihood ratio	0.83	0.75	0.75
Positive predictive value	88.9%	51.5%	51.5%
Negative predictive value	73.1%	75.2%	75.2%

When comparing age, gender, and BMI of those with HH detected on HRM to those with HH not detected on HRM, there was no statistical difference (table 1).

DISCUSSION

Recent studies have shown the use of HRM in detecting HH. In our study, we illustrate the ability of HRM to identify HH in comparison with physician-based review in one of the most obese populations in the USA. We demonstrated automated analysis of oesophageal landmarks in HRM identify HH with a sensitivity of 11.4% and specificity of 99.1% when using barium oesophagram or OGD as a reference standard. Given our patient population's high BMI range, we were able to assess the effects of obesity on detecting HH. Our findings suggest that HRM is an unreliable tool in the visualisation of HH in patients with obesity.

We should highlight the fact that our study used barium oesophagram and OGD as the reference standard for determining the sensitivity of HRM in the detection of HH. Interpreters of our study should note that definitive diagnosis of an HH can only be made by intraoperative visualisation. Our study provides value in that it serves as a comparison for the identification to that of non-surgical methods. Compared with other reference studies that assessed HH in surgical patients, our study examined a wide range of patients undergoing manometry for a number of indications. By not limiting our study population to patients who were simply surgical candidates, our results are potentially more applicable to the general obese population. Rather, our study examines the utility of using HRM as a screening tool for the diagnosis of HH in everyday clinical practice.

Our findings differ from that of studies aimed at identifying HH in non-obese patients. Studies have shown that obesity results in alterations at the gastro-oesophageal junction.¹⁰ In patients with obesity, augmentation of both gastric and oesophageal pressure has been demonstrated in comparison to that of non-obese patients. The degree to which each of these individual pressures vary

likely varies between patients and may alter the distance between the LOS and CD thus potentially altering the visualisation of HH on HRM. Furthermore, among all individuals, differences in waist circumference has also been shown to be associated with alterations in these pressures. Though we did not measure waist circumference in our obese population, this factor may potentially account for some of the variation between studies in obese versus non-obese patients.

While OGJ type III represents the morphology most often attributed to HH, others have proposed that OGJ type II should also be viewed as abnormal.^{7 11} Given the dynamic nature of the OGJ, further separation of the LOS and the CD may be induced by peristalsis and therefore OGJ type II may represent an overt HH.⁷ To best assess the ability of HRM to identify HH, our study considered both OGJ morphology types II and III to be diagnostic of an HH.

Previous studies on HRM detection of HH have shown that using type III as the sole criteria for defining an HH yielded poorly sensitive results.⁶ To further assess this, we reanalysed our data to only include type III morphology. As expected, sensitivities dropped to 8.6% and 14.3% respectively, while also increasing the rate of false negatives. Regardless of the manometric criteria used, our study found HRM to be an unreliable test in patients with obesity.

Within our study population, automated landmark localisation of LOS and PIP using manometry software was not as accurate in diagnosing HH relative to interpreters who independently reviewed the OPT reports, despite a fair degree of agreement among raters. In the subgroup analysis between patients with HH identified on OGD and those with barium oesophagram, we saw that automated analysis was slightly more sensitive in reference to OGD. Though among all studies, the independent physician review increased the sensitivity for HH diagnosis. However, this same review process led to a decrease in specificity for HH identification. Additionally, there was no evidence to suggest that age, BMI or gender influenced whether a patient was likely to test positive for HH using either HRM or OGD. Comparing the sensitivity of HH diagnosis using HRM, physicians 1 and 2 performed very similarly to those in published data using OGD as gold standard.^{12 13}

To the best of our knowledge, this is the first study investigating errors in automated software localisation at the OGJ. Accurate OGJ localisation and OGJ parameters is important for an accurate diagnosis and may guide surgical options in patients undergoing gastric bypass surgery with possible consideration for hernia repair. In foregut surgery and HH repair, OGJ characterisation guides the type of fundoplication (Nissen vs Toupet or Dor) performed and, in turn, whether patients are likely to develop dysphagia after surgery.¹⁴

Our study has several limitations. As noted previously, HH was detected using OGD and barium oesophagram whereas the most accurate method of diagnosis would

be direct surgical visualisation. Second, the data for the study was collected retrospectively by reviewing reports for HRM, OGD and barium oesophagram, thus it is susceptible to confounding factors for which were not measured or accounted. HH noted on OGD reports did not always include the size or grade. Thus, we relied on a review of intraoperative images for the axial displacement of the OGJ. Our evaluation does gain strength from the fact that all procedures (OGD and HRM) were performed in a standard and protocolised process by a small, trained team to minimise variation. All physician interpreters were trained independently to read manometry and not by the same teacher. It has been shown that interpretation of HRM may vary as much as 10% based on manufacturer, software used, patient position, gender and body habitus.¹⁵ Such variation between interpreters would undoubtedly have an effect on our findings. However statistical analysis demonstrated a fair agreement among our reviewers. Finally, our manometry system uses Chicago Classification version 2.0 instead of the most recent revision released in 2015 (v3.0) which research has found corrects for the under and over diagnosis of conditions.¹⁶

In summary, compared with physician visual interpretation of OPT plots, automated identification of HH by manometry software was more specific, but less sensitive. Physician interpretation of LOS and PIP when analysing OPT reports improves the sensitivity of HH identification by HRM. Automated identification of oesophageal landmarks using HRM is specific, but not sensitive for visualisation of HH. Use of automated identification of HH using HRM alone may lead to an increased number of false negatives, and subsequent under reporting of this condition. More specifically, our study found HRM to be an inefficient test in the visualisation of HH when using a non-surgical reference standard in the setting of an obese population.

Contributors All authors contributed meaningfully to the production of this report with the following specifications: SMS-K assisted in the research, project design, data collection and drafting of the manuscript. FC assisted in the research, project design, data collection and drafting of the manuscript. AA assisted in the research, project design and drafting of the manuscript. JK assisted in the research, project design and drafting of the manuscript. NS assisted in the research, project design and drafting of the manuscript.

Funding All authors report no funding for this report by the public nor commercial industry.

Competing interests None declared.

Patient consent for publication Not required.

Ethics approval This study was approved by the Institutional Review Board of West Virginia University, protocol ID #1711834750.

Provenance and peer review Not commissioned; externally peer reviewed.

Data sharing statement Data are available upon reasonable request.

Open access This is an open access article distributed in accordance with the Creative Commons Attribution Non Commercial (CC BY-NC 4.0) license, which permits others to distribute, remix, adapt, build upon this work non-commercially, and license their derivative works on different terms, provided the original work is properly cited, appropriate credit is given, any changes made indicated, and the use is non-commercial. See: <http://creativecommons.org/licenses/by-nc/4.0/>.



REFERENCES

1. Hill LD, Kozarek RA, Kraemer SJ, *et al.* The gastroesophageal flap valve: in vitro and in vivo observations. *Gastrointest Endosc* 1996;44:541–7.
2. Kahrilas PJ, Kim HC, Pandolfino JE. Approaches to the diagnosis and grading of hiatal hernia. *Best Pract Res Clin Gastroenterol* 2008;22:601–16. and.
3. Kahrilas PJ, Bredenoord AJ, Fox M, *et al.* The Chicago classification of esophageal motility disorders, v3.0. *Neurogastroenterol Motil* 2015;27:160–74.
4. Agrawal A, Tutuian R, Hila A, *et al.* Identification of hiatal hernia by esophageal manometry: is it reliable? *Dis Esophagus* 2005;18:316–9.
5. Tolone S, Savarino E, Zaninotto G, *et al.* High-resolution manometry is superior to endoscopy and radiology in assessing and grading sliding hiatal hernia: A comparison with surgical in vivo evaluation. *United European Gastroenterol J* 2018;6:981–9.
6. Khajanchee YS, Cassera MA, Swanström LL, *et al.* Diagnosis of type-I hiatal hernia: a comparison of high-resolution manometry and endoscopy. *Dis Esophagus* 2013;26:1–6.
7. Weijenborg PW, van Hoeij FB, Smout AJPM, *et al.* Accuracy of hiatal hernia detection with esophageal high-resolution manometry. *Neurogastroenterol Motil* 2015;27:293–9.
8. Che F, Nguyen B, Cohen A, *et al.* Prevalence of hiatal hernia in the morbidly obese. *Surg Obes Relat Dis* 2013;9:920–4.
9. Fleiss JL, Cohen J. The equivalence of weighted kappa and the intraclass correlation coefficient as measures of reliability. *Educ Psychol Meas* 1973;33:613–9.
10. Pandolfino JE, El-Serag HB, Zhang Q, *et al.* Obesity: a challenge to esophagogastric junction integrity. *Gastroenterology* 2006;130:639–49.
11. Pandolfino JE, Kim H, Ghosh SK, *et al.* High-resolution manometry of the EGJ: an analysis of crural diaphragm function in GERD. *Am J Gastroenterol* 2007;102:1056–63.
12. Weitzendorfer M, Köhler G, Antoniou SA, *et al.* Preoperative diagnosis of hiatal hernia: barium swallow X-ray, high-resolution manometry, or endoscopy? *Eur Surg* 2017;49:210–7.
13. Pandolfino JE, Kwiatek MA, Ho K, *et al.* Unique features of esophagogastric junction pressure topography in hiatus hernia patients with dysphagia. *Surgery* 2010;147:57–64.
14. DeLay K, Austin GL, Menard-Katcher P. Anatomic abnormalities are common potential explanations of manometric esophagogastric junction outflow obstruction. *Neurogastroenterol Motil* 2016;28:1166–71.
15. Jain M, Srinivas M, Bawane P, *et al.* Does Chicago classification address symptom correlation with high-resolution esophageal manometry? *Euroasian J Hepatogastroenterol* 2017;7:122–5.
16. Imaging G. ManoView ESo user manual version 3.0.1 2013.