

2015

Cystic fibrosis diagnosed via presentation of intussusception in childhood

Patrick C. Bonasso
West Virginia University

Jason L. Turner
West Virginia University

Richard A. Vaughan
West Virginia University

Don K. Nakayama
West Virginia University

Follow this and additional works at: https://researchrepository.wvu.edu/faculty_publications

Digital Commons Citation

Bonasso, Patrick C.; Turner, Jason L.; Vaughan, Richard A.; and Nakayama, Don K., "Cystic fibrosis diagnosed via presentation of intussusception in childhood" (2015). *Faculty & Staff Scholarship*. 2255.
https://researchrepository.wvu.edu/faculty_publications/2255

This Article is brought to you for free and open access by The Research Repository @ WVU. It has been accepted for inclusion in Faculty & Staff Scholarship by an authorized administrator of The Research Repository @ WVU. For more information, please contact ian.harmon@mail.wvu.edu.



Cystic fibrosis diagnosed via presentation of intussusception in childhood



Patrick C. Bonasso*, Jason L. Turner, Richard A. Vaughan, Don K. Nakayama

West Virginia University, 1 Medical Center Drive, Morgantown, WV 26505, USA

ARTICLE INFO

Article history:

Received 6 December 2014

Received in revised form

15 January 2015

Accepted 17 January 2015

Key words:

Cystic fibrosis

Intussusception

Cystic fibrosis screening

ABSTRACT

The presentation of intussusception leading to the diagnosis of cystic fibrosis is rare, with only a limited number of cases previously reported in the literature. We encountered such a case which describes a unique clinical presentation of intussusception providing a broad discussion of the disease and its pathophysiology. Although statewide screening programs have been created, cystic fibrosis can still go undiagnosed until late childhood.

Published by Elsevier Inc. This is an open access article under the CC BY-NC-ND license (<http://creativecommons.org/licenses/by-nc-nd/4.0/>).

We recently encountered a rare case of an 8-year-old boy presenting with intussusception leading to the diagnosis of cystic fibrosis although he had previous significant clinical symptoms. Historically, the incidence of cystic fibrosis is 1:2500 births. Intussusception occurs in cystic fibrosis patients with average age of onset of 9–9.5 years with 1–2% developing intussusception in their lifetime [1]. In a review of the Cystic Fibrosis Foundation national patient registry, the author reports 96 out of 20,096 (0.005%) patients with intussusception as a primary, yet unusual, presentation [2].

1. Case report

An 8-year-old boy had a two day history of intermittent right upper and lower quadrant pain. The boy did not have bloody stool, nausea, or vomiting. Physical examination revealed voluntary guarding in the right side of abdomen with localized tenderness.

He had a life-long history of both pulmonary and gastrointestinal conditions. He had a history of poor weight gain with a body mass index (BMI) less than the 50th percentile. Since birth, he had been treated for colds, sinus infections, and otitis media approximately three times per year with resolution via outpatient therapy.

His gastrointestinal history includes hospital evaluation for stool impaction and constipation and chronic hunger every two to three hours. The patient's mother reported he had flocculent and very odoriferous stools with an oil sheen and orange-ish color that clogs the toilet at times.

A computed topography (CT) scan was performed showing a dilated appendix with peri-appendiceal inflammatory stranding, ileocolic intussusception, bronchiectasis of the right middle lobe and lingula, and almost entire fatty replacement of the pancreas (Fig. 1).

He underwent water-soluble contrast enema hydrostatic reduction with resolution of the intussusception and instant pain relief. His diet was advanced and he was discharged home the following day (Fig. 2).

Because of his CT scan findings and impressive GI and pulmonary history, he underwent DNA and sweat chloride testing for cystic fibrosis. The diagnosis was confirmed and treatment was initiated with pulmonary toilet and pancreatic enzyme replacement. He did not have recurrence of the intussusception.

2. Discussion

Our patient was born in 2005, three years before routine newborn testing became a statewide mandate. Without early diagnosis of cystic fibrosis, it can lead to failure to thrive and chronic upper respiratory infections. Newborn screening and early diagnosis improves height and weight at least through

* Corresponding author. WVU Department of Surgery, P.O. Box 9238, Health Sciences Center, 1 Medical Center Drive, Morgantown, WV 26506-9238, USA. Tel.: +304 203 5524.

E-mail address: Pbonass3@hsc.wvu.edu (P.C. Bonasso).

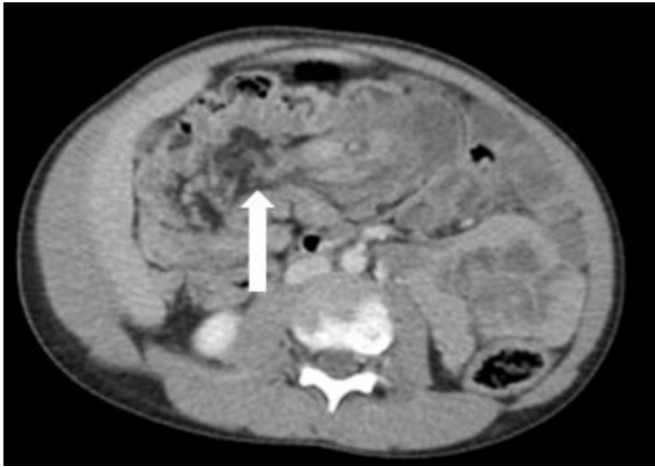


Fig. 1. White arrow: The pancreas (white arrows) shows fatty replacement with hypo-attenuation and tiny areas of residual glandular pancreatic tissue.

adolescence [3]. With early diagnosis, nutrition status is evaluated in these patients to help avoid severe nutritional complications of infancy including anemia from Vitamin E deficiency, zinc deficiency, linoleic acid deficiency, hypoelectrolytemia, and protein-calorie malnutrition [4].

Nationally, cystic fibrosis screening is a part of the Newborn screening (NBS) test. Screening is accomplished via determination of immunoreactive trypsinogen (IRT) concentrations from dried blood spots. IRT is high in CF infants due to leakage of protein into the circulation after exocrine pancreatic injury. When the IRT is high initially, the second step is to perform a DNA mutation analysis from the dried blood spot for a set of CF mutations or recheck IRT concentration is 2–3 weeks depending on which state the baby is born.

Our case describes a patient presenting with intussusception and an extensive gastrointestinal and pulmonary history. These clinical findings lead to the diagnosis of cystic fibrosis. The

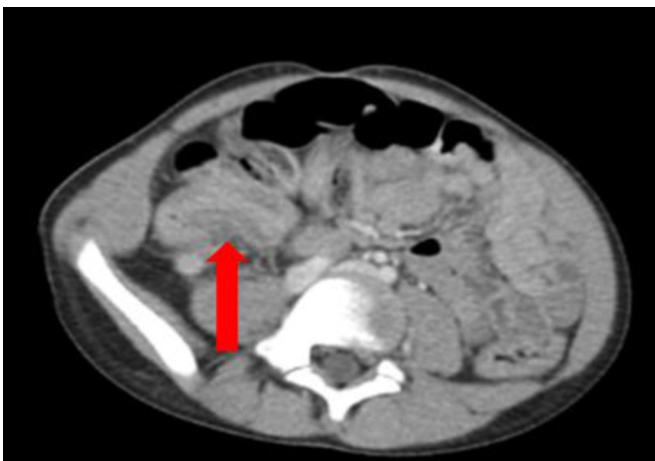

Fig. 2. Red arrow: The terminal ileum with intussusception.

development of intussusception in healthy children is an infrequent occurrence with an incidence of approximately 1.5–4:1000 [1]. The ileocolic subtype is the most common. Intussusception has been historically described as “telescoping” of the intestine. There is risk for bowel ischemia due to compromise of blood supply. Patients commonly present with abdominal pain and symptoms of small bowel obstruction. In children, the cause is often unknown while in adults, although rare, commonly is due to an underlying medical condition. The peak incidence is at 2 years. The pathophysiology of intussusception differs between healthy children and children with CF. Healthy children develop intussusception secondary to hypertrophy of the submucosal lymphoid tissues (Peyer’s patches) while children with CF develop intussusception secondary to inspissated feces [5]. Clinical history and physical examination becomes essential to determine if testing for cystic fibrosis indicated in children with intussusception.

When first evaluating a child for idiopathic intussusception, clinical exam and history create suspicion of the diagnosis. Limiting radiation exposure, Ultrasound is the imaging of choice showing the classical target or bull-eye sign. Some children also have an abdominal x-ray revealing intestinal obstruction. Treatment is performing an air or barium enema to both diagnosis and treat. In older children with suspected intussusception, further imaging such as CT scan may be required for a definitive diagnosis due to its rare late presentation. CT scan will show duplicated layering of bowel with formation of concentric rings.

3. Conclusion

Cystic fibrosis may go undetected at birth and present clinically in older children with idiopathic intussusception. Standard CT scan imaging of a patient presenting with acute abdominal pain can aid the diagnosis of cystic fibrosis. The rare diagnosis must still be thought of during surgical evaluation even when a clinical diagnosis has previously not been made.

Conflicts of interest

None.

Acknowledgments

I would like to acknowledge the West Virginia University Health Sciences Library for providing access to reference articles.

References

- [1] Holsclaw DS, Rocmans C, Shwachman H. Intussusception in patients with cystic fibrosis. *Pediatrics* 1971;48(1):51–8.
- [2] Rosenstein BJ. What is cystic fibrosis diagnosis? *Clin Chest Med* 1998;19(3):423–41.
- [3] Farrell PM, Kosorok MR, Rock MJ, Laxova A, Zeng L, Lai HC, et al. Early diagnosis of cystic fibrosis through neonatal screening prevents severe malnutrition and improves long-term growth. Wisconsin Cystic Fibrosis Neonatal Screening Study Group. *Pediatrics* 2001;107:1–13.
- [4] Merelle ME, Huisman J, Alderden-van der Vecht A, Taat F, Bezemer D, Griffioen RW, et al. Early versus late diagnosis: psychological impact on parents of children with cystic fibrosis. *Pediatrics* 2003;111:346–50.
- [5] Chaun H. Colonic disorders in adult cystic fibrosis. *Can J Gastroenterol* 2001;15:586–90.