

CARDIAC VALVAR REPLACEMENT IN SHEEP – DESCRIPTION OF SURGICAL TECHNIQUE AND OUTCOME

(Substituição valvar cardíaca em ovinos – Descrição da técnica operatória e análise dos resultados)

SILLAS, T.¹; COSTA, F. D. A.²; VILANI, R. O.²; SOUZA, F. P.³; VEIGA, S. L.⁴;
DOHMEN, P. M.⁵; WOUK, A. F. P. F.²

¹ Mestre em Ciências Veterinárias Universidade Federal do Paraná (UFPR).

² Departamento de Medicina Veterinária UFPR

³ PUC-PR. Disciplina de Clínica Médica e Cirúrgica de Animais de Fazenda

⁴ Médico Cirurgião Cardiovascular do Serviço de Cirurgia Cardíaca da Santa Casa de Misericórdia da PUC-PR.

⁵ Médico Cirurgião Cardiovascular e Pesquisador da Charité Humboldt University – Berlin

RESUMO – Visando avaliar um protocolo experimental de pesquisa com próteses valvares cardíacas em ovinos, as técnicas cirúrgicas de substituição valvar pulmonar, aórtica e mitral de 58 cirurgias cardíacas foram analisadas. Através de procedimentos padronizados os ovinos (idade 18 ± 7 semanas e o peso 30 ± 9.9 kg) foram submetidos ao implante de próteses valvares biológicas. Quarenta animais receberam próteses valvares pulmonares, 14 animais receberam próteses aórticas e quatro animais receberam próteses mitrais. O quarto espaço inter-costal foi considerado de eleição para realização das três técnicas operatórias avaliadas. O método de circulação extracorpórea (CPB) por canulação da aorta descendente e do átrio direito foi considerado rápido e seguro. O tempo de CPB durante a substituição valvar pulmonar foi de 34 ± 14 minutos e a mortalidade 7,5%. A substituição valvar aórtica, com implante subcoronariano, teve tempo de CPB 119 ± 5 minutos e mortalidade de 57%. Durante a substituição valvar mitral o tempo de CPB foi 74 ± 22 minutos e mortalidade 50%. A técnica de implante valvar pulmonar foi muito eficiente, entretanto a alta mortalidade das técnicas de implante valvar aórtico e mitral, associadas à maior complexidade cirúrgica e elevado tempo de CPB, faz necessário refinamentos técnicos para melhorar o aproveitamento dos animais nas cirurgias das valvas cardíacas esquerdas

Palavras-chave: Cirurgia, cardiovascular, experimental, ovelhas.

ABSTRACT – To evaluate the technical procedures of a research protocol with tissue-engineered heart valves in sheep, the surgical techniques for pulmonic, aortic and mitral valve replacement and the outcome of 58 heart valve surgeries was analyzed. The sheeps (age 18 ± 7 weeks and body weigh 30 ± 9.9 kg) were implanted with valve bioprosthesis under standard protocols. Forty animals received pulmonic valve prosthesis, fourteen animals received aortic prosthesis and four animals were implanted with mitral prosthesis. The fourth intercostal space were considered the best for all operative techniques. The cardiopulmonary bypass (CPB) method through canulation of descending aorta and right atrial were considered fast and secure. The CPB time of pulmonic valve replacement was 34 ± 14 minutes and mortality rate was 7,5%. The CPB time of subcoronarian aortic valve implantation was 119 ± 5 minutes and the mortality rate was 57%. In mitral substitution the CPB time was 74 ± 22 minutes and mortality was 50%. The technique of pulmonic valve replacement was very efficient, however the mortality rate of both aortic and mitral valve surgery, associated with the highly surgical technical complexity and elevated CPB time, require technical refinements to improve exploitation of the animals on the left side cardiac surgeries.

Key words: Surgery, cardiovascular, experimental, ovine.

INTRODUCTION

The conservative surgical treatment of heart valve diseases may be used for improvement of valvar function. Unfortunately, valvar replacement is required when anomalies and degenerative process can't be corrected with valve plastics. (BODNAR and ROSS, 1981) In spite of considerable evolution of the surgical results, the replacement of cardiac valves remains challenging, because there isn't a perfect prosthesis available to substitute the natural valves.

The research of new designed valvar prosthesis and their structural biological materials requires the implantation of these in animals that resemble the hemodynamic conditions of humans. The utilization of ovines in cardiac surgery was initially done as an alternative model motivated by "antivivisectionist" movement that refutes the use of dogs in research. The advantages encountered in ovines include the better tolerance to cardiopulmonary bypass (CPB), low rate of sepsis, easy handling and permissive behavior under laboratorial conditions. The sheep is also considered a challenge model to test calcification of new circulatory bioprosthesis. (OZAKI, *et al.*, 2004)

Currently, the ovine model is extensively used for experimental studies in heart failure, coronary and valvar surgery. (GHANTA *et al.*, 2007; MASELLI *et al.*, 2006; RESETAR *et al.*, 2007) The surgical procedure of valve replacement in sheep is crucial for research of new designed valves, evaluate bio-integration of decellularized and re-endothelialized valves and the capability of acellular bioprosthetic heart valve to be more durable. (LICHTENBERG *et al.*, 2006)

To establish and evaluate the technical procedures of advanced research protocol with tissue-engineered heart valves, this study sought to describe the results of a standard pre-operative, anesthetic, trans-operative and post-operative protocol and outcome of pulmonic, mitral and aortic valve replacement in sheep.

Material And Methods

The selected 58 mixed breed ovines (*Ovis aries*) aged between 18 ± 7 weeks were dewormed with ivermectine (0,2mg/kg/im) and confirmed health by clinical evaluation and complete blood count analysis. The sheep fastened for 36 hours before surgeries and received antibiotic therapy with ceftiofur (4,4mg/kg) and gentamicine (1mg/kg). The anesthetic pre-medications included butorphanol tartrate (0,4mg/kg/iv) and diazepam (0,5mg/kg/iv) and the induction of anesthesia was done with ketanine (10mg/kg/iv). The sheep was mechanically ventilated with 3% halothane

in oxygen and maintained with propofol (0,6mg/kg/min) during the CPB. Continuous electrocardiograph, oximetry, corporal temperature and arterial pressure were monitored during trans-operative period.

A total of 40 pulmonic, 14 aortic and four mitral valve bioprosthesis were implanted by left thoracotomy. Under sterile conditions, the skin incision was made from the medial point of the costal arch to near the sternum (ventro-lateral approach), like described previously by DOHMEN *et al.* (2005). The third or fourth intercostals spaces (ICS) were accessed with ligation and transection of the left mammary artery and vein. Before the pericardium manipulation 1mg/kg lidocaine and 250U/kg heparine was infused intravenously. The pericardiotomy was made like described by WOUK and PIPPI (1986), with a "T" shape incision with the long axis longitudinally.

The canulation for the CPB was made through a double purse string non-transfixating suture on descending aorta and simple purse string suture on right atrial auricle. The size of the arterial canula was 14 to 16 French and the venous canula was 34 French. The CPB was initiated in 50 – 70ml/kg/min (2 – 2,5L/min) and mild hypothermia (34-35°C) with a roller pump machine, 9mm arterial tubes, 12mm venous tubes, pediatric oxygenator and cardiomy reservoir with 3,7L. A prime volume was fixed in 900ml of saline solution in 100% oxygen.

Pulmonic valve replacement

Twenty eight valvar bioprosthesis were implanted on the right ventricle outflow tract (RVOT). The pulmonary artery was transected above the pulmonic valve. The leaflets of native pulmonary valve were excised and a portion of approximately two centimeters of pulmonary artery was resected. The implantation of the prosthetic valved tube was initiated by the distal anastomosis, with a continuous suture pattern, and finally completed by the proximal anastomosis, both with a cardiovascular polypropilene suture, with careful de-airing before circulation was restarted.

Aortic valve replacement

Fourteen bioprosthesis were implanted on the left ventricle outflow tract (LVOT). For aortic arch assessment a complete transections of the pulmonary trunk was made. After the root aortic occlusion an antegrade cardioplegy was performed. The aortic arch was transected above the valve region. A vent was used for preventing right ventricle distention. The native leaflets were excised. The antegrade cardioplegia was carried directly on the coronary ostiums each 15 minutes to maintain

assystoly. The endoluminal implantation was initiated with the proximal anastomosis and completed with the suture of the distal portion of the prosthesis around both coronary ostium (subcoronarian valvar implantation) with polipropilene 5-0. The replacement was finished by anastomosis of the aortic root and pulmonary trunk. A defibrillator was used to reverse the myocardial fibrillation.

Mitral valve replacement

It was used four valvar bioprosthesis in mitral position. The ascendant aorta was clamped and the anterograde cardioplegia of the aortic root was made and repeated each 15 minutes to cardiac arrest. The implantation was made through longitudinal left atriotomy and with a single interrupted suture or three continuous sutures around the annulus with polipropilene 4-0. A vent was used for preventing left ventricle distention. The atrium was closed with a single continuous polipropilene suture 6-0. The air inside the left atrium was removed and a defibrillator was used to reverse the myocardial fibrillation.

Thoracic closure and post-operative period

The pericardium was left unclosed in all animals. A chest tube was placed for continuous suction during the recovery of the animals. The thoracic closure was done in layers. All animals were kept in the surgical room until recovery of laryngeal reflex, body temperature and capability to stand alone. After the recovery, the animal were maintained in small

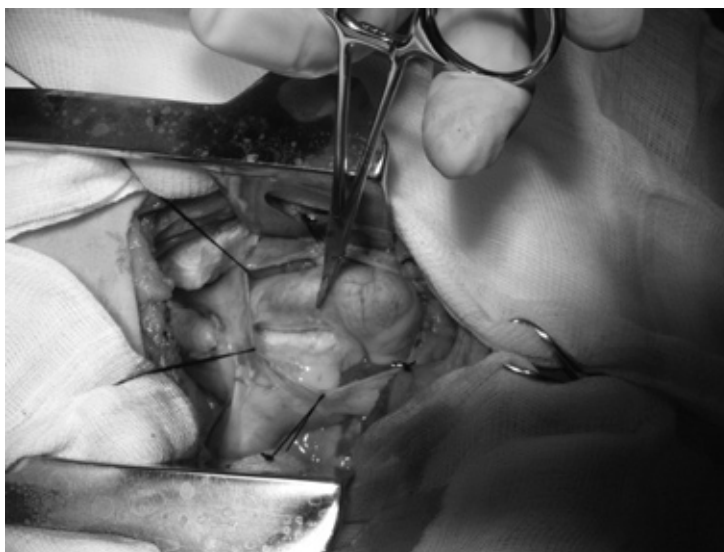
areas with pasture, and dairy clinical examination and medication that included flunixin meglumine (0,5mg/kg/im/sid), butorphanol tartrate (0,5mg/kg/im/bid) during three days, and the antibiotics continued during seven days post-operatively. The observations of this study ended on 30th post-operative day and the ovines were maintained alive for different post-operative periods according other evaluation protocols.

Results And Discussion

There was gastric reflux or gastric timpanism (bloat) in 5,2% of the ovines (3/58). Others researchers used 12 hours of fasting and didn't described any complications, sugesting that prolonged fasting time improve gastric secretion and fermentation. (ALI *et al.*, 1996, SANTOS *et al.*, 2002)

The third and fourth ICS (intercostal space) were used, in 17,2% (10/58) and 82,7% (48/58) of the animals, respectively. The fourth ICS allowed an excellent centralization of the surgical field in all valvar replacements (FIGURE 1) and were described by other researchers. (CHEUNG *et al.*, 1999; JUTHIER *et al.*, 2006) The third ICS evidenced a decentralized operative field making the aortic canulation and the mitral and aortic valvar replacement more difficult. SHINOKA *et al.* (1995) also described the third ICS approach in sheep for pulmonary replacement. One of the animals was mistakenly accessed through the fifth ICS and this had to be converted for the fourth ICS for the valve replacement.

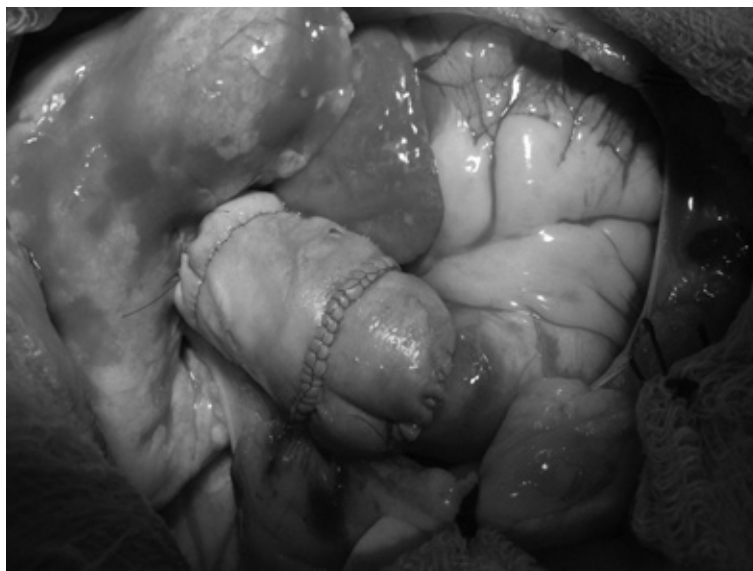
FIGURE 1– ASPECT OF THE PERICADIAL BED AND PULMONARY TRUNK IN SHEEP SUBMITTED TO VALVAR REPLACEMENT THROUGH THE LEFT 4TH INTERCOSTAL SPACE TORACOTOMY (CURITIBA, 2006)



The canulation of the right atrium (RA) and descendent aorta was effective for CPB. Insufficient venous drainage related to entrance of air into the RA occurred in 5.1% (3/58) and wrong positioning of the venous canula in 3,4% (2/58%) of the animals. Bleeding in aortic canulation (34,4%) were successfully controlled and resulted from difficulty in positioning the canula through the vascular punction orifice. Aortic dissection (invasion of blood between the vascular layers of the aortic wall) fatally occurred in one animal during a difficult aortic canulation. The hematocrit of five ovines evaluated diminished 20 to 30% during CPB with the fixed 900ml prime volume.

In the RVOT replacement the continuous suture pattern used in the proximal and distal anastomosis was considered fast and secure. (FIGURE 2) The main complication was residual bleeding in proximal and distal anastomosis, that happened in 92,5% of the animals (37/40) and was corrected by placement of additional single suture points. There was one case of uncontrolled bleeding from anastomosis (2,5% of the cases) on RVOT. The time of CPB during RVOT replacement was 34 ± 14 minutes. The intra-operative mortality of RVOT replacement was 7,5% (3/40). There was 5% of mortality related cardiac depression and persistent hypotension (2/40) and 2,5% related to uncontrolled bleeding on the anastomosis (1/40).

FIGURE 2 – FINAL ASPECT OF PULMONAR VALVE REPLACEMENT IN SHEEP (CURITIBA, 2006)



The complexity of the subcoronarian prosthetic LVOT replacement was related to the necessary pulmonary trunk transection (to access the aortic root) and the very small intraluminal field to suture the prosthesis. These two steps specially contribute to prolonged CPB time. All additional interurrences, like problems with the vent drainage were time consuming and potentially grave. Others researchers also mentioned difficulties in the visualization of aortic valve annulus after positioning the prosthesis inside the aortic root. (JOURDINAUD *et al.*, 2007) The CPB time of LVOT replacement was 119 ± 5 minutes, the aortic clamping time was 80 ± 11 minutes and 5 to 6 cardioplegias were made. The mortality of LVOT

replacement was 57% (8/14) and was related to ventricular fibrillation and asystolia in 50% (4/8) and cardiac depression and irresponsive hypotension in 50% (4/8).

The continuous suture was faster and technically easier compared to the simple suture in the mitral prosthesis implantation, however more insecure. (FIGURE 3) The CPB time of mitral valve was 74 ± 22 minutes, the aortic clamping time was 59 ± 13 minutes and 3 to 4 cardioplegias were made. (TABLE 1) The global mortality of mitral replacement was 50% (2/4), and was caused by the suture rupture in one animal and asystolia in other animal. (TABLE 2)

FIGURE 3 – FINAL ASPECT OF MITRAL VALVE REPLACEMENT IN SHEEP (CURITIBA, 2006)

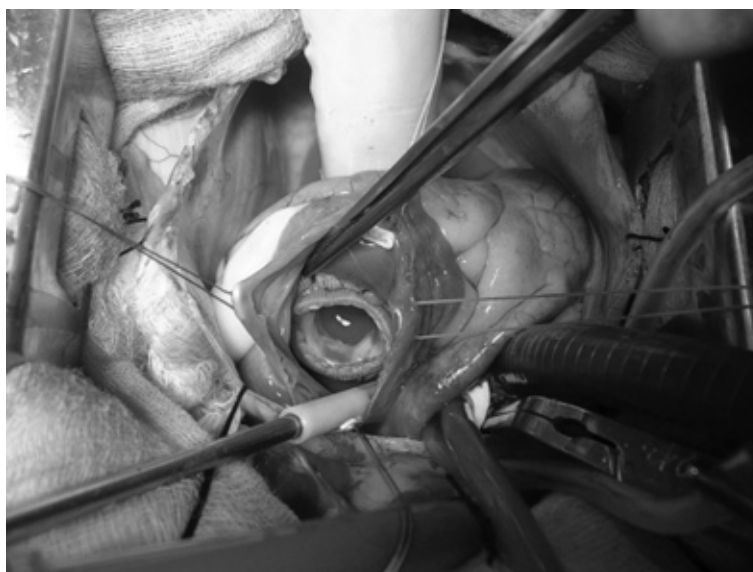


TABLE 1 – RELATIONSHIP BETWEEN CAUSES OF DEATH AND THREE VALVAR REPLACEMENT OPERATIVE TECHNIQUE IN SHEEP. (CURITIBA, 2006)

<i>Causa mortis</i>	<i>OPERATIVE TECHNIQUE</i>	OCURRENCE (%)
Aortic dissection	Arterial canulation	1,7 (1/58)
Bleeding	Pulmonar replacement	2,5 (1/40)
Suture rupture	Mitral replacement	25 (1/4)
Myocardial depression and low arterial pressure	Pulmonar replacement	5 (2/40)
	Aortic replacement	28 (4/14)
	Aortic replacement	28 (4/14)
Ventricular fibrillation and asytolia	Mitral replacement	25 (1/4)
	Pleural drainage	1,7 (1/58)

TABLE 2 – RELATIONSHIP BETWEEN INTRAOPERATIVE MORTALITY, GENERAL MORTALITY AND THREE VALVAR REPLACEMENT OPERATIVE TECHNIQUE IN SHEEP. (CURITIBA, 2006)

TECHNIQUE	DEATHS/ NUMBER OF OPERATIONS	MORTALITY RATE (%)
Pulmonary replacement	3/40	7,5
Aortic replacement	8/14	57
Mitral replacement	2/4	50
General mortality*	15/58	25,8

* The mortality rate includes two deaths not directly related to the valvar replacement operative technique. Endocarditis deaths were not included.

It was evident the strong influence of CPB time on mortality. (TABLE 3) The lower mortality rates of aortic valve replacement in sheep described by some authors were associated with lower CPB times. (SALERMO *et al.*, 1998) Nonetheless, other researchers that had longer CPB times had a mortality rate similar to the obtained in the aortic replacement of this experiment. (DAVID *et al.*, 1988) Other authors also obtained significantly lower mortality rate with a

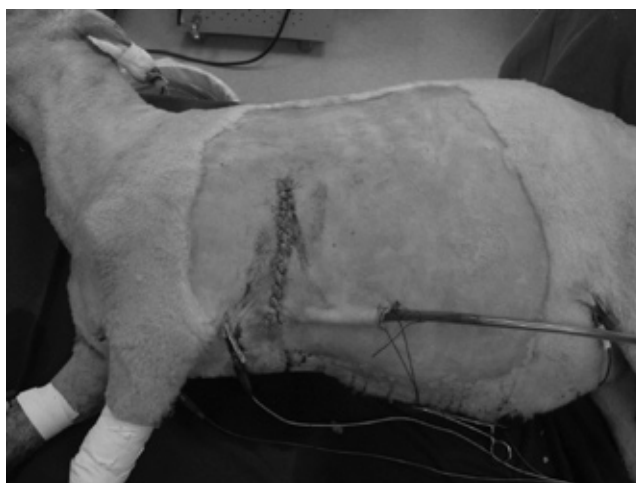
heart beating technique replacement of mitral valve in sheep, indicating that the prolonged CPB time and myocardial ischemia had also influenced the mortality. (ALI *et al.*, 1996)

The postoperative drainage during the anesthetic recovery was successful in 96,5% (56/58) the animals. (FIGURE 4) There were two cases of pneumothorax after tube removal, causing death of one animal.

TABLE 3 – RELATIONSHIP BETWEEN OPERATIVE TECHNIQUE, BYPASS TIME AND NUMBER OF CARDIOPLEGIAS IN VALVAR REPLACEMENT IN SHEEP. (CURITIBA, 2006)

VALVAR REPLACEMENT	BYPASS TIME (MINUTES)	NUMBER OF CARDIOPLEGIAS	MORTALITY (%)
Pulmonar	34 ± 14	----	7,5%
Aortic	119 ± 5	5-6	57%
Mitral	74 ± 22	3-4	50%

FIGURE 4 – FINAL ASPECT OF LEFT VENTROLATERAL THORACOTOMY APPROACH AND POSTOPERATIVE DRAINAGE IN SHEEP (CURITIBA, 2006)



CONCLUSIONS

The operative protocol used is very efficient for pulmonic valve replacement in sheep, although the surgical technique for aortic and mitral valve replacement has to be improved to diminish the CPB time and myocardial ischemic condition. Also, a highly trained team, including veterinary workup, specialized technician care and the improvement of the post-operative intensive care units are necessary to improve the exploitation of the animals on the left side cardiac surgeries.

REFERENCES

- ALI, M.L.; KUMAR, S.P.; BJORNSTAD, K.; DURAN, C. M. G. The sheep as an animal model for heart valve research. **Cardiovascular Surgery**. v.4, n.4, p.543-549, 1996.
- BODNAR,E.; ROSS,D. Valvular homografts. In: Bodnar E, Frate R. **Replacement cardiac valves**. New York: Pergamon Press. p.287-306, 1981.
- CHEUNG,D.T.; CHOO,S.J.; GROBE,A.C.; MARCHION,D.C.; LUO,H.H.; PANG,D.C.; FAVARA,B.E.; OURY,J.H.; DURAN,C.M.G. Behavior of vital and killed autologous pericardium in the descending aorta of sheep. **The Journal of Thoracic and Cardiovascular Surgery**, v. 118, p.998-1005, 1999.
- DAVID,T.E.; ROPCHAN,G.C.; BUTANY,J.W. Aortic valve replacement with stentless porcine bioprostheses. **Journal of Cardiac Surgery**. v. 3, p.501-505, 1988.
- DOHMEN,P.M.; DA COSTA,F.; LOPES,S.V.; YOSHI,S.; SOUZA,F.P.; VILANI,R.; DA COSTA,M.B.; KORNERTZ,W. Results of a Descellularized Porcine Heart Valve Implanted into the Juvenile Sheep Model. **The Heart Surgery Forum**. v.8, n.2, p.1140, 2005.
- GHANTA,R.K.; RANGARAJ,A.; UMAKANTHAN,R.; LEE,L.; LAURENCE,R.G.; FOX,J.A.; BOLMAN,R.M.; COHN, L.H.; CHEN,F.Y. Adjustable, physiological ventricular restraint improves left ventricular mechanics and reduces dilatation in an ovine model of chronic heart failure. **Circulation**. v. 115, n. 10, p. 1201-1210, 2007.
- JOUDINAUD,T.M.; FLECHER,E.M.; CURRY,J.W.; KEGEL,C.L.; WEBER,P.A., DURAN,C.M. Sutureless stented aortic valve implantation under direct vision: lessons from a negative experience in sheep. **Journal of Cardiac Surgery**, v.22, n. 1, p.13-17, 2007.
- JUTHIER,F.; VINCENTELLI,A.; GAUDRIC,J.; CORSEAUX,D.; FOUQUET,O.; CALET,C.; LE TOURNEAU,T.; SOENEN,V. Decellularized heart valve as a scaffold for in vivo recellularization: Deleterious effects of granulocyte colony-stimulating factor. **The Journal of Thoracic and Cardiovascular Surgery**. v. 131,n.4, p. 843-52, 2006
- LICHTENBERG,A.; TUDORACHE,I.; CEBOTARI,S.; SUPRUNOV,M.; TUDORACHE,G.; GOERLER,H.; PARK,J.K.; HILFIKER-KLEINER,D.; RINGES-LICHTENBERG,S.; KARCK,M.; BRANDES,G.; HILFIKER,A.; HAVERICH,A. Preclinical testing of tissue-engineered heart valves re-endothelialized under simulated physiological conditions. **Circulation**. v. 114, n.1, p. 1559-1565, 2006
- MASELLI,D.; GUARRACINO,F.; CHIARAMONTI,F.; MANGIA,F.; BORELLI,G.; MINZIONI,G. Percutaneous mitral annuloplasty: an anatomic study of human coronary sinus and its relation with mitral valve annulus and coronary arteries. **Circulation**. v. 114, n. 5, p.377-380, 2006.
- OZAKI,S.; HERIJGERS,P.; FLAMENG,W. A new model to test the calcification characteristics of bioprosthetic heart valves. **Annals of Thoracic and Cardiovascular Surgery**. v.10, n.1, p.23-28, 2004.
- RESETAR,M.E.; ULLMANN,C.; BROESKE,P.; LUDWIG-SCHINDLER,K.; DOLL,N.K.; SALAMEH,A.; DHEIN,S.; MOHR,F.W. Selective arterialization of a cardiac vein in a model of cardiac microangiopathy and macroangiopathy in sheep. **The Journal of Thoracic and Cardiovascular Surgery**. v. 133, v.5, p.1252-1256, 2007.
- SALERNO C. T. ; PEDERSON T. S. ; OUYANG D. W., BOLMAN R. M. 3rd, BIANCO R. W. Chronic evaluation of orthotopically implanted bileaflet mechanical aortic valves in adult domestic sheep. **Journal of Investigative Surgery**. v.11, p.341-347, 1998.

SANTOS,P.C. ; GEROLA,L.R. ; PESSA,C.J.N. ; BRANCO,J.N.R. ; CASAGRANDE,I. ; BUFFOLO,E. A juvenile sheep model for the stentless bioprostheses implanted as aortic root replacements. **Revista Brasileira de Cirurgia Cardiovascular.** v.17, n.1, p.90-98, 2002.

SHINOKA,T.; BREUER,C.K.; TANEL,R.E.; ZUND,G.; MIURA,T.; MA,P.X.; LANGER,R.; VACANTI,J.P.; MAYER,J.E. Tissue engineering heart valves: valve leaflet replacement study in a lamb model. **The Annals of Thoracic Surgery.** v. 60, n. 6, p.513-516, 1995.

WOUK,A.F.P.F; PIPPI,N.L. Totracotomia em Eqüinos. **Revista do Centro de Ciências Rurais.** v.16, n.3, p.251-272, 1986

Recebido para publicação: 12/12/2007
Aprovado: 25/05/2008