

RETINAL DEGENERATION IN A PIT BULL DOG: ELECTRORETINOGRAPHIC FINDINGS

(Aspectos eletrorretinográficos em um cão da raça Pit Bull)

SAFATLE, A.M.V.¹; SALOMÃO, S.R.²; BEREZOVSKY, A.²; SACAI, P.Y.²;
FANTONI, D.T.¹; YASBEK, K.V.¹; BARROS, P.S.M.¹

¹School of Veterinary Medicine, University of São Paulo, Brazil;

²Clinical Electrophysiology of Vision Laboratory, Department of Ophthalmology, Federal University of São Paulo, Brazil.

ABSTRACT – Electroretinogram (ERG) is a non-invasive electrophysiologic test widely used in both human and veterinary ophthalmology to evaluate retinal function. Case report: due to recent cases of severe visual impairment in Pit Bull dogs in our clinic, we decided to evaluate the retinal function by full-field ERG in a 5-month-old male Pit Bull dog whose owner have noticed visual impairment since 40 days of age. Under general anesthesia, the dog was submitted to full-field ERG testing, according to ISCEV (International Society for Clinical Electrophysiology of Vision) standard protocol. ERG recordings were obtained in one eye after 30 minutes of dark adaptation from a fully dilated pupil, using a monopolar contact lens electrode. Non-detectable scotopic and photopic responses were found, confirming the devastating effect of the retinal degeneration. Conclusion: ERG was able to quantify the severity of retinal degeneration on retinal function. We believe that heredogram study of these animals may be helpful to better understand this new retinal condition affecting Pit Bull dogs.

Key-words: electroretinography, dog, retinal degeneration, Pit Bull.

RESUMO – O eletrorretinograma (ERG) consiste em exame objetivo, não invasivo, capaz de avaliar a função retiniana tanto na oftalmologia humana como na veterinária. Caso Clínico: com o recente surgimento em São Paulo, de cães da raça Pit Bull apresentando déficit visual severo, optou-se por realizar ERG de campo total em um filhote macho, 5 meses de idade, com baixa de visão desde os 40 dias de idade, com intuito de avaliar sua função retiniana. O animal, sob anestesia geral, foi submetido ao ERG, segundo o protocolo padrão da ISCEV (International Society for Clinical Electrophysiology of Vision). Em um dos olhos foi adaptado eletrodo de lente de contato monopolar, após adaptação ao escuro por 30 minutos e dilatação completa da pupila. As respostas escotópicas e fotópicas mostraram-se não detectáveis, confirmando o efeito devastador da degeneração na função retiniana. Comentários conclusivos: o Erg foi capaz de detectar a severidade da degeneração retiniana e acredita-se que o estudo do heredograma destes animais possibilitará melhor compreensão desta nova doença.

Palavras-chave: eletrorretinografia, cão, degeneração retiniana, Pit Bull.

Introduction

Full-field electroretinogram is the complex record of electrical potentials that originate from the retina after photostimulation (BIRCH, 1989; BIRCH and ANDERSON, 1992; KOMAROMY *et al.*, 1998a). The ERG is obtained from the difference in potential between the corneal surface, through a contact lens electrode and the reference electrode which can be connected to the contact lens itself (bipolar lens) or to any other place of the skin, such as the frontal region or the ear lobe (monopolar lens) (PEREIRA *et al.*, 2003).

The importance of this method is due to the fact that it is an objective diagnostic method (TZEKOV and ARDEM, 1999), noninvasive, and capable to evaluate retinal function, making possible an early detection of lesions in the external retinal layers (CHAUDIEU and MOLON-NOBLOT, 2004). This diagnostic method has been widely used in both veterinary and human medicine. In human beings ERG is used in many conditions for the diagnosis of hereditary diseases such as retinitis pigmentosa (RP), to detect and follow the proliferative and nonproliferative retinopathy in the diabetic patient among other conditions (OFRI *et al.*, 1993). In veterinary medicine this method has shown itself of great importance in small animals, although it can also be used in large (KOMAROMY *et al.*, 2003) and exotic animals. In dogs ERG is mostly used for the preoperative evaluation of patients with cataract, for the characterization of disturbances that cause blindness such as glaucoma, retinal dysplasia, degenerative retinopathies, optic nerve hypoplasia, Sudden Acquired Retinal Degeneration (SARD) (KOMAROMY *et al.*, 1998b) and achromatopsia (HURN *et al.*; 2003). In cats ERG can be used for the diagnosis of retinal diseases such as hereditary retinal degeneration, noninflammatory retinopathy and central retinal degeneration caused by a lack of taurine in the diet (SIMS, 1999).

To carry out full-field ERG in human beings, it is advisable to follow the standard protocol defined by the International Society for Clinical Electrophysiology of Vision (ISCEV). In this protocol there are five responses to be registered through a fully dilated pupil after thirty

minutes of dark adaptation. The responses are: scotopic rod response, scotopic maximal response, scotopic response for oscillatory potentials, photopic single-flash cone response and photopic 30Hz flicker for cone response (MARMOR and ZRENNER, 1999).

Two types of ERG protocols are recommended for testing dogs: a simplified protocol to determine the retinal function before submitting the animal to cataract surgery and a more complex protocol with the purpose of diagnosing disturbances in the photoreceptor layer (NARSFSTRÖM *et al.*, 2002).

The latter is made up by the following responses: scotopic rod response, scotopic maximal response, photopic cone response and photopic flicker stimulus.

The first recorded response is the rod response recorded twenty minutes after dark adaptation with white light stimulus having its maximum intensity attenuated in 2.0 logarithmic units, with a neutral density filter and an interval of two seconds between stimuli (NARSFSTRÖM *et al.*, 2002). The second response, scotopic maximal response is obtained with high-intensity stimuli which contain both cones and rods responses. The stimulus is presented with the eye adapted to darkness and without the presence of background light with an interval of ten seconds between stimuli (NARSFSTRÖM *et al.*, 2002).

After ten minutes of light adaptation, the third response, which is the cone response is recorded. In this response the activity of the cones is isolated by means of a white background light with luminance of approximately 30 to 40 cd.m⁻². The stimulus intensity is maximum, with one second interval between stimulus. The last response, flicker stimulus, is obtained through an intermittent stimulus at minimum temporal frequency of 30 Hz and it is registered in the presence of background light with luminance of 30 cd.m⁻². With the purpose of reducing interference a frequency of 31Hz is recommended (NARSFSTRÖM *et al.*, 2002).

As the number of Pit Bull dogs has increased in São Paulo, we have observed a progressive visual deficit in young animals, which has led to blindness in the first months of life, without showing any signs of any other systemic

disease. Since literature is lacking about this breed visual deficit, we performed a full-field electroretinogram on a Pit Bull dog in order to help in the diagnosis of retinal degeneration.

Case Report

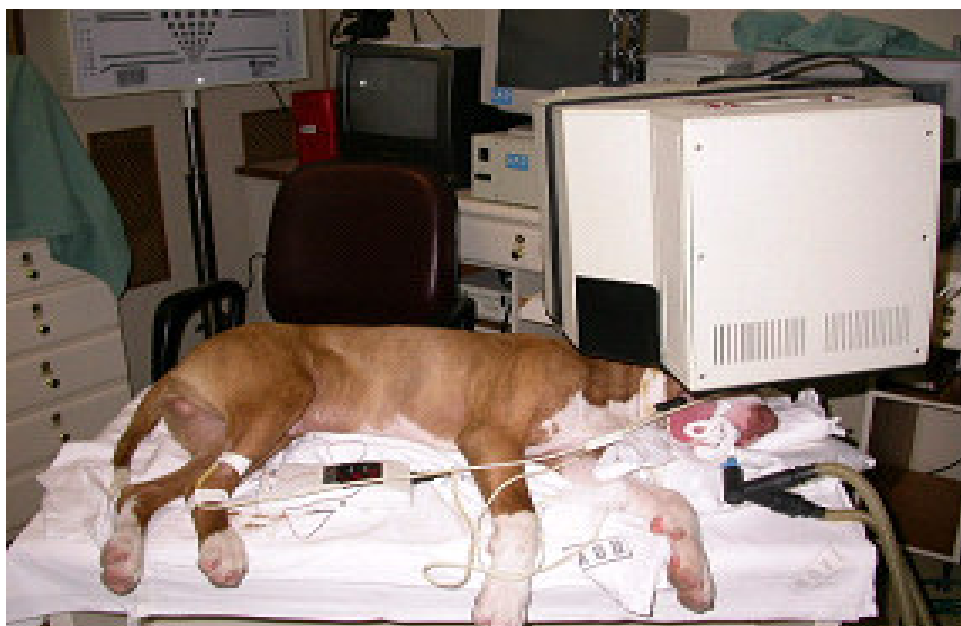A Pit Bull male dog, five months old, whose owner had detected blindness since the first forty days of life and with a family history of four brothers of the same litter also blind and with apparently normal parents, was referred to the Ophthalmology Service of the Department of Surgery of Veterinary Medicine Hospital, University of São Paulo.

At the ophthalmologic exam, the eyes presented calmness, the tear Schirmer (STT) test was $25\text{mm}\cdot\text{min}^{-1}$ in both eyes, the intraocular pressure (Tonopen XL Bio-rad - USA) was of 12 mmHg in both eyes, with a direct and consensual pupilar reflex to light diminished bilaterally. The clinical examination presented absence of threat reflex, incapacity to follow objects in movement as well as to overcome obstacles. When submitted to direct and indirect ophthalmoscopy, hyporeflexivity of tapetal retina in both eyes and discrete paleness of the

left optic disk with normal in caliber and number retinal vessels were noted, suggesting initial retinal atrophy. The ERG recording session was performed in the Clinical Electrophysiology of Vision Lab of the Department of Ophthalmology of Federal University of São Paulo – Paulista School of Medicine, São Paulo, Brazil.

The animal was withheld of food for eight hours and of liquids for two hours. Tropicamide 1% was used to dilate the pupils and the animal was sedated with acepromazine ($0.1\text{mg}/\text{kg}$) and pethidine ($2\text{mg}/\text{kg}$) both intramuscularly. The cephalic vein was cannulated and lactated Ringer's solution administered throughout the entire procedure at an infusion rate of $5\text{ml}\text{kg}^{-1}\text{hour}^{-1}$. Twenty minutes after premedication, induction of anesthesia was performed with propofol ($5\text{mg}\text{kg}^{-1}$) administered IV slowly in a single bolus. Orotracheal intubation was performed and 100% oxygen was offered through a rebreathing circuit of a small animal anesthesia machine and maintenance of anesthesia established with a continuous infusion of propofol ($0.5\text{mg}\cdot\text{kg}^{-1}\cdot\text{min}^{-1}$). To ensure that the ocular globe would stay centralized, rocuronium ($0.3\text{mg}\cdot\text{kg}^{-1}$) was administered.

FIGURE 1 – FULL FIELD ERG PROCEDURE IN A PIT BULL DOG.



All stimuli were presented in a Ganzfeld dome (LKC Technologies Inc., Gaithersburg, MD, USA), the inside of which was painted with a highly reflective white paint. The Ganzfeld dome was attached to a frame that allowed it to be lowered over the dog's head. Signals were amplified (gain, X10.000; 0.3-500 Hz), digitized, averaged, saved and displayed by a digital plotter (UTAS E-3000 System, LKC Technologies Inc., Gaithersburg, MD, USA). The animal was positioned in right lateral recumbence and with the aid of a support, the stimulation shade (Ganzfeld) was placed over the right eye. (FIGURE 1) After protecting the cornea with a 2% methylcellulose eyewash an ERG-jet monopolar contact lens was adapted. After the region has been clipped and cleaned, a reference electrode, previously filled with electrolytic gel was placed at the temporal canthus of the right eyelid, while the ground electrode also filled with electrolytic gel, was placed at the frontal region.

After thirty minutes of dark adaptation in a complete dark room, the procedure was performed according to the standard protocol recommended by the ISCEV, which is constituted of five responses: 1) scotopic rod response (average of 20) was the first signal measured after 30 minutes of dark adaptation, since it is the most sensitive to light adaptation. The stimulus was a dim white flash (0.00981 cd.s/m^2) derived from the standard flash (2.467 cd.s/m^2) by 2.4 log unit of attenuation. The low-pass filter was 0.3 Hz and the high-pass was 500Hz. 2) The maximal response (average of 10) is elicited by the white standard flash (2.467 cd.s/m^2) in dark-adapted eye and contains rod and cone response. The same band-pass filter was used. 3) The Oscillatory potentials (average of 20) were obtained by the maximal intensity white light with a 75Hz low-cut

and 500Hz high-cut filter. 4) The single-flash cone is achieved by the maximal intensity white light on a 30 cd/m^2 background presented at 1 HZ. 5) 30Hz to elicit only cone responses. A period of 10 minutes was allowed to adapt to the background light when collecting the cone responses. Ten to twenty responses were computer-averaged. The last response was 30-Hz flicker for which 50 trials were averaged. The stimulus was the standard flash (2.467 cd.s/m^2) in a light-adapted eye. The low-pass filter was 0.3 Hz and the high-pass was 500Hz. In order to standardize the exam, a previous procedure was performed in a four years old Dachshund dog, considered clinically and ophthalmologically healthy.

Results

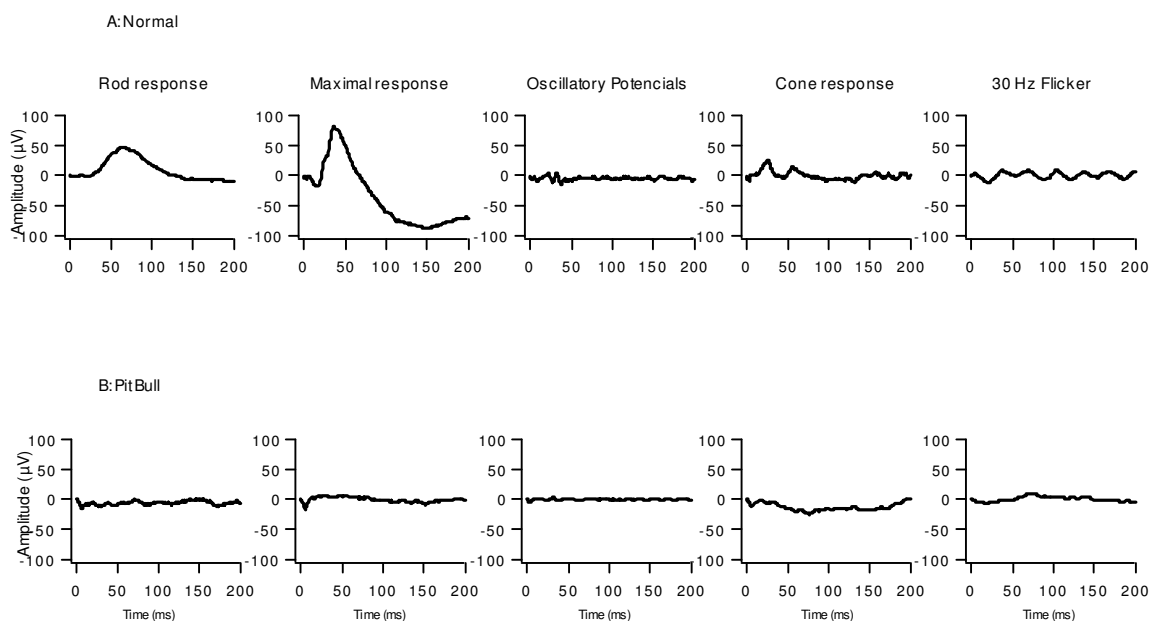
Non-detectable scotopic rod responses and scotopic maximal response were found in full-field ERG of this Pit Bull dog. Oscillatory potentials amplitude measured with the addition of OP wavelets was severely diminished ($10.4 \text{ } \mu\text{V}$). Related to cone function, single flash photopic cone responses were non-detectable with severely reduced amplitude ($6.7 \text{ } \mu\text{V}$) and prolonged b-wave implicit time (41.4 ms) for 30 Hz flicker.

For the healthy adult dachshund dog the ERG findings were: scotopic rod response - peak-to-peak amplitude was $45.9 \text{ } \mu\text{V}$ and the b-wave implicit time was 66.5 ms ; scotopic maximal response - peak-to-peak amplitude was $100.2 \text{ } \mu\text{V}$; oscillatory potentials - summed amplitude for OP wavelets was $49.6 \text{ } \mu\text{V}$; photopic single-flash cone response - peak-to-peak amplitude and the b-wave implicit time were $23.3 \text{ } \mu\text{V}$ and 26.0 ms respectively and the photopic 30 Hz flicker - amplitude was $15.0 \text{ } \mu\text{V}$ and the b-wave implicit time of 41 ms (FIGURE 2) (TABLE 1).

TABLE 1 – ELECTRORETINOGRAPHIC FINDINGS FROM A PIT BULL DOG WITH RETINAL DEGENERATION AND A HEALTHY DACHSHUND DOG.

	Pit Bull dog	Dachshund dog
Scotopic rod response	Non-detectable	Amplitude - $45.9 \text{ } \mu\text{V}$ b-wave implicit time - 66.5 ms
Scotopic maximal response	Non-detectable	Amplitude - $100.2 \text{ } \mu\text{V}$
Oscillatory potentials	$10.4 \text{ } \mu\text{V}$	$49.6 \text{ } \mu\text{V}$
Photopic cone response	Non-detectable	Amplitude - $23.3 \text{ } \mu\text{V}$ b-wave implicit time - 26.0 ms
30Hz flicker	Amplitude - $6.7 \text{ } \mu\text{V}$ b-wave implicit time - 41.4 ms	Amplitude - $15.0 \text{ } \mu\text{V}$ b-wave implicit time - 41.0 ms

FIGURE 2 – FULL-FIELD ERG RECORDINGS FROM A HEALTHY DASCHUND DOG (UPPER PANELS), AND A PIT BULL DOG WITH RETINAL DEGENERATION, FOR ROD, MAXIMAL RESPONSE, OSCILLATORY POTENTIALS, SINGLE-FLASH CONE AND 30 HZ-FLICKER.



Discussion

Full field ERG is an important diagnostic method either to confirm or to rule out retinal diseases. In veterinary medicine it has been indicated in the early diagnose of the progressive retinal atrophy (PRA), which is a hereditary degeneration of the photoreceptors layers, condition that is very similar to retinitis pigmentosa in man. For this reason, the dogs with PRA are used as spontaneous models and have been contributing with the study of the disease in human being (OFRI, 2002).

The literature showed that in more than twenty breeds of dogs, in which the disease has been studied with the electroretinogram, the changes in the ERG appear much earlier than the clinical signs, and in the great majority of the cases, the disease starts its manifestation when the animals are still pups. In this way it is possible to restrain the dissemination of the disease, avoiding breeding of the diseased animals (OFRI, 2002).

To our knowledge there is no citation in the literature of retinal degeneration with a hereditary character or related to the breed in the Pit Bull dogs, being the recognition in our environment quite recently.

The full-field ERG protocol that was used is

that recommended by the ISCEV for human beings, with is considered the more complete, making possible to obtain the five responses.

ERG responses were either non detectable or severely reduced, which confirms the severe retinal disturbance, affecting function of both rods and cones. However, by fundus ophthalmoscopy only, it was not possible to detect the degree of retinal impairment (CHAUDIEU and MOLON-NOBLOT, 2004).

On the other hand, with the ERG, which is a noninvasive objective exam it was possible to detect the severity of the retinal disturbance (TZEKOV and ARDEM, 1999).

ERG was able to quantify the severity of retinal degeneration on retinal function. We believe that heredogram study of these animals may be helpful to better understand this new retinal condition affecting Pit Bull dogs.

Conclusion

The ERG was able to quantify the severity of retinal impairment, confirming the retinal degeneration diagnosis in a Pit Bull dog with severe visual impairment. Further heredogram and follow-up studies of these animals might be helpful to the understanding of this new retinal disease.

Acknowledgment

The authors express appreciation to Dr Dennis Brooks and Dr Andras Komáromy for assistance. This paper was presented in a XXIII Ophthalmology Brazilian College Congress in 2003. Supported by FAPESP grant 97/11493-3 to S.R. Salomão.

REFERENCES

BIRCH, D.G. Clinical Electroretinography. **Ophthalmology Clinics of North America**, Philadelphia, v. 2, p. 469-497, 1989.

BIRCH, D.G.; ANDERSON, J.L. Standardized full-field electroretinography. **Archives of Ophthalmology**, Chicago, v. 110, p. 1571-1576, 1992.

CHAUDIEU, G.; MOLON-NOBLOT, S. Early retinopathy in the Bernese Mountain Dog in France: preliminary observations. **Veterinary Ophthalmology**, Oxford, v. 7, p. 175-182, 2004.

HURN, S.D.; HARDMAN, C.; STANLEY, R.G. Day-blindness in three dogs: clinical and electroretinographic findings. **Veterinary Ophthalmology**, Oxford, v. 6, p. 127-130, 2003.

KOMAROMY, A.M.; ANDREW, S.E.; SAPP JR., H.L.; BROOKS, D.E., DAWSON, W.W. Flash electroretinography in standing horses using DTL microfiber electrode. **Veterinary Ophthalmology**, Oxford, v. 6, p. 27-33, 2003.

KOMAROMY, A.M.; SMITH, P.J.; BROOKS, D.E. Electroretinography in dogs and cats. Part I: retinal morphology and physiology. **The Compendium on Continuing Education for the Practice Veterinarian**, Princeton Junction, v. 20, p. 343-354, 1998a.

KOMAROMY, A.M.; SMITH, P.J.; BROOKS, D.E. Electroretinography in dogs and cats. Part I: retinal morphology and physiology. **The Compendium on Continuing Education for the Practice Veterinarian**, Princeton Junction, v. 20, p. 355-366, 1998b.

MARMOR M.F.; ZRENNER E. Standard for clinical electroretinography (1999 up date). **Documenta Ophthalmologica**, Danvers, v. 97, p. 143-156, 1998-99.

NARSFSTRÖM, K.; EKESTEN, B.; ROSOLEN, S.G.; SPIESS, B.M.; PERCICOT, C.L.; OFRI, R. Guidelines for clinical electroretinography in the dog. **Documenta Ophthalmologica**, Danvers, v. 105, p. 83-92, 2002.

OFRI, R.; DAWSON, W.W.; FOLI, K.; GELATT, K.N. Chronic ocular hypertension alters local retinal responsiveness. **British Journal of Ophthalmology**, London, v. 77, p. 502-508, 1993.

OFRI, R. Clinical electrophysiology in veterinary ophthalmology – the past, present and future. **Documenta Ophthalmologica**, Danvers, v. 104, p. 5-16, 2002.

PEREIRA, J.M.; MENDIETA, L.; SACAI, P.Y.; SALOMÃO, S.R.; BEREZOVSKY, A. Estudo normativo do eletrorretinograma de campo total em adultos jovens. **Arquivos Brasileiros de Oftalmologia**, São Paulo, v. 66, p. 137-144, 2003.

SIMS, M.H. Electrodiagnostic evaluation of vision. In: **VETERINARY ophthalmology**. 3rd ed. Baltimore: Lippincott Williams e Wilkins, 1999. p. 483-507.

TZEKOV, R.; ARDEM, G.B. The electrretinogram in diabetic retinopathy. **Survey of Ophthalmology**, Brookline, v. 44, p. 53-60, 1999.

Recebido para publicação: 07/07/2005
Aprovado: 10/10/2005