

**TRANSRECTAL ULTRASONOGRAPHY FOR EARLY PREGNANCY DETERMINATION
IN SARDA BREED LAMBS*****Ultrasonografia transretal para determinação de gestação precoce em borregas da
raça Sarda*****FERRARI, M.V.¹; CATONE, G.²; GIARDINA, P.²; PETRALIA, P.²;
FERRARI, L.D.R.¹**¹ Universidade Federal do Paraná, Curitiba/PR, Brazil.² Università di Camerino, Italy.Corresponding author: Marcos Vinicius Ferrari: vargasferrari@gmail.com**ABSTRACT**

Serial transrectal ultrasound examinations were performed to determine the earliest day at which pregnancy could be detected after mating, as well as to determine the feasibility of the method, at normal flock management conditions without previous fasting and water restriction. Transrectal ultrasonography was carried out daily from day 12th to 25th and once on day 35th after breeding in Sarda breed yearling ewe lambs. The feasibility of the method was evaluated in terms of necessity or not to remove rectal feces during examinations, adequacy to perform examination due to rectal conditions (gases, edema, etc.), adequacy to visualize uterine and ovarian structures and to make accurate pregnancy diagnosis based on uterine findings. The experiment showed that transrectal ultrasound examinations can be suitably used for early pregnancy diagnosis in yearling ewe lambs, without the necessity of previous fasting, lifting the abdomen up and restraining the animals in recumbent position. The transrectal ultrasound method showed to be practicable during daily management of the flock, in terms of animal feeding, watering and staff availability.

Key words: diagnosis; feasibility; pregnancy; sheep; ultrasound**RESUMO**

Exames ultrasonográficos transretais em série foram realizados para determinar o primeiro dia no qual a gestação poderia ser diagnosticada após acasalamento, e para determinar a praticidade do uso do método, em condições normais de manejo dos animais sem prévio jejum e restrição de água. A ultrasonografia transretal foi feita diariamente desde o 12^o até o 25^o dias e uma vez no 35^o dia após acasalamento, em borregas de um ano de idade da raça Sarda. Os parâmetros utilizados para verificar a praticidade do método foram: a necessidade ou não de remover as fezes do reto durante os exames; a possibilidade de fazer o exame devido às condições retais (gases, edema, etc.); a visualização de estruturas uterinas e ovarianas; e a possibilidade de fazer acurado diagnóstico de gestação com base em achados uterinos. O experimento mostrou que a ultrasonografia transretal pode ser usada com sucesso no diagnóstico precoce da gestação em borregas, sem a necessidade de prévio jejum hídrico-alimentar, sem elevação do abdômen durante o exame e sem a necessidade de manter as borregas em decúbito dorsal. Verificou-se que o método é prático e pode ser utilizado já a partir do 16^o dia pós acasalamento para diagnóstico de gestação, durante o manejo normal e diário dos animais, em termos de alimentação e de disponibilidade de pessoal auxiliar.

Palavras-chave: diagnóstico; ecografia; gestação; ovino; praticidade

INTRODUCTION

Among the various methods proposed to perform pregnancy diagnosis and ovarian activity evaluation in sheep, real-time, B-mode transrectal ultrasound technique has showed to provide a highly accurate method for determining ovarian structures (Noel et al., 1993; Souza et al., 1997; Viñoles et al., 2004) and early-pregnancy diagnosis (Schrick and Inskeep, 1993). More recently, serial transrectal ultrasound examinations have been proposed as an efficient way to determine the development patterns of some fetal organs and parts in Ossimi sheep (Ali and Hayder, 2007). Reproductive ultrasound studies in sheep have gained importance as the pregnant sheep has been proposed as a model for human pregnancy (Barry and Anthony, 2008).

Early diagnosis of pregnancy is a fundamental tool for the success of sheep enterprise, allowing breeders to take important decisions on reproductive and commercial management of the flock. Briefly, transrectal scanning has been performed by introduction of the previous lubricated transducer into the rectum until bladder and uterine horn visualization, then followed by clockwise and counter-clockwise rotation of the transducer across the reproductive tract (Schrick et al., 1993). Practically, this technique has been performed in all experiments regarding transrectal ultrasonography in sheep. Variation on the method has regarded frequency of transducers (5-8 MHz) and management of animals previous and during ultrasound examinations.

To perform transrectal ultrasound technique, previous experiments have stated the necessity of keeping the females in dorsal recumbent position in tilting squeeze chutes (Schrick and Inskeep, 1993; Wurst et al., 2007), previous fasting (Karen et al., 2004), lifting the abdomen up (Karen et al., 2004; Ali and Hayder, 2007),

and emptying the rectum out of feces prior transducer insertion (Viñoles et al., 2004).

In terms of transducer frequency, use of 7,5 MHz transducer allowed the visualization of positive signs of pregnancy as early as on day 12 after mating, while visualization of extra-embryonic fluid, embryonic vesicles, embryo and fetal heartbeat was achieved from days 15 to 20 after mating (Schrick and Inskeep, 1993; Gonzalez et al., 1998; Ferrari et al., 2008a). With a 5 MHz transducer, first signs of pregnancy were observed on days 17-19 after breeding (Garcia et al., 1993; Doize et al., 1997), while embryo on day 25 (Buckrell et al., 1986).

Nevertheless, transrectal ultrasound method for early pregnancy diagnosis should be simple, reliable, no time-consuming, and practicable under normal farm management. To be accepted by breeders and used in large-scale flocks, transrectal ultrasound method should not bring difficulties to the daily management of the flock, in terms of animal feeding and staff availability.

Considering that yearling Sarda ewe lambs have a medium frame and a small body size (Assonapa, 2009) which could bring difficulties to perform early pregnancy diagnosis under field conditions, an evaluation of feasibility of transrectal ultrasound method was performed. Examinations were performed to determine the earliest day at which pregnancy could be detected, as well as to determine the practicability of the method at normal flock management conditions. Therefore, the practicability of the method was evaluated in terms of necessity or not to remove rectal feces during examinations, impossibility to perform examination due to rectal conditions, visualization of uterine and ovarian structures, and pregnancy diagnosis based on uterine findings.

MATERIAL AND METHODS

Animals and management

Sixty-three yearling Sarda ewe lambs which had estrus synchronized with intravaginal 40 mg FGA-sponges plus 400 IU of eCG were used in this study. Intravaginal sponges were removed after 12 days and eCG was administered *i.m.* at the moment of sponge withdrawal. All ewe lambs were kept together in the same pen. Fertile rams with a chest marker were introduced into the ewe lambs group 30 hours after sponge withdrawal. Day zero was considered as the day in which each ewe lamb was detected as effectively mated, by visualization of rump marks. To perform transrectal examinations, ewe lambs were restrained by neck with an adequate capture equipment used normally as a feeding facility, and kept in stationary position, with no previous fast or water restriction. All examinations started at 01:00 p.m., occasion on which all animals had already been fed in the morning as well as during the capture procedure.

Ultrasound procedure

Serial ultrasound examinations were carried out daily from days 12 to 25 and once on day 35 after mating in all ewe lambs mated. A real-time ultrasound scanner equipped with an 8 MHz linear array transducer (Titan®) was used in all examinations. After introduction of the lubricated transducer into the rectum, uterus and ovaries were scanned by careful rotational movements from outside, performed by a plastic rod taped to the transducer. Findings were diligently written in an apposite table.

Parameters evaluated

At each examination, were recorded the necessity to empty out the rectum and reinsert the transducer due to presence of rectal feces, the impossibility to perform ultrasound due to rectal conditions (gases or edema), uterus and bladder visualization, ovaries and ovarian structures

(follicles and corpora lutea), and visualization of uterine findings, like presence of extra-embryonic fluids, gestational sac, gestational membranes and embryo. During examinations, was considered and recorded the presence of these findings, as well as the diameter of the gestational sac and embryo heartbeat. Positive pregnancy diagnoses were ultimately confirmed by lambing records.

RESULTS

A total of 945 transrectal ultrasound scans were performed in all 63 ewe lambs (tab.1). Overall pregnancy rate, which was confirmed on day 35 and at lambing, was 65% (41/63). There was necessity to empty out the rectum and reinsert the transducer throughout all the experiment, at an average rate of 5,2% ($\pm 2,7$) of all examinations. It occurred due to a formation of a plug of feces around the transducer which not allowed adequate moving of it, therefore not allowing a good visualization of the structures. In the second day of examination (13th day), the vast majority of the ewe lambs showed an important rectal edema and tympanism, which not allowed the correct visualization of uterus and ovaries in 94% of examinations. However, from the third day (14th day) forward, there were no more cases of impossibility to perform transrectal examinations due to rectal conditions. On the other hand, apart from the examination of the 13th day, uterus and ovaries were suitably visualized in all animals in all occasions.

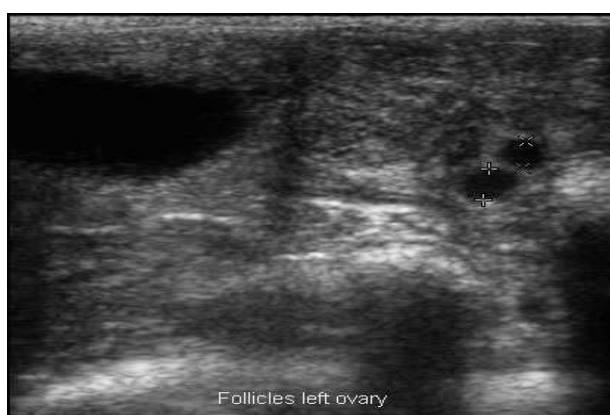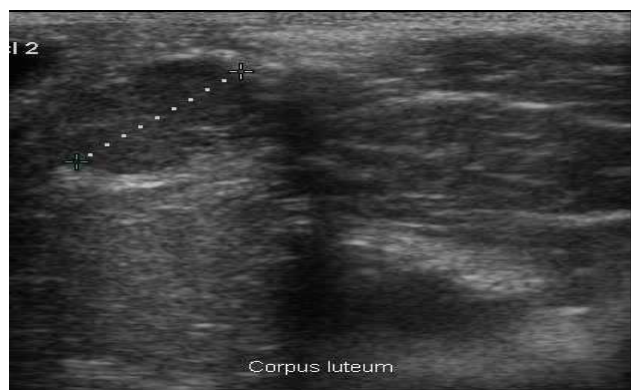
From day 12 to 15 after mating, was only possible to observe follicles (figure 1), corpora lutea (figure 2) and uterine folds, not being visualized any finding indicative of pregnancy except for the corpus luteum. Until the 15th day, there was no visualization of any uterine contents.

Extra-embryonic fluids (figure 3) were observed by day 16 in 31% (n=13) of ewe lambs and in 69% (n=29) of them by day

Table 1 - Results of transrectal ultrasound method for pregnancy in ewe lambs

Day after mating	Parameters evaluated (%)										Detected pregnancy	Correct positive pregnancy diagnosis	False positive pregnancy diagnosis
	A	B	C	D	E	F	G	H	I				
12	12	0	100	85	0	0	0	0	0	0	0	(ne)	(ne)
13	10	94	6	3	0	0	0	0	0	0	0	(ne)	(ne)
14	6	0	100	100	0	0	0	0	0	0	0	(ne)	(ne)
15	5	0	100	100	0	0	0	0	0	0	0	(ne)	(ne)
16	5	0	100	100	31	0	0	0	0	0	31	100	0
17	6	0	100	100	69	0	0	0	0	0	69	100	0
18	3	0	100	100	0	88	0	0	0	0	88	100	0
19	4	0	100	100	0	90	0	0	0	0	90	100	0
20	3	0	100	100	0	100	31	62	0	0	100	100	0
21	5	0	100	100	0	100	50	100	31	0	100	100	0
22	2	0	100	100	0	100	100	100	100	0	100	100	0
23	4	0	100	100	0	100	100	100	100	0	100	100	0
24	5	0	100	100	0	100	100	100	100	0	100	100	0
25	3	0	100	100	0	100	100	100	100	0	100	100	0
35	5	0	100	(ne)	(ne)	(ne)	(ne)	(ne)	(ne)	(ne)	100	100	0

A: necessity to empty out the rectum and reinsert the transducer; B: impossibility to perform examination due to rectal edema or gases; C: uterus and bladder visualization; D: ovaries and ovarian structures visualization; E: extra embryonic fluids; F: gravidic sac measurement; G: embryo heartbeat; H: embryo diameter measurement; I: fetal membrane presence; (ne): not evaluated.

Figure 1 - follicles on left ovary, 15th day.Figure 2 - two corpora lutea on right ovary, 15th day.

17. Based on these findings, correct positive pregnancy diagnosis was 100% on both days, as confirmed by the subsequent transrectal examination on day 35 and by lambing records. However, negative pregnancy diagnosis was not stated on these days of examination, therefore ewe lambs not showing extra-embryonic fluids were not diagnosed as not-pregnant, but rather as worthy of a new examination on subsequent days. Negative pregnancy diagnosis was only stated on day 35 and at lambing.

A clearly gestational sac was possible to be observed and measured in 88% of pregnant ewe lambs on day 18 and in 90% of them on day 19, with a positive pregnancy diagnosis rate of 100% from day 19 to 35 after mating in all ewe lambs diagnosed as pregnant. Fetal heartbeat was first detected on day 20 in 31% of pregnant ewe lambs, in 50% of them on day 21 and in 100% from this day to 35th after mating. Embryo diameter (figure 4) could be evaluated from day 20 in 62% of

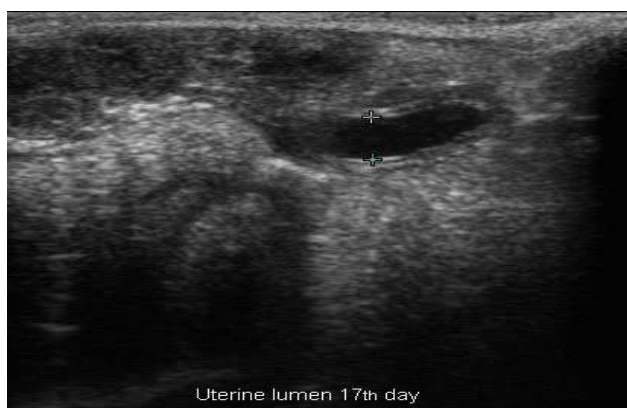

Figure 3 - Uterine extra-embryonic fluid, 17th day.

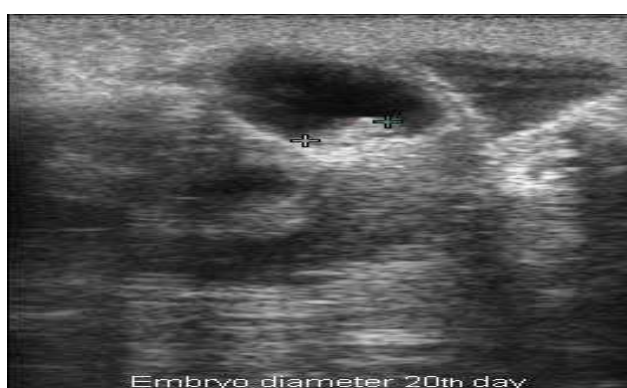


Figure 4 - Embryo diameter measurement – 20th day.

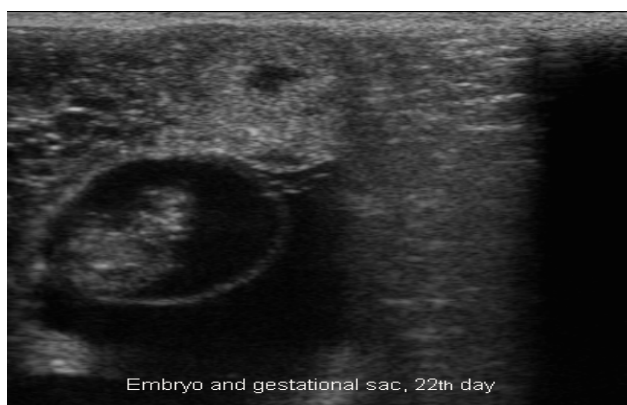

Figure 5 - Embryo and gestational sac visualization. 22nd day.

pregnant ewe lambs and in 100 % of them by day 21 forward.

Allantoid membrane and amniotic sac were clearly visible by days 21 and 22 (fig.5) and all pregnancies previously recorded were confirmed on day 35 after mating and at lambing.

DISCUSSION

Early diagnosis of pregnancy in sheep is crucial for adequate and economical management of farm exploitation, allowing separation of pregnant females and rebreeding non pregnant, as well improvement of feed management of the entire flock. However, methods used to detect early pregnancy need to be practical under field conditions, otherwise are not received as suitable by farmers and practitioners.

In spite of the importance of the authors whom have previously worked with transrectal ultrasonography, their proposed animal management could be impracticable under normal farm conditions, due to the necessity to alter normal feeding organization of the flock and necessity of more available farm-workers to help during ultrasound examinations. As well, due to be time-consuming, should be not suitable in large-scale farms. On the contrary, transrectal ultrasound method should provide a simple, rapid, accurate and non-invasive way to perform early-pregnancy diagnosis in sheep (Karen et al., 2001).

In this trial, results showed that performing transrectal ultrasonography in ewe lambs without previous fasting or lifting up the abdomen was an efficient method for early-pregnancy diagnosis. In the same way, keeping the animals in stand-stationary position, without the necessity of any special chute, was proved to be very practicable, neither time-consuming nor staff demanding. In terms of overall pregnancy rate percentage, results were considered as expected considering the age and breed of the animals, as well as the method for estrus synchronization used (Ferrari et al., 2008b) in this experiment.

Although the results showed that there was necessity to empty out the rectum throughout the experiment, a rate of only 5,2% was acceptable and proved to

be not time-consuming. In terms of findings, the results were very similar to those obtained by other authors using a 7,5 MHz transducer (Schrick and Inskeep, 1993; Gonzalez et al., 1998). In terms of accuracy of diagnosis, results obtained showed that from day 20th of examination all pregnant ewe lambs were detected, as confirmed by examination on day 35 and lambing records. On the other hand, some authors found greatest accuracy between days 25 and 35 after breeding (Schrick and Inskeep, 1993; Wurst et al., 2007).

CONCLUSION

Transrectal ultrasonography with an 8 MHz transducer can be used without the necessity of previous fasting, lifting the abdomen up and restraining the animals in recumbent position. For ovarian activity evaluation and early-pregnancy diagnosis, the method proved to be highly practicable under normal farm conditions, as the ovarian visualization and pregnancy diagnosis could be performed as early as 12 and 16 days after breeding, respectively.

REFERENCES

- ALI, A.; HAYDER, M. Ultrasonographic assessment of embryonic, fetal and placental development in Ossimi sheep. **Small Ruminant Research**, v.73, p.277-282, 2007.
- ASSOCIAZIONE NAZIONALE della PASTORIZIA - ASSONAPA. Disponível em: <<http://www.assonapa.com>>, Acesso em: 29/10/2009.
- BARRY, J.S.; ANTHONY, R.V. The pregnant sheep as a model for human pregnancy. **Theriogenology**, v.69, p.55-67, 2008.
- BUCKRELL, B.C.; BONNET, B.N.; JOHNSON, W.H. The use of real-time ultrasound rectally for early pregnancy diagnosis in sheep. **Theriogenology**, v.25, p.611-655, 1986.
- DOIZE, F.; VAILLANCOURT, D.; CARABIN, H. et al. Determination of gestational age in sheep and goats using transrectal ultrasonography measurement of placentomes. **Theriogenology**, v.48, p.449-460, 1997.
- FERRARI, M.V.; CATONE, G.; PETRALIA, P. et al. Feasibility of transrectal ultrasound method for determination of early pregnancy in Sarda breed lambs. **Reproduction in Domestic Animals**, v.43, n.2, p.75, 2008a.
- FERRARI, M.V.; CATONE, G.; BARONI, M. et al. Effectiveness of oestrus-induction treatments in Sarda breed lambs during non-breeding season. **Hungarian Veterinary Journal**, v.130, n.2, p.118, 2008b.
- GARCIA, A.; NEARY, M.K.; KELLY, G.R. et al. Accuracy of ultrasonography in early pregnancy diagnosis in the ewe. **Theriogenology**, v. 39, p.847-861, 1993.
- GONZÁLEZ, B.A.; SANTIAGO, M.J.; LOPEZ S.A. Estimation of fetal development in Manchega dairy ewes by transrectal ultrasonographic measurements. **Small Ruminant Research**, v. 27, p.243-250, 1998.
- KAREN, A.; KOVÁCS, P.; BECKERS, J. et al. Pregnancy diagnosis in sheep: review of the most practical methods. **Acta Veterinaria Brno**, v. 70, p.115-126, 2001.
- KAREN, A.; SZABADOS, K.; REICZIGEL, J. et al. Accuracy of transrectal ultrasonography for determination of pregnancy in sheep: effect of fasting and handling of the animals. **Theriogenology**, v.61, p.1291-1298, 2004.
- NOEL, B.; BISTER, J.L.; PAQUAY, R. Ovarian follicular dynamics in Suffolk ewes at different periods of the year. **Journal of Reproduction and Fertility**, v.99, p.695-700, 1993.
- SCHRICK, F.N.; INSKEEP, E.K. Determination of early pregnancy in ewes utilizing transrectal ultrasonography. **Theriogenology**, v.40, n.2, p.295-306, 1993.
- SCHRICK F.N.; SURFACE, R.A.; PRITCHARD, J.Y. et al. Ovarian structures during the estrous cycle and early pregnancy in ewes. **Biology of Reproduction**, v.49, p.1133-1140, 1993.
- SOUZA, C.J.H.; CAMPBELL, B.K.; BAIRD, D.T. Follicular dynamics and ovarian steroid secretion in sheep during the follicular and early luteal phases of the estrous cycle. **Biology and Reproduction**, v. 56, p.483-488, 1997.
- VIÑALES, C.; MEIKLE, A.; FORSBERG, M. Accuracy of evaluation of ovarian structures by transrectal ultrasonography in ewes. **Animal Reproduction Science**, v.80, p.69-79, 2004.
- WURST, A.K.; DIXON, A.B.; INSKEEP, E.K. Lack of effect of transrectal ultrasonography with restraint on lambing rate and prolificacy in ewes. **Theriogenology**, v. 68, p.1012-1016, 2007.