

ROMANIAN NEUROSURGERY

Vol. XXXIV | No. 2 June 2020

Malfunction of a ventriculoperitoneal
shunt during pregnancy. Two clinical
cases and literature review

Haidara A.,
Diallo O.,
Tokpa A.,
Nda H.A.,
Yao K.S.



Malfunction of a ventriculoperitoneal shunt during pregnancy. Two clinical cases and literature review

Haidara A.¹, Diallo O.², Tokpa A.¹, Nda H.A.³, Yao K.S.¹

¹ Department of Neurosurgery, Teaching Hospital of Bouaké, Bouaké, COTE D'IVOIRE

² Department of Neurosurgery, Hospital of MALI

³ Department of Neurosurgery, Teaching Hospital of Yopougon, Abidjan, COTE D'IVOIRE

ABSTRACT

Bringing a pregnancy to term is possible for a woman carrying a ventriculoperitoneal bypass valve, however, pregnancy can be a source of malfunction of the bypass system. We report two cases of malfunction of a VPS during the pregnancy's 3rd trimester in two patients aged 25 and 30 years respectively. The valve was examined in both cases and the persistence of the neurological signs required a cesarean section. The diagnostic aspects and management strategies were discussed as regards these two cases and throughout the literature review.

INTRODUCTION

Since the introduction of derivative CSF techniques in the treatment of hydrocephalus, the prognosis for children with this pathology has considerably improved [2,12,15,24,26] Bacterial meningitis is a common cause of morbidity in pediatric wards and constitutes the main aetiology of hydrocephalus occurrence [8.23]. With the development of neurosurgery in the past 20 years, many children are operated on from an early age and most often benefit from the establishment of a VPS. Today, many of these female children are of childbearing age. Malfunction can occur in 50% to 70% of women in labour with VPS, and doesn't necessarily mean anything in the development of future pregnancies. [18]. Treatment may be difficult and requires multidisciplinary collaboration between neurosurgeons, obstetrician-gynecologists-, and anaesthetists.

CLINICAL CASES

Case 1

A 25-year-old pregnant woman, second gesture and primiparous, was admitted to the gyneco-obstetrics emergency department for seizures

Keywords
malfunction,
pregnancy,
ventriculoperitoneal shunt



Corresponding author:
Tokpa André

Teaching Hospital of Bouaké,
Bouaké, Cote d'Ivoire

valentin_tokpa@yahoo.fr

Copyright and usage. This is an Open Access article, distributed under the terms of the Creative Commons Attribution Non-Commercial No Derivatives License (<https://creativecommons.org/licenses/by-nc-nd/4.0/>) which permits non-commercial re-use, distribution, and reproduction in any medium, provided the original work is unaltered and is properly cited.

The written permission of the Romanian Society of Neurosurgery must be obtained for commercial re-use or in order to create a derivative work.

ISSN online 2344-4959
© Romanian Society of
Neurosurgery



First published
June 2020 by
London Academic Publishing
www.lapub.co.uk

and impaired alertness. There was a record in the case of a VPS bypass performed at the age of 5 years for obstructive hydrocephalus. A previous pregnancy 5 years ago had been carried to term without incident. The physical examination revealed a Glasgow score of 11 without focal neurological deficit. The diagnosis of a pregnancy toxemia in the 3rd trimester was brought up. However, blood pressure and pulse were normal, blood sugar and proteinuria dosages were also normal. The obstetric examination found a pregnancy of 32 weeks of amenorrhea (WA), a uterine height (UH) at 29 cm in relation to gestational age, and fetal heart sounds (FHS) being normal. The VPS examination noted resistance to depression of the valve reservoir and the Cranio-cerebral CT scan showed dilation of the ventricular cavities with a ventricular drain in place (Figure 1). An evaluation of the VPS has been carried out. Removal of the peritoneal drain did not reveal any obstruction of the distal catheter, and it was reintroduced into the peritoneal cavity. The post-operative course was marked by a noteworthy improvement in the state of consciousness. The patient was kept under intensive care monitoring observation. A week later moderate signs of intracranial hypertension (ICHT) reappeared. A caesarean was performed at 34 WA. Upon extraction of the newborn, the peritoneal drain was found in the vesico-uterine pouch. After verifying its permeability and extensive washing of the operating site, the drain was replaced in the peritoneal cavity. The post-operative course was satisfactory for the mother and for the child throughout a follow-up of 15 months.

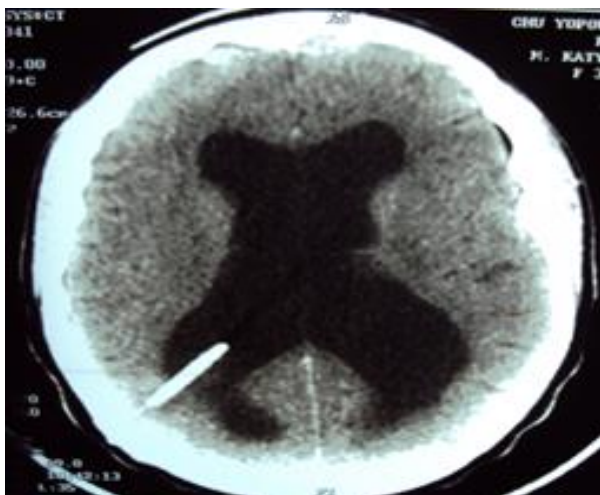


Figure 1. Head CT scan showing ventricular dilation.

Case 2

A 30-year-old pregnant woman, first gesture, consulted in neurosurgery for headache and visual disturbances having developed for a week during a pregnancy of 34 weeks. There was a record of VPS for post-meningitis hydrocephalus at the age of 6 years. A valve revision was performed at the age of 16 following a VPS malfunction and the patient had retained neurosensory sequelae with a significant decrease in visual acuity. Upon examination, the blood pressure was normal. The obstetrical examination found an UH at 30cm in relation to the gestational age and the fetal heart sounds were normal. The cranioencephalic scanner had shown dilation of the ventricular cavities. Given the worsening of neurological disorders with impaired alertness, a revision of the VPS was carried out. The peritoneal drain has been repositioned on the other side of the midline. The clinical improvement had been brief and the outcome on day two was marked by the onset of seizures and a new impairment of consciousness. An emergency Cesarean was performed with the extraction of a newborn with a good Apgar score. The development was marked by an improvement in consciousness but with permanent blindness in the mother.

DISCUSSION

Ventriculoperitoneal shunt remains the most widely used method for the treatment of hydrocephalus [18]. Its complications, which are most often mechanical and/or infectious, have been widely reported in the literature [1,3,4,7]. In pregnant women with a VPS, malfunction can occur in 50% to 70% of cases [2,18,20,26]. Furthermore, it is established that VPS has a higher incidence of fault during pregnancy than other types of leads [2,5,10,21,24,25,27]. It usually occurs during the pregnancy's 3rd trimester [2,5,18,26]. A summary of the cases reported in the literature is shown in Table 1. The mechanism for the occurrence of VPS malfunction remains still little understood [11]. The mechanism most often described would be the increase in intra-abdominal pressure due to the presence of the fetus, which would hinder resorption of CSF in the peritoneum [5,11,12,13]. The regression of symptoms observed in most series after childbirth is an argument in favor of this mechanism. The second hypothesis would be the compression of the catheter by a large uterus or a neighboring viscera

such as the stomach, bladder or liver [14,15]. In our 1st case, the peritoneal drain was wound in the vesico-uterine pouch. In our 2nd case, the malfunction is linked to a functional obstruction of the peritoneal catheter, probably related to the increase in intra-abdominal pressure. It has been noted by several authors that there is no correlation between the type of valve and the occurrence of the fault. [17, 20,21].

The classic clinical picture is the occurrence of signs of intracranial hypertension (ICHT) whose intensity is variable. These are usually isolated or associated with persistent headaches to vomiting or visual disturbances [11]. These signs can also be observed in pregnant women without VPS malfunction noted. In the series of Wishoff et al. [27], 59% of patients with VPS had signs of intracranial hypertension. The onset of drowsiness, confusion syndrome, blindness, or altered consciousness is evidence of the severity of intracranial hypertension. The occurrence of inaugural convulsive seizures as in our first case, or intense headache, can mimic the image of pre-eclampsia in the third trimester of pregnancy and mislead the diagnosis of valve malfunction [2,10,15,24]. A malfunction can be suspected through the revision of the VPS which sometimes displays resistance to the depression of the valve reservoir. However, the majority of current VPS systems are no longer equipped with a flexible CSF tank. The scanner and/or MRI, in the event of a malfunction, assesses the dilation of the ventricular cavities associated or not with transependymal resorption and erasure of the cortical grooves with a well-positioned ventricular drain. There is however a risk of irradiation of the fetus by X-rays [6,18]. Isotopic cisternography can diagnose the malfunction, but also risks fetal exposure to radioactive products [5, 6, 18,27]. MRI is the examination of choice because it does not involve any risk of fetal irradiation, and makes it possible to assess the hydrodynamics of the LCS on the flow sequences [2,6,13,18,27]. The problem is the existence of a shunt which is not compatible with MRI, and the deregulation of the drainage pressure by the magnetic field [9]. In our two cases, the scanner made it possible to diagnose the malfunction of the VPS.

The treatment of VPS malfunction during pregnancy requires a multidisciplinary collaboration between obstetrician-gynecologist,

anesthesiologist-resuscitator, and neurosurgeon. It must take into account gestational age, and especially the mother's neurological state. Valve overhaul is sometimes not necessary. Liakos et al [17], in their series, had respectively reported a rate of malfunction and valve revision of 13.7% and 5% among 138 pregnancies followed in 70 patients. When the neurological signs are moderate, a conservative treatment is proposed as a first intervention by several authors. [5,11,13,14,27]. The bed rest sometimes associated with a diuretic treatment such as furosemide or acetazolamide and the daily mechanical pumping of the valve reservoir when possible most often allow a regression of the symptoms of ICHT and allow to carry pregnancy to term. Mechanical pumping can be associated with regular suction of the valve reservoir [5, 11, 12]. However, we believe that this method, even if it can be effective in managing ICHT, carries a high risk of infection. In our 1st case, the change of site of the peritoneal drain allowed us to attain an acceptable period for childbirth. Hawg et al 2010, have advocated for the same approach. Rees et al made the change to the complete system although obstruction of catheter was not proven. Several authors argue for the conversion of VPS to VAS (ventriculoatrial shunt) in the event of malfunction [11,15,21,22,25]. The arguments proposed are the low rate of malfunction and neurological signs observed in the patients with a VAS during pregnancy. Sova et al [26] had proposed the externalisation of the peritoneal catheter until delivery, but this approach in our opinion increases the risk of infection. Endoscopic ventriculocisternostomy can be performed in case of VPS malfunction on obstructive hydrocephalus, and at the same time allows the complete removal of the defective bypass system [9,25]. The obstetric approach also depends on the neurological condition of the patient. In most of the series vaginal delivery is recommended [2,6,9,13,18]. On the other hand, in the event of significant neurological deterioration, a cesarean is necessary. In this case, the revision of the VPS can be carried out simultaneously.

Table 1. Summary of cases from the literature.

Authors	Maternal age (years)	Gestational age (WA)	symptoms	treatment	Type of birth	anaesthesia	outcome	
							mother	new-born
Freo et al [10]	35	36	coma	Shunt revision	Caesarean section	general	good	good
Hwang et al [13]	32	-	Headache and drowsiness	Shunt revision	Caesarean section	general	good	good
Cuisimano et al [5]	21	30	Headache and vomiting	Pumping and suction	Caesarean section	general	good	good
Houston et al [12]	26	33	Headache and nausea	suction	Vaginal delivery	No anaesthesia	good	good
Riffaud et al [25]	33	20	Headache, vomiting and visual disturbance	Ventriculocisternostomy and valve removal	Vaginal delivery	epidural anaesthesia	good	good
	26	15	Headache and visual disturbance	Ventriculocisternostomy and valve removal	Vaginal delivery	epidural anaesthesia	good	unspecified
	27	8	headache	Ventriculocisternostomy and valve removal	Vaginal delivery	epidural anaesthesia	good	good
Hanakita et al [11]	25	32	Headache, visual disturbance and alertness disorder	conversion of VPS to VAS	Vaginal delivery	No anaesthesia	good	good
Fletcher et al. [9]	32	36	Headache, amnesia and urination	Shunt revision	Caesarean section	general	good	good
Rees et al [24]	27	20	Convulsions and alertness disorder	Change of ventriculoperitoneal bypass device	abortion	No anaesthesia	good	bad
Sova et al [26]	27	27	Headache, diplopia and Parinaud	External ventricular drain	Caesarean section	general	good	good

			syndrome					
Murakami et al [21]	20	unspecified	Headache and visual disturbance	conversion of VPS to VAS	Vaginal delivery	epidural anaesthesia	good	good
Kleinman et al. [14]	20	29	Headache and vomiting	pumping	Vaginal delivery	No anaesthesia	good	good
Kurtsoy et al. [15]	34	31	Headache, vomiting and balance disorder	conversion of VPS to VAS	unspecified	unspecified	good	good

CONCLUSION

The treatment of a bypass malfunction during pregnancy is sometimes difficult. It requires close collaboration between neurosurgeons, obstetrician-gynecologists, and anaesthetists. Awareness of these different actors is necessary given the number of female children who have reached the reproductive age. The choice of ventriculocisternostomy in the treatment of hydrocephalus in children when it is indicated may allow avoiding the occurrence of this complication. It is also a treatment of choice when hydrocephalus or VPS malfunction occurs during pregnancy. In all cases, carrying out a pre, peri and post conceptual survey of patients with VPS is necessary.

REFERENCES

- Ahmed A, Sandlas G, Kothari P, Sarda D, Gupta A, Karkera P, Joshi P. Outcome analysis of shunt surgery in hydrocephalus. *J. Indian. Assoc. Pediatr. Surg.* 2009, 14 (3): 98-101.
- Bradley NK, Liakos AM, Mcallister JP, Magram G, Kinsman S, Bradley MK. Maternal shunt dependency: implications for obstetric care, neurosurgical management, and pregnancy outcomes and a review of selected Literature. *Neurosurgery.*1998, 43 (3): 448-60.
- Browd SR, Ragel BT, Gottfried ON, Kestle JR. Failure of cerebrospinal fluid shunts: part I : Obstruction and mechanical failure. *Pediatr. Neurol.* 2006, 34 (2),83-92.
- Browd SR, Ragel BT, Gottfried ON, Kestle JR. Failure of cérebrospinal fluid shunts: part II: over drainage, loculation, and abdominal complications. *Pediatr. Neurol.* 2006,34 (3):171-6.
- Cusimano MD, Meffe FM, Gentili F, Sermer M. Ventriculoperitoneal shunt malfunction during pregnancy. *Neurosurgery.* 1990,27(6):969-71.
- Cusimano MD, Meffe FM, Gentili F, Sermer M. 1991.Management of pregnant woman with cerebrospinal fluid shunt. *Pediatr. Neurosurg.*1991,92 (17):10-3.
- Drake JM, Kestle JR, Milner R, Cinalli G, Boop F, Piatt JJR, Haines S, Schiff SJ, Cochrane DD, Steinbok P, Macneil N.1998 Randomized trial of cerebrospinal fluid shunt valve design in pediatric hydrocephalus. *Neurosurgery.* 1998,43:294-303.
- Eholier Sp, Boni B, Aoussi E, Konan A, Orega M, Koffi A L, Ba Zézé V, Bissagnene E, Kadio A. Complications neurochirurgicales des méningites Purulentes en zone tropicale. *Neurochirurgie.* 1999,45(3):219-24.
- Fletcher H, Crandon lw, Webster D. Maternal Hydrocephalus in Pregnancy and Delivery: A Report of Two Cases. *West. Indian. med. J.*2007,56(6):558-9.
- Freo U, Pitton M, Carron M, Ori C. 2009.Anesthesia for urgent sequential ventriculoperitoneal shunt revision and cesarean delivery. *Int. j. obstet. Anesth.* 2009,18(3): 284-7.
- Hanakita J, Suzuki T, Yamamoto Y, Kinuta Y, Nishihara KJ. Ventriculoperitoneal shunt malfunction during pregnancy. *J Neurosurg.*1985, 63(3):459-60.
- Houston CS, Clein LJ. Ventriculoperitoneal shunt malfunction in a pregnant patient with meningomyelocele. *CMAJ.*1989,141(1):701-2.
- Hwang S.C, Tae-Hee K, Bum-Tae K, Soo-Bin I, Won-Han S. Acute Shunt Malfunction after Cesarean Section Delivery. *J. Korean. Med. Sci.*2010,25(4):647-50.
- Kleinman G, Sutherling W, Martinez M, Tabsh K. Malfunction of ventriculoperitoneal shunts during pregnancy. *Obstet Gynecol.* 1983,61(6):753-4.
- Kurtsoy A, Selçuklu A, Kemal Kr, Pasaoglu A, Kavuncu Al. Management of Maternal Hydrocephalus. *Turkish Neurosurgery.*1994,4:174-5.

16. Landwehr JB, JR, Isada NB, Pryde PG, Johnson MP, Evans MI, Canady AI. Maternal neurosurgical shunts and pregnancy outcome. *Obstet Gynecol.* 83(1):134-7.
17. Liakos AM, Bradley NK, Magram G, Muszynski C. Hydrocephalus and the reproductive health of women: the medical implications of maternal shunt dependency in 70 women and 138 pregnancies. *Neurol Res.* 2000,22(1):69-88.
18. Maheut-Lourmière J, Chu Tan S. Hydrocephalus during pregnancy with or without neurosurgical history in childhood. Practical advice for management *Neurochirurgie.* 2000,46 (2):117-21.
19. Monafared AH, Kee SK, Apuzzo MLJ, Collea JV. Obstetric management of pregnant woman with extracranial shunts. *Can. Med. Assoc. J.* 1979,120(5):562-3.
20. Mouelhi C, Srasra M, Zhioua F, Ferchiou M, Zine S, Meriah S. Maternal hydrocephaly and pregnancy. *Rev. Fr. Gynecol. Obstet.* 89(2):88-90.
21. Murakami M, Morine M, Iwasa T, Takahashi Y, Miyamoto T, Hon PK, Nakagawa Y. Management of maternal hydrocephalus requires replacement of ventriculoperitoneal shunt with ventriculoatrial shunt: a case report. *Arch. Gynecol.Obstet.* 2010,282 (3):339-42.
22. Okagaki A, Hanzaki H, Moritake K, Mori T. 1990. Case report: pregnant woman with a ventriculoperitoneal shunt to treat hydrocephalus. *Asia. Oceania. J.Obstet. Gynaecol.* 1990,16: 111-3.
23. Orega M, Eholier S P, Boni N, Konan A, Koffi A L. Méningites purulentes et complications neuro-chirurgicales chez l'enfant à Abidjan. *Médecine d'Afrique Noire.* 2005,52(4):251-2.
24. Rees GJ, Francis C, Sizer A R. Convulsions in an undiagnosed pregnancy due to blocked ventriculoperitoneal shunt. *J. Obstet. Gynaecol.* 2008,26(5), 533-4.
25. Riffaud L, Ferre, JC, Carsin-Nicol B, Morandi X. Endoscopic third ventriculostomy for the treatment of obstructive hydrocephalus during pregnancy. *Obstet. Gynecol.* 2006,108:801-4.
26. Sova M, Smrcka, M, Baudysova O, Gogela J Management of a shunt malfunction during pregnancy. *Bratisl Lek Listy.* 2001,102(12):562-3.
27. Wishoff JH, Kratzert KJ, Handwerker SM, Young BK, Epstein F. Pregnancy in patients with cerebrospinal fluid shunts: report of a series and review of the literature. *Neurosurgery.* 1991,29(6):827-31.