

ROMANIAN NEUROSURGERY

Vol. XXXIV | No. 2 June 2020

Presentation, management and
outcomes of pituitary adenomas. A 10-
year experience from a single tertiary
neurosurgery centre

Bogdan Ionut David,
Ligia Gabriela Tataranu,
Vasile Gheorghe Ciubotaru,
Aurelia Mihaela Sandu,
Radu Mircea Gorgan



Presentation, management and outcomes of pituitary adenomas. A 10-year experience from a single tertiary neurosurgery centre

Bogdan Ionut David^{1,3}, Ligia Gabriela Tataranu^{2,3},
Vasile Gheorghe Ciubotaru³, Aurelia Mihaela Sandu³, Radu Mircea Gorgan^{2,3}

¹ PhD Student. University of Medicine and Pharmacy "Carol Davila", Bucharest, ROMANIA

² University of Medicine and Pharmacy "Carol Davila", Bucharest, ROMANIA

³ Department of Neurosurgery, Emergency Clinical Hospital Bagdasar-Arseni, Bucharest, ROMANIA

ABSTRACT

Introduction: One of the most frequently encountered intracranial tumours are the pituitary adenomas, these accounting for 5% to 20%. Therapeutic strategies vary largely, from medical therapy to complex neurosurgical procedures. The transsphenoidal approach can solve most of the lesions of the pituitary area, as long as the invasion of the adjacent structures is not significant. The transcranial approach is indicated in tumours with extensive invasion

Materials and methods: We performed a retrospective study in the Bagdasar-Arseni Emergency Hospital Neurosurgery that aimed to analyze the demographics, signs and symptoms, therapeutic strategy, surgical approach, complications, and histopathology, from 2010 to 2019.

Results: The total number of hospitalization records, including the follow-up hospitalization and/or second surgery hospitalization, was of 1107. Furthermore, there were 704 unique patients. The most common signs and symptoms encountered for the first admission were headache (245 – 34.56%), optic chiasm deficits (153 – 21.58%), acromegaly (85 – 11.99%). However, the majority of patients (507 – 71.51%) presented with some sort of hormonal imbalance or diabetes insipidus. On the one hand, a number of 325 (45.84%) patients had non-surgical treatment. On the other hand, a total of 384 (54.16%) surgeries for pituitary tumours were performed in this period.

Discussion: In our study, the patients who underwent surgery benefited from either microsurgical transsphenoidal or transcranial surgeries. Even if the transsphenoidal approach was used far more, there was a greater relapse proportion in these patients. Transcranial surgery, even if followed by a far less proportion of relapse surgery, carried with it the burden of more days spent in hospital (most of the time twice as much as for the transsphenoidal patients).

Keywords

pituitary adenoma,
transcranial approach,
transsphenoidal approach



Corresponding author:
Bogdan Ionut David

University of Medicine and
Pharmacy "Carol Davila",
Bucharest, Romania

david.bogdan.med@gmail.com

Copyright and usage. This is an Open Access article, distributed under the terms of the Creative Commons Attribution Non-Commercial No Derivatives License (<https://creativecommons.org/licenses/by-nc-nd/4.0/>) which permits non-commercial re-use, distribution, and reproduction in any medium, provided the original work is unaltered and is properly cited.

The written permission of the Romanian Society of Neurosurgery must be obtained for commercial re-use or in order to create a derivative work.

ISSN online 2344-4959
© Romanian Society of
Neurosurgery



First published
June 2020 by
London Academic Publishing
www.lapub.co.uk

Conclusion: Both transsphenoidal and transcranial approaches have advantages and disadvantages, thus the best strategy would be to tailor each surgery to each patient, keeping an open mind to all available approaches

INTRODUCTION

One of the most frequently encountered intracranial tumors are the pituitary adenomas, these accounting for 5% to 20% of all tumor lesions at this level. Most of the developing countries of the world estimate an incidence of about 20 cases per 100.000 population (1), while European developed countries agree on 3,9-4 new cases per 100.000 people each year, the prevalence hovering between 78 and 94 cases per 100.000 people.

While most of the tumors that originate in the pituitary gland are usually benign, the behavior of these lesions can be unpredictable. Thus, one can encounter anything from clinically silent, indolent tumors, all the way to extremely aggressive malignancies. Therefore, a meticulous understanding of the anatomy of the area and also of the specific physiology of the hypothalamo-pituitary complex is mandatory. (2) The therapeutic strategies vary largely, from medical therapy to complex neurosurgical procedures, depending on the aforementioned characteristics of the lesions.

As far as signs and symptoms are concerned, these again vary according to the nature of the tumor and the local extension. The clinician has to look for hormonal dysfunction, visual field deficits, decreased visual acuity, anterior pituitary dysfunction and headache. (3) The usual therapeutic strategy is to try to medically manage any case. If this is not enough or neurological/hormonal deficits occur, the obvious step is taken towards surgical management. At this stage, the neurosurgeon has to decide which surgical approach and technique best tailors every case: transcranial, transsphenoidal microsurgical or transsphenoidal endoscopic, as well as any combined approach that he or she might find adequate.

Regarding surgical approach used, one must look back to the era of Schloffer (1907), Hirsch (1910s) and Cushing (1920s). They were the ones who paved the road for the transsphenoidal approach for pituitary lesions. However, in the first half of the 20th century, due to lack of antibiotic therapy, the results were dismal. Hence, Cushing abandoned the technique and favored the transcranial approach. However,

with introduction of the operating microscope, endoscope and development of powerful antibiotics, the transsphenoidal approach soon regained attention. Nowadays, there is a general consensus that the transsphenoidal approach can solve most of the lesions of the pituitary area, as long as the invasion of the adjacent structures is not significant. Furthermore, an experienced neurosurgeon, more familiar with the transcranial approach, will usually have similar results by using this method. Therefore, as long as the lesion permits both surgical strategies, it usually comes down to surgeon preferences and experience. Non the less, the more complex the lesion, the more surgeons prefer the transcranial approach. (3).

MATERIALS AND METHODS

This is a retrospective study conducted in the Bagdasar Arseni Emergency Hospital Neurosurgery Departments 3 and 4 that aims to analyze the demographics, signs and symptoms, therapeutic strategy, surgery approach used, complications associated with these approaches, histopathology of pituitary tumors, over the course of 10 years, from January 2010 to December 2019.

To keep in line with confidentiality agreements and laws, each patient was coded and the original identification was removed. Data was collected directly from the electronic patient charts by the primary author.

Data included in the study were age, gender, number of days of hospitalization, number of hospitalizations for each patient, signs, symptoms, type of surgery (approach used), perioperative complications (CSF leak, hematoma, neurological deficits) and also death within period of hospitalization.

In order to be included in the study, the patients had to have diagnosis of pituitary tumor, be of either gender, with no limit in regard to age. The patient had to had been inbound in one of either Neurosurgery 3 or 4 Department and have an outgoing diagnosis of pituitary adenoma. All patients presenting with other sellar or parasellar masses were excluded (such as craniopharyngioma, epidermoid cyst, anterior circulation aneurysm).

RESULTS

The study included all patients presenting with pituitary tumors between January 2010 and

December 2019 on either of Department 3 or 4 of Neurosurgery in Bagdasar Arseni Hospital, Bucharest. Thus, 1107 hospitalization records were taken into account, including the follow-up hospitalization and/or second surgery hospitalization. Furthermore, there were 704 unique patients (personal identification numbers were analyzed).

The gender distribution was 243 (34.27%) women and 466 (65.73%) men (figure 1), minimum age was 14 and maximum was 84, with a mean age of 56.24 (62.77 years old for women and 52.77 years old for men) (figure 2).

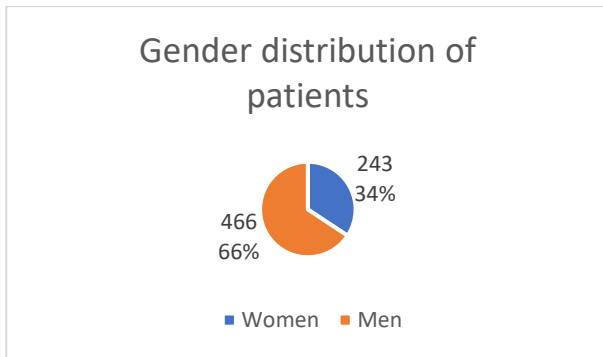


Figure 1.




Figure 2.

The most common signs and symptoms encountered for the first admission were headache (245 – 34.56%), optic chiasm deficits (153 – 21.58%), acromegaly (85 – 11.99%). However, the majority of patients (507 – 71.51%) presented with some sort of hormonal imbalance or diabetes insipidus (figure 3).

On the one hand, a number of 325 (45.84%) patients had non-surgical treatment: they were either referred to an Endocrinology Department to begin conservative treatment, or a "watchful waiting" ensued after the first radiological evaluation (figure 4).

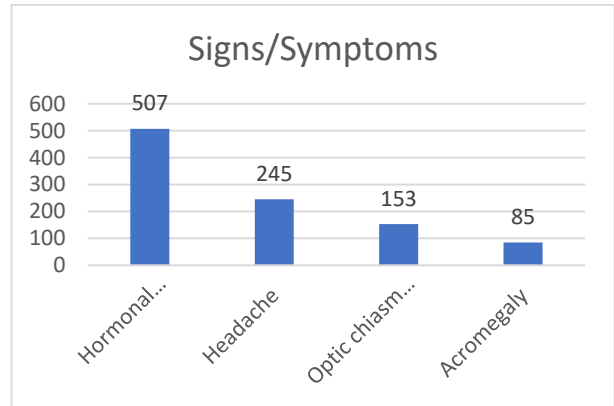


Figure 3.

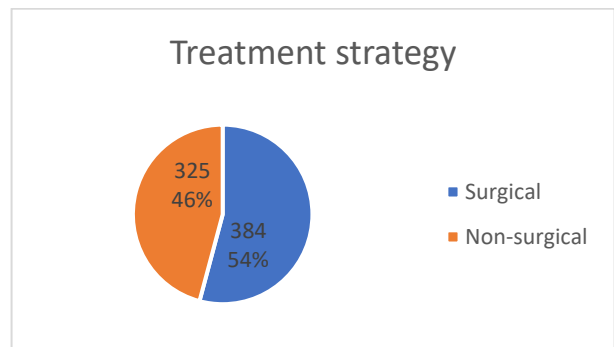


Figure 4.

On the other hand, a total of 384 (54.16%) surgeries for pituitary tumors were performed in this period as follows: 243 primary transsphenoidal surgeries, 36 primary transcranial surgeries, 62 transsphenoidal reinterventions, 18 transcranial interventions for relapse after transsphenoidal surgeries, 6 transsphenoidal surgeries after failed Gamma-Knife therapy, 8 combined approach surgeries (both transsphenoidal and transcranial) and 2 transcranial approaches after transcranial relapse (figure 5).

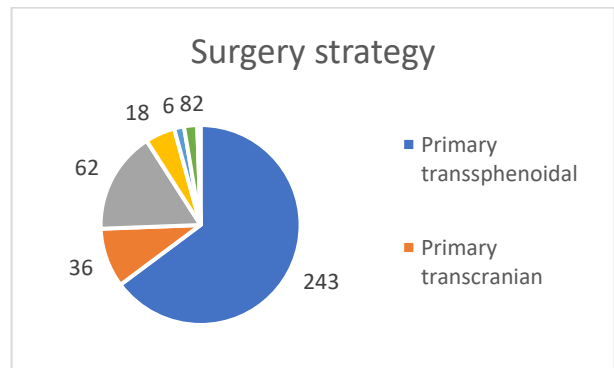


Figure 5.

Out of the patients who underwent surgery, 122 (31.77%) were macroadenomas, with extension ranging from only suprasellar, to one or both cavernous sinuses, anterior cranial fossa or third ventricle.

The histopathology examination revealed 95 GH secreting tumors (24.74%), 21 ACTH secreting tumors (5.46%), 18 prolactinomas (4.68%), 11 gonadotropin secreting hormones (2.86%). The rest were non secreting tumors (62.26%) (figure 6).

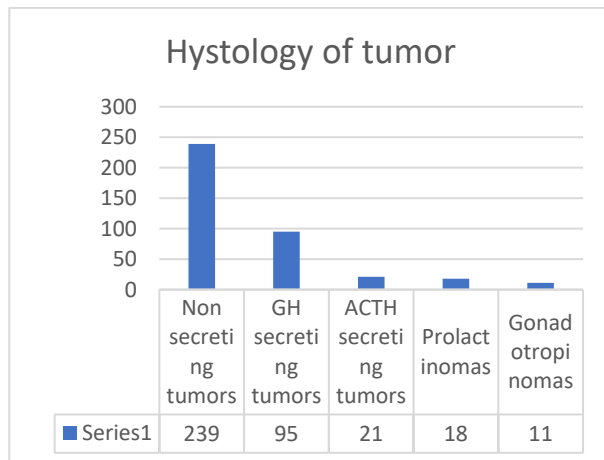


Figure 6.

The mean number of days of hospitalization was of 7.5 for the entire group, with an average of 7 days for the transsphenoidal approach and an average of 13 days for the transcranial approach (figure 7).

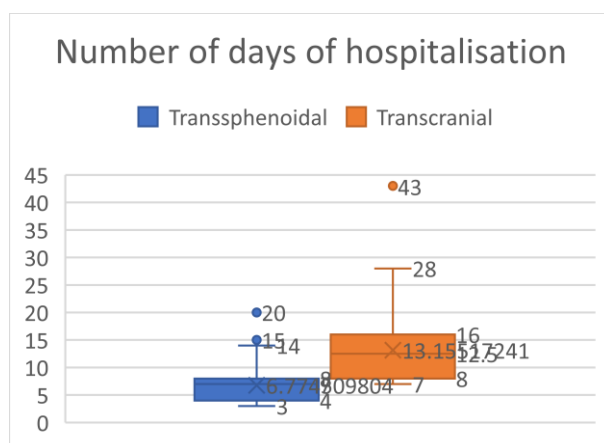


Figure 7.

The most common surgical complication encountered was pituitary insufficiency reported in 23 cases, while CSF leakage was observed in 17 cases.

For the total number of hospitalizations, 4 deaths were recorded: one after transsphenoidal surgery of a patient with a macroadenoma invading both cavernous sinuses, two patients who presented with acute hydrocephalus at admission and GCS less than 6, and one patient died of cardiac arrest in his sleep prior to surgery. No deaths were recorded for the transcranial group.

DISCUSSIONS

Hypothalamic/pituitary disorders represent a multifaceted pathology and, due to advancement of treatments, technology and understanding of physiopathology of the region, lately, not one type of strategy gets to be the gold standard. (2) Thus, recent understanding of complex mechanisms concerning cellular and molecular biology has brought medical treatment very high up in the list of strategies of treatment for pituitary tumors. Hence, almost half the patients who were admitted to our Neurosurgical Clinic benefited from a conservative treatment.

On the other hand, even though there is no consensus on the world stage of neurosurgery regarding the gold standard treatment in case of incidental discovered pituitary tumors, there is a different story when it comes to tumors which provoke neurological deficits of any sort, endocrine dysfunction beyond the drugs' capacity of compensating, or even pose an immediate threat to the patient's life. Most recent articles (4), (5) suggest a surgical strategy as first option in these cases, but this is where the consensus stops. There are mainly three types of surgical approaches: transcranial, microsurgical transsphenoidal and endoscopic transsphenoidal, each with its own advantages and disadvantages.

In our study, the patients who underwent surgery benefited from either microsurgical transsphenoidal or transcranial surgeries. Even if the transsphenoidal approach was used far more, there was a greater relapse proportion in these patients (figure 8). Furthermore, there were patients who underwent as many as 10 consecutive transsphenoidal surgeries in the course of the 10 years analyzed. Moreover, there were a number of patients who needed transcranial reintervention after the transsphenoidal approach did not offer the desired result. Only two patients underwent reintervention after transcranial approach, both of them with no relapse after the second surgery.

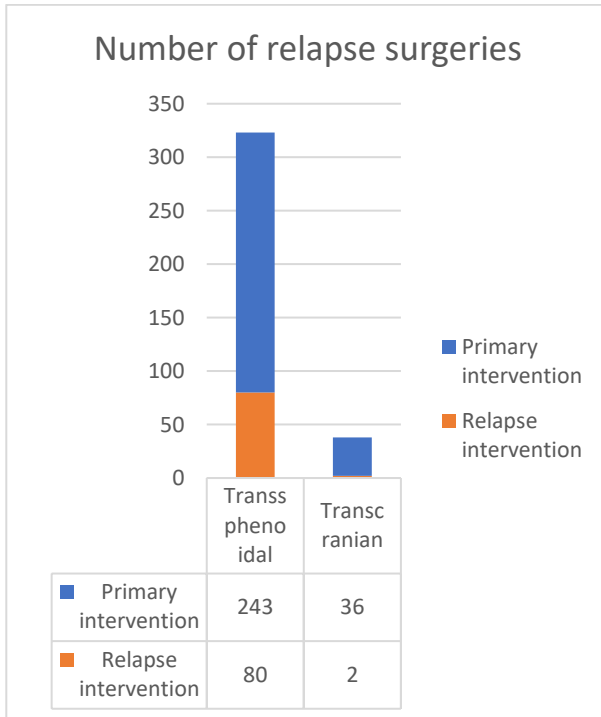


Figure 8.

On the other hand, transcranial surgeries, even if followed by a far less proportion of relapse surgery, carried with it the burden of more days spent in hospital (most of the time twice as much as for the transsphenoidal patients). Moreover, there were cases in which the transcranial approach was not enough for the tumor to be completely removed, in which case, a second transsphenoidal approach was used during the same hospitalization (the combined approach cases – 8 patients).

We also found a number of cases in which the first treatment option was Gamma-Knife therapy that proved not sufficient and a transsphenoidal approach was used in these cases.

In accordance with most of the studies published, our patient data base revealed a clear dominance of male over female patients and also a younger age of debut for the disease (or diagnosis) for men as opposed to women. Furthermore, due to the relative early diagnosis in the natural evolution of the disease, only 122 cases out of 384 operated patients presented with macroadenomas. Moreover, all of the patients who underwent transcranial approach presented with macroadenomas.

The most common symptoms that brought patients to the doctor were headache, optic chiasm deficits and body modification specific to GH

hypersecretion. However, there was quite a large proportion of patients (mostly microadenomas) who were diagnosed with a brain tumor after the hormonal imbalances were discovered or patients who underwent a CT scan for another pathology (for example: post-traumatic CT scans performed after car crashes that reveal pituitary tumors).

The most notable complications were CSF fistulae and pituitary insufficiency. These appeared in a total of less than 1% of all hospitalizations and less than 7% out of the patients who underwent surgery (17 fistulae, 23 pituitary insufficiency). Furthermore, all of the patients with CSF fistulae were part of the transsphenoidal approach group, none of the transcranial approach group presenting this complication.

Out of the total number of hospitalizations (1107), 4 deaths were reported, out of which only one directly related to the treatment option-transsphenoidal surgery, thus a death rate of less than 0.72 for the entire group.

CONCLUSIONS

Even with the advancements in molecular and cellular biology, surgery remains one of the most important aspects of pituitary tumors treatment. Even if there is still no general consensus on what the ideal approach should be, our study reveals that both transsphenoidal and transcranial approaches have advantages and disadvantages, thus the best strategy would be to tailor each surgery to each patient, keeping an open mind to all available approaches.

CONFLICTS OF INTEREST

The authors declare no conflict of interests

Funding: none.

REFERENCES

1. Presentation, Management, and Outcomes of Nonfunctioning Pituitary adenomas: An experience from a developing country. Das B, Batool S, Khoja A, et al. e5759, s.l.: Cureus 11(9), September 25, 2019. DOI: 10.7759/cureus.5759.
2. A Survey on Pituitary Surgery in Italy. Domenico Solari, Paolo Cappabianca et al. E1-E10, s.l. : World Neurosurgery, 2018. <https://doi.org/10.1016/j.wneu.2018.11.186>.
3. Complications associated with microscopic and endoscopic transsphenoidal pituitary surgery: experience of 1153 consecutive cases treated at a single

tertiary pituitary center. Matthew S Agam, BS, Gabriel Zada, MD et al. June 1, Los Angeles, California : Journal of Neurosurgery, Published online June 1, 2018. DOI: 10.3171/2017.12.JNS172318..

4. Endoscopic versus Microscopic Pituitary Adenoma Surgery: A Single-center Study. Ajler Pablo, Beltrame Sofia, Toscano Maximiliano, Fainstein Day Patricia, Campero Alvaro, Yampolsky Claudio, Carizzo Antonio. 4, s.l. : Neeurology India, 2019, Vol. 67. DOI: 10.4103/0028-3886.266241.
5. Comparison of Endoscopic Versus Microsurgical Resection of Pituitary Adenomas with Parasellar Extension and Evaluation of the Predictive Value of a Simple 4-Quadrant Radiologic Classification. Gianluca Trevisi, Vera Vigo, Maria Grazia Morena, Domenico Luca Grieco, Mario Rigante, Carmelo Anile, Annunziato Mangiola. E1-E6, s.l. : World Neurosurg., 2018. <https://doi.org/10.1016/j.wneu.2018.09.215>.