



Research paper

Dissociations in cortical thickness and surface area in non-comorbid never-treated patients with social anxiety disorder

Xun Zhang^{a,b}, Qiang Luo^{a,b}, Song Wang^{a,b}, Lihua Qiu^{a,b,c}, Nanfang Pan^{a,b}, Weihong Kuang^d, Su Lui^{a,b}, Xiaoqi Huang^{a,b}, Xun Yang^{e,*}, Graham J. Kemp^f, Qiyong Gong^{a,b,g,*}

^a Huaxi MR Research Center (HMRR), Functional and Molecular Imaging Key Laboratory of Sichuan Province, Department of Radiology, West China Hospital of Sichuan University, Chengdu 610041, Sichuan, China

^b Psychoradiology Research Unit of Chinese Academy of Medical Sciences (2018RU011), West China Hospital of Sichuan University, Chengdu 610041, China

^c Department of Radiology, The Second People's Hospital of Yibin, Yibin 644000, China

^d Department of Psychiatry, State Key Lab of Biotherapy, West China Hospital of Sichuan University, Chengdu 610041, PR, China

^e School of Public Affairs, Chongqing University, Chongqing 400044, China

^f Liverpool Magnetic Resonance Imaging Centre (LiMRIC) and Institute of Life Course and Medical Sciences, University of Liverpool, Liverpool, United Kingdom

^g Department of Psychology, School of Public Administration, Sichuan University, Chengdu 610041, China



ARTICLE INFO

Article History:

Received 22 April 2020

Revised 30 June 2020

Accepted 10 July 2020

Available online xxx

Keywords:

Social anxiety disorder

Magnetic resonance imaging

Cortical thickness

Cortical surface area

Prefrontal cortex

Balloon model

ABSTRACT

Background: Abnormalities of functional activation and cortical volume in brain regions involved in the neurobiology of fear and anxiety have been implicated in the pathophysiology of social anxiety disorder (SAD). However, few studies have performed separate measurements of cortical thickness (CT) and cortical surface area (CSA) which reflect different neurobiological processes. Thus, we aimed to explore the cortical morphological anomaly separately in SAD using FreeSurfer.

Methods: High-resolution structural magnetic resonance images were obtained from 32 non-comorbid never-treated adult SAD patients and 32 demography-matched healthy controls. Cortical morphometry indices including CT and CSA were separately determined by FreeSurfer and compared between the two groups via whole-brain vertex-wise analysis, while partial correlation analysis using age and gender as covariates were conducted.

Findings: The patients with SAD showed decreased CT but increased CSA near-symmetrically in the bilateral prefrontal cortex (PFC) of the dorsolateral, dorsomedial, and ventromedial subdivisions, as well as the right lateral orbitofrontal cortex; increased CSA in the left superior temporal gyrus (STG) was also observed in SAD. The CSA in the left PFC was negatively correlated with the disease duration.

Interpretation: As the balloon model hypothesis suggests that the tangentially stretched cortex may cause dissociations in cortical morphometry and affect the cortical capacity for information processing, our findings of dissociated morphological alterations in the PFC and cortical expansion in the STG may reflect the morphological alterations of the functional reorganization in those regions, and highlight the important role of those structures in the pathophysiology and neurobiology of SAD.

Funding: This study was funded by the National Natural Science Foundation of China (Grant Nos. 31700964, 31800963, 81621003, and 81820108018).

© 2020 The Authors. Published by Elsevier B.V. This is an open access article under the CC BY-NC-ND license. (<http://creativecommons.org/licenses/by-nc-nd/4.0/>)

1. Introduction

Social anxiety disorder (SAD), also called social phobia, is a common disabling psychiatric condition characterized by marked, persistent fear and emotional discomfort in social or performance

situations [1,2]. People with SAD are intensely worried about negative evaluation and scrutiny by others and attempt to avoid participation in social activities, thus causing severe personal, professional, and academic functional impairments [3]. An estimated 7%–13.3% of people suffer from SAD at some point [4], and approximately 90% of SAD patients have at least one comorbid disorder, such as major depression disorder (MDD), bipolar disorder, or autism [5]. Considering the high prevalence and potential severity of SAD, understanding this disorder better is essential for achieving early diagnosis and timely intervention. Increasing attention is paid to understanding its

* Corresponding authors.

E-mail addresses: yangxunj@163.com (X. Yang), qiyonggong@hmrrc.org.cn (Q. Gong).

Research in Context

Evidence before this study

Social anxiety disorder (SAD) is a prevalent disabling psychiatric condition characterized by marked, persistent fear and emotional discomfort in social situations, accompanied with severe personal, professional and academic functional impairments. Increasing attention is paid to understanding its pathophysiology and identifying potential neuroanatomical biomarkers, but results are of limited consistency, in need of validation and replication. To date, most structural analyses have focused on cortical gray matter volume using voxel-based morphometry, revealing a widespread but variable pattern of gray matter deficits. Considering the cortical volume confounds the effects of both cortical thickness (CT) and cortical surface area (CSA), which reflect unique characteristics in terms of brain development, cytology, and genetics, joint analysis of CT and CSA may offer sensitive information and better insights. However, few studies have conducted separate investigations of CT and CSA in SAD. Further, some researches have investigated CT alterations in SAD with mixed and partially contradictory findings. These diverse results may be attributed to some confounding factors such as comorbidity with other psychiatric disorders, concomitant therapy, sex ratio (e.g. studying all-male participants), and methodological differences (e.g. whole-brain vs region-of-interest analyses). In the context, the present study aimed to explore the cortical anomaly of CT and CSA in non-comorbid never-treated adult patients with SAD using surface-based morphometry (SBM) analysis.

Added value of this study

The current study showed that SAD patients had a thinner but expanded cortex near-symmetrically in the bilateral prefrontal cortex (PFC) of the dorsolateral, dorsomedial, and ventromedial subdivisions, as well as the right lateral orbitofrontal cortex, in addition to surface expansion in the left superior temporal gyrus (STG). For the first time, our study demonstrated dissociations in CT and CSA in non-comorbid never-treated adult patients with SAD, which might provide some useful information for understanding the neurobiology of SAD and furtherly characterizing candidate biomarkers in the early diagnosis and targeted therapy.

Implications of all the available evidence

These results are consistent with the 'balloon model' hypothesis that the tangentially stretched cortex causes dissociations in cortical morphometry which affect the cortical capacity for information processing. Our results demonstrate the morphological aspects of the functional reorganization in PFC and STG, and provide structural evidence for their involvement in the pathophysiology and neurobiology of SAD.

pattern of GMV deficits in nearly most cortical and subcortical regions [8–22]. However, the reported results have been heterogeneous and sometimes inconsistent, which may be attributed to a small sample size, differing patient characteristics (comorbidity with other psychiatric disorders, concomitant treatment, and sex ratio), and methodological differences (notably between whole-brain and hypothesis-driven region of interest (ROI) analyses).

In addition, the cortical volume confounds the effects of both cortical thickness (CT) and cortical surface area (CSA); for example, no change in GMV could conceal cortical thinning (decreased CT) with concurrent surface expansion (increased CSA) or vice versa [23]. Therefore, investigating group differences in both CT and CSA may offer better insights. It is suggested that joint analysis of CT and CSA should take the place of the analysis of cortical volume [24]. However, only a handful of original articles have examined CT in SAD with mixed and partially contradictory results [10,22,25–28]. A pilot ROI-based study involving 13 unmedicated SAD patients found decreased CT in the frontal pole (rostral prefrontal cortex (PFC)), the rostral middle frontal gyrus (rMFG) within the dorsolateral PFC (dlPFC), medial orbitofrontal cortex (mOFC), primary motor cortex, postcentral gyrus, supramarginal gyrus, temporal pole, inferior temporal gyrus (ITG), fusiform, and insula [25]; in contrast, a subsequent study including 14 male patients (3 patients with comorbidity and 2 patients with current medication) found only increased CT in the lingual and fusiform gyri [26]; In a recent whole-brain study involving 24 non-comorbid medication-naïve SAD patients, the authors found abnormalities in brain regions similar to previous reports but often with opposite alterations [10]; the SAD patients showed increased CT in the superior frontal gyrus (SFG), caudal MFG, anterior cingulate cortex (ACC), temporal pole, superior parietal gyrus, supramarginal cortex, ITG, and insula, and decreased CT in the lateral OFC (lOFC), rMFG, and precentral cortex. The largest study investigating CT in SAD assessed 46 patients using both ROI and whole-brain approaches [27]. In the ROI-based analysis, the SAD patients had larger CT in the ACC, temporal pole, and insula (only the ACC survived correction for multiple comparisons); the whole-brain analysis revealed increased CT in the dlPFC (including the SFG and MFG), right superior parietal lobule, and angular gyrus. Importantly, 19/46 patients were taking antidepressant medication, although medication was used as a covariate of no interest to control the effects of treatment in the analysis.

Furthermore, the CSA is a very different morphometry metric from CT in terms of brain development, cytology, and genetics. Longitudinal studies have revealed the strikingly different developmental trajectories of CSA and CT [29,30]. An inverse relationship between CT and CSA (i.e. larger CSA accompanied by thinner cortices or vice versa) is often reported in both healthy subjects and patients [29,31–33]. This inverse association may be the result of white matter growth - myelin growth, both subcortical and intracortical, that stretches the cortex tangentially to the pial surface, like a balloon, resulting in expanded and thinner cortices - this is the 'balloon model' hypothesis [34–36]. At the cellular level, the radial unit hypothesis suggests that cortical neurons are organized radially as cell columns and that the CT reflects the number of neurons within the columns, while the CSA reflects the number of columns [37]. From a genetic perspective, the CSA and CT have been regarded as essentially unrelated and distinct endophenotypes influenced by different genetic contributions [38]. In practice, while both CT and the CSA contribute to GMV, a change in the GMV is usually mainly explained by a change in the CSA [39]. In any case, differences in CT and CSA should be investigated separately, potentially offering more neuroanatomical information and better neurobiological insight. So far only one study has examined the CSA in SAD using an ROI approach to investigate the co-segregation and heritability of CSA in families genetically enriched for SAD; in this study, the majority of subjects (22/39) were diagnosed with subclinical SAD (defined as meeting the criteria for SAD without impairing limitations in

pathophysiology and identifying potential neuroanatomical biomarkers [6], but the results are of limited consistency, in need of validation and replication [7].

To explore the neuroanatomical substrates of SAD-related pathophysiology and thus identify potential specific biomarkers of SAD, it is important to select appropriate structural parameters. To date, most neuroimaging structural analyses have focused on cortical gray matter volume (GMV). Several studies investigating SAD have measured the GMV in cortical and subcortical structures using voxel-based morphometry (VBM), revealing a widespread but variable

important functioning areas), and most subjects had a psychiatric comorbidity [28].

In this context, to the best of our knowledge, we conducted the first whole-brain vertex-wise analysis of structural abnormalities in both CT and the CSA in non-comorbid never-treated patients with SAD using FreeSurfer software, a sensitive SBM approach focused on the cerebral cortex. We also conducted exploratory analyses of the relationships between the morphological deficits and clinical features of SAD. In view of existing sparse and mixed SAD-related changes in CT and CSA, we don't intend to hypothesize the alteration direction and pattern of CT/CSA.

2. Materials and methods

2.1. Participants

We recruited thirty-two adult patients with SAD from the outpatient clinic of the Mental Health Center of the West China Hospital, Sichuan University, Chengdu, China [40]. SAD was diagnosed by consensus of two experienced attending psychiatrists based on the Diagnostic and Statistical Manual of Mental Disorders, 4th edition (DSM-IV) criteria via the Structured Clinical Interview for DSM Disorders (SCID) [41]. All patients were right-handed and drug-naive without any comorbid psychiatric disorders.

For comparison, thirty-two HCs matched for sex, age (within a 5-year gap), and handedness were recruited from the local area through poster advertisements, and we use the SCID-Non-Patient Version to confirm the lifetime absence of psychiatric and neurological illness. This recruitment plan led to nineteen healthy subjects having notable levels of social anxiety but not meeting criteria for SAD.

The exclusion criteria for both patients and HCs included the following: comorbid neurological disorders or other axis I psychiatric disorders; axis II antisocial or borderline personality disorders (verified by the SCID); past or current psychiatric treatment (psychopharmacological or psychological therapy); history of substance dependence or abuse; learning or developmental disorders; history of head injury; major physical illness, such as cardiovascular disease, liver disease or brain tumors, as assessed by clinical evaluations and medical records; family history of mental disorders; claustrophobia or other contraindications to magnetic resonance imaging (MRI) examination; and current pregnancy. Individuals were also excluded if they were aged under 18 or over 60 years to minimize age-related effects.

All participants were assessed using the self-administered Liebowitz Social Anxiety Scale (LSAS), which is the most commonly used clinical scale in SAD studies [42]. The LSAS provides a score for both a fear factor (LSASF) and a social avoidance factor (LSASA), and the total score (LSAST) is their sum.

All procedures in this study conform to the ethical standards of the Declaration of Helsinki and the ethical principles in the Belmont Report. This study was approved by the Medical Research Ethics Committee of West China Hospital at Sichuan University. All subjects provided written informed consent before the study.

2.2. MRI data acquisition

We performed whole brain MRI using a 3.0 T MR scanner (Siemens Trio, Erlangen, Germany) with a 12-channel head coil. During the scans, the subjects were instructed to keep their eyes closed, relax and remain as still as possible. Foam pads were used to restrict head motion. We obtained high-resolution three-dimensional T1-weighted images using a spoiled gradient recalled sequence (repetition time 1900 ms, echo time 2.26 ms, flip angle 9°, 176 sagittal slice thickness 1 mm, field of view 240 × 240 mm², data matrix 256 × 256, voxel size 1 × 1 × 1 mm³, and in-plane resolution

0.94 × 0.94 mm²). Each scan was inspected by an experienced neuro-radiologist to rule out visible movement artifacts and gross structural abnormalities.

2.3. Image processing

The cortical reconstruction and estimation of CT and the CSA were performed based on the 3D-T1 images using the FreeSurfer package 6.0.0 (<http://surfer.nmr.mgh.harvard.edu>), which consists of a set of automated sequences to complete the construction of the cortical model. Briefly, the whole process was completed automatically, including motion correction, averaging of multiple volumetric T1 weighted images, skull stripping using a deformable template model, automated registration to the Talairach space, segmentation of the subcortical white matter and deep gray matter volumetric structures, normalization of intensity, tessellation of the gray matter, and white matter boundaries, automated topology correction and surface deformation following intensity gradients to optimally place the gray/white and gray/cerebrospinal fluid borders. The whole segmentation procedure was visually inspected for inaccuracies, and manual corrections were performed as necessary by adding control points [43,44]. Subsequently, the procedures involved surface inflation and registration to a spherical atlas based on individual cortical folding patterns to match the cortical geometry across the subjects, and then the cortex was auto-parcellated into 34 different gyral regions per hemisphere using gyral and sulcal anatomy [45,46]. Eventually, surface maps were created following the registration of the cortical reconstructions of all subjects to a common average surface, and the surface maps were smoothed using a Gaussian kernel of 10 mm full-width half-maximum. CT was defined as the average shortest distance between the white/gray matter boundary and the gray matter/CSF boundary at each point [47], and the CSA of each parcellation per hemisphere was obtained by summing the area of all tessellations on the gray matter surface [48]. This measurement of the cortical parameters using FreeSurfer has been verified against histological analyses and has good test-retest reliability [44].

2.4. Statistical analysis

The group differences in the demographic and clinical data were assessed using a two-sample *t*-test for continuous variables (age, LSAST, LSASA, and LSASF) and chi-square tests for the discrete variable (sex) using IBM SPSS Statistics 22.0. Significance level was set at $P < 0.05$.

To assess the group differences in CT and the CSA, whole-brain vertex-wise analyses were performed using the graphical user interface of FreeSurfer known as QDEC (Query, Design, Estimate, Contrast) [49,50]. We used a general linear model (GLM) to compare the CT and CSA between the SAD patients and HCs with age and sex as covariates. Because all images were aligned to a common surface template, we did not use the intracranial volume as a covariate. The Monte Carlo Null-Z Simulation was conducted to control for multiple comparisons (10,000 iterations, cluster-forming $P < 0.05$, cluster-wise corrected $P < 0.05$). Additionally, to control the potential effects of the anxiety level of HCs, we excluded HCs with LSAS score > 30 and SAD patients with LSAS score ≤ 30 [51,52], and conducted a subgroup analysis (including 30 SAD patients and 13 HCs) to identify CT/CSA differences between worse-affected SAD patients and 'completely normal' subjects (i.e. HCs with low or no symptoms) (see *Supplementary Materials*).

To identify the relationships between the structural alterations and clinical characteristics, the command of *mris_anatomical_stats* in FreeSurfer was used to calculate the average CT/CSA in the significant clusters; then, we conducted a partial correlation analysis between the mean CT/CSA and clinical features (age, LSAST, LSASA, LSASF, and

disease duration) using sex and age as covariates with a critical value of $P < 0.05$ in the SAD group.

3. Results

3.1. Demographic and clinical characteristics

We enrolled 32 adult patients with SAD and 32 sex- and age-matched HCs. Table 1 shows their detailed demographic and clinical characteristics. There were no significant differences between the groups in the sex composition or mean age. Relative to the HCs, the subjects with SAD exhibited significantly higher LSAS scores. For subgroup analysis, LSAS were also higher in SAD patients, and there were no significant differences in age and sex between the 30 SAD patients and the 13 HCs (see Table S1).

3.2. Group differences in the CT

The whole-brain vertex-wise analysis revealed that compared to the HCs, the SAD patients had thinner cortices (lower CT) in three clusters located in the bilateral SFG with large portions extending into the rMFG and rostral ACC (corrected with Monte Carlo simulations of $P < 0.05$). No areas had higher CT in the SAD patients (Fig. 1 and Table 2). All aforementioned results survived well in subgroup analysis (see Supplementary Materials).

3.3. Group differences in the CSA

The whole-brain vertex-wise analysis revealed that compared to the HCs, the SAD patients had 5 clusters with significantly larger CSA as follows: cluster 1 in the left hemisphere mainly covered the SFG and partially extended into the rostral ACC; cluster 2 in the left hemisphere was located in the rMFG; cluster 3 in the left hemisphere was mainly located in the STG, extending partly into the middle temporal gyrus (MTG); cluster 4 in the right hemisphere mainly covered the SFG and substantially extended into the ACC; and cluster 5 in the right hemisphere was located in the IOFC extending into the rMFG (all clusters corrected with Monte Carlo simulations of $P < 0.05$). There were no regions with decreased CSA in the SAD patients (Fig. 2 and Table 2). All aforementioned results survived well in subgroup analysis (see Supplementary Materials).

3.4. Correlation between morphometrical alterations and clinical variables

After controlling for the confounders of sex and age, the partial correlation analysis showed that the increased CSA in the left SFG cluster (in the PFC) was significantly inversely related to the SAD durations ($r = -0.422$, $P = 0.02$) (Fig. 3). There was no significant association between the cortical morphometrical changes and LSAS.

Table 1
Demographics and clinical characteristics of participants.

Characteristics	SAD (N = 32)	HCs (N = 32)	P-value
Sex (Male/Female)	20/12	20/12	1.000*
Age (years)	23.3 ± 3.7 (18–30)	22.9 ± 2.8 (19–30)	0.650**
Illness duration (years)	7.3 ± 3.5 (1–15)	–	–
LSAST	62.7 ± 22.0 (28–103)	39.2 ± 23.6 (4–85)	< 0.001**
LSASF	30.9 ± 10.4 (14–50)	20.1 ± 12.5 (2–47)	< 0.001**
LSASA	31.8 ± 12.9 (14–62)	19.1 ± 11.6 (0–43)	< 0.001**

Data are presented as the means ± standard deviations (minimum - maximum).

* P value obtained using a chi-square test.

** P value obtained using a two-sample t-test.

Abbreviations: HCs, healthy controls; LSAST, LSASF, and LSASA, total score and fear and avoidance factor of the Liebowitz Social Anxiety Scale (LSAS); SAD, social anxiety disorder.

4. Discussion

To the best of our knowledge, this study is the first to investigate cortical morphometrical alterations in both CT and CSA of non-comorbid never-treated patients with SAD at the whole-brain level. All patients were non-comorbid and free of treatment, thereby eliminating the confounding effects of comorbidity and therapy, which is beneficial to explore the “pure” specific SAD-related neurobiological mechanisms. Compared to the HCs, the patients with SAD had thinner and expanded cortices in the bilateral PFC (mainly bilateral dlPFC, dorsomedial PFC (dmPFC), ventromedial PFC (vmPFC)), and right IOFC). In addition, the CSA was increased in the left STG cluster. There was a negative correlation between the CSA of the left SFG cluster (in the PFC) and the duration of SAD. These findings were nearly symmetrical in the same region of the PFC, the core region of the classic fear circuit (including the PFC, ACC, insula, amygdala, and hippocampus) that underlies the dysfunctional emotion and cognitive processing in SAD [53]. Our findings may reflect the structural substrate of the dysfunctional social information processing and emotion regulation in SAD.

4.1. Possible neurobiology of the dissociated morphological alterations in PFC and cortical expansion in STG

This dissociation of morphological abnormalities (decreased CT but increased CSA) symmetrically in the bilateral PFC and the cortical expansion in left STG may reflect a cortical reorganization process. To explain this type of dissociation, the popular ‘balloon model’ hypothesis proposes that myelin growth, both subcortical and intracortical, stretches the cortex tangentially to the pial surface, like a balloon, resulting in expanded and thinner cortices (i.e., larger in surface area and thinner in thickness) [34–36]. Such cortical reorganization has been suggested to be the result of the differential effects of genes that control the developmentally distinct periods of symmetric and asymmetric division and the mechanical effects of gyrification, which is a process of tangential surface expansion to fit a relatively small volume [54]. The expansion of a balloon would result in the further separation of small structural units of the balloon. Likewise, such balloon-like stretching of cerebral cortex could cause the neuronal columns consisting of the structural units to move apart and become more spatially separated. Meanwhile, the tangential expansion could also stretch the dendrites in the neuropil between them to a flatter orientation. These cytoarchitectural alterations lead to less overlap among neighboring neuronal columns and dendrites; this is expected to result in greater local functionality in corresponding cortices including differentiation among afferent information and signal-processing ability [36], because more tangential arrangements of columns and dendrites could guarantee less interferences from neighboring units and wider columns or modules for sampling a larger set of incoming signals. In other words, such structural changes of cortex stretching along with, for example, experience-related pruning and strengthening of specific connections, disentangles neighboring neuronal columns, enables the relevant parts of the cortex to increase functional specialization, makes the neuronal units more distinct and independent regarding functions, and thus more efficient to differentiate incoming signal patterns and potentiate the information-processing capacity in the cortical regions [35,36].

Such dissociated morphological alterations (larger CSA accompanied by thinner cortices or vice versa) have been observed in studies of other diseases [55–57]. For example, a longitudinal research demonstrated that the relative preservation over time of the CSA and a thinning of the cortex in the frontal, occipital lobe, and cingulate observed in a high-risk schizophrenia group may be candidate indicators of vulnerability to schizophrenia [31]. In another study, patients with Williams syndrome, a rare genetic neurodevelopmental disorder characterized by hypersociability (lack of fear for strangers),

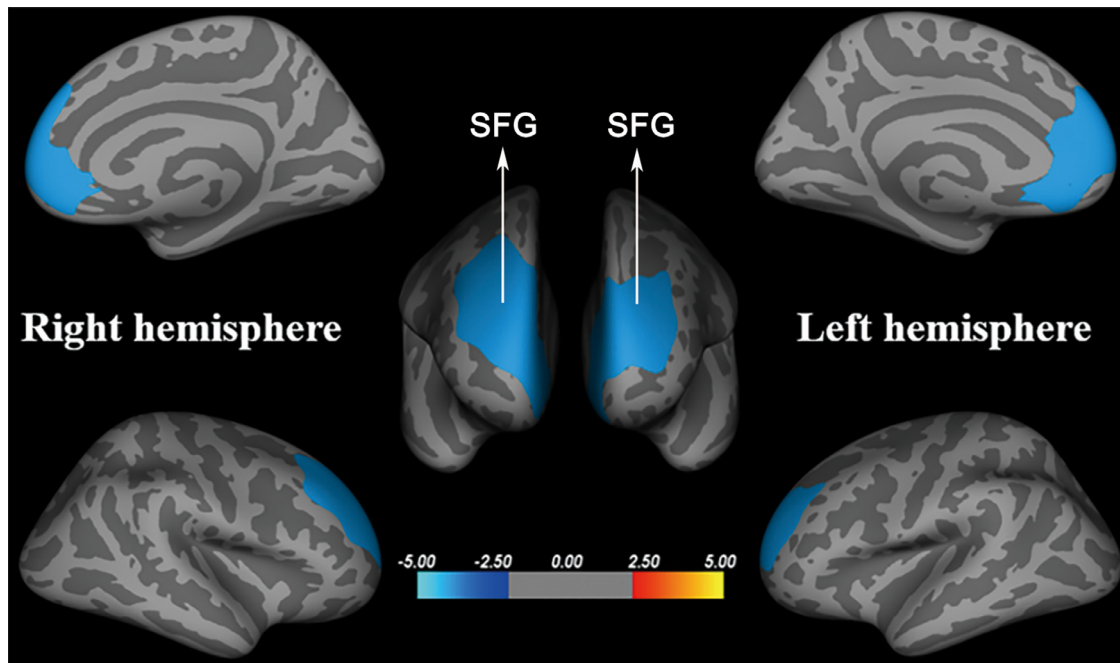


Fig. 1. Brain regions with cortical thickness differences between social anxiety disorder patients and healthy controls (corrected with Monte Carlo Null-Z Simulation of $P < 0.05$). Warmer colors (positive values) represent increased cortical thickness, while cooler colors (negative values) represent decreased cortical thickness in social anxiety disorder patients compared to those in healthy controls. Abbreviations: SFG, superior frontal gyrus.

which is in some respects the opposite of the symptomatology of SAD, had a lower CSA with greater CT (i.e., the opposite to our findings) in some cortical regions, such as the SFG, rMFG, and transverse temporal gyrus [58]. Likewise, reduced CSA predominantly in frontal and temporal lobes and increased CT mainly in frontal, parietal, and occipital regions were observed in Down syndrome relative to typical controls [32]. Intriguingly, a recent study including the ENIGMA-CNV consortium and the UK Biobank data (45,756 individuals) explored the associations of pathogenic copy number variations of the 15q11.2 deletion and duplication with cognition and cortical/subcortical morphology. Compared with noncarriers, deletion carriers showed a pattern of decreased CSA and increased CT particularly across the ACC,

frontal lobe, and pre/postcentral gyrus, while duplication carriers showed an opposite pattern of increased CSA and decreased CT [33].

Nevertheless, other studies have also reported regions with altered CT showing no changes in CSA or vice versa [28,59], as well as CT and CSA changes in the same direction [56,60,61]. Likewise, the left STG in our study revealed cortical expansion without thickness changes. Putatively, it is suggested that synaptic pruning and dendritic arborization could affect another cortical phenotype, namely the cortical gyrification, which, along with CSA, is a driving factor of ontogenetic and phylogenetic changes in GMV [62,63]. Put it another way, a brain region can increase surface area through complex gyrification, with no change in CT, or vice versa [64,65]. Consequently, it is

Table 2

Significant clusters with altered cortical thickness or surface area in social anxiety disorder patients versus healthy controls.

Brain regions	Maximum vertex coordinate of significant clusters			Size (mm ²)	P-value for CWP
	Tal-X	Tal-Y	Tal-Z		
Cortical thickness					
SAD < HCs					
Left SFG	-9.3	53.1	13.4	4929.15	0.00010
Right SFG	16.3	53.1	18.5	5702.41	0.00010
Right SFG	13.6	-3.6	61.8	2418.51	0.02100
SAD > HCs					
none					
Cortical surface area					
SAD > HCs					
Left STG	-49.3	2.4	-18.3	3320.39	0.00010
Left SFG	-7.6	29.4	38.5	2649.40	0.00030
Left rMFG	-39.8	35.6	21.8	1790.61	0.01130
Right IOFC	18.6	20.3	-17.2	4521.55	0.00010
Right SFG	8.9	51.5	17.3	3579.38	0.00150
SAD < HCs					
none					

All clusters survived correction for multiple comparisons using a Monte Carlo simulation, resulting in a corrected cluster-wise $P < 0.05$.

Abbreviations: CWP, cluster-wise probability; HCs, healthy controls; IOFC, lateral orbitofrontal cortex; rMFG, rostral middle frontal gyrus; SAD, social anxiety disorder; SFG, superior frontal gyrus; STG, superior temporal gyrus.

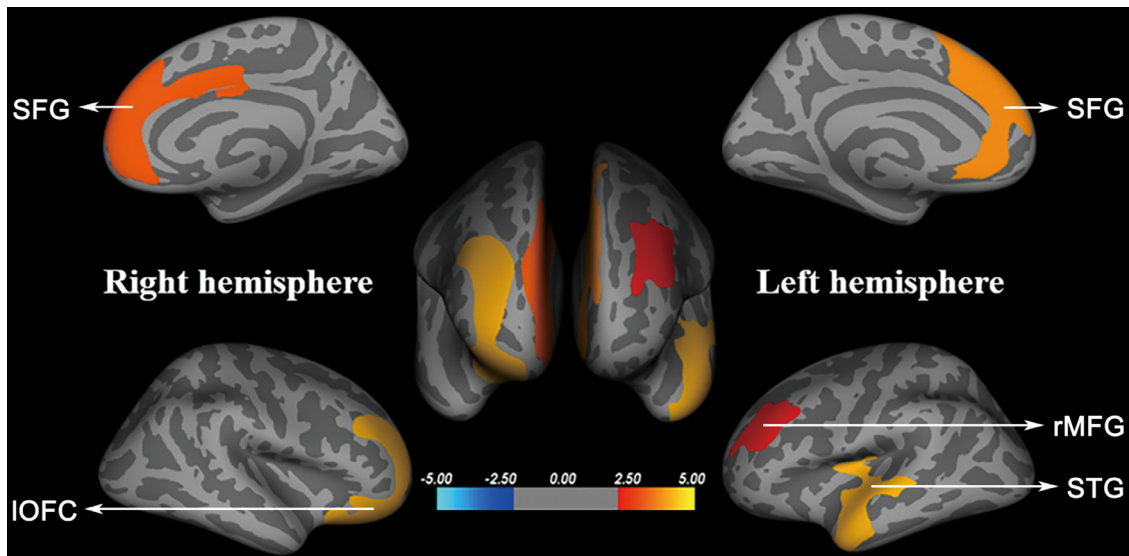


Fig. 2. Brain regions with cortical surface area differences between social anxiety disorder patients and healthy controls (corrected with Monte Carlo Null-Z Simulation of $P < 0.05$). Warmer colors (positive values) represent increased cortical surface area, while cooler colors (negative values) represent decreased surface area in social anxiety disorder patients compared to those in healthy controls. Abbreviations: IOFC, lateral orbitofrontal cortex; rMFG, rostral middle frontal gyrus; SFG, superior frontal gyrus; STG, superior temporal gyrus.

suggested that a combination of the aforementioned hypotheses might fit well with the currently observed complex relationships of CT and CSA [66]. Future cytoarchitectonic studies are warranted to further investigate the sophisticated pattern of cortex.

4.2. The dissociated morphological alterations of the PFC in SAD

This finding of significantly reduced CT and increased CSA in the PFC is consistent with the classic fear circuit model in which dysfunction in the PFC is involved in the pathogenesis of SAD as it is (along with the insula, ACC, and amygdala) in other anxiety disorders [53]. As a key node of the classic fear circuit, the PFC potentially plays a crucial role in social behavior control, information processing, and emotion regulation [67], and in the latter, different subdivisions of the PFC perform distinctive functions [68], which we briefly consider here.

The dlPFC plays a central role in appraisal, reappraisal, subjective emotion, and self-awareness [69], and its dysfunction may be associated with increased vulnerability to pathological anxiety [70]. In this sense, 'appraisal' refers to the evaluation of the meaning of the stimuli to the organism; 'reappraisal', which is an important strategy for emotion regulation, involves changing the way one thinks about a situation to decrease its emotional impact and is associated with positive affect and interpersonal relationships [71]. The idea that dysfunction of the dlPFC may underlie the functional deficiency in cognitive control including appraisal and reappraisal of emotion regulation in SAD is supported by a positron emission tomography study revealing increased blood flow in the dlPFC as SAD patients anticipated a public speaking task [72], and the functional MRI evidence of greater response of dlPFC during regulation for physical threat in SAD [73]. The adjacent dmPFC is also a hub region for emotional appraisal, reappraisal, self-referential judgments, and attentional allocation towards emotional stimuli [74]. The translational circuit of the

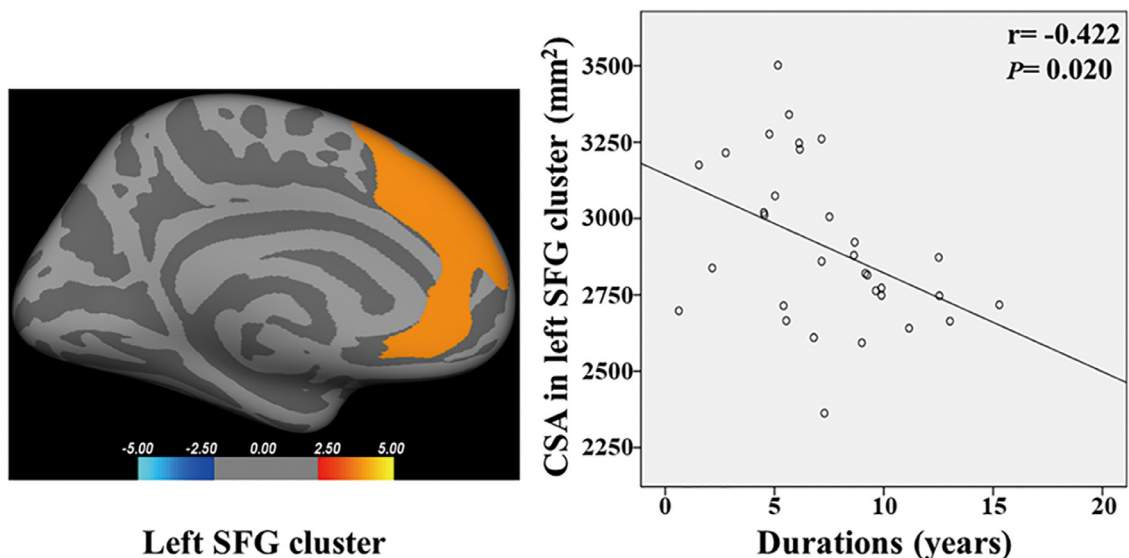


Fig. 3. Scatterplots showing negative correlations between average cortical surface area of the left superior frontal gyrus cluster and disease durations in social anxiety disorder.

dmPFC and amygdala has been reported to prompt behaviors to adapt and circumvent harm when patients with anxiety disorder are in threatening environments [75]. In addition, the activation of the dmPFC in anxiety disorder patients has been reported to be negatively related to worry, an internal avoidance strategy that is one of the core symptoms of SAD, and individuals with anxiety disorder reappraised less often than HCs and showed less activation in the dlPFC and dmPFC during reappraisal, which was inversely correlated with anxiety severity and functional impairments [76]. Considering the crucial roles of the dlPFC/dmPFC in the appraisal and reappraisal of emotion regulation, coupled with aforementioned idea that dissociated morphological abnormalities may potentiate the information-processing capacity, the decreased CT and increased CSA in the dlPFC/dmPFC observed in the present study may be related to an undue evaluation of others in social interaction and response to the sustained reappraisal of anxiety-related stimuli in SAD.

The vmPFC also showed decreased CT and increased CSA in the SAD patients. Although the vmPFC is also a key node in emotion regulation, it has mainly been implicated in the inhibition and extinction of fear and anxiety responses [74,77]. In previous neuroimaging studies, dysfunction in the vmPFC has been related to the generation of negative emotions, including anxiety and fear [78,79], while SAD patients demonstrated hyperactivity in (para)limbic regions, including the amygdala, insula, and hippocampus, in the face of negative, especially socially aversive stimuli and participation in socioemotional events [80–82]. Interestingly, greater vmPFC responses to unintentional (embarrassment-mediated) situations were also observed in SAD patients [83], and regarded as a potential endophenotype of SAD [84]. It has been speculated that the vmPFC is involved in the inhibition of fear responses by suppressing overactivity in (para)limbic regions when SAD patients are confronted with anxiety-related stimuli [68]. Neuroimaging studies have also linked the vmPFC to the extinction of fear memory as follows: functional MRI demonstrated increased activity in the vmPFC during extinction recall [85], and structural MRI showed that the CT in vmPFC was positively correlated with the magnitude of extinction retention [86]. Hence, the thinner and expanded cortex of the vmPFC in the present study could be interpreted as compensatory response of the vmPFC to enhance the suppression of overactivity in (para)limbic structures and mediate fear memory extinction in the face of external conditioned stimuli in SAD. Moreover, our study also observed increased CSA in the right IOFC. The OFC is involved in various higher-order executive functions, particularly control and inhibition of incongruous behavioral and emotional responses, and dysfunction in the OFC has been implicated in anxiety [87]. Specifically, evidence from neuroimaging studies has indicated that the IOFC, to some extent like the vmPFC, was dedicated to mediating responses to negative affective states [88], and hyperactivity in the IOFC was found in the presence of prominent anxiety-laden cognitions. Accordingly, anxious individuals have been hypothesized to require the enhanced recruitment of the OFC to attenuate the negative emotional response to aversive stimuli [89]. In support of this hypothesis, SAD patients have decreased regional cerebral blood flow in the OFC but increased flow in the amygdala during public speaking, which was explained as emotional dysregulation linked with failure to inhibit negative affect [90]. Thus, the increased CSA in the IOFC we observed may reflect compensatory mechanisms to dampen anxiety or a response to the sustained attenuation of negative emotion in SAD.

Taken together, as noted by Etkin et al. [68], there is an essential differentiation among PFC subregions. The current findings may provide a detailed and defined neural structural basis for the different subdivisions of the PFC involved in the classic fear network and the hypothesis that the disturbance of the normally well-balanced neurocognitive circuit is related to an imbalance among heightened cognition (undue appraisal and reappraisal) of anxiety-related stimuli, overactive emotional arousal to external stimuli, and defective top-

down regulatory mechanisms in SAD [91,92], which remains to be further explored in functional studies.

The exploratory correlation analysis found a negative association between the increased CSA in the PFC and SAD duration. SAD typically emerges early in life [93], and is chronic and persistent. Further, untreated SAD may progressively lead to fear and avoidance of social situations and relationships. In our sample 22 (69%) patients had their first onset in adolescence, and the course lasted for many years. On average, our longer-duration patients showed less increase of CSA in PFC. According to fear-network theory [53,92], anxiety disorders are associated with alterations in fear neurocircuitry, such that 'bottom-up' processes in the amygdala which respond to threat are exaggerated, and regulation of these processes by PFC is impaired. One might expect that patients with longer disease course would show more serious PFC damage, the opposite of our observation of CSA in PFC. A longitudinal MRI study revealed cortical volume reduction in bilateral dmPFC in SAD patients after cognitive behavioral group therapy [22]. Consistent with this, our recent SAD resting study found an increased resting connectivity in the frontolimbic/perceptual system circuits [40]. An appealing interpretation of this finding is that top-down control modulation is increased but still fails to compensate for heightened social anxiety [40,92]. We suspect that as the disease progresses, patients gradually reduce such excessive cognitive efforts. This would make sense of the negative association between illness duration and CSA PFC. Since clinical population-based developmental research in the context of brain structure is limited, longitudinal studies will be needed to clarify whether participation of people with chronic illness will exhibit more or less CSA expansion in PFC. In addition, our failure to find significant correlations between symptom severity and neuroanatomical differences is in line with recent studies [10,27], but somewhat inconsistent with some other studies that reported significant associations between SAD symptom severity and structural alterations (in GMV or CT) [9,11,14,16–18,25,26]. This difference may perhaps be explained by method and sample differences such as sample size and characteristics. Besides, another interpretation proposed by Brühl for such lack of correlation with symptom severity is that those neuroanatomical alterations were more linked to the category of disorder than the psychopathological dimension [27], which remains to be investigated in future research.

4.3. The temporal cortical expansion in SAD

Another important finding is the cortical expansion in the left STG cluster (extending to the MTG). Consistent with our results, a recent meta-analysis found that non-comorbid SAD patients had larger GMV in the right STG and MTG [12], while the GMV in the STG decreased after cognitive behavioral group therapy [94], or after 12 weeks of treatment with escitalopram [95]. Neurofunctionally, hyperactivation in the STG/MTG has also been observed during facial emotion processing, emotional response, and a social evaluative threat task [96]. A recent functional MRI study also revealed a positive associations between social anxiety level of SAD patients and brain activation of STG and MTG in response to unintentional social norm violations [84]. Indeed, the STG is a pivotal component of the perceptual system involved in the perception of facial expression and averted gaze, the evaluation of personality traits in others, and analysis of the dispositions and intentions of others' actions [97]. As patients with SAD are characterized by excessive focus on others' intention and facial expression, undue fear of negative appraisal and scrutiny by others, our findings of temporal expansion may offer structural evidence for the dysfunctional temporal social information processing system in SAD [98]. As a crucial region for abstract conceptual social knowledge, STG is active during emotional judgment of social value-related behavior, across different contexts of moral sentiments [99]. STG is recruited in conditions that require subjects

to recall episodic or semantic memory, suggesting that it integrates interoceptive information with information about the current environmental situation for assessment of emotional state [100]. Additionally, considering the important roles of those temporal regions in visual perception and visual mental imagery [101], it is speculated that increased STG activation may be linked to increased saliency of the social situations when SAD patients envision themselves in the hypothetical scenes [84]. It may therefore be that cortical expansion of STG in our study may reflect structural alterations corresponding to such functional changes.

4.4. Comparison between our results and previous findings and potential implications

Increasing attention is paid to understanding the pathophysiology and identifying potential neuroanatomical biomarkers in SAD, but the results have been of limited consistency. Previous structural MRI (GMV/CT/CSA) studies, which have been recently summarized in [28], have reported a wide pattern of brain regions with altered CT, including the PFC, parietal, and temporal lobule [10,25–27]. Several factors might contribute to the differences from our results. From a methodological perspective, first, we used automated software FreeSurfer for preprocessing and statistical analysis; this is a validated SBM method with good test-retest reliability which has been verified against histological analyses [44,102]. In contrast some previous studies used manual segmentation or less accurate software [103,104]. Second, we used vertex-wise whole brain comparison, different from the ROI analysis adopted in some other studies [25,27], which increases the risk of Type II error dramatically [105]. Third, GMV is a complicated parameter, driven by many factors such as CT, CSA, and cortical folding (gyrification) [24], so group differences in GMV may be not necessarily explained by those in CT or CSA; a cluster with altered GMV may show no differences in CT or CSA [39]. Fourth, VBM and SBM differ in terms of methodology and biology, and SBM is more sensitive to abnormalities of gray matter structure in some circumstances, and differences in results from two methods have been reported [106,107]. Turning now to sampling, medications and comorbidity can confound results. Our SAD patients are non-comorbid never-treated, while previous studies recruited comorbid and/or treated patients; studies have shown that comorbidity with other psychiatric disorders and therapy have effects on gray matter structures [22,108]. For instance, patients with MDD comorbid with generalized anxiety disorder show thinner cortices in the right fusiform gyrus and medial orbitofrontal area, and left temporal pole and lateral occipital lobe, compared with HCs and non-comorbid MDD patients [109]. Another potential confounder is that some of our HCs showed some levels of anxiety falling short of DSM-IV criteria for SAD: we consider this in the Limitations section. In short, there are many aspects of the methodological, medical, and socio-demographic domains that are associated with, or perhaps cause, neuroanatomical abnormalities in SAD.

Additionally, comorbid disorders are highly prevalent and significantly affect the clinical course in patients with SAD. Co-occurring and overlapping symptoms may lead to complicated clinical presentation, and increase the risk of misdiagnosis and poorer treatment outcomes [110]. In vivo neuroimaging allows the investigation of brain changes associated with anxiety disorders. However, mapping complex symptoms onto similarly complex multivariate brain patterns in heterogeneous samples could confound results. Thus, SAD patients with comorbidity may have different underlying clinical and neural mechanisms from patients without comorbidity. To minimize the possibility that analytic results are driven by comorbidity, we limited the inclusion criteria to a particular non-comorbid group of participants. For similar reasons, patients with comorbidities have often been excluded from treatment studies in SAD [111]. The application

of the strict inclusion criteria in the current study in effect increases the internal validity at some cost to the external validity.

Furthermore, neuroscience has an important role in a translational approach to inform not only the selection, optimal use, refinement or development of treatment strategies but also the non-pharmacological neurobiological interventions. For instance, the choice of deep brain stimulation of the subgenual cingulate as described by Mayberg and colleagues was based on converging evidence from neuroimaging studies which linked this region to sadness in healthy volunteers [112]. As a result, those regions with gray matter abnormalities are potential therapy targets. For example, direct modulation of anxiety-related regions via real-time functional MRI neurofeedback [113], repetitive transcranial magnetic stimulation [114,115], deep brain stimulation [112], and drug targeted to those regions may be promising strategies. Additionally, if future studies confirm the close (perhaps causal) relation between the gray matter alterations and occurrence and progression of SAD, those regions could be neurobiological biomarkers for early diagnosis of SAD, and noninvasive and reliable tools for therapeutic efficacy evaluation and disease prognosis [116]. As Bas-Hoogendam pointed out in a recent review, insight into the neurobiology of SAD is essential for conducting effective interventions to improve the life quality of SAD patients [7]. Despite many important efforts, there are still significant gaps between neuroscience and clinical practice. Current symptom-based diagnostic categories for psychiatric disorders are not defined by pathophysiology, and what remains largely obscure is the association between pathophysiological mechanisms and clinical symptoms. Further, a better understanding is needed of anxiety-based measures in longitudinal studies of treatment effect.

4.5. Limitations

First, a cross-sectional study cannot definitively identify causal relationships between structural alterations and disease state. To do this we will need large longitudinal studies recruiting high-risk people (such as people with high innate vulnerability of developing SAD based on the genotypes and endophenotypes [117,118]) and following-up SAD patients long-term. Second, it would have been desirable to measure and if feasible to match the patients with HCs in intelligence, as a previous meta-analysis has shown that brain volume is positively correlated with intelligence [119]. However, as there is no clear evidence that SAD patients suffer from intellectual impairment, we do not expect that this is a significant confounder. Third, our sample size is not large compared to recent studies investigating other psychiatric disorders, as we used strict inclusion criteria of non-comorbid never-treated adult SAD patients, with the hope to explore the “pure” SAD-specific pathophysiology and neurobiology; to the best of our knowledge, the current study is thus far the largest study investigating thickness and surface area in non-comorbid never-treated SAD patients at the whole-brain level; however, the strict criteria may also limit the generalizability of our findings, so future studies may benefit from investigating the effects of those confounded factors on the cortical morphological alterations. Fourth, we used a SBM analysis to determine CT and the CSA in the cortical mantle and therefore likely missed relevant changes in subcortical structures, such as the amygdala, thalamus, striatum, and hippocampus, which are of vital importance in the pathogenesis of SAD [92]. Fifth, the diagnosis and absence of SAD was confirmed by two experienced psychiatrists based on the DSM-IV, while LSAS scores were not applied to restrict the recruitment of patients and HCs. Indeed, our recruitment plan led to some healthy subjects having notable levels of social anxiety but not meeting criteria for SAD. Nevertheless, the subgroup analysis between SAD patients (LSAS score > 30) and “completely normal” (LSAS score ≤ 30) indicated that our main results survived well and the effects of notable anxiety level in HCs on our findings were limited. In the future studies, the LSAS scores

could be introduced in the recruitment criteria, and further studies could be conducted to investigate the differences among SAD patients, healthy people with notable anxiety levels, and traditionally “completely normal” healthy subjects.

5. Conclusion

In summary, this study is the first to identify the dissociations in cortical morphometry including the CT and the CSA in non-comorbid never-treated adult patients with SAD at the whole-brain level, which complemented and extended prior SAD-related neuroimaging studies. Our findings of dissociated morphological alterations in the bilateral PFC and cortical expansion in the left STG may provide a detailed and solid structural evidence for the involvement of different subdivisions of the PFC and STG in dysfunctional emotion processing and regulation, as well as the inhibition and memory extinction of the excessive fear and anxiety responses in SAD, which might offer some preliminary information for understanding of the neurobiological basis of SAD and further identification of candidate biomarkers in SAD.

Declaration of Competing Interest

There are no conflicts of interest.

Funding sources

This study was funded by the National Natural Science Foundation of China (Grant Nos. 31700964, 31800963, 81621003, and 81820108018), the Program for Changjiang Scholars and Innovative Research Team in University (PCSIRT, Grant No. IRT16R52) of China, and Fundamental Research Funds for the Central Universities of China (Grant No. 2020CDJSK01XK02). Dr. Gong would also like to acknowledge the support from his Changjiang Scholar Professorship Award (Award No. T2014190) of China, the Functional and Molecular Imaging Key Laboratory of Sichuan Province (FMIKLSP, Grant 2019JDS0044), and the American CMB Distinguished Professorship Award (Award No.F510000/G16916411) administered by the Institute of International Education, USA. The funding sources had no involvement in the study design, data collection and analysis, results interpretation, or writing of the paper.

Author contributions

QY Gong and X Yang designed the study and supervised the conduct of the study. X Yang, Q Luo, LH Qiu, and WH Kuang contributed to the data collection. S Wang, NF Pan, S Lui, and XQ Huang provided methodological advice. X Zhang and X Yang performed the data analysis and results interpretation. X Zhang, X Yang, and Graham J. Kemp drafted the manuscript, which all authors reviewed and approved for publication.

Data availability statement

The data and code that support the findings of present study are available from the corresponding author through reasonable request. The data and code sharing adopted by the authors comply with the requirements of the funding institute and with institutional ethics approval.

Acknowledgments

The authors would like to express their sincere appreciation to the tutors and colleagues for providing valuable help. We also thank all the participants in this study.

Supplementary materials

Supplementary material associated with this article can be found, in the online version, at doi:10.1016/j.ebiom.2020.102910.

References

- [1] Robinson OJ, Charney DR, Overstreet C, Vytal K, Grillon C. The adaptive threat bias in anxiety: amygdala-dorsomedial prefrontal cortex coupling and aversive amplification. *Neuroimage* 2012;60(1):523–9.
- [2] First MB. Diagnostic and statistical manual of mental disorders, 5th edition, and clinical utility. *J Nerv Ment Dis* 2013;201(9):727–9.
- [3] Ruscio AM, Brown TA, Chiu WT, Sareen J, Stein MB, Kessler RC. Social fears and social phobia in the USA: results from the National Comorbidity Survey Replication. *Psychol Med* 2008;38(1):15–28.
- [4] Stein MB, Stein DJ. Social anxiety disorder. *Lancet* 2008;371(9618):1115–25.
- [5] Meier SM, Petersen L, Mattheisen M, Mors O, Mortensen PB, Laursen TM. Secondary depression in severe anxiety disorders: a population-based cohort study in Denmark. *Lancet Psychiat* 2015;2(6):515–23.
- [6] Heimberg RG, Butler RM. Research on social anxiety disorder continues to escalate: a commentary on Asmundson and Asmundson’s analysis of publication trends in the anxiety disorders. *J Anxiety Disord* 2018;56:8–10.
- [7] Bas-Hoogendam JM, Westenberg PM. Imaging the socially-anxious brain: recent advances and future prospects. *F1000Res* 2020;9.
- [8] Talati A, Pantazatos SP, Schneier FR, Weissman MM, Hirsch J. Gray Matter Abnormalities in Social Anxiety Disorder: primary, Replication, and Specificity Studies. *Biol Psychiat* 2013;73(1):75–84.
- [9] Frick A, Engman J, Alaie I, et al. Enlargement of visual processing regions in social anxiety disorder is related to symptom severity. *Neurosci Lett* 2014;583:114–9.
- [10] Zhao Y, Chen L, Zhang W, et al. Gray matter abnormalities in non-comorbid medication-naïve patients with major depressive disorder or social anxiety disorder. *EBioMedicine* 2017;21:228–35.
- [11] Bas-Hoogendam JM, van Steenbergen H, Pannekoek JN, et al. Voxel-based morphometry multi-center mega-analysis of brain structure in social anxiety disorder. *Neuroimage-Clin* 2017;16:678–88.
- [12] Wang X, Cheng B, Luo Q, Qiu L, Wang S. Gray matter structural alterations in social anxiety disorder: a voxel-based meta-analysis. *Front Psychiatry* 2018;9:449.
- [13] Liu Z, Hu Y, Zhang Y, et al. Altered gray matter volume and structural co-variance in adolescents with social anxiety disorder: evidence for a delayed and unsynchronized development of the fronto-limbic system. *Psychol Med* 2020;1–10.
- [14] Liao W, Xu Q, Mantini D, et al. Altered gray matter morphometry and resting-state functional and structural connectivity in social anxiety disorder. *Brain Res* 2011;1388:167–77.
- [15] Meng YJ, Lui S, Qiu CJ, et al. Neuroanatomical deficits in drug-naïve adult patients with generalized social anxiety disorder: a voxel-based morphometry study. *Psychiat Res-Neuroim* 2013;214(1):9–15.
- [16] Irlé E, Barke A, Lange C, Ruhleder M. Parietal abnormalities are related to avoidance in social anxiety disorder: a study using voxel-based morphometry and manual volumetry. *Psychiat Res-Neuroim* 2014;224(3):175–83.
- [17] Cheng BC, Huang XQ, Li SG, et al. Gray matter alterations in post-traumatic stress disorder, obsessive-compulsive disorder, and social anxiety disorder. *Front Behav Neurosci* 2015;9.
- [18] Tükel R, Aydın K, Yuksel C, Ertekin E, Koyuncu A, Tas C. Gray matter abnormalities in patients with social anxiety disorder: a voxel-based morphometry study. *Psychiat Res-Neuroim* 2015;234(1):106–12.
- [19] Kawaguchi A, Nemoto K, Nakaaki S, et al. Insular volume reduction in patients with social anxiety disorder. *Front Psychiatry* 2016;7.
- [20] Talati A, Pantazatos SP, Hirsch J, Schneier F. A pilot study of gray matter volume changes associated with paroxetine treatment and response in social anxiety disorder. *Psychiatry Res* 2015;231(3):279–85.
- [21] Mansson KNT, Salami A, Frick A, et al. Neuroplasticity in response to cognitive behavior therapy for social anxiety disorder. *Transl Psychiat* 2016;6.
- [22] Steiger VR, Bruhl AB, Weidt S, et al. Pattern of structural brain changes in social anxiety disorder after cognitive behavioral group therapy: a longitudinal multimodal MRI study. *Mol Psychiatry* 2017;22(8):1164–71.
- [23] Ducharme S, Albaugh MD, Nguyen TV, et al. Trajectories of cortical surface area and cortical volume maturation in normal brain development. *Data Brief* 2015;5:929–38.
- [24] Winkler AM, Greve DN, Bjuland KJ, et al. Joint Analysis of Cortical Area and Thickness as a Replacement for the Analysis of the Volume of the Cerebral Cortex. *Cerebral cortex* 2018;28(2):738–49.
- [25] Syl S, Hattingh CJ, Fouché JP, et al. Grey matter abnormalities in social anxiety disorder: a pilot study. *Metab Brain Dis* 2012;27(3):299–309.
- [26] Frick A, Howner K, Fischer H, Eskildsen SF, Kristiansson M, Furmark T. Cortical thickness alterations in social anxiety disorder. *Neurosci Lett* 2013;536:52–5.
- [27] Bruhl AB, Hanggi J, Baur V, et al. Increased cortical thickness in a frontoparietal network in social anxiety disorder. *Hum Brain Mapp* 2014;35(7):2966–77.
- [28] Bas-Hoogendam JM, van Steenbergen H, Tissier RLM, Houwing-Duistermaat JJ, Westenberg PM, van der Wee NJA. Subcortical brain volumes, cortical thickness and cortical surface area in families genetically enriched for social anxiety disorder – A multiplex multigenerational neuroimaging study. *EBioMedicine* 2018;36:410–28.

- [29] Storsve AB, Fjell AM, Tamnes CK, et al. Differential longitudinal changes in cortical thickness, surface area and volume across the adult life span: regions of accelerating and decelerating change. *J Neurosci* 2014;34(25):8488–98.
- [30] Tamnes CK, Herting MM, Goddings AL, et al. Development of the cerebral cortex across adolescence: a multisample study of inter-related longitudinal changes in cortical volume, surface area, and thickness. *J Neurosci* 2017;37(12):3402–12.
- [31] Bois C, Ronan L, Levita L, et al. Cortical surface area differentiates familial high risk individuals who go on to develop schizophrenia. *Biol Psychiat* 2015;78(6):413–20.
- [32] Lee NR, Adeyemi EI, Lin A, et al. Dissociations in cortical morphology in youth with down syndrome: evidence for reduced surface area but increased thickness. *Cerebral cortex* 2016;26(7):2982–90.
- [33] Writing Committee for the E-CNVWG, van der Meer D, Sonderby IE, et al. Association of copy number variation of the 15q11.2 BP1-BP2 region with cortical and subcortical morphology and cognition. *JAMA Psychiatry* 2019:1–11.
- [34] Harasty J, Seldon L, Chan P, Halliday G, Harding A. The left human speech-processing cortex is thinner but longer than the right. *Aust J Psychol* 2001;53(3):180.
- [35] Seldon HL. Does brain white matter growth expand the cortex like a balloon? Hypothesis and consequences. *Laterality* 2005;10(1):81–95.
- [36] Seldon HL. Cortical laminar thickness and column spacing in human temporal and inferior parietal lobes: intra-individual anatomical relations. *Laterality* 2006;11(3):226–50.
- [37] Rakic P. Specification of cerebral cortical areas. *Science* 1988;241(4862):170–6.
- [38] Chen CH, Fiecas M, Gutierrez ED, et al. Genetic topography of brain morphology. *P Natl Acad Sci USA* 2013;110(42):17089–94.
- [39] Winkler AM, Kochunov P, Blangero J, et al. Cortical thickness or grey matter volume? The importance of selecting the phenotype for imaging genetics studies. *Neuroimage* 2010;53(3):1135–46.
- [40] Yang X, Liu J, Meng Y, et al. Network analysis reveals disrupted functional brain circuitry in drug-naive social anxiety disorder. *Neuroimage* 2019;190:213–23.
- [41] MB F. Structured clinical interview for DSM-IV axis I disorders (SCID). American Psychiatric Press; 1997.
- [42] Liebowitz MR, Gorman JM, Fyer AJ, Klein DF. Social phobia - review of a neglected anxiety disorder. *Arch Gen Psychiat* 1985;42(7):729–36.
- [43] Fischl B, Salat DH, Busa E, et al. Whole brain segmentation: automated labeling of neuroanatomical structures in the human brain. *Neuron* 2002;33(3):341–55.
- [44] Reuter M, Schmansky NJ, Rosas HD, Fischl B. Within-subject template estimation for unbiased longitudinal image analysis. *Neuroimage* 2012;61(4):1402–18.
- [45] Fischl B, van der Kouwe A, Destrieux C, et al. Automatically parcellating the human cerebral cortex. *Cerebral cortex* 2004;14(1):11–22.
- [46] Desikan RS, Segonne F, Fischl B, et al. An automated labeling system for subdividing the human cerebral cortex on MRI scans into gyral based regions of interest. *Neuroimage* 2006;31(3):968–80.
- [47] Fischl B, Dale AM. Measuring the thickness of the human cerebral cortex from magnetic resonance images. *P Natl Acad Sci USA* 2000;97(20):11050–5.
- [48] Palaniyappan L, Mallikarjun P, Joseph V, White TP, Liddle PF. Regional contraction of brain surface area involves three large-scale networks in schizophrenia. *Schizophr Res* 2011;129(2–3):163–8.
- [49] Bruno JL, Hosseini SMH, Saggat M, Quintin EM, Raman MM, Reiss AL. Altered brain network segregation in fragile X syndrome revealed by structural connectomics. *Cerebral cortex* 2017;27(3):2249–59.
- [50] van Eijndhoven P, van Wingen G, Katzenbauer M, et al. Paralimbic cortical thickness in first-episode depression: evidence for trait-related differences in mood regulation. *Am J Psychiatry* 2013;170(12):1477–86.
- [51] Mennin DS, Fresco DM, Heimberg RG, Schneier FR, Davies SO, Liebowitz MR. Screening for social anxiety disorder in the clinical setting: using the Liebowitz Social Anxiety Scale. *J Anxiety Disord* 2002;16(6):661–73.
- [52] Xiao Rong, Wu Weili, Zhang Wei. The application of liebowitz social anxiety scale in high schools and universities in Chengdu. *West China Med J* 2007;22(4):708–10.
- [53] Etkin A, Wager TD. Functional neuroimaging of anxiety: a meta-analysis of emotional processing in PTSD, social anxiety disorder, and specific phobia. *Am J Psychiatry* 2007;164(10):1476–88.
- [54] Ronan L, Voets NL, Hough M, et al. Consistency and interpretation of changes in millimeter-scale cortical intrinsic curvature across three independent datasets in schizophrenia. *Neuroimage* 2012;63(1):611–21.
- [55] Park HJ, Lee JD, Kim EY, et al. Morphological alterations in the congenital blind based on the analysis of cortical thickness and surface area. *Neuroimage* 2009;47(1):98–106.
- [56] Durazzo TC, Tosun D, Buckley S, et al. Cortical thickness, surface area, and volume of the brain reward system in alcohol dependence: relationships to relapse and extended abstinence. *Alcohol Clin Exp Res* 2011;35(6):1187–200.
- [57] Abe C, Ekman CJ, Sellgren C, Petrovic P, Ingvar M, Landen M. Cortical thickness, volume and surface area in patients with bipolar disorder types I and II. *J Psychiatry Neurosci* 2016;41(4):240–50.
- [58] Meda SA, Pryweller JR, Thornton-Wells TA. Regional brain differences in cortical thickness, surface area and subcortical volume in individuals with Williams syndrome. *PLoS ONE* 2012;7(2):e31913.
- [59] Schmaal L, Hibar DP, Samann PG, et al. Cortical abnormalities in adults and adolescents with major depression based on brain scans from 20 cohorts worldwide in the ENIGMA major depressive disorder working group. *Mol Psychiatry* 2017;22(6):900–9.
- [60] van Erp TGM, Walton E, Hibar DP, et al. Cortical brain abnormalities in 4474 individuals with schizophrenia and 5098 control subjects via the enhancing neuro imaging genetics through meta analysis (ENIGMA) consortium. *Biol Psychiat* 2018;84(9):644–54.
- [61] Hoogman M, Muetzel R, Guimaraes JP, et al. Brain imaging of the cortex in ADHD: a coordinated analysis of large-scale clinical and population-based samples. *Am J Psychiat* 2019;176(7):531–42.
- [62] Rakic P. Evolution of the neocortex: a perspective from developmental biology. *Nat Rev Neurosci* 2009;10(10):724–35.
- [63] White T, Su S, Schmidt M, Kao CY, Sapiro G. The development of gyrification in childhood and adolescence. *Brain Cogn* 2010;72(1):36–45.
- [64] Petanjek Z, Judas M, Simic G, et al. Extraordinary neoteny of synaptic spines in the human prefrontal cortex. *Proc Natl Acad Sci USA* 2011;108(32):13281–6.
- [65] Aleman-Gomez Y, Janssen J, Schnack H, et al. The human cerebral cortex flattens during adolescence. *J Neurosci* 2013;33(38):15004–10.
- [66] Tamnes CK, Herting MM, Goddings AL, et al. Development of the cerebral cortex across adolescence: a multisample study of inter-related longitudinal changes in cortical volume, surface area, and thickness. *J Neurosci* 2017;37(12):3402–12.
- [67] Miskovic V, Schmidt LA. Social fearfulness in the human brain. *Neurosci Biobehav R* 2012;36(1):459–78.
- [68] Etkin A, Egner T, Kalisch R. Emotional processing in anterior cingulate and medial prefrontal cortex. *Trends Cogn Sci* 2011;15(2):85–93.
- [69] Craig AD. How do you feel? Interoception: the sense of the physiological condition of the body. *Nat Rev Neurosci* 2002;3(8):655–66.
- [70] Kalisch R. The functional neuroanatomy of reappraisal: time matters. *Neurosci Biobehav R* 2009;33(8):1215–26.
- [71] Gross JJ. Emotion regulation: affective, cognitive, and social consequences. *Psychophysiology* 2002;39(3):281–91.
- [72] Tillfors M, Furmark T, Marteinsdottir I, Fredrikson M. Cerebral blood flow during anticipation of public speaking in social phobia: a PET study. *Biol Psychiat* 2002;52(11):1113–9.
- [73] Goldin PR, Manber T, Hakimi S, Canli T, Gross JJ. Neural bases of social anxiety disorder: emotional reactivity and cognitive regulation during social and physical threat. *Arch Gen Psychiatry* 2009;66(2):170–80.
- [74] Raichle ME. The Brain's default mode network. *Annu Rev Neurosci* 2015;38:433–47.
- [75] Robinson OJ, Krinsky M, Lieberman L, Allen P, Vytal K, Grillon C. The dorsal medial prefrontal (anterior cingulate) cortex-amygdala aversive amplification circuit in unmedicated generalised and social anxiety disorders: an observational study. *Lancet Psychiat* 2014;1(4):294–302.
- [76] Ball TM, Ramsawh HJ, Campbell-Sills L, Paulus MP, Stein MB. Prefrontal dysfunction during emotion regulation in generalized anxiety and panic disorders. *Psychol Med* 2013;43(7):1475–86.
- [77] Hiser J, Koenigs M. The Multifaceted Role of the Ventromedial Prefrontal Cortex in Emotion, Decision Making, Social Cognition, and Psychopathology. *Biol Psychiatry* 2018;83(8):638–47.
- [78] Guroglu B, Haselager GJT, van Lieshout CFM, Takashima A, Rijpkema M, Fernandez G. Why are friends special? Implementing a social interaction simulation task to probe the neural correlates of friendship. *Neuroimage* 2008;39(2):903–10.
- [79] Binelli C, Muniz A, Subira S, et al. Facial emotion processing in patients with social anxiety disorder and Williams-Beuren syndrome: an fMRI study. *J Psychiatr Neurosci* 2016;41(3):182–91.
- [80] Blair KS, Geraci M, Korelitz K, et al. The pathology of social phobia is independent of developmental changes in face processing. *Am J Psychiat* 2011;168(11):1202–9.
- [81] Klumpp H, Angststadt M, Phana KL. Insula reactivity and connectivity to anterior cingulate cortex when processing threat in generalized social anxiety disorder. *Biol Psychol* 2012;89(1):273–6.
- [82] Straube T, Kolassa IT, Glauer M, Mentzel HJ, Miltner WHR. Effect of task conditions on brain responses to threatening faces in social phobics: an event-related functional magnetic resonance Imaging study. *Biol Psychiat* 2004;56(12):921–30.
- [83] Blair KS, Geraci M, Hollon N, et al. Social norm processing in adult social phobia: atypically increased ventromedial frontal cortex responsiveness to unintentional (embarrassing) transgressions. *Am J Psychiatry* 2010;167(12):1526–32.
- [84] Bas-Hoogendam JM, van Steenbergen H, Tissing RLM, van der Wee NJA, Westenberg PM. Altered neurobiological processing of unintentional social norm violations: a multiplex, multigenerational functional magnetic resonance imaging study on social anxiety endophenotypes. *Biol Psychiatry Cogn Neurosci Neuroimaging* 2019.
- [85] Phelps EA, Delgado MR, Nearing KI, LeDoux JE. Extinction learning in humans: role of the amygdala and vmPFC. *Neuron* 2004;43(6):897–905.
- [86] Milad MR, Quinn BT, Pitman RK, Orr SP, Fischl B, Rauch SL. Thickness of ventromedial prefrontal cortex in humans is correlated with extinction memory. *P Natl Acad Sci USA* 2005;102(30):10706–11.
- [87] Milad MR, Rauch SL. The role of the orbitofrontal cortex in anxiety disorders. *Ann NY Acad Sci* 2007;1121:546–61.
- [88] O'Doherty J, Kringelbach ML, Rolls ET, Hornak J, Andrews C. Abstract reward and punishment representations in the human orbitofrontal cortex. *Nat Neurosci* 2001;4(1):95–102.
- [89] Rauch SL, Shin LM, Phelps EA. Neurocircuitry models of posttraumatic stress disorder and extinction: human neuroimaging research - past, present, and future. *Biol Psychiatry* 2006;60(4):376–82.
- [90] Tillfors M, Furmark T, Marteinsdottir I, et al. Cerebral blood flow in subjects with social phobia during stressful speaking tasks: a PET study. *Am J Psychiat* 2001;158(8):1220–6.
- [91] Cisler JM, Koster EHW. Mechanisms of attentional biases towards threat in anxiety disorders: an integrative review. *Clin Psychol Rev* 2010;30(2):203–16.
- [92] Bruhl AB, Delsignore A, Komossa K, Weidt S. Neuroimaging in social anxiety disorder—a meta-analytic review resulting in a new neurofunctional model. *Neurosci Biobehav Rev* 2014;47(260–80).

- [93] Rapee RM, Spence SH. The etiology of social phobia: empirical evidence and an initial model. *Clin Psychol Rev* 2004;24(7):737–67.
- [94] Steiger VR, Bruhl AB, Weidt S, et al. Pattern of structural brain changes in social anxiety disorder after cognitive behavioral group therapy: a longitudinal multimodal MRI study. *Mol Psychiatr* 2017;22(8):1164–71.
- [95] Cassimjee N, Fouché JP, Burnett M, et al. Changes in regional brain volumes in social anxiety disorder following 12 weeks of treatment with escitalopram. *Metab Brain Dis* 2010;25(4):369–74.
- [96] Gentili C, Gobbi MI, Ricciardi E, et al. Differential modulation of neural activity throughout the distributed neural system for face perception in patients with Social Phobia and healthy subjects. *Brain Res Bull* 2008;77(5):286–92.
- [97] Allison T, Puce A, McCarthy G. Social perception from visual cues: role of the STS region. *Trends Cogn Sci* 2000;4(7):267–78.
- [98] Fonzo GA, Ramsawh HJ, Flagan TM, et al. Common and disorder-specific neural responses to emotional faces in generalised anxiety, social anxiety and panic disorders. *Brit J Psychiatr* 2015;206(3):206–15.
- [99] Zahn R, Moll J, Paiva M, et al. The neural basis of human social values: evidence from functional MRI. *Cerebral cortex* 2009;19(2):276–83.
- [100] Terasawa Y, Fukushima H, Umeda S. How does interoceptive awareness interact with the subjective experience of emotion? An fMRI Study. *Hum Brain Mapp* 2013;34(3):598–612.
- [101] Ganis G, Thompson WL, Kosslyn SM. Brain areas underlying visual mental imagery and visual perception: an fMRI study. *Brain Res Cogn Brain Res* 2004;20(2):226–41.
- [102] Fischl B. FreeSurfer. *Neuroimage* 2012;62(2):774–81.
- [103] Fischl B, Dale AM. Measuring the thickness of the human cerebral cortex from magnetic resonance images. *Proc Natl Acad Sci USA* 2000;97(20):11050–5.
- [104] Morey RA, Petty CM, Xu Y, et al. A comparison of automated segmentation and manual tracing for quantifying hippocampal and amygdala volumes. *Neuroimage* 2009;45(3):855–66.
- [105] Lieberman MD, Cunningham WA. Type I and Type II error concerns in fMRI research: re-balancing the scale. *Soc Cogn Affect Neurosci* 2009;4(4):423–8.
- [106] Palaniyappan L, Mallikarjun P, Joseph V, White TP, Liddle PF. Folding of the prefrontal cortex in schizophrenia: regional differences in gyrification. *Biol Psychiatry* 2011;69(10):974–9.
- [107] Palaniyappan L, Liddle PF. Differential effects of surface area, gyrification and cortical thickness on voxel based morphometric deficits in schizophrenia. *Neuroimage* 2012;60(1):693–9.
- [108] Kilts CD, Kelsey JE, Knight B, et al. The neural correlates of social anxiety disorder and response to pharmacotherapy. *Neuropsychopharmacol* 2006;31(10):2243–53.
- [109] Canu E, Kostic M, Agosta F, et al. Brain structural abnormalities in patients with major depression with or without generalized anxiety disorder comorbidity. *J Neurol* 2015;262(5):1255–65.
- [110] Koyuncu A, Ince E, Ertekin E, Tukul R. Comorbidity in social anxiety disorder: diagnostic and therapeutic challenges. *Drugs Context* 2019;8:212573.
- [111] Liebowitz MR, Careri J, Blatt K, et al. Vortioxetine versus placebo in major depressive disorder comorbid with social anxiety disorder. *Depress Anxiety* 2017;34(12):1164–72.
- [112] Mayberg HS, Lozano AM, Voon V, et al. Deep brain stimulation for treatment-resistant depression. *Neuron* 2005;45(5):651–60.
- [113] deCharms RC, Maeda F, Glover GH, et al. Control over brain activation and pain learned by using real-time functional MRI. *Proc Natl Acad Sci U S A* 2005;102(51):18626–31.
- [114] Cohen H, Kaplan Z, Kotler M, Kouperman I, Moisa R, Grisaru N. Repetitive transcranial magnetic stimulation of the right dorsolateral prefrontal cortex in post-traumatic stress disorder: a double-blind, placebo-controlled study. *Am J Psychiatry* 2004;161(3):515–24.
- [115] Hoogendam JM, Ramakers GM, Di Lazzaro V. Physiology of repetitive transcranial magnetic stimulation of the human brain. *Brain Stimul* 2010;3(2):95–118.
- [116] Frick A. Common and distinct gray matter alterations in social anxiety disorder and major depressive disorder. *EBioMedicine* 2017;21:53–4.
- [117] Otowa T, Hek K, Lee M, et al. Meta-analysis of genome-wide association studies of anxiety disorders. *Mol Psychiatry* 2016;21(10):1391–9.
- [118] Bas-Hoogendam JM, Blackford JU, Bruhl AB, Blair KS, van der Wee NJA, Westenberg PM. Neurobiological candidate endophenotypes of social anxiety disorder. *Neurosci Biobehav Rev* 2016;71(362–78).
- [119] McDaniel MA. Big-brained people are smarter: a meta-analysis of the relationship between in vivo brain volume and intelligence. *Intelligence* 2005;33(4):337–46.