

6-1985

Enteroclysis for the Examination of the Small Bowel

Robert D. Halpert

Peter J. Feczko

Cathrine E. Keller

Judith Iorio

Follow this and additional works at: <https://scholarlycommons.henryford.com/hfhmedjournal>



Part of the [Life Sciences Commons](#), [Medical Specialties Commons](#), and the [Public Health Commons](#)

Recommended Citation

Halpert, Robert D.; Feczko, Peter J.; Keller, Cathrine E.; and Iorio, Judith (1985) "Enteroclysis for the Examination of the Small Bowel," *Henry Ford Hospital Medical Journal* : Vol. 33 : No. 2 , 116-121.
Available at: <https://scholarlycommons.henryford.com/hfhmedjournal/vol33/iss2/17>

This Article is brought to you for free and open access by Henry Ford Health System Scholarly Commons. It has been accepted for inclusion in Henry Ford Hospital Medical Journal by an authorized editor of Henry Ford Health System Scholarly Commons.

Enteroclysis for the Examination of the Small Bowel

Robert D. Halpert, MD,* Peter J. Feczko, MD,* Cathrine E. Keller, MD,† and Judith Iorio, RT*

Detailed evaluation of the small bowel is difficult because of its inaccessibility. The small bowel follow-through examination using barium, has low diagnostic sensitivity. Enteroclysis, the injection of contrast material through a

duodenal or jejunal tube, offers a newer and highly sensitive method of radiological evaluation. Our paper describes the technique, clinical indications, and side effects of enteroclysis.

Traditionally, diagnostic evaluation of the small bowel has depended on the small bowel follow-through (SBFT) examination using barium. However, the effectiveness of this method has been limited by its low diagnostic sensitivity (1) and by the inaccessibility of the small bowel itself. Despite considerable advances in fiberoptic endoscopy of the gastrointestinal tract, development of better techniques to evaluate the small bowel is much needed. Tubal installation of barium, or enteroclysis, has long been known (2), but its use has been quite limited until recently because it has been associated with considerable patient discomfort. Now, as a result of technical improvements, enteroclysis is being used more widely (3).

Comparison of Small Bowel Follow-through with Enteroclysis

In 1982, 854 SBFT studies were performed at our institution. Diagnostic evaluation was based on the interpretation of intermittent radiographs of the small bowel (Fig 1) obtained after the patient had ingested a large amount of barium; the procedure was continued until barium reached the colon. If the loop of bowel where a lesion occurred was not filled or if adjacent barium-filled loops covered the loop in question, lesions of considerable size might be missed (4).

By contrast, the enteroclysis examination can provide detailed evaluation of the entire small bowel from the ligament of Treitz to the ileocecal valve (Fig 2). The radiologist performs intermittent fluoroscopy during the entire examination and, using a compression technique, examines each loop of bowel as it becomes distended with contrast medium. Diagnostic evaluation by enteroclysis can be made with some confidence, whereas the SBFT examination is at best a good survey technique. While the SBFT examination is suitable for evaluation of diseases that diffusely involve all or major portions of the small bowel, it is particularly weak in the identification of focal lesions (5).

Technique

Before the examination, 10 mg of metaclopramide is administered intravenously. This is usually withheld if there is clinical

and radiologic evidence of significant small bowel obstruction. After a topical anesthetic has been applied to the posterior pharynx, a 12-polyvinyl enterostomy tube is passed through the patient's mouth and into the stomach. A guidewire is then introduced through the tube to control the direction of the tube tip so that it can be maneuvered through the stomach and pyloric channel into the duodenum. If the tip extends beyond the ligament of Treitz, the final position of the tube is considered to be optimal (Fig 3). An electric pumping device is used to instill a dilute barium sulfate suspension at a constant flow rate. Fluoroscopic evaluation of each loop of bowel is undertaken by means of compression technique and 100-mm camera spot radiographs. Both the metaclopramide and the installation of contrast medium into the small bowel stimulate peristaltic activity and move the barium column along. Behind the head of the column where maximal distention occurs, detailed mucosal evaluation is possible because of physiological hypotonia resulting from bowel distention. The examination is complete when barium reaches the cecum, usually within 10 to 15 minutes. Factors that may delay the passage of barium include dilated, fluid-filled loops of bowel (secondary to obstruction or ileus) or inadequate patient bowel preparation.

Patient Preparation

Adequacy of the bowel preparation before the examination will determine the rate of passage of barium to the cecum. In our experience, a full colonic preparation like that performed before a double-contrast barium enema examination is necessary. An empty collapsed cecum and right colon facilitate movement of the barium column through the ileum, whereas residual fluid or fecal material will decelerate the

Submitted for publication: February 27, 1985

Accepted for publication: April 27, 1985

*Department of Diagnostic Radiology, Division of Gastrointestinal Radiology, Henry Ford Hospital

†Department of Diagnostic Radiology, Henry Ford Hospital

Address reprint requests to Dr Halpert, Department of Diagnostic Radiology, Henry Ford Hospital, 2799 W Grand Blvd, Detroit, MI 48202.

Acceptable
tion shows

barium co
nificant il
occurs, th
loops of s
sure of th
barium m
discomfo
tory bowe
recomme
teroclysis

No comp
enterocly
method. s
asionally
dary to th
A few pa
flux durin
which pe
jejunum,

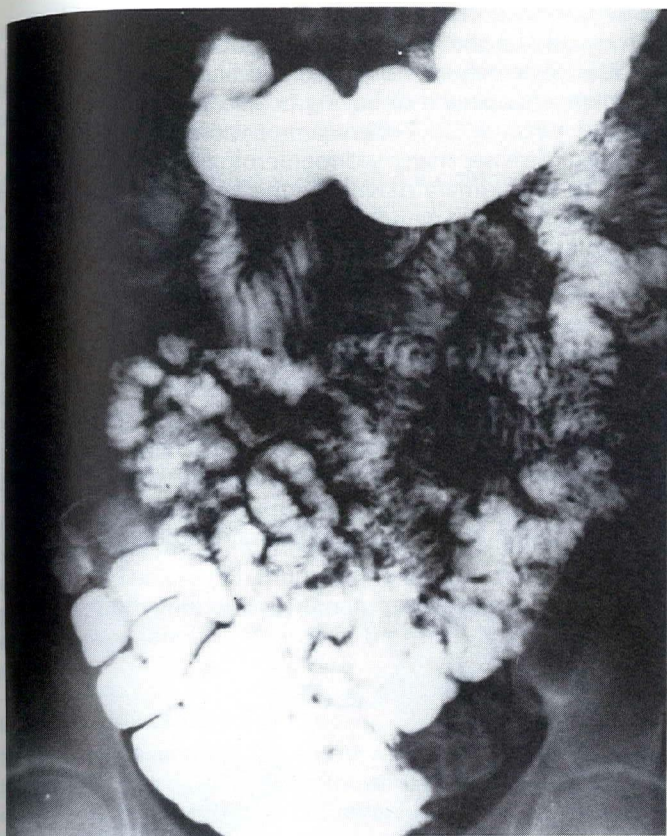

Fig 1

Acceptable static image from routine small bowel follow-through examination shows partial filling of jejunal loops and overlapping ileal loops.

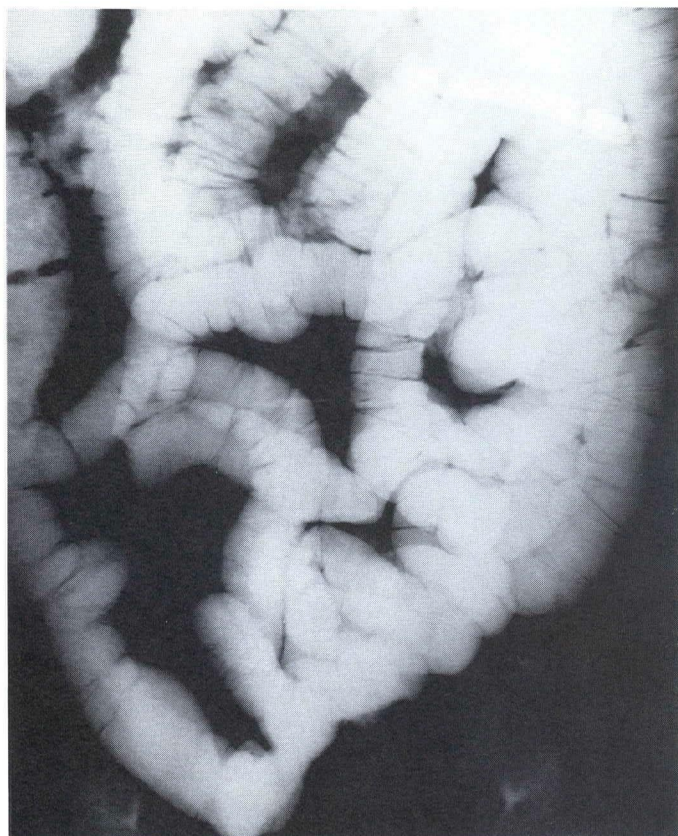


Fig 2

Routine overhead image from normal enteroclysis examination demonstrates adequate distention of all loops of small bowel including the ileum.

barium column in the distal small bowel and produce significant ileal hypotonia at the head of the column. When this occurs, the column must be moved through the last several loops of small bowel solely by means of the hydrostatic pressure of the infusion pump. As a result, not only does the barium move slowly, but the patient also experiences more discomfort. Except for patients who have active inflammatory bowel disease or significant mechanical obstruction, we recommend a full colonic bowel preparation before the enteroclysis examination.

Side Effects and Complications

No complications have been associated with the small bowel enteroclysis examination in the three years we have used the method. Side effects are uncommon and generally mild. Occasionally, diarrhea is reported after the examination, secondary to the fluid volume infused into the gastrointestinal tract. A few patients may vomit because of duodenal gastric reflux during the examination, but the use of the electric pump, which permits continuous, controlled barium delivery to the jejunum, greatly lowers the incidence of reflux.

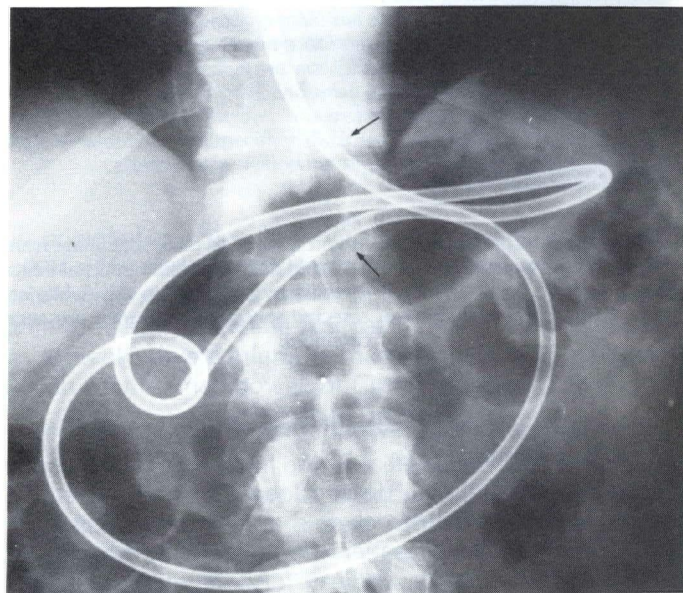


Fig 3

Optimal placement of tube beyond ligament of Treitz. Upper arrow demonstrates gastroesophageal junction, and lower arrow indicates level of ligament of Treitz. Tip of tube is just distal to ligament.

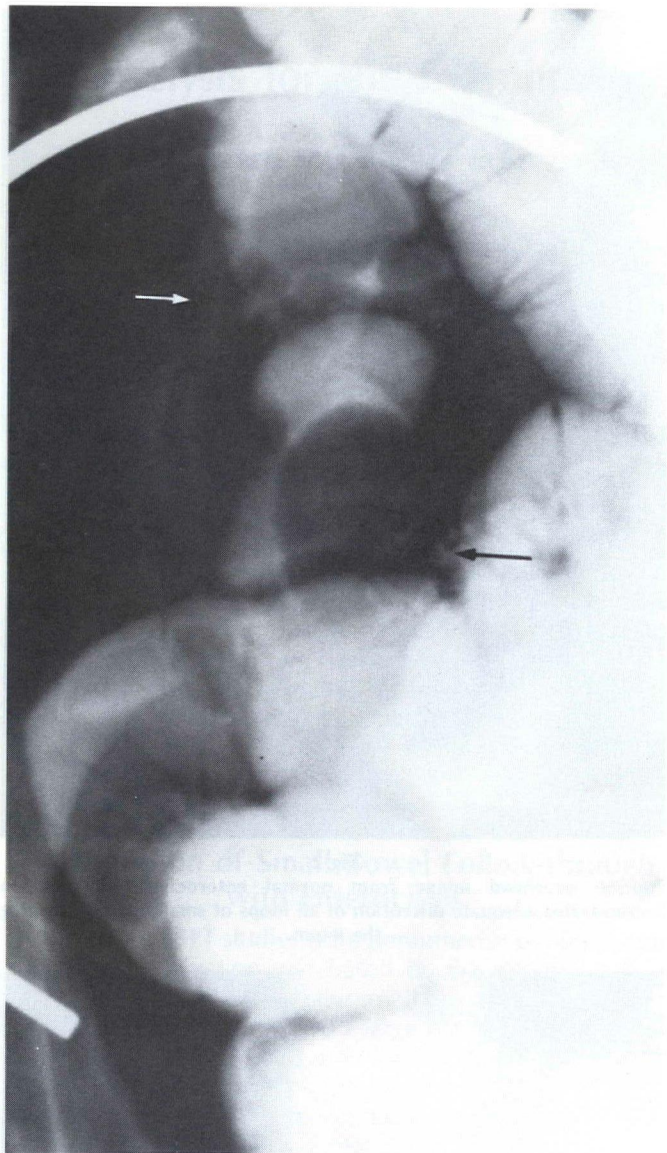


Fig 4

Male patient who presented with chronic abdominal pain. Spot image from enteroclysis examination reveals an ovoid polypoid lesion in distal ileum (black arrow) as well as nodular irregularity just distal to this (white arrow). Histological evaluation of resected specimen confirmed presence of carcinoid.

Clinical Indications

Chronic abdominal pain

Because of its ability to distend loops of small bowel in a controlled manner, enteroclysis should be used in the diagnostic examination of patients who present with chronic abdominal pain that may indicate focal stenotic small bowel lesions (6). Inflammatory or malignant strictures, adhesive bands, focal ischemic changes or narrowing secondary to lesions such as carcinoid (Fig 4) are optimally demonstrated by enteroclysis. In addition, polypoid lesions causing inter-

mittent intussusception as well as early metastatic disease can usually be shown to advantage. Both are easily missed by SBFT. Enteroclysis is also used to evaluate the small bowel in patients suspected of having or known to have Crohn's disease. Because SBFT often cannot accurately evaluate the extent of disease, many gastroenterologists rely on enteroclysis as the primary diagnostic method. Proximal or skip lesions can be well demonstrated (Fig 5), and the possibility of finding fistulous connections is also increased.

Small bowel obstruction

There is disagreement among both radiologists and surgeons about the role of enteroclysis in patients who present with clinical and radiographic findings of small bowel obstruction. Some advocate enteroclysis examination for all such patients, while others do not agree (7). The aim of the small bowel contrast examination in this clinical setting is to confirm the clinical suspicion of the obstructive lesion, identify the level of the lesion, and demonstrate radiographically its

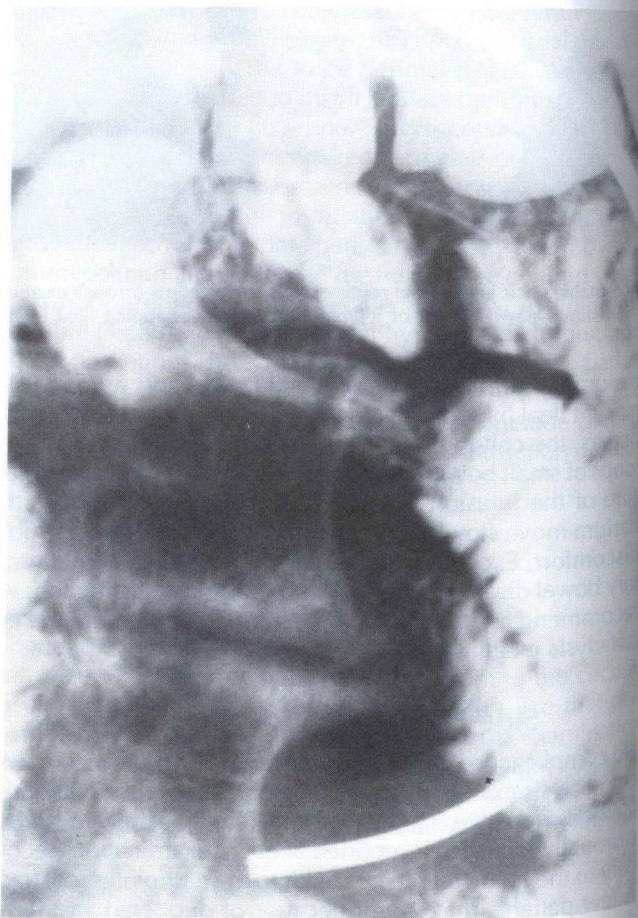

Fig 5

Male patient who presented with chronic abdominal pain. Findings of all previous endoscopic and radiographic evaluations were normal. Spot radiograph obtained during enteroclysis examination revealed area of focal stricture in middle jejunum. Surgical resection of this area revealed isolated and focal involvement of Crohn's disease.

physical cha
(Fig 6). Altho
its use is mo
obstruction
tive site ma

SBFT exami
occasionally
ing small bo
helpful in de
cess by noti
the colon, n
cause of the
over, the hi
draws addit
of the bowe
nature of th

Routine SBFT
helpful in di
tive lesion.
problem; be
ed that insp
occur (8).

Gastrointe

Enteroclysi
tion of acut
in whom e
upper and
a bleeding
chronic ga

Male patient
radiograph
intact muco
Resected sp

physical characteristics to offer a more definitive diagnosis (Fig 6). Although enteroclysis can best achieve these goals, its use is most profitable in minor to moderate degrees of obstruction in which the exact localization of the obstructive site may be unclear on the SBFT.

SBFT examination using water soluble contrast material is occasionally performed in patients who are suspected of having small bowel obstruction. While this procedure may be helpful in demonstrating the presence of an obstructive process by noting the delayed passage of contrast material into the colon, marked dilution of the contrast agent occurs because of the retained fluid above an obstructive lesion. Moreover, the high osmolality of water soluble contrast material draws additional fluid into the gut and makes visualization of the bowel unlikely. In most patients, the precise level and nature of the obstructive process cannot be determined.

Routine SBFT examination using barium is somewhat more helpful in demonstrating the level and nature of the obstructive lesion. The use of barium will not aggravate the clinical problem; both animal and human studies have demonstrated that inspissation of barium in the small bowel does not occur (8).

Gastrointestinal bleeding

Enteroclysis examination can be very useful in the evaluation of acute or chronic gastrointestinal bleeding in patients in whom endoscopic and radiographic examination of the upper and lower gastrointestinal tract has failed to identify a bleeding site. Although the small bowel is the source of chronic gastrointestinal bleeding in relatively few patients,

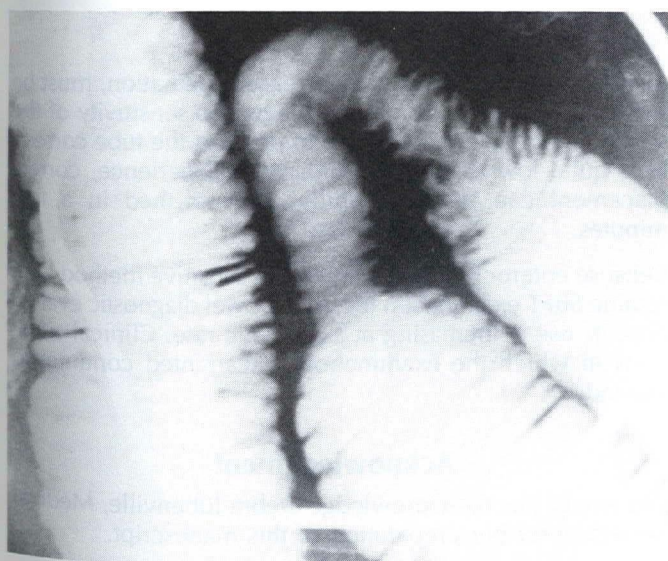


Fig 6

Male patient who presented with intermittent severe abdominal pain. Spot radiograph from enteroclysis examination shows area of focal narrowing, intact mucosa, and some evidence of wall thickening in proximal jejunum. Resected specimen demonstrated fibrotic changes secondary to focal ischemic disease.

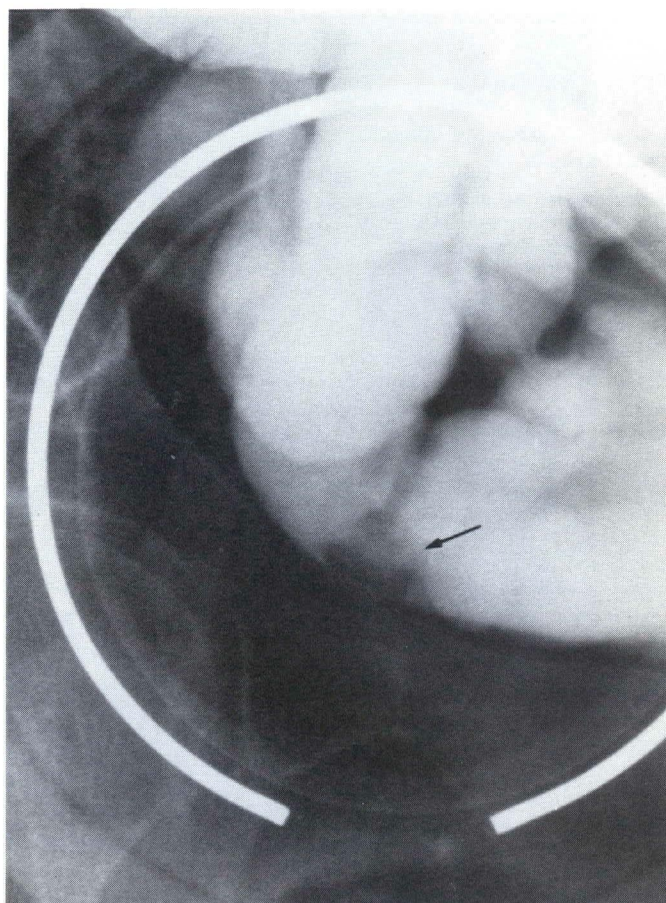


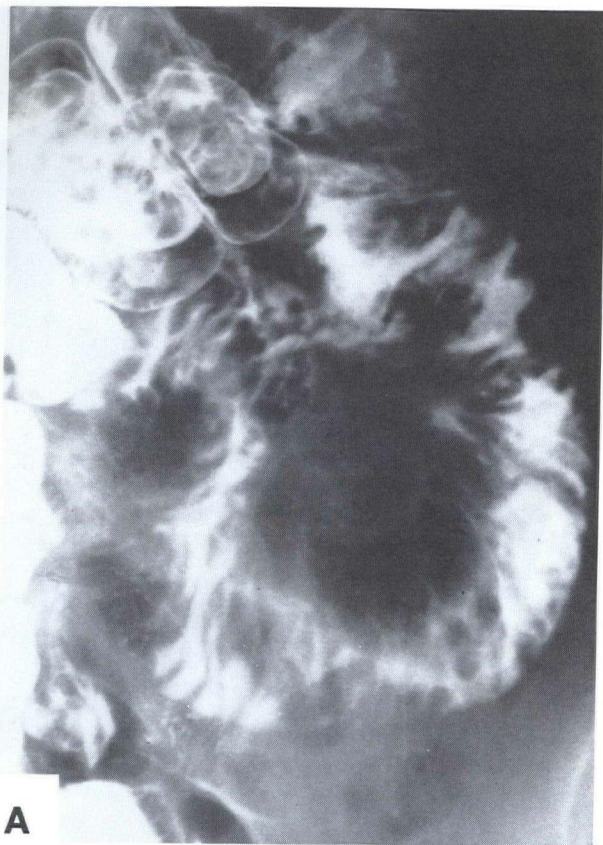
Fig 7

Male patient who presented with intermittent gastrointestinal bleeding. Upper and lower tract radiographic and endoscopic examinations revealed no source of bleeding. Findings of small bowel follow-through examinations were interpreted as normal. Examination of small bowel using enteroclysis was performed, and small polypoid filling defect was identified in the distal ileum (arrow). This area was surgically resected, and pathological examination of specimen disclosed a submucosal hematoma of uncertain origin. Following surgery, bleeding ceased.

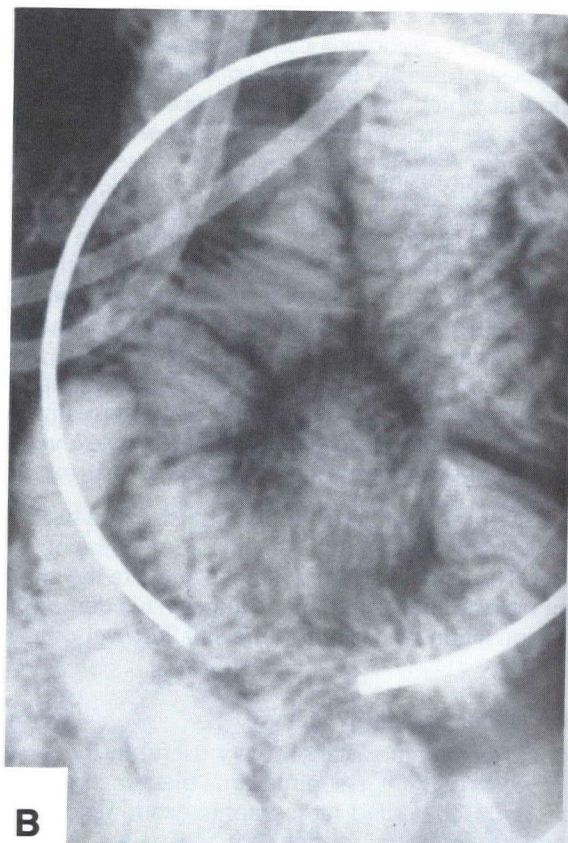
its potential as a bleeding source greatly increases when all other types of diagnostic studies have been negative. Even when findings of SBFT are negative, enteroclysis has been able to identify bleeding sources in the small bowel such as Meckel's diverticulum, primary or metastatic malignant lesions of the small bowel, or Crohn's disease (5,9) (Fig 7).

Inconclusive small bowel follow-through examinations

Examination of the small bowel using enteroclysis is extremely effective at confirming or excluding questionable lesions identified by findings of routine SBFT examination (Fig 8). In our institution, enteroclysis is most commonly used for those patients whose SBFT examinations are inconclusive. Radiographs of the small bowel obtained intermittently during the routine SBFT procedure may have a false positive interpretation. Areas of focal spasm may be interpreted as stenotic lesions; air bubbles or food that present as filling



A



B

Fig 8

Young woman referred for evaluation of possible small bowel lymphoma. Representative radiograph from small bowel follow-through examination (A) demonstrates numerous nodular irregularities in middle jejunum, resulting in diagnosis of possible lymphoma. Spot radiograph from enteroclysis examination (B) demonstrates normal appearing jejunum.

defects may be erroneously interpreted as polypoid processes. Conversely, because lesions may be hidden in the barium column or may occur in nonbarium filled loops, findings of the routine SBFT examination can commonly be incorrectly interpreted as normal. In addition, both the head and tail of the barium column may look grossly abnormal due to partial filling and peristaltic activity rather than for pathological reasons.

Discussion

Use of small bowel enteroclysis is increasing. In 1984, of 932 SBFT examinations performed in our department, 73 were enteroclysis studies (7.8%). By contrast, 18 and 37 enteroclysis examinations were performed in 1982 and 1983, respectively. During 1984, only 23.9% of SBFT but 41.1% of enteroclysis examinations revealed demonstrable abnormalities. The major disadvantage of enteroclysis, the degree of patient discomfort associated with the peroral passage of

a jejunal tube as well as the increased irradiation, must be weighed against the improved diagnostic sensitivity of the study. The frequency of failure to position the tube correctly is quite low (6.4% in 1984). With experience, correct placement can be successfully accomplished in a few minutes.

Because enteroclysis is a much more sensitive method than routine SBFT examination for small bowel diagnostic evaluation, its use is increasing at a dramatic rate. Clinical situations in which the examination is warranted continue to expand.

Acknowledgment

We would like to acknowledge Debra Jubenville, Medical Secretary, for her preparation of this manuscript.

1. Diner WC, H... intestine: Revi... South Med J
2. Pesquera GS... intestine. AJF
3. Sellink JL. Ex... tubation. Lei
4. Magliante DC... follow-throu... 144:737-9.
5. Sanders SE, ... aminations.

References

1. Diner WC, Hoskins EOL, Navab F. Radiologic examination of the small intestine: Review of 402 cases and discussion of indications and methods. *South Med J* 1984;77:68-74.
2. Pesquera GS. A method for the direct visualization of lesions in the small intestine. *AJR* 1929;22:254-7.
3. Sellink JL. Examination of the small intestine by means of duodenal intubation. Leiden: Stenfert Kroese, 1971.
4. Maglinte DDT, Burney BT, Miller RE. Lesions missed on small bowel follow-through: Analysis and recommendations. *Radiology* 1982;144:737-9.
5. Sanders SE, Ho CS. The small bowel enema: Experience with 150 examinations. *AJR* 1976;127:743-51.
6. Maglinte DDT, Peterson LA, Vahey TN, Miller RE, Chernish SM. Enteroclysis in partial small bowel obstruction. *Am J Surg* 1984;147:325-9.
7. Caroline DF, Herlinger H, Laufer I, Kressel HY, Levine MS. Small-bowel enema in the diagnosis of adhesive obstructions. *AJR* 1984;142:1133-9.
8. Nelson SW, Christoforidis AJ, Roenigk WJ. Barium suspensions versus water-soluble iodine compounds in the study of obstruction of the small bowel. An experimental study of physiological characteristics and radiographic value. *Radiology* 1963;80:252-4.
9. Maglinte DDT, Elmore MF, Isenberg M, Dolan PA. Meckel diverticulum: Radiologic demonstration by enteroclysis. *AJR* 1980;134:925-32.