

## Original Article

DOI: 10.22114/ajem.v0i0.126

## Efficacy of Half-length vs. Standard-sized Short Arm splint in Soft Tissue Injuries of the Hand and Wrist: a Randomized Controlled Trial

Mohammadreza Yasinzadeh<sup>1</sup>, Hamed Basir-Ghafouri<sup>1</sup>, Niloofar Abazarian<sup>2</sup>, Seyed-Mohammad Hosseini-Kasnavieh<sup>1</sup>, Shahrzad Behjat<sup>1\*</sup>

1. Trauma and Injury Research Center, Iran University of Medical Sciences, Tehran, Iran.

2. School of Medicine, Alborz University of Medical Sciences, Karaj, Iran.

\*Corresponding author: Shahrzad Behjat; Email: shahrzadbehjat@yahoo.com

Published online: 2019-02-28

### Abstract

**Introduction:** Hand and wrist soft tissue injuries are common orthopedic problems that are traditionally treated with short arm splint, which covers the forearm to 1 cm distal to the elbow crease.

**Objective:** The present study was conducted to compare the treatment efficacy of traditional standard-size splint with half-length short arm splint.

**Method:** In this randomized, controlled, clinical trial, patients with hand and wrist soft tissue injuries were randomly assigned to two groups. Group one received standard-sized short arm splints and the other group received half-length short arm splints. The swelling and pain scores were compared between the groups by the end of weeks one, two and three.

**Results:** A total of 256 patients with a mean age of  $36.96 \pm 12.27$  years were enrolled in this study, and 71.9% of them were male. No statistically significant differences were observed in terms of swelling between the two groups after one and two weeks ( $P=0.41$ ,  $P=0.18$ ). None of the patients had swelling after three weeks. No statistically significant differences were observed between the two groups in terms of the pain score after one, two and three weeks ( $P=0.47$ ,  $P=0.29$ ,  $P=0.92$ ).

**Conclusion:** In this study, half-length short arm splints were found to be as effective as standard short arm splints.

**Key words:** Immobilization; Hand; Soft Tissue Injuries; Splints; Wrist

**Cite this article as:** Yasinzadeh M, Basir-Ghafouri H, Abazarian N, Hosseini-Kasnavieh SM, Behjat S. Efficacy of Half-length vs. Standard-sized Short Arm splint in Soft Tissue Injuries of the Hand and Wrist: a Randomized Controlled Trial. *Adv J Emerg Med.* 2019;3(2): e16.

### INTRODUCTION

Limb injuries are a common cause for emergency medical visits and are quite broad in range, from complicated fractures and amputations to minor soft tissue injuries. Although soft tissue injuries do not need surgical interventions and do not cause permanent disability, they have a considerable impact on the patients' functioning and can limit their daily and professional abilities. The mismanagement of soft tissue injuries can prolong patient suffering and increase the time needed to reach baseline abilities. Immobilization is one of the most common treatments known for soft tissue injuries. Theoretically, immobilization facilitates the healing process by decreasing pain and protecting the extremity from further injury (1). Immobilization prevents repeated bleeding, and secondary injury to the healing tissue (2). It helps the fibroblasts properly invade the injured area in the early phase of healing, which leads to cell proliferation and collagen fiber production. During

this time, mobilization enhances type-3 collagen production and the formation of weaker tissues (3). The most popular method for ensuring immobilization at Emergency Departments (EDs) worldwide is splinting with plaster cast. Although orthopedic immobilization devices are available in different forms, plaster splints are still the most common way for limb immobilization because of their lower costs, availability and compatibility with the patients' individual limb size and length. The splint that is used for wrist and hand immobilization is short arm splint, which covers the interphalangeal joints and metacarpal bones and extends 1 cm distal to the elbow crease or just proximal to the elbow (4, 5).

Recent studies have questioned the common methods and previous standard lengths of splints and casts (6-9). Shorter arm splints have been shown to preserve the normal range of motion of the metacarpophalangeal joint at the distal end (6).

Short arm radial gutter splint showed comparable performance to long arm sugar tong splint for the initial immobilization of distal radius fractures (10, 11). Another study compared sugar tong splint with short arm double splint after distal radius fracture reduction and similarly reported that the loss of reduction was not different between these two immobilization methods (7). There are also studies on the costs and benefits of immobilization techniques (8). Some studies have examined simpler and more comfortable methods such as the use of splints rather than casting and have generally concluded that splinting is as effective as casting and improves the patients' satisfaction and function (12- 15).

Although the length of the short arm splint is not well studied and no strong evidence was found on the exact proximal end of the short arm splint, the definition noted earlier is accepted as the standard length. The heavy weight of this type of splint causes discomfort for the patient and can lead to poor compliance with the treatment and an immature discontinuation of splint use; therefore, if splints can be shortened, the patient will experience more comfort and have a higher tolerance. In addition, less plasters would be used for making a single splint and the costs will consequently be lowered. This study was conducted to compare the use of standard-sized short arm splint with half-length short arm splint for the treatment of soft tissue injuries in terms of reducing the pain score and swelling.

## METHODS

### *Study design and setting*

This randomized controlled trial was conducted from April 2016 to March 2017 at Haftom-e-Tir Hospital –a major trauma center in the south of Tehran, Iran. The data collectors and analyzers were blinded to the group allocations. The research project was approved by the ethics committee of Iran University of Medical Sciences in Tehran, Iran (Ethics Code: 9311307006) and registered at the Iranian Registry of Clinical Trials (IRCT20170105031787N; <http://www.irct.ir>). Written informed consent was obtained from all the patients prior to entering the study. The researchers fully adhered to the Declaration of Helsinki Principles throughout the study.

### *Participants*

All the patients over age 18 who visited the ED with upper extremity trauma distal to the elbow and diagnosed with soft tissue injury during the study period were included using convenience sampling. Standard short arm splints were used for the

control group and half-length short arm splints for the intervention group.

The exclusion criteria were defined as the presence of fracture anywhere distal to the elbow, visiting the ED more than 24 hours after the injury, soft tissue injury requiring surgical intervention and the presence of lacerations. The diagnosis of fractures was based on any imaging modality chosen at the physician's discretion (X-ray or CT scan).

Based on a similar study on the subject, the minimum sample size was estimated as 135 per group (13). This sample size would yield an 80% power to detect a minimally-significant difference of 1.3 points (16) on the numeric rating scale at the significance level of 5%.

### *Randomization*

The participants were randomly assigned to two groups using simple randomization with a computer-generated sequence table. The emergency medicine attendant supervising the study also performed the randomization sequence; the PGY-3 emergency medicine resident who cooperated with the study as a researcher then selected the participants based on the defined inclusion criteria. Allocation was carried out by the head nurse of the clinical shift in the ED, who was blinded to the intervention.

### *Intervention*

The splints were composed of eight to ten plaster layers (B.P.I Co., Iran) wrapped in cotton pads placed in the volar position of the arm, beginning from the phalanxes tips in hand injuries and metacarpal head in wrist injuries to 1 cm distal to the elbow crease in the control group and the mid-forearm in the intervention group.

### *Outcome Measures*

Outcome measures included the patients' pain score and the presence or absence of swelling. Pain scores were assessed using the Numeric Rating Scale (NRS) with the minimum of 0 indicating 'no pain' and the maximum of 10 indicating 'the worst pain ever'. The pain scores and swelling were recorded at the initial ED visit before receiving any analgesics, and then, by the end of weeks one, two and three of splinting (i.e. during the follow-up), the pain score (NRS) and swelling status were recorded by phone calls. The research collaborator in charge of the follow-up was also blinded to the group allocation.

### *Statistical Analysis*

Data were analyzed in SPSS-24 using the per protocol method. The normality of data distribution was tested using the Kolmogorov-Smirnov test. The parametric analysis was carried

out using the independent T-test and the non-parametric analysis using Mann-Whitney's test. The Chi-square test was also used for comparing the nominal data. P-value<0.05 was considered statistically significant.

**RESULTS**

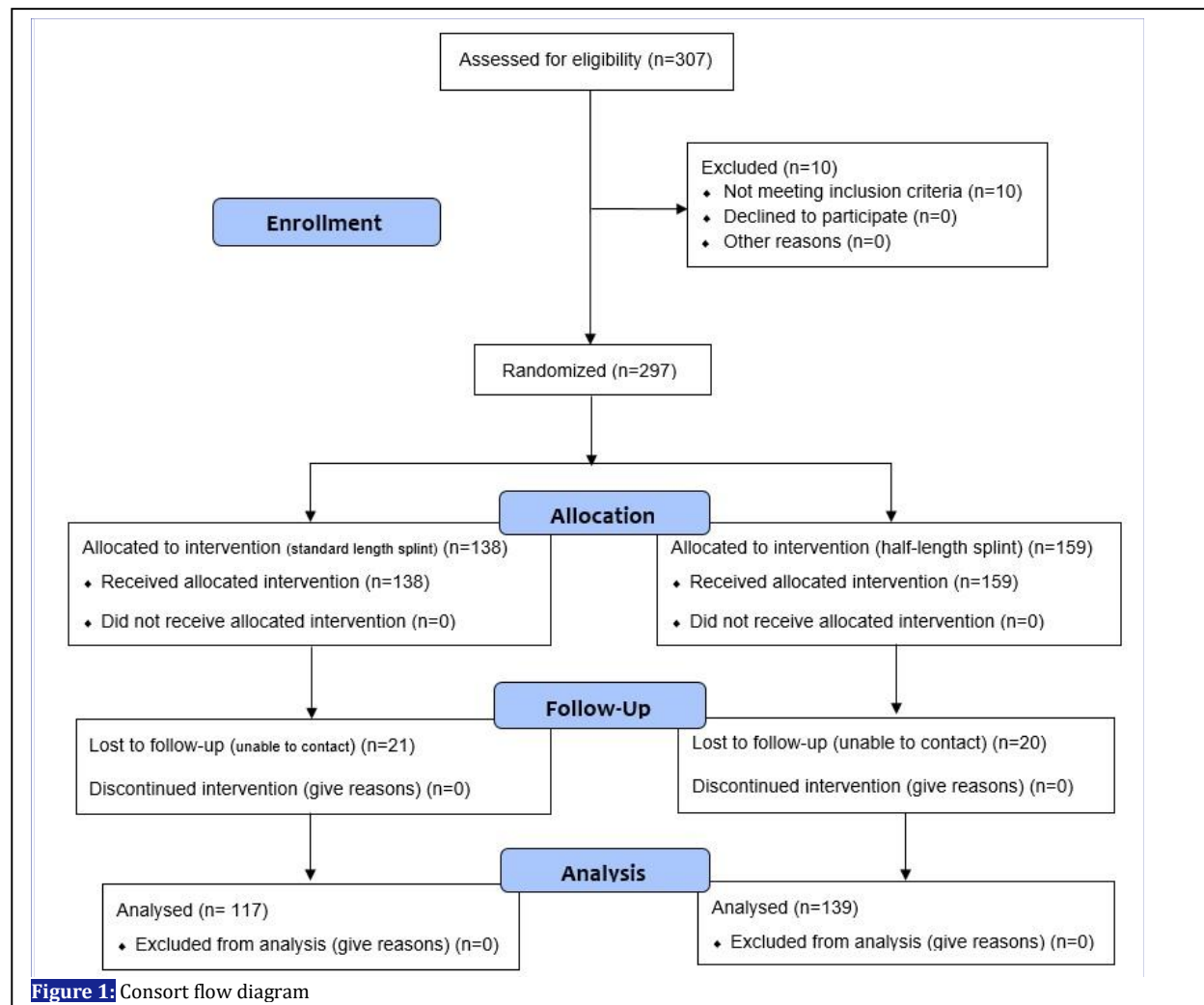
During the study period, a total of 307 patients visiting the ED of Haftom-e-Tir Hospital were enrolled through convenience sampling. Ten patients were excluded for not meeting the inclusion criteria; the remaining 297 patients were randomly allocated to two groups. A total of 138 patients entered the standard-length splint group and 159 entered the half-length splint group. Among them, 21 patients in the standard splint group and 20 patients in the half-length splint were excluded due to their unavailability for follow-up. Five patients in each group were excluded for having late-diagnosed fractures. Ultimately, 256 patients (117 in the standard-length splint group

and 139 in the half-length splint group) were analyzed. Figure 1 presents the CONSORT flow diagram.

Among the subjects analyzed, 71.9% were male and 28.1% were female. The mean age of the participants was  $36.96 \pm 12.27$  years. No statistically significant differences were observed between the two groups at baseline in terms of characteristics including age, gender, presence of swelling and initial pain score (Table 1).

After one week, 23 patients (19.7%) in the standard splint group and 33 patients (23.7%) in the half-length splint had swelling, and no statistically significant differences were observed between them (P=0.41). The mean pain score was  $2.49 \pm 1.56$  after one week in the standard splint group and  $2.42 \pm 1.43$  in the half-length splint group, and there was no statistically significant difference between the two groups in this regard (P=0.47)

After two weeks, two patients (1.7%) in the



**Table 1:** The baseline demographic characteristics of the participants

Variable	Short Arm Splint		P
	Standard Size (n=117)	Half-Length (n=139)	
Age (mean ± SD in year)	35.82 ± 11.07	37.91 ± 13.19	0.17
Gender [n (%)]			
Male	86 (73.5)	98 (70.5)	0.34
Female	31 (26.5)	41 (29.5)	
Presence of initial swelling [n (%)]	50 (42.7)	73 (52.5)	0.07
Initial pain score (mean ± SD in the NRS*)	5.13 ± 1.11	4.9 ± 1.22	0.21

\* NRS: The Numerical Rating Scale

standard splint group and seven (5.0%) in the half-length splint group had swelling, and no statistically significant differences were observed between them ( $P=0.18$ ). The mean pain score after two weeks was  $1.01 \pm 1.12$  in the standard splint group and  $0.88 \pm 1.10$  in the half-length splint group, and there were no statistically significant differences between the two groups ( $P=0.92$ ).

After three weeks, none of the patients had swelling. The mean pain score was  $0.26 \pm 0.52$  in the standard splint group and  $0.21 \pm 0.51$  in the half-length splint group after three weeks, and there were no statistically significant differences between the two groups ( $P=0.29$ ).

## DISCUSSION

The present study shows that there were no significant differences between the standard short arm splint and the half-length short arm splint in terms of the examined outcome measures, i.e. reduced swelling and pain score, over the three weeks of the follow-up.

This study is unique in that databases such as Google Scholar, Medline and EBSCO were searched; however, this search led to no similar studies, although various studies have challenged the common methods of immobilization.

Joon Yub Kim et al. reported that if the distal end of short arm splints is located 1 cm proximal to the transverse palmar crease, the complete range of motion of the MCP joint is preserved; in contrast, when the distal end of the splint is at the transverse crease or 1 cm distal to the crease, the flexion angle reduces to 83 and 56 degrees (6). Another study showed that short arm cast length can affect active forearm rotation; in fact, the rotation range of motion is better preserved when the cast ends at the proximal one-third of the distance between the wrist and the elbow flexion crease (9). Jae Hoon Lee et al. compared short arm double splint with sugar-tong splint in distal radius fractures and concluded that the loss of reduction, reduction in arm, shoulder, and hand score, and shoulder stiffness did not differ significantly between the two groups (7). Short arm radial gutter splint and long arm

sugar-tong splint showed comparable performances in post-reduction immobilization in distal radius fractures, although short arm radial gutter splint was better tolerated by the patients and the patients who were treated with this method of immobilization obtained better arm, shoulder and hand scores (10). A similar study by Cho JH et al. also confirmed that short arm radial gutter splints can minimize limitations in elbow motion and daily life activities while their reduction loss rate is comparable to sugar-tong splints (11). Park M. J. et al. compared short arm and long arm plaster casts and found that short arm casts are as effective as long arm casts for stable distal radius fractures in older patients, although they are more comfortable and reduce restriction on daily activities (17).

The present findings may be more valuable in certain aspects. Plaster splints, which are currently the most popular way for immobilization in EDs, adjust the patients' arm length; in a medium-sized adult, three plaster rolls are needed for making a standard short arm splint. In contrast, two plaster rolls are needed for making a half-length short arm splint. Each plaster roll costs approximately USD 1.5, which means that if half-length splints can be used instead of popular splints, at least USD 1.5 can be saved in costs per patient. Given the large number of splints made and used daily, this cost reduction is worth considering. Nevertheless, as these figures provide only a rough estimate, further cost and benefit studies should be designed and performed to prove this finding.

## Limitations

This study was limited to cases of soft tissue injury; however, it can serve as a guide for further studies on the use of shorter splints and casts for wrist and hand fractures. Another limitation of the study was that it did not measure the patients' compliance and satisfaction with the treatment, which should be taken into consideration in future studies.

## CONCLUSIONS

Based on the findings of the present study, half-length short arm splints appear to be as effective as

traditional standard splints in the treatment of pain and swelling caused by soft tissue injuries of the hand and wrist. Half-length short arm splints are cheaper and lighter than standard ones and can improve the patients' treatment compliance and make the splint more comfortable.

#### ACKNOWLEDGEMENTS

The authors wish to express their appreciation and thanks to all colleagues for their cooperation in the present study.

#### REFERENCES

1. Roberts, James R., Catherine B. Custalow, Todd W. Thomsen, and Jerris R. Hedges. 2014. Roberts and Hedges' clinical procedures in emergency medicine, vol.1, 999-1000
2. Land TL, Lynch JM, Stanley-Green S. Soft Tissue Injuries. Common Musculoskeletal Problems: Springer; 2015. p. 157-69.
3. Kannus P. Immobilization or early mobilization after an acute soft-tissue injury? *Phys Sportsmed.* 2000; 28(3):55-63.
4. Roberts, James R., Catherine B. Custalow, Todd W. Thomsen, and Jerris R. Hedges. 2014. Roberts and Hedges' clinical procedures in emergency medicine, vol.1, 1009
5. Tintinalli EJ, Stapczynski JS, Ma O J, Yealy D, Meckler DG, Cline MD. Tintinalli's Emergency Medicine: A Comprehensive Study Guide, 8th edition. New York: McGraw-Hill; 2015
6. Kim JY, Sohn DW, Park HY, Yoo JH, Kim JH, Jung MG, et al. The Effect of Distal Location of the Volar Short Arm Splint on the Metacarpophalangeal Joint Motion. *Clin Orthop Surg.* 2016;8(2):181-6.
7. Lee JH, Hong SH, Kim YJ, Back JH, Lee JS. Effect of Different Splints on Displacement after Closed Reduction of the Distal Radius Fractures: A Comparison of Short Arm Double Splint and Sugar-Tong Splint. *J Korean Soc Surg Hand.* 2015;20(3):104-9.
8. Acree JS, Schlechter J, Buzin S. Cost analysis and performance in distal pediatric forearm fractures: is a short-arm cast superior to a sugar-tong splint? *J Pediatr Orthop B.* 2017;26(5):424-8.
9. Kim JK, Park ES. The effect of short arm cast length on forearm rotation. *J Hand Surg Am.* 2014;39(4):629-33.
10. Bong MR, Egol KA, Leibman M, Koval KJ. A comparison of immediate postreduction splinting constructs for controlling initial displacement of fractures of the distal radius: a prospective randomized study of long-arm versus short-arm splinting. *J Hand Surg Am.* 2006;31(5):766-70.
11. Denes JA, Goding R, Tamborlane J, Schwartz E. Maintenance of reduction of pediatric distal radius fractures with a sugar-tong splint. *Am J Orthop (Belle Mead NJ).* 2007;36(2):68-70.
12. Boutis K, Willan A, Babyn P, Goeree R, Howard A. Cast versus splint in children with minimally angulated fractures of the distal radius: a randomized controlled trial. *CMAJ.* 2010;182(14):1507-12.
13. Williams KG, Smith G, Luhmann SJ, Mao J, Gunn JD, Luhmann JD. A randomized controlled trial of cast versus splint for distal radial buckle fracture: an evaluation of satisfaction, convenience, and preference. *Pediatr Emerg Care.* 2013; 29(5):555-9.
14. Jordan KT, Howell JM, Lauerman WC, Butzin CA. A radiographic comparison of short-arm cast and plaster and fiberglass wrist splints. *Am J Emerg Med.* 1993;11(6):590-1.
15. Mobarakeh MK, Nemati A, Noktesanj R, Fallahi A, Safari S. Application of removable wrist splint in the management of distal forearm torus fractures. *Trauma Mon.* 2013; 17(4):370-2.
16. Farrar JT, Young JP, LaMoreaux L, Werth JL, Poole RM. Clinical importance of changes in chronic pain intensity measured on an 11-point numerical pain rating scale. *Pain.* 2001; 94(2):149–58.

#### AUTHORS' CONTRIBUTION

All the authors met the standards of authorship based on the recommendations of the International Committee of Medical Journal Editors.

#### CONFLICT OF INTEREST

None declared.

#### FUNDING

None declared.

17. Park M, Kim J, Lee H, Lim T, Jung H, Lee J. Is a short arm cast appropriate for stable distal radius fractures in patients older than 55 years? A randomized prospective multicenter study. *J Hand Surg Eur* Vol. 2017; 42(5):487-92.