

Case Report

DOI: 10.22114/ajem.v0i0.100

Interstitial Nephritis Presenting as Acute Kidney Injury Following Ingestion of Alternative Medicine Containing Lead: A Case ReportSaranya Moorthy¹, Arpith Easo Samuel^{1*}, Fabith Moideen¹, Jayameena Peringat²

1. Department of Emergency Medicine, Baby Memorial Hospital, Kerala, India.

2. Department of Nephrology, Baby Memorial Hospital, Kerala, India.

*Corresponding author: Arpith Easo Samuel; Email: arpitheasosamuel@gmail.com

Published online: 2018-07-28

Abstract

Introduction: Some studies have shown that patients consuming alternate medicine can suffer from complications like acute kidney injury (AKI) due to heavy metal poisoning. The use of traditional ayurvedic herbal remedies may be difficult to identify as a source of toxicity, especially if the treating doctor is not aware of this habit, unless a detailed history is taken. In this report, we describe a patient who had consumed ayurvedic supplements for treating fever and abdominal pain and presented to our emergency department (ED) with AKI.

Case presentation: A 24-year-old male presented to the ED with complaints of abdominal pain, fever and loose stools. His blood tests revealed AKI and he was started on emergency hemodialysis. His renal function improved after only one cycle of dialysis and he was discharged in a stable condition.

Conclusion: Acute lead toxicity should be suspected in patients with abdominal and neurological dysfunction who have a history of chronic ayurvedic medicine intake and thus should be promptly treated. Physicians should rule out potential toxicity from these supplements and have a heightened level of suspicion for lead toxicity in patients presenting with abdominal pain and AKI without any obvious cause.

Key words: Acute kidney injury; Alternate medicine; Acute tubulointerstitial nephritis; Lead

Cite this article as: Moorthy S, Samuel AE, Moideen F, Peringat J. Interstitial Nephritis Presenting as Acute Kidney Injury Following Ingestion of Alternate Medicine Containing Lead: A Case Report. *Adv J Emerg Med.* 2019;3(1): e8.

INTRODUCTION

Interstitial nephritis (also called tubulointerstitial nephritis) is inflammation of the interstitium surrounding the tubules of the kidneys. One of the causes of interstitial nephritis is exposure to heavy metals like lead, mercury, arsenic etc., either acutely or chronically. Chronic low-level exposure to lead can be considered to be a causative factor in cognitive dysfunction, neurobehavioral disorders, neurological damage, hypertension, and renal impairment (1). The extent of renal damage depends on the dose and duration of exposure. Here, we describe a case of interstitial nephritis following unintended lead consumption after which the patient presented with acute kidney injury (AKI).

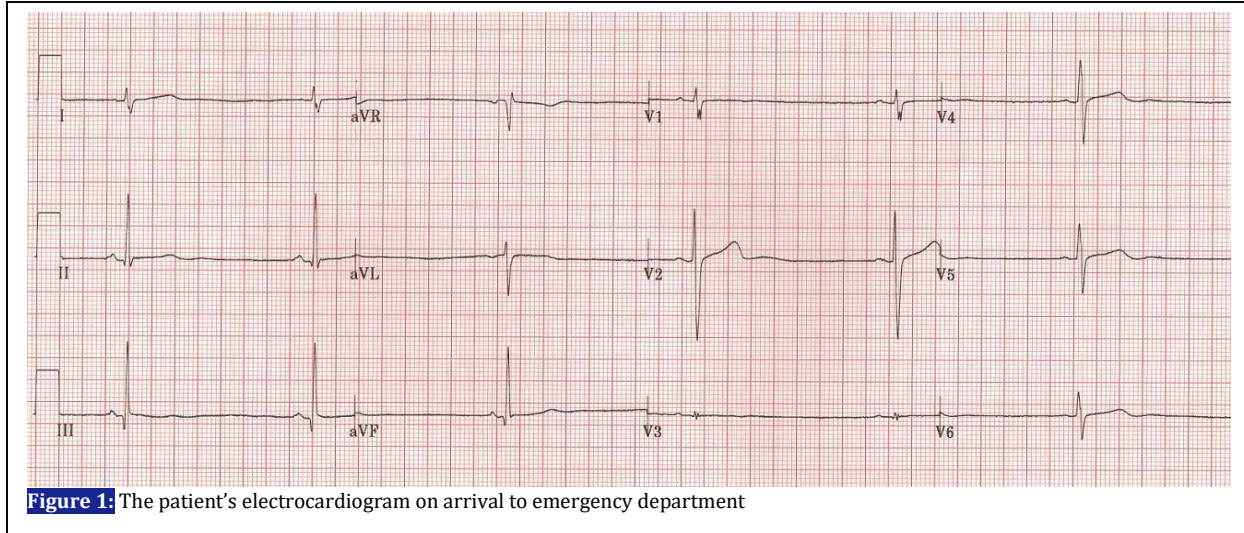
CASE PRESENTATION

A 24-year-old man with complaints of fever, abdominal pain and 3 episodes of passing loose stools consulted an alternative medicine practitioner and was given ayurvedic medications. Following intake of the medicines, he had worsening diffuse abdominal pain and vomiting along with decreased urine output. He went to a

local hospital on the 2nd day and was found to have deficient renal function (his serum creatinine level was 10.3 mg/dl). He was referred to our emergency department (ED) on the 3rd day for further management. He had no history of comorbidities or any known underlying disease.

On examination, he was conscious, oriented, with a pulse rate of 64/min, blood pressure of 132/80 mmHg, respiratory rate 24/min, and an O₂ saturation (SpO₂) of 99% on room air. He also had some minor facial and pedal edema. Respiratory and cardiovascular system examinations were normal. Abdomen examination showed moderate tenderness in the left lower quadrant with no mass palpable and no flapping tremors.

His electrocardiogram (ECG) showed sinus bradycardia (Figure 1). Non-enhanced computed tomography (CT) scan of the abdomen showed no obvious renal or ureteric calculi, nor any pelvicalyceal/ureteric dilatation on either side. He had minimal ascites and bilateral basal pleural effusion. Upon admission, his hemoglobin was 13.5, blood urea 121, serum creatinine 11.33 mg/dl, serum sodium 139 mmol/l, serum



potassium 3.9 mmol/l, total bilirubin 0.5 mg/dl, and direct bilirubin 0.1 mg/dl. His ABG showed compensated metabolic acidosis with a pH of 7.36, PCO₂ of 28 mmHg and HCO₃ of 18meq/l.

The patient was admitted to the nephrology department since he had metabolic disturbances and AKI. He was taken for emergency hemodialysis via a left double lumen femoral catheter. He started improving clinically after one session of dialysis and other supportive care. His renal function rapidly improved and his serum creatinine was 2.17 mg/dl on the fifth day of admission. The femoral catheter was then removed and he was discharged on day six. On follow up his serum creatinine was within normal limits (1.2 mg/dl). The ayurvedic supplement he had been taking was sent for toxicological analysis and showed the presence of a high concentration of lead which might have caused the interstitial nephritis leading to AKI in our patient. The serum level of lead was not measured in this patient

DISCUSSIONS

The kidney is an organ susceptible to heavy metal poisoning. Poisoning can occur acutely or due to chronic exposure. The most common renal lesions include acute tubular necrosis, cortical necrosis, and interstitial nephritis. Both acute and chronic exposure to heavy metals can cause tubulointerstitial injuries without any obvious morphological changes and they can occur within days of exposure to the offending drug (2). Chronic heavy metal exposure is an important but under-recognized cause of renal damage. The diagnosis is usually made by the finding of unexplained renal dysfunction and a history of exposure to a heavy metal (3).

Acute lead poisoning has been reported frequently from India, the Middle Eastern countries and Mexico due to the popular usage of traditional and herbal medicines. This should be a matter of grave concern to patients who take such remedies, and to health professionals and health authorities in these countries (4).

In cases of acute lead poisoning the patient may present with encephalopathy, seizures, altered mental status, papilloedema, ataxia, abdominal pain, and Fanconi's syndrome. The combination of abdominal or neurologic dysfunction with hemolysis should raise suspicions about lead toxicity. Anemia and basophilic stippling may or may not be present, and patients with neurotoxicity may develop permanent central neurologic damage. Measurement of serum lead levels is necessary for a definitive diagnosis.

There are various traditional medical methods, has been long used in all around the world (5). Among them, ayurvedic medicine originated in India more than 3,000 years ago and still has a role in the country's health care systems. This traditional medical system promotes the use of herbal agents, minerals, and metal compounds, special diets, and other unique health practices. Ayurvedic medicine has not been widely studied and its safety assessment needs additional investigations. Some cases associated with its use, such as status epilepticus, fatal infant encephalopathy, congenital paralysis, sensorineural deafness, and developmental delay have been previously reported in this regard (6); and as in our case that presented with AKI following use of ayurvedic herbal medicines, induced lead toxicity.

CONCLUSIONS

Acute lead toxicity should be suspected in patients with abdominal and neurological dysfunction who have a history of chronic ayurvedic medicine intake and they should be promptly treated. In our opinion, physicians should rule out potential toxicity from these supplements and have a heightened level of suspicion for lead toxicity in any patients with abdominal pain and AKI without an obvious cause.

ACKNOWLEDGMENTS

We thank the residents, nurses, and paramedical staff of the Department of Emergency Medicine and Nephrology at Baby Memorial Hospital, Kerala, India.

REFERENCES

1. Lin JL, Lin-Tan DT, Hsu KH, Yu CC. Environmental lead exposure and progression of chronic renal diseases in patients without diabetes. *N Engl J Med.* 2003;348(4):277-86.
2. Jha V, Rathi M. Natural medicines causing acute kidney injury. *Semin Nephrol.* 2008;28(4):416-28.
3. Sathe K, Ali U, Ohri A. Acute renal failure secondary to ingestion of ayurvedic medicine containing mercury. *Indian J Nephrol.* 2013;23(4):301-3.
4. Tait PA, Vora A, James S, Fitzgerald DJ, Pester BA. Severe congenital lead poisoning in a preterm infant due to a herbal remedy. *Med J Aust.* 2002;177(4):193-5.
5. Karimpour Reihan S, Firuzei E, Khosravi M, Abbaszadeh M. Coagulation Disorder following Red Clover (*Trifolium Pratense*) Misuse: a Case Report. *Adv J Emerg Med.* 2018;2(2):e20.
6. Saper RB, Kales SN, Paquin J, Burns MJ, Eisenberg DM, Davis RB, et al. Heavy metal content of ayurvedic herbal medicine products. *JAMA.* 2004;292(23):2868-73.

AUTHORS' CONTRIBUTION

All authors passed four criteria for authorship contribution based on recommendations of the International Committee of Medical Journal Editors.

CONFLICTS OF INTEREST

The authors have no conflicts of interest to report. Any conflicts that the editor considers relevant to the content of the manuscript have been disclosed.

FUNDING

No funding from any source was received or used for this case report.