

Case based learning points

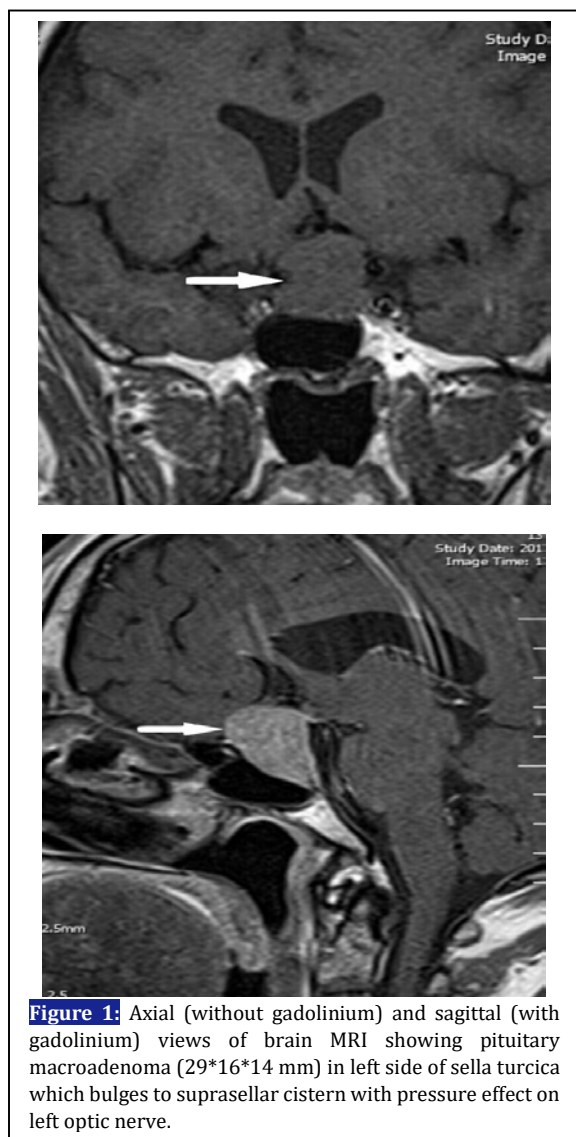
DOI: 10.22114/ajem.v0i0.84

Pituitary Macroadenoma with Mildly Elevated Serum Prolactin: Hook EffectMahnaz Pejman Sani¹, Mahbube Ebrahimipur^{1*}, Mohammad Reza Mohajeri-Tehrani²

1. Department of Internal Medicine, Shariati Hospital, Tehran University of Medical Sciences, Tehran, Iran.

2. Endocrinology and Metabolism Research Center, Endocrinology and Metabolism Clinical Sciences institute, Tehran University of Medical Sciences, Tehran, Iran.

*Corresponding author: Mahbube Ebrahimipur, Email: m-ebrahimpur@tums.ac.ir

Cite this article as: Pejman Sani M, Ebrahimipur M, Mohajeri-Tehrani MR. Pituitary Macroadenoma with Mildly Elevated Serum Prolactin: Hook Effect. Adv J Emerg Med. 2018;2(4): e49.**CASE PRESENTATION**

A 45-year-old man was admitted in our department with complaints of severe headache for over 6 months period. He also suffered from

several problems such as visual field defect, decreased energy and libido, body hair loss, cold intolerance, decreased appetite and dry skin. On physical examination, he was afebrile: blood pressure (BP): 110/70 mm/Hg, pulse rate (PR) :65 beat/min, body mass index (BMI): 24. He had no terminal hair on face or chest and subcutaneous adipose tissue mass had been decreased substantially. Laboratory tests revealed; Hb: 12 g/dL (N: 14–17 g/dL), Total testosterone: 1.2 ng/mL (N: --10 ng/mL), Luteinizing hormone (LH):3.3MIU/mL (N: 1–8 MIU/mL), Follicle Stimulating hormone (FSH): 1.3 MIU/mL (N: 1–7 MIU/mL), T4:3.4 micg/dL (N:4–12 micg/dL), TSH:0.6 MIU/mL (N: 0.5–5 MIU/mL), Prolactin:100 ng/mL (2–24 ng/mL), serum cortisol:6 MIU/mL (N: 4–21 MIU/mL), IGF1: 162 ng/mL (50–245). Pituitary MRI showed macroadenoma (29*16*14 mm) in left side of sella turcica which bulged to suprasellar cistern with pressure effect on left optic nerve (figure 1, 2). Visual field examination revealed mild temporal hemianopia. These findings are consistent with macroadenoma and mild prolactin elevation. We also observed a discrepancy between pituitary tumor size and prolactin level. The correct estimate of serum prolactin was obtained after serial dilutional measurement. Serum prolactin after dilution was 6470 ng/mL. With these findings pituitary macroadenoma was diagnosed and treatment with cabergoline (dopamine agonist) 0.5 mg/week was started. After one month follow-up he had no symptoms, visual field defect was improved and pituitary MRI showed significant shrinkage of tumor.

LEARNING POINTS

Pituitary adenomas are the most common of sellar masses; prolactinoma accounts for 45% of the pituitary adenomas. Microadenoma is most commonly seen in female and macroadenomas in

males (1). Overall, there is a relationship between the level of prolactin and the size of adenomas. Patients with macroprolactinoma often have serum level of prolactin above 1000 ng/mL, but this association is not a rule (2). The hook effect is a cause for discrepancy between prolactin level and the size of the adenoma. Interpretation of serum prolactin concentration between 20 and 200 ng/mL in the presence of macroadenoma due to hook effects should be done with caution. This problem can be avoided by repeating the assay using a 1:100 dilution of serum. (3)
Hook effect is seen in 20% of macroprolactinoma

(1). Macroprolactinoma in men tends to occur at an advanced age, with a peak during the fourth decade of life. Symptoms at the time of diagnosis are decreased libido, hypogonadism, headache, and reduced visual field (4). The goals of the treatment of macroprolactinoma are to reduce the size of the mass and improve visual field defect. The first line of treatment is the use of dopamine agonist. Cabergoline has fewer side effects compared with bromocriptine and has a more positive effect on reduction of serum prolactin (5). Dopamine agonists can reduce the size of mass in a few days after initiating therapy (1).

REFERENCES

1. S.Aljabri K, Bokhari SA, Akl A. Giant Prolactinoma: Case Report and Review of Literature. *Am J Med Case Rep.* 2015;3(12):399-402.
2. Delgrange E, Raverot G, Bex M, Burman P, Decoudier B, Devuyst F, et al. Giant prolactinomas in women. *Eur J Endocrinol.* 2014;170(1):31-8.
3. Melmed S, Casanueva FF, Hoffman AR, Kleinberg DL, Montori VM, Schlechte JA, et al. Diagnosis and treatment of hyperprolactinemia: an Endocrine Society clinical practice guideline. *J Clin Endocrinol Metab.* 2011;96(2):273-88.
4. Grozinsky-Glasberg S, Shimon I. Unusual clinical presentations of giant prolactinomas. *Pituitary.* 2011;14(4):340-4.
5. Rahmanian M, Meybodi HA, Larijani B, Mohajeri-Tehrani M-r. Giant prolactinoma: case report and review of literature. *J Diabetes Metab Disord.* 2013;12(1):3.