

Electrocardiogram Interpretation

DOI: 10.22114/ajem.v1i1.7

A 26-Year-Old Man with Headache

Mehran Sotoodehia^{1*}

1. Department of Emergency Medicine, Sina Hospital, Tehran University of Medical Sciences, Tehran, Iran.

*Corresponding author: Mehran Sotoodehia; Email: m-sotoodehia@tums.ac.ir

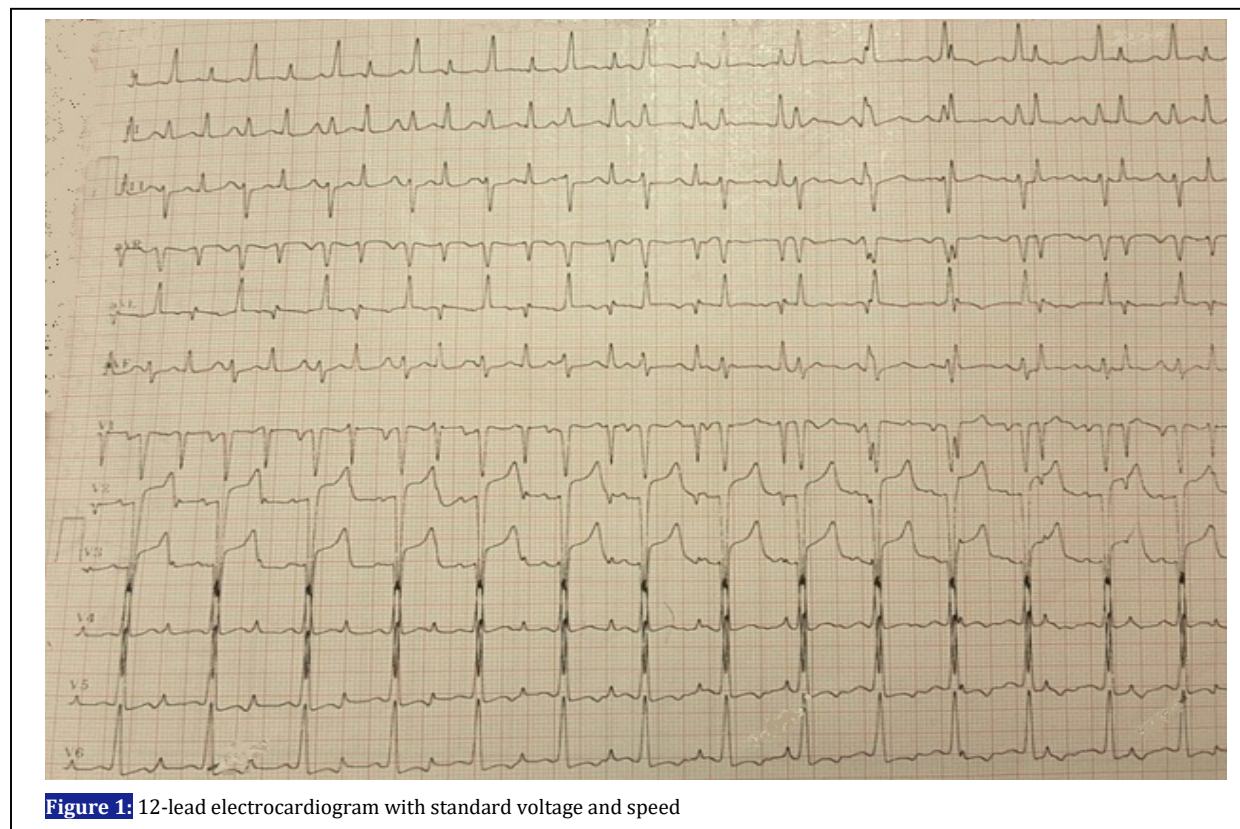


Figure 1: 12-lead electrocardiogram with standard voltage and speed

The electrocardiogram (ECG) discussed in this article is related to a 26-year-old man with chief complaint of headache accompanied with nausea and diplopia. The ECG discussed in the present article is shown in figure 1. What is the correct interpretation of this ECG?

- Interpolated bigeminy premature ventricular contractions (PVC)
- Electrical alternans due to pericardial effusion
- Undersensing pacemaker malfunction
- Transplanted heart

At first sight, it seems that an electrical alternans is present in the rhythm of this ECG because in some leads every other QRS complex is reversed regarding polarity or in some of the others, amplitudes decrease and increase. Electrical alternans is the indicator of pericardial effusion

and tamponade. In this case, changes are made to the shape or amplitude of ECG complexes change alternatively. In the most common form, alternative changes can be viewed better in QRS complexes and in mid precordial leads. These alternative changes can be seen simultaneously in every other QRS complex and T wave. This means that in one beat the amplitude or shape of QRS complexes and T wave are normal and in the next beat the amplitude or shape of QRS complexes and T wave change. In the rarest cases, electrical alternans in QRS complexes and T and P waves happen simultaneously and in every other heart rhythm, this situation happens only in cardiac tamponade (1-3). With more attention, this diagnosis is ruled out for the ECG discussed in this article, since at times QRS complexes get closer, then they collapse and overlap and after that they

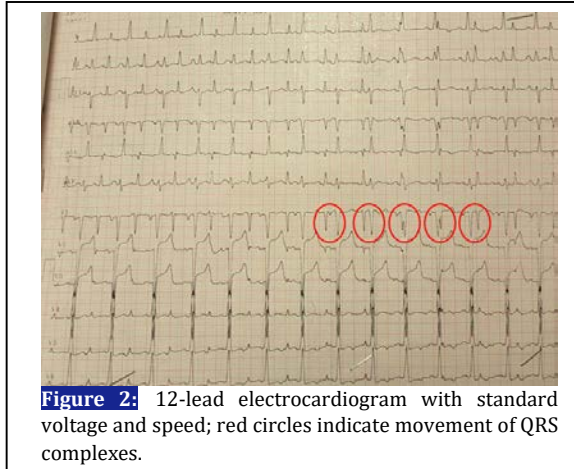


Figure 2: 12-lead electrocardiogram with standard voltage and speed; red circles indicate movement of QRS complexes.

gain distance from each other again, which is not present in the definition of electrical alternans at all. The discussed changes are marked as examples in figure 2 and on v1 lead.

The second diagnosis that comes to mind when looking at the ECG is the presence of bigeminal PVCs. This diagnosis is also dismissed like electrical alternans, because QRS complexes overlap in some parts of the rhythm (4, 5).

The third diagnosis that is considered in this situation is the presence of a pacemaker in the patient, which is working alongside the normal focus of cardiac pacemaker. Of course in this

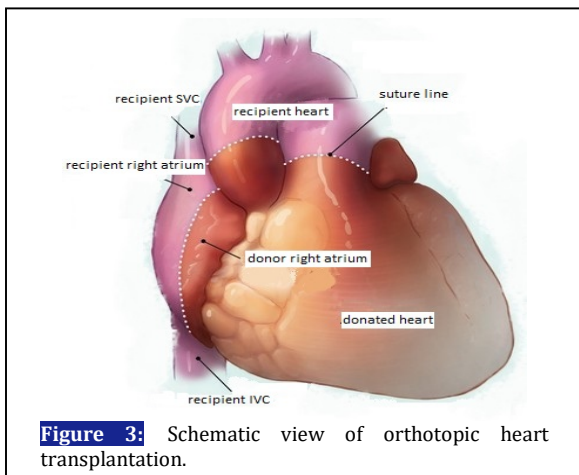


Figure 3: Schematic view of orthotopic heart transplantation.

situation, due to the presence of overlapping complexes called fusion beats, pacemaker must have been affected with undersensing so that despite the normal pacing in the heart, it continues to make impulses (6, 7). However, another more uncommon possibility is presence of a VOO or DOO pacemaker that continues its activity regardless of the background function of the heart and therefore, at times interferes with the background rhythm of the heart. This type of pacemaker is not placed for patients these days and this view of pacemaker activity is only seen when a magnet is placed on the pacemaker to evaluate the pacing of the device (8-10). Yet, diagnosis of any pacemaker being present is ruled out in this ECG, as nowhere in the ECG there is a spike wave before QRS complexes resulting from pacemaker activity.

The only diagnosis left for this ECG is simultaneous presence of 2 different foci for making complexes of the ECG. This situation is seen in a transplanted heart. To understand the changes in ECG after heart transplantation, pointing out these tips is necessary. Heart transplants are done with 2 methods: orthotopic and heterotopic (11).

In orthotopic transplant, posterior wall of the right and left atrium of the receiver are preserved and attached to the atriums of the donor (figure 3). In this situation, the remaining atrial tissue contains sinoatrial (SA) knot, which has a pacing activity independent from the transplanted heart. The transplanted atrial tissue also has an independent pacing activity from the SA knot of the receiver. In this situation, two P waves are seen in ECG, one without QRS complexes, which belongs to the receiver's SA knot, and the other has QRS complexes with a 1:1 ratio, which belongs to the transplanted atrial tissue (12-14). The image of ECG in this situation has been shown in figure 4, in which D wave belongs to the donor tissue and R wave belongs to the atrial tissue of the receiver.

In a heterotopic transplant, which is also called a double heart, the heart of the patient is kept and the transplanted heart is attached to it.

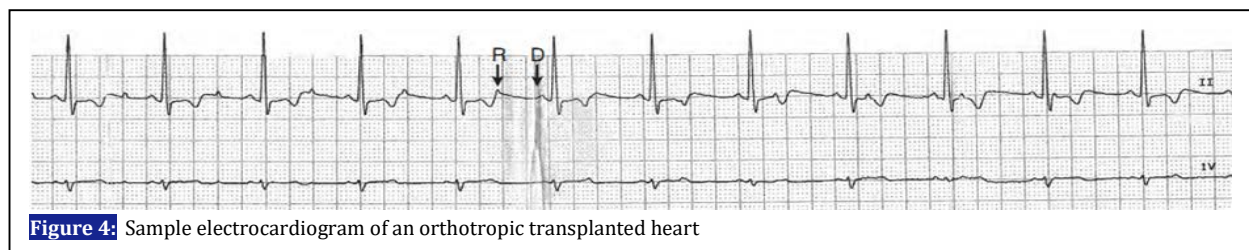


Figure 4: Sample electrocardiogram of an orthotopic transplanted heart

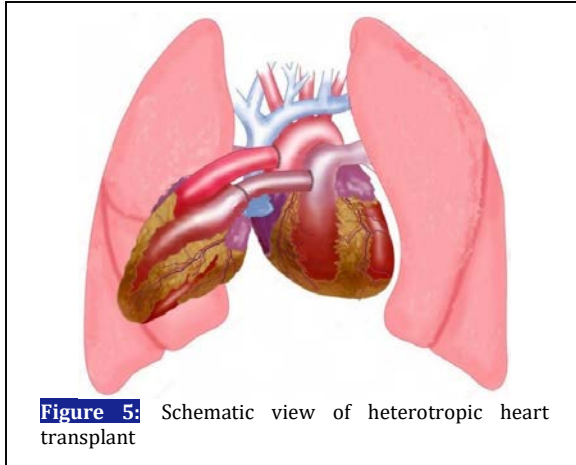


Figure 5: Schematic view of heterotropic heart transplant

As can be seen in figure 5, pulmonary artery and aorta of the donor's heart are connected to the pulmonary artery and aorta of the receiver's heart, respectively and superior vena cava of the transplanted heart is also connected to the right atrium of the receiver's heart so that the body's venous blood flows in both hearts. In this situation, the patient has two real hearts, each of which has its own electrical activity and 2 independent electrical activities are evident on the ECG, but at places they are seen as a fusion complex since they overlap (15-17). As ECG records the waves from the surface of the body and cannot record the activity of each heart separately, when both hearts undergo depolarization simultaneously, the resulting wave is recorded as a compound complex or a fusion. In the ECG under discussion that can be seen in figure 6, the activity of each heart is shown using arrows in the same direction. The resulting ST segment and T wave changes are due to alteration of the natural pattern of ventricular

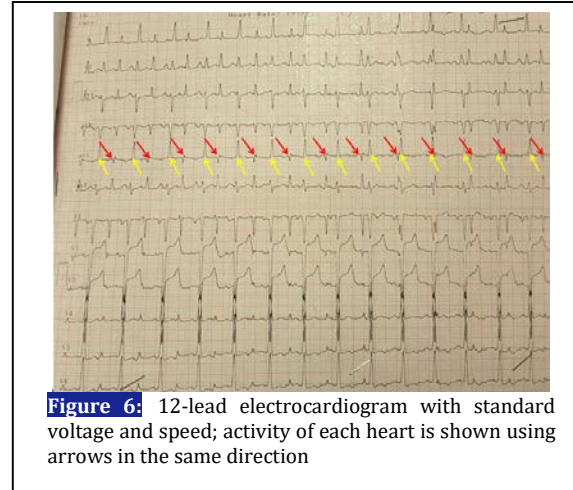


Figure 6: 12-lead electrocardiogram with standard voltage and speed; activity of each heart is shown using arrows in the same direction

repolarization in the dysfunctional heart of the receiver, which is distinguished from the transplanted heart via bigger QRS complexes, and is not necessarily a sign of current heart ischemia, yet it does not rule it out either. Another way of differentiating the transplanted and dysfunctional hearts is paying attention to the axis of the hearts. The axis of narrow complexes is about 60 degrees and the axis of big complexes is about 0 degrees, which indicates that the transplanted heart with narrow complexes is placed at the right side of the dysfunctional and receiver heart with big complexes and left bundle branch block (LBBB) view. Therefore, the answer to this ECG is a heterotropic transplanted heart.

REFERENCES

1. Smith JM, Clancy EA, Valeri CR, Ruskin JN, Cohen RJ. Electrical alternans and cardiac electrical instability. *Circulation*. 1988;77(1):110-21.
2. Fox JJ, McHarg JL, Gilmour RF. Ionic mechanism of electrical alternans. *Am J Physiol Heart Circ Physiol*. 2002;282(2):H516-H30.
3. Spencker S, Müller D, Mochmann H-C. Pericardial effusion and electrical alternans. *Resuscitation*. 2008;76(2):163-4.
4. Mattu A, Brady WJ. *ECGs for the emergency physician 2*: John Wiley & Sons; 2011.
5. Fotiadis D, Likas A, Michalis L, Papaloukas C. *Electrocardiogram (ECG): automated diagnosis*. Wiley encyclopedia of biomedical engineering. 2006.
6. Pascale P, Pruvot E, Graf D. Pacemaker Syndrome During Managed Ventricular Pacing. *J Cardiovasc Electrophysiol*. 2008;20:574-6.
7. Israel C, Ekosso-Ejangue L, Sheta M. Analysis of pacemaker ECGs. *Herzschrittmacherther Elektrophysiol*. 2015;26(3):260-73.

8. Verlato R, Baccillieri MS, Turrini P. Pacemaker Malfunction: Myth or Reality? The Arrhythmic Patient in the Emergency Department: Springer; 2016. p. 163-75.
9. Hesselton AB. Simplified Interpretation of Pacemaker ECGs: An Introduction: John Wiley & Sons; 2008.
10. Fåhræus T. Pacemaker electrocardiography. *Comprehensive Electrocardiology*: Springer; 2010. p. 1767-92.
11. Newcomb AE, Esmore DS, Rosenfeldt FL, Richardson M, Marasco SF. Heterotopic heart transplantation: an expanding role in the twenty-first century? *Ann Thorac Surg*. 2004;78(4):1345-50.
12. John R, Liao K. Orthotopic heart transplantation. *Oper Tech Thorac Cardiovasc Surg*. 2010;15(2):138-46.
13. Liao KK, John R, Shumway SJ. Orthotopic Heart Transplantation. *Congestive Heart Failure and Cardiac Transplantation*: Springer; 2017. p. 431-47.
14. Lefroy DC, Fang JC, Stevenson LW, Hartley LH, Friedman PL, Stevenson WG. Recipient-to-donor atrioatrial conduction after orthotopic heart transplantation: surface electrocardiographic features and estimated prevalence. *Am J Cardiol*. 1998;82(4):444-50.
15. MacLachlan HI, Dalzell JR. An Unusual Electrocardiogram in a Heart Transplant Recipient. *Am J Med*. 2015;128(7):e7-e8.
16. Kerensky RA, Leontiadis E, Magninas A, Cokkinos DV. Heterotopic heart transplantation. *Clin Cardiol*. 2004;27(5):280-.
17. Kadner A, Chen RH, Adams DH. Heterotopic heart transplantation: experimental development and clinical experience. *Eur J Cardiothorac Surg*. 2000;17(4):474-81.