



## The damaging effect of consuming fermented *Oryza sativa* var. glutinosa on the pancreatic organ

Ruqiah Ganda Putri Panjaitan\* & Ika Rahmawati

Biology Education Department, University of Tanjungpura, Pontianak-78124, Indonesia

Received 02 May 2019; revised 25 December 2019

The damaging effect of consuming fermented *Oryza sativa* var. glutinosa on Pancreatic Organ. Tuak is one of the alcoholic drinks made using recipes from the ancestors of the Dayak tribe in the West Kalimantan region. Tuak is commonly consumed especially at traditional ceremonies and holidays. Some studies report that consuming alcoholic drinks negatively impacts health. This study aimed to examine the effect of consuming tuak on blood glucose levels and histopathology of the pancreatic organ. Male mice were grouped into four groups, ten mice each. Group A was negative control (no administered tuak), group B, C, and D were administered tuak at dose 0.26 mL/20 g body weight per day for 7, 14, and 21 consecutive days. Compared to the negative control, the administration of tuak at different time spans showed an increase in blood glucose levels ( $P < 0.05$ ) and in the scoring lesion of the pancreatic organ ( $P < 0.05$ ). It is concluded that the pancreatic organ damage that occurred due to repeated use of tuak is accompanied by increasing blood glucose levels.

**Keywords:** Blood glucose level, Fermented *Oryza sativa* var. glutinosa, Histopathology of pancreatic organ

Tuak is one type of traditional drink. In some tribes in Indonesia, tuak is usually used in various celebrations such as weddings, rice harvests, and Christmas<sup>1</sup>. Tuak is traditionally made based on the fermentation process. One type of tuak is the water which results from the fermentation of *Oryza sativa* var. glutinosa. The recipe for making tuak from fermented *Oryza sativa* var. glutinosa is inherited from generation to generation.

According to many researchers, tuak is a liquor and the alcohol which is contained in this liquor is ethanol. In the body, ethanol can be oxidized to acetaldehyde and then oxidized again to acetic acid by aldehyde dehydrogenase. Furthermore, the product of ethanol metabolism could cause hypoxia in the liver, and also increase the number of reactive oxygen

hypertension is because alcoholic beverages contain a variety of chemical compounds that can cause coagulation in blood, so that exacerbates the work of the heart to pump blood. Then, the risk of increased blood pressure is proportional to the number of alcoholic beverages consumed. More than that, they mentioned that giving 20% alcohol as much as 4 g/day/kg body weight can increase the pulse pressure<sup>12</sup>. Furthermore, the administration of 20% alcohol to Wistar strain rodents for six consecutive weeks could result in liver tissue damage<sup>9</sup>. The excessive consumption of alcoholic beverages in humans can lead to acute pancreatitis<sup>13</sup>. Moreover, the disruption of  $Ca^{2+}$  homeostasis can lead to severe damage to the pancreas, resulting in premature

alcoholic beverages per oral could lead to alcoholic diseases in humans. When a person consumes alcoholic beverages continuously then the digestive enzymes that oxidize alcohol will become saturated resulting in an increase in blood alcohol levels quickly. Furthermore, the high blood alcohol level can cause various toxic effects in humans<sup>4,6,7,9-11</sup>. Also, the habit of consuming alcoholic beverages could affect the occurrence of hypertension. The occurrence of

es, vacuolisation and necrotic cell death features typical of acute pancreatitis. Acute pancreatitis is a formidable disease that causes significant mortality<sup>14,15</sup>.

The pancreas is an organ that plays a role in regulating blood glucose levels. In microanatomy, it is known that the pancreas consists of acinar cells and Langerhans islet cells. Acinar cells play a role in secreting digestive enzymes into the small intestine to participate in the digestive process, whereas the Langerhans islet cells are primarily tasked with regulating blood sugar levels<sup>10,16-18</sup>. Langerhans islets composed of Langerhans islet cells include  $\beta$  cells,

\*Correspondence:  
E-mail: ruqiah.gpp@gmail.com

$\alpha$  cells,  $\Delta$  cells, and pancreatic polypeptides<sup>10,15-19</sup>. More than that, the damage to pancreatic  $\beta$  cells can lead to increased blood glucose levels due to the disruption of insulin production<sup>19-31</sup>.

Insulin is a hormone that functions to convert glucose into glycogen. In conditions where insulin cannot be produced as a result of pancreatic organ dysfunction, glucose cannot be converted into glycogen. Consequently, glucose in the blood increases continuously, and this condition leads to hyperglycemia or elevated blood glucose levels<sup>20-31</sup>. The hyperglycemia condition will lead to the formation of reactive oxygen species that can exacerbate the destruction of pancreatic  $\beta$  cells<sup>17,18,28-31</sup>. The consumption of tuak is a tradition for the community of ethnic Dayak, so it is important to know the negative impacts that arise from consumption. Thus, the purpose of this study was to determine the effect of consuming tuak on blood glucose levels and histopathology of pancreatic organs.

## Material and Methods

### Animals

Male Balb/c mice were used as the experimental animal. They were 2-3 months and their weight was between 20-29 g. Before the experiment began, the animals were acclimatized. Animals were provided with standard rodent pellet diet, and the water and food were allowed *ad libitum*.

### The process of making tuak

Tuak is made by using 1 kg of *Oryza sativa* var. glutinosa which is washed with clean water, then put into a saucepan with 1 liter of water and cooked for  $\pm$  30 min. Then, as much as 40 g of fermentation yeast is mashed. The *Oryza sativa* var. glutinosa that has been cooked is then cooled. Furthermore, the *Oryza sativa* var. glutinosa is put into a jar that has previously been sprinkled with yeast, and the top of the *Oryza sativa* var. glutinosa is also sprinkled with yeast and some fresh chili. The jar is tightly covered for seven days. After seven days, the water in which results is taken and stored in a container. The liquor is named tuak. The laboratory of Badan Pengawas Obat dan Makanan at Pontianak-Indonesia in a letter No. PM.04.04.982.05.16.1098 stated that tuak contains ethanol content of 9.95%. This tuak is grouped in Group B liquor, which means liquor that can still be consumed.

### The damaging effect of consuming tuak on the pancreatic organ

Forty mice were grouped into four, each group consisting of ten mice. Group A was not administered

tuak while groups B, C, and D were administered tuak for 7, 14, and 21 consecutive days. Tuak was administered by using gastric sonde at dose 0.26 mL/20 g body weight per day. Blood sampling and pancreas organ sampling was performed on 1<sup>st</sup>, 8<sup>th</sup>, 15<sup>th</sup>, and 22<sup>nd</sup> day, respectively, for the group without tuak and the group that was administered tuak for 7, 14, and 21 consecutive days.

### Biochemical evaluation

Before blood sampling, the mice are not given any feed for  $\pm$ 18 h. Blood samples were taken from a wounded tail using a 26 g lancet (Medilance). The tool used to measure blood glucose levels is Easy Touch<sup>®</sup> GCU with Easy Touch<sup>®</sup> blood glucose strip.

### Histopathological examination

Sample pancreatic organs were routinely processed, then stained with hematoxylin-eosin<sup>32</sup>. The results of the staining were observed under a light microscope, and changes that appear were given a score.

0 = No specific changes were found

1 = Langerhans islet cells of the pancreas experienced edema and atrophy.

2 = Acinar cells underwent the dilation of lobules and karyolysis also the cells of the Langerhans islets experienced edema and atrophy.

3 = Acinar cells underwent the dilation of lobules and karyolysis also the cells of the Langerhans islets experienced edema, atrophy, and necrosis.

### Statistical analysis

The data of blood glucose levels and scoring of histopathological description were analyzed statistically by one-way ANOVA followed by Turkey's multiple comparisons using SPSS 23 for Windows. The difference was considered significant at  $P < 0.05$ .

## Results

The test results revealed that tuak used in this study contains ethanol with levels of 9.95% which means that this liquor can still be consumed. From (Table 1), it can be seen that the blood glucose level in the administered tuak group was higher than in the no administered tuak group ( $P < 0.05$ ). Related to (Table 1), the histopathologic scores of pancreatic organs in the administered tuak group was higher than the no administered tuak group (Table 2 & Fig. 1) ( $P < 0.05$ ). The results showed that the longer tuak was consumed, the higher the blood glucose levels. Similarly, the histopathological scoring

Table 1 — The average of blood glucose levels of male mice treated, with treatments of no administered tuak and administered tuak at dose 0.26 mL/20 g body weight per day for 7, 14, and 21 consecutive days (n=10)

Groups	Blood glucose level (mg/dL)
No administered tuak	54.70 ± 14.92 <sup>a</sup>
Administered tuak for 7 days	108.80 ± 22.69 <sup>b</sup>
Administered tuak for 14 days	93.10 ± 21.49 <sup>b</sup>
Administered tuak for 21 days	91.00 ± 26.25 <sup>b</sup>

Note: \*The data presented here represents samples ± standard deviation (SD).

\*Different superscript alphabet within the column indicate significant value at  $P < 0.05$ .

Table 2 — The damage scoring average of the pancreas in male mice with the treatment of no administered tuak and administered tuak at dose 0.26 mL/20 g body weight per day for 7, 14, and 21 consecutive days

Groups	Scoring Average
No administered tuak	0.00 ± 0.00 <sup>a</sup>
Administered tuak for 7 days	2.30 ± 0.48 <sup>b</sup>
Administered tuak for 14 days	2.50 ± 0.53 <sup>b</sup>
Administered tuak for 21 days	2.67 ± 0.50 <sup>b</sup>

Note: \*Different superscript alphabet within the column indicate significant value at  $P < 0.05$ .

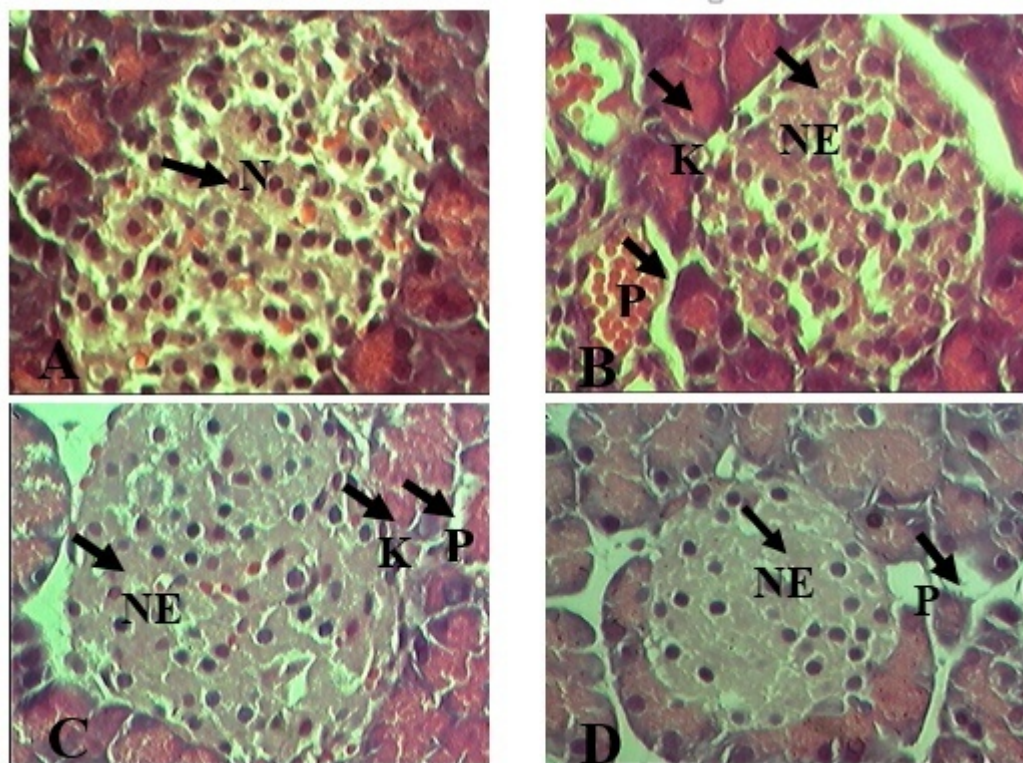


Fig. 1 — (A) Pancreas section of mice with no administered tuak; (B) Administered tuak for 7 days; (C) 14 days; and (D) 21 days. Tuak was administered orally at dose 0.26 mL/20 g body weight. Fig. (A) Showed pancreatic cell normal (N); Fig. (B-D) Showed pancreatic cell damage, NE (necrosis of Langerhans islet cells), P (dilation of lobules space in acinar cells), and K (karyolysis of acinar cells); and (H & E) (objective 40x)

of the pancreas also showed the extent of damage that got worse along with the length of time of tuak consumption.

### Discussion

Related to the result of this study, Mukherjee (2014)<sup>5</sup> reported that the effects of the consumption of alcoholic beverages are not only related to the amount consumed but also their consumption patterns. It has previously been reported that the consumption of alcoholic beverages in long terms causes severe

biological damage as well as negative effects by damaging the organs<sup>2-5,26</sup>. This research showed that the blood glucose levels and histopathology of pancreatic organs in the group without the tuak administration showed no change. Related to that, the histopathology of the pancreatic organ under normal condition is characterized by the orderly arrangement of endocrine cells that spread on the islets of Langerhans with a uniform shape and the size of the cytoplasm visibly proportional to the nucleus and unchanged. Also, the  $\beta$  cells and  $\alpha$  cells are in

relatively good condition which is marked by the condition of relatively close Langerhans islets. More than that, under normal conditions there is also minimal collagen fiber deposition<sup>10,18,21,30</sup>.

The damage to the pancreatic organ is associated with an increase in blood glucose levels<sup>20-29</sup>. The results of this study showed that in addition to the increase in blood glucose levels, the administration of tuak for 7, 14, and 21 consecutive days also showed the changes in the histopathology of the pancreatic organ. In the group for 7 days consecutively administered tuak as much as 70% of animals showed karyolysis and the dilation in the acinar cells, while the other 30% showed karyolysis and the dilation of lobular cells in acinar cells and necrosis in the islets of Langerhans cells. In the group with administered tuak for 14 days, 50% showed the dilation of lobules in acinar cells, while the other 50% showed the presence of necrosis of the cells of the Langerhans islets characterized by the tight arrangement of the cells of the Langerhans islets, the dilation of lobules in acinar cells, and karyolysis in acinar cells. Even in the group with tuak for 21 days as many as 10% of animals died on the eighth day of treatment, another 30% of experimental animals experienced a dilation of lobules in acinar cells, and another 60% experienced necrosis on Langerhans islet cells and dilation of lobules in acinar cells. According to Suarsana *et al.* (2010)<sup>21</sup>, the occurrence of death in animals in the treatment group may be group may be associated with the variations of body resistance of each individual.

Many researchers stated that the organ damage resulting from consuming alcoholic beverages is caused by a compound resulting from the metabolism of alcohol itself<sup>4,5,9-12,26</sup>. Furthermore, the consumption of alcoholic beverages would increase the number of free radicals but lower the antioxidants in the body resulting in oxidative stress. More than that, many researchers also stated that the oxidative stress will cause lipid peroxidation that will cause cell membrane damage so that the process of regulating the various substances through the passive and active transport process will be disrupted. Then, the loss of cell membrane integrity will lead to the accumulation of excess fluid in a tissue called edema which is the phase leading to necrosis<sup>11,14-20</sup>. Related to this study, according to the impact of free radicals on pancreatic organs is damage to pancreatic  $\beta$  cells that affect the number and size of the islet of Langerhans. Damage to  $\beta$  cells will have an impact on the inability of the

pancreas to produce the insulin hormone according to the needs of the body or low insulin secretion into the blood vessels that in the end will result in the occurrence of hyperglycemia. We assumed that the longer the tuak was consumed then the greater the damage caused to the pancreas organ.

### Conflicts of interest

All authors declare no conflict of interest.

### Acknowledgment

The authors are thankful to the Dayak tribe people in West Kalimantan-Indonesia, especially to Ms. Iin Ekawati, for sharing their knowledge to making tuak.

### References

- 1 Riskiyani S, Jannah M & Rahman A, Aspek sosial budaya pada konsumsi minuman beralkohol (tuak) di Kabupaten North Toraja. *Media Kesehat Masy Indones*, 11 (2015) 76.
- 2 Das SK & Vasudevan DM, Effect of ethanol on liver antioxidant defense systems: a dose dependent study. *Indian J Clin Biochem*, 20 (2005) 80.
- 3 Zakhari S, Overview: how is alcohol metabolized by the body?. *Alcohol Res Health*, 29 (2006) 245.
- 4 Mukherjee S, Das SK & Vasudevan DM, Effects of ethanol consumption on different organs-a brief overview. *Asian J Biochem*, 2 (2007) 386.
- 5 Mukherjee S, Alcohol metabolism and generation of free radicals: a deep insight. *OA Alcohol*, 2 (2014) 1.
- 6 Rachdaoui N & Sarkar DK, Pathophysiology of the effects of alcohol abuse on the endocrine system. *Alcohol Res*, 38 (2016) 1.
- 7 Setiawan VW, Monroe K, Lugea A, Yadav D & Pandol S, Uniting epidemiology and experimental disease models for alcohol-related pancreatic disease. *Alcohol Res*, 38 (2016) 1.
- 8 Noradina, Hutagaol AN & Siregar Y, Pemberian vitamin E terhadap fragilitas eritrosit pada mencit (*Mus musculus L.*) yang dipapari tuak. *J Ilm Keperawatan Imelda*, 3 (2018) 361.
- 9 Suaniti NM, Djelantik AAGS, Suastika K & Astawa NM, Liver damage due to alcohol intoxication repeat in wistar rats. *IndoVet J*, 13 (2012) 199.
- 10 El-Encin Rizk AA, Fattah SA & El Sebaie M, Can vitamin E protect the pancreas against ethanol-induced alterations in adult male albino rats? A histomorphometric and immunohistochemical study. *Kash Al Ainy Med J*, 23 (2017) 43.
- 11 Shalбиеva N, Mareninova OA, Gerloff A, Yuan J, Waldron RT, Pandoll SJ & Gukovskaya AS, Effects of oxidative alcohol metabolism on the mitochondrial permeability transition pore and necrosis in a mouse model of alcoholic pancreatitis. *Gastroenterol*, 44 (2013) 437.
- 12 Siswanto B, Agustingsih D & Purwono S, Rosela (*Hibiscus sabdariffa*) mencegah kenaikan tekanan nadi kenaikan malondialdehyde dan meningkatkan status antioksidan total tikus yang diinduksi alkohol. *J Obstretika Scientia*, 2 (2014) 103.
- 13 Pratama H, Tatalaksana pankreatitis aku. *CDK-238*, 43 (2016) 190.
- 14 Criddle DN, Reactive oxygen species,  $Ca^{2+}$  stores and acute pancreatitis; a step closer to therapy?. *Cell Calcium*, 60 (2016) 180.

- 15 Mukherjee R, Mareninova OA, Odinkova IV, Huang W, Murphy J, Chvanov M, Javed MA, Wen L, Booth DM, Cane MC, Awais M, Gavillet B, Pruss RM, Schaller S, Molkentin JD, Tepikin AV, Petersen OH, Pandol SJ, Gukovsky I, Criddle DN, Gukovskaya AS & Sutton R, NIHR Pancreas Biomedical Research Unit, Mechanism of mitochondrial permeability transition pore induction and damage in the pancreas: Inhibition prevents acute pancreatitis by protecting production of ATP. *Gut*, 65 (2016) 1333.
- 16 Armstrong JA, Cash NJ, Ouyang Y, Morton JC, Chvanov M, Latawiec D, Awais M, Tepikin AV, Sutton R & Criddle DN, Oxidative stress alters mitochondrial bioenergetics and modifies pancreatic cell death independently of cyclophilin D, resulting in an apoptosis-to-necrosis shift. *J Biol Chem*, 293 (2018) 8032.
- 17 Veerabhadrapppa KV & Raveendra RJ, Antidiabetic activity of ethanolic extract of *Sesbania grandiflora*. *Int J Res Pharm Sci*, 8 (2017) 650.
- 18 WalvekarMV, Potphode ND, Desai SS & Deshmukh VM, Histological studies on islets of langerhans of pancreas in diabetic mice after curcumin administration. *Int J Pharm Clin Res*, 8 (2016) 1314.
- 19 Hosseini A, Shaffiee-Nick R & Ghorbani A, Pancreatic  $\beta$  cell protection/regeneration with phytotherapy. *Braz J Pharm Sci*, 51 (2015) 1.
- 20 Sharma S, Mishra V & Srivastava N, Protective effect of *Trigonella foenum-graecum* and *Cinnamomum zeylanicum* against diabetes induced oxidative DNA damage in rats. *Indian J Biochem Biophys*, 56 (2019) 15.
- 21 Suarsana IN, Priosoeryanto BP, Bintang M & Wresdiyati T, Profile of blood glucose and ultrastructure of  $\beta$  cells pancreatic islet in alloxan compound induced rats. *Indo J Anim Vet Sci*, 15 (2010) 118.
- 22 Mistry KN, Dabhi BK & Joshi BB, Evaluation of oxidative stress biomarkers and inflammation in pathogenesis of diabetes and diabetic nephropathy. *Indian J Biochem Biophys*, 56 (2019) 45.
- 23 Aprila IF, Salim MN, Daud R, Armansyah T, Asmiliana N & Jamin F, Effect of long bean (*Vigna unguiculata*) on blood glucose level of mice (*Mus musculus*) induced by alloxan. *J Med Vet*, 9 (2015) 97.
- 24 Zubaidah E & Nuril F I, Effects of apple vinegar and salacca vinegar on reducing blood glucose and pancreatic histopathology of diabetic wistar rats. *Med J Brawijaya*, 28 (2015) 297.
- 25 Sewani-Rusike CR, Jumbam DN, Chinhoyi LR & Nkeh-Chungag BN, Investigation of hypoglycemic and hypolipidemic effects of an aqueous extract of *Lupinus albus* legume seed in streptozotocin-induced type-1 diabetic rats. *Afr J Tradit Comple Altern Med*, 12 (2015) 36.
- 26 Pandarekandy ST, Kannamparthazhathethil SG, Abdulrahiman R, Shahal A, Subrahmanyam SP & Edakkot S, A Prospective Study to Evaluate Daily Moderate Consumption of Ethanol on Oxidative Stress Markers of Diabetes Induced Wistar Strain Albino Rats. *Br J Pharm Res*, 8 (2015) 1.
- 27 Zhang X, Jin T, Shi N, Yao L, Yang X, Han C, Wen L, Du D, Szatmary P, Mukherjee R, Liu T, Xia Q, Criddle DN, Huang W, Chvanov M & Sutton R, Mechanisms of pancreatic injury induced by basic amino acids differ between L-arginine, L-ornithine, and L-histidine. *Front Physiol*, 9 (2019) 1.
- 28 Njeri LK, Njangiru IK, Eliud NMN & George OO, Antidiabetic activity of administration of aqueous extract of *Berberis holstii*. *J Diabetes Metab*, 8 (2017) 1.
- 29 Zolghadar L, Farahani BV, Ghasemzadeh H & Javadi N, Physicochemical studies of closed loop insulin delivery system based on intelligent carboxymethyl cellulose hydrogel. *Indian J Biochem Biophys*, 56 (2019) 125.
- 30 Jasmine R, Ganesh KA & Rajaram R, Probing the mechanism of the anti-diabetic potential of a terpenoid from *Elephantopus scaber* L., an Indian ethnomedicinal plant in STZ diabetic rats-*In vivo* and *in silico* analysis. *Indian J Biochem Biophys*, 55 (2018) 384.
- 31 Robertson RP, Harmon J, Tran POT & Poutout V,  $\beta$ -cell glucose toxicity, lipotoxicity, and chronic oxidative stress in type 2 diabetes. *Diabetes*, 53 (2004) S119.
- 32 Adam GO, Kim GB, Lee SJ, Lee H, Kim SJ, Kim JS & Kang HS, Ultraviolet-C haematogenous oxidation therapy of lipopolysaccharide-induced endotoxemia in a rabbit model: A biochemical study. *Indian J Biochem Biophys*, 56 (2019) 445.