



Some Comparative Anatomical Studies on the Laryngeal Muscles and Cavity of Buffaloes, Camels and Donkeys

Mohamed A. Metwally, Hatem B. Hussieni, Ahmed A. Kassab, Eman A. Eshrah*

Department of Anatomy and Embryology, Faculty of Veterinary Medicine, Benha University, Egypt.

ARTICLE INFO

Original Research

Received:

11 June 2018

Accepted:

29 June 2018

Keywords

Laryngeal Muscles Cavity
Buffaloes
Camels
Donkeys

ABSTRACT

The aim of this study was to compare between the laryngeal muscles and cavity in buffaloes, camels and donkeys. A total of 30 larynxes (10 larynxes from each species) were subjected to study. In the three species, the laryngeal muscles were similar to those of other domestic animals, but the hyoepiglotticus muscle of camel was remarkably longer. Although the thyroarytenoideus muscle was undivided in the buffalo and camel, the slightly deeper lateral ventricle in camel, allowed the muscle anterior part to be covered with mucous membrane forming the vestibular fold. The laryngeal cavity of donkey was characterized by the presence of lateral laryngeal sacculae that located between the two separate parts of thyroarytenoideus muscle, the vestibular and vocal muscles; the presence of two small pouches on both sides of median laryngeal recess, and the cuneiform tubercle, which was a mucosal elevation that covered the cuneiform process. This study will fill a gap in the field of comparative anatomy and help other clinical investigation applied on these animals.

J. Adv. Vet. Res. (2018), 8 (3), 32-37

Introduction

Camels and donkeys have peculiar vocalization. Camels are known by their ability to produce different ranges of sounds; up to 14 voices that differ in pitch and intensity. Donkeys are the only known domestic animals that able to produce sound during inspiration (Lindsay and Clayton, 1986). This indicates the presence of special laryngeal anatomy, which may be related to the muscular attachment or the shape of laryngeal cavity. Comparison between animals will help understanding their anatomical peculiarities and provide important information to the field of comparative phonetics and animal vocalization.

The muscles of the larynx can be classified according to their attachments into extrinsic and intrinsic muscles. In the domestic animals, there are three extrinsic muscles, include sternothyroideus, thyrohyoideus and hyoepiglotticus. There are at least five intrinsic muscles, include, cricothyroideus, cricoarytenoideus lateralis, arytenoideus transverses, thyroarytenoideus muscles, and the cricoarytenoideus dorsalis (Hare,

1975; Nickel *et al.*, 1979). The laryngeal cavity in domestic animals resembles the Glass-hour, with the narrowest part represents the glottis, the entrance is the adituslaryngis and the outlet is the infraglottic cavity (Nickel *et al.*, 1979).

Studying laryngeal anatomy is important to plan for any surgical interference or clinical investigation in larynx. It also helps understanding the pathogenesis, fate and development of certain diseases, such as laryngeal hemiplagia or "roaring" in equine (Thiemann and Bell, 2000; Badawy, 2005). However, literature regarding the internal anatomy of larynx is scarce, for these, the aim of the present study was to compare between the laryngeal muscles and cavity in buffaloes, camels and donkeys. The origin, insertion and relations of the muscles as well as the cavity partitions, ventricles and recess were discussed.

Materials and methods

The present investigation was carried out on 30 larynxes of buffaloes, camels and donkeys. Buffaloes and camel's heads were obtained immediately after slaughtering at Toukh abattoir (Benha, Egypt), while donkey's heads were obtained from donkey's euthanized at the Faculty of Veterinary Medicine, Benha University, Egypt. Ten heads (5 males and 5 females)

*Corresponding author: Eman A. Eshrah
E-mail address: mevet213@gmail.com

from each species were kept at 4°C and used for gross anatomical study.

For gross anatomy, larynxes were dissected to demonstrate the laryngeal muscles and cavity. The different laryngeal measurements were performed according to Abdel-Rahman (1990); Moussa (1998).

Nomenclature used in this study was adopted by Nomina Anatomica Veterinaria (2006); Schaller (1992).

This study was approved by the Institutional Animal Care and Use Committee of Benha University, Egypt.

Results

Musculi laryngis

Extrinsic muscles of the larynx

M. sternothyroideus

In buffaloes, the sternothyroideus muscle (Figs 1/10, 2/6) was inserted on dorsal half of caudal border of thyroid lamina in adjacency with origin of *M. thyropharyngeus* and *thyrohyoideus*. In camels, it was ended on the lateral surface of the lamina of the thyroid cartilage, caudal to oblique line (linea obliqua) and just caudal to the origin of *M. thyrohyoideus*, while in the donkey it was inserted only at caudal part of oblique line.

In the three species the sternothyroid muscle was related superficially to omohyoideus muscle and deeply to the cricothyroideus, cricopharyngeus and thyropharyngeus muscles.




Fig. 1. A photograph of fresh specimens of ventral view of larynx in buffalo, camel and donkey (formalized specimen) showing: 1) *Corpus thyroideum*. 2) *M. cricothyroideus*. 3) *Lig. Cricothyroideum*. 4) *Cartilage cricoidea*. 5) *Lig. cricotracheale*. 6) First tracheal ring. 7) *Os hyoideus*. 8) *M. ceratohyoideus*. 9) *M. thyrohyoideus*. 10) *M. sternothyroideus*. 11) *M. hyoepiglotticus*.

M. thyrohyoideus

The thyrohyoideus muscle (Figs 1/9, 2/5) was a paired muscle.

In buffaloes and camels, the muscle fibers were directed rostrally, while in donkeys they were directed rostradorsally. In buffaloes and donkeys, it was a strap-like muscle, but in camels, only the caudal half was strap like, while, the rostral half fanned out toward its insertion.

It was originated from linea obliqua in buffaloes, and from linea obliqua and the adjacent part ventral to it in camels. It arose from caudoventral part of linea obliqua of lateral surface of thyroid lamina in donkeys.

In donkeys, it was inserted on caudal border of thyrohyoid bone. Whereas, in buffaloes and camels, it was inserted on caudal border of thyrohyoid and ipsilateral half of basihyoid, but in buffaloes, only the distal part of caudal border was included.

In the three species, the thyrohyoideus muscle related medially to lamina of thyroid cartilage and the thyrohyoid membrane. In buffaloes and camels, it also related laterally to the omohyoideus muscle and the mandibular gland.

M. hyoepiglotticus

In the three species, the hyoepiglotticus muscle (Fig 1/11) was a single muscle, and the muscle fibers directed caudodorsally and it was notably long in camel.

In buffaloes, it was originated from the medial aspects of the right and left ceratohyoid bones. In camel, it arose from the ventral half of medial surface of the right and left ceratohyoid bones and in donkey it arose from the middle of dorsal surface of basihyoid bone and the dorsal surface of lingual process of hyoid bone. In the three species the right and left bundles proceed caudally converging toward midline, and the muscle inserted on middle of lingual surface of epiglottic cartilage.

Intrinsic muscles of the larynx

M. cricothyroideus

The cricothyroideus (Figs 2/2, 3/2) was a paired muscle, as its name implies, it located between the cricoid and the thyroid cartilages. It was rectangular to square shaped muscle, with rostradorsal-directed the fibers. It was related laterally to the termination of the *M. sternothyroideus*, and medially to the cricoid arch and the cricothyroid ligament.

In buffaloes and camels, the *M. cricothyroideus* was originated from the caudal border, the lateral and ventral surfaces of the cricoid arch. In donkeys, it arose from the caudal border and the lateral surface of the cricoid arch. In the three species, the muscle was inserted at the ventral border of the caudal thyroid cornu, but in camels and donkeys, it also made insertion on the adjacent part of the lateral surface of thyroid lamina.

M. cricoarytenoideus lateralis

The cricoarytenoideus lateralis (Fig 3/3) was a paired muscle, which located medial to the thyroid lamina and the *M. cricothyroideus*. In three species, the muscle was taken origin from the rostral border of the lateral part of the cricoid arch, but it originated also from the adjacent part of the lateral surface of the cricoid arch, in the buffalo and donkey. It was inserted on the muscular process ventrolateral parts in buffalo and camel, and caudo-ventral parts in donkey.

The muscle was related laterally to the medial surface of

the thyroid lamina and medially to the caudal part of the thyroarytenoideus muscle and the vocal process of the arytenoid cartilage in buffaloes and camels, as well as, Muscle vocalis and the laryngeal ventricle (laryngeal saccule) in donkeys.

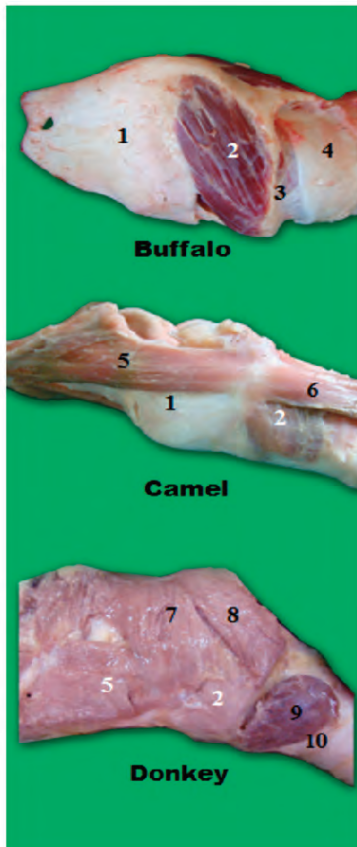


Fig. 2. A photograph of fresh specimens of lateral view of larynx in buffalo, camel and donkey (formalized specimen) showing: 1) *Cartilago thyroidea*, 2) *M. cricothyroideus*, 3) *Lig.cricotracheale*, 4) First tracheal ring, 5) *M. thyrohyoideus*, 6) *M. sternothyroideus*, 7) *M. thyropharyngeus*, 8) *M. cricopharyngeus*, 9) *Gl. thyroidea*, 10) Trachea.

M. thyroarytenoideus

The thyroarytenoideus muscle (Fig 3/4) was a paired muscle. In buffaloes and camels, it was undivided and originated from the base and ventral part of the lateral border of epiglottis, the medial surface thyroid lamina and the cricothyroid membrane. It was inserted into the muscular and the vocal processes of the arytenoid cartilage. It was related medially to the laryngeal mucous membrane, and the ventricular and the vocal ligaments, while it was related laterally to the lamina of the thyroid cartilage, the *cricoarytenoideus lateralis* muscle and a fat pad.

In donkeys, *M. thyroarytenoideus* was divided into two parts a rostral part *M. ventricularis* and a caudal one *M. vocalis*, which separated by the laryngeal ventricle (Figs 3/5, 6).

M. Ventricularis (Fig 3/6) arose from the rostroventral part of the medial thyroid lamina, and a small part of the cricothyroid membrane and inserted on the muscular process of the arytenoid cartilage. It was related to the cuneiform cartilage and the vestibular ligament medially, and to the lamina of the thyroid cartilage laterally.

M. vocalis (Fig 3/5) was originated from the body of the thyroid cartilage, inserted on the muscular and vocal processes of the arytenoid cartilage, and related medially to the vocal ligament, and laterally to the lateral cricoarytenoideus muscle.

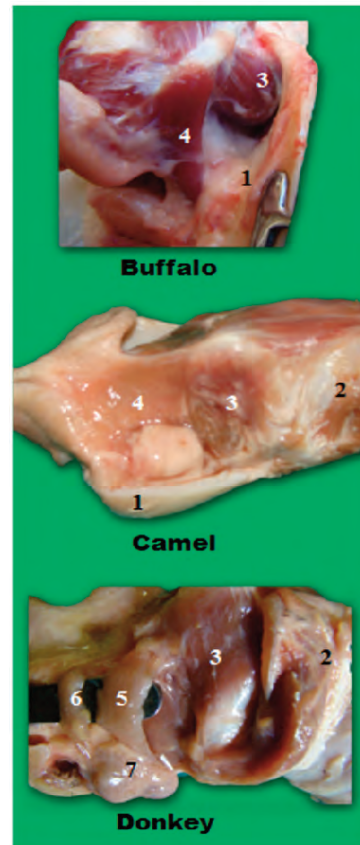


Fig. 3. A photograph of fresh specimens of lateral view of larynx after removal of thyroid lamina in buffalo, camel and donkey showing: 1) *Cartilagothyroidea*. 2) *M.cricothyroideus*. 3) *M. cricoarytenoideus lateralis*. 4) *M. thyroarytenoideus*. 5) *M. vocalis*. 6) *M. ventricularis*. 7) *Ventriculus laryngis*

M. cricoarytenoideus dorsalis

The cricoarytenoideus dorsalis muscle (Fig 4/2) was a paired muscle, which located in dorsal surface of the larynx and the muscle and its fellow together with the median crest of the cricoid lamina have the shape of a butterfly. It was originated from the median crest of cricoid lamina, and the adjacent rough area on both sides, its fibers were directed rostrrolaterally to insert on the muscular process of the arytenoid cartilage. It was related dorsally to the beginning of the esophagus. In buffalo and donkeys, some superficial fibers of this muscle blended with the esophageal wall to form *M. cricoesophageal*.

M. arytenoideus transversus

The arytenoideus transversus muscle (Fig 4/3) was a single muscle, which extended between the arycorniculate ligaments and related dorsally to the esophageal entrance. It was originated from the ridge between the dorsal and the lateral surfaces of one arytenoid cartilage (*Crista arcuata*), and passed transversely across the dorsal aspect of the larynx to be inserted on the same ridge of the opposite cartilage.

Cavum laryngis

Aditus laryngis

The adituslaryngis (Fig 5/3) was bounded laterally by aryepiglottic folds, rostrally by epiglottis and caudodorsally by corniculate processes. In buffaloes and donkeys, it was oval, while in camels, it was triangular with its base directed toward

the epiglottis.

Its longitudinal axis (length) was ranged between 2-2.5 cm, 3.5-4.5 cm and 2-2.5 cm in length, in buffaloes, camels and donkeys, respectively. Its transverse axis (width) was measured 2.5-3.5cm, 3-4 cm and 2-3 cm in buffaloes, camels and donkeys, respectively.

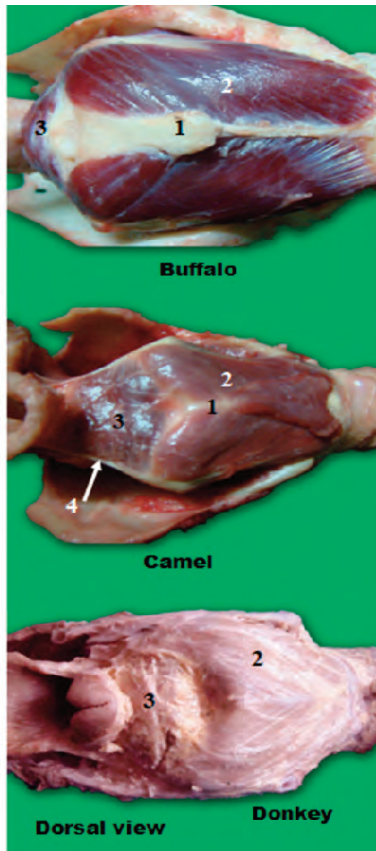


Fig. 4. A photograph of fresh specimens of dorsal view of larynx in buffalo, camel and donkey (formalized specimen) showing: 1) *Crista mediana*. 2) *M. cricoarytenoideus dorsalis*. 3) *M. arytenoideus transverses*. 4) *Lig. Arycorniculatum*.

Plica aryepiglottica

The aryepiglottic fold (Fig 5/10) was extended from lateral border of the epiglottis. In donkeys, it blended to arytenoid and the corniculate process, while in buffaloes and camels, it was extended caudodorsally lateral to corniculate process, and then curved medially over the arytenoid and cricoid cartilages, until it united with the floor of the esophageal vestibule. Its length was measured 10-15 cm in the camel, 7-10 cm in the buffalo and 2-5-4 cm in the donkey.

Tuberculum cuneiforme

Only in donkeys, the cuneiform tubercle was present as a mucosal elevation, which located at the ventral part of the aryepiglottic folds, where it covered the cuneiform processes. It was measured 2-2.5 cm in length.

Tuberculum corniculatum

The tuberculum corniculatum (Fig 5/2) was formed a mucosal eminence formed by the processus corniculatus, caudodorsal to the *aditus laryngis*.

Vestibulum laryngis

The laryngeal vestibule was compressed laterally and ex

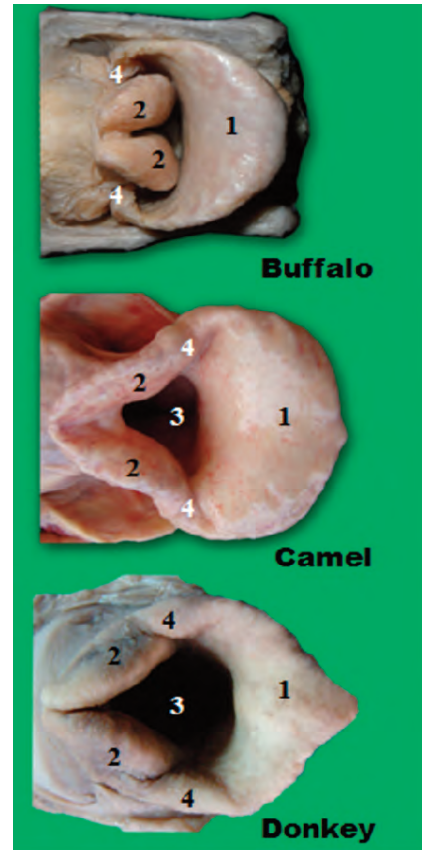


Fig. 5. A photograph of formalized specimens of Adituslaryngis in buffalo, donkey and camel (fresh specimen) showing: 1) *Cartilago epiglottica*. 2) *Tuberculum corniculatum*. 3) *Aditus laryngis*. 4) *Plica aryepiglottica*.

tended from aditus laryngis to glottis, and communicated ventrally with median laryngeal recess.

In camels, the vestibule communicated laterally with laryngeal ventricle through a slit like opening (Fig 6/5). This communication was also present in donkey but the opening was wider and crescent-like. In buffaloes, the laryngeal ventricle and its opening were absent.

Ventriculus laryngis

In camels, the laryngeal ventricle (Fig 6/5) was a shallow evagination located in the lateral wall of the laryngeal vestibule. It was located between the vestibular and vocal folds and dips into the thyroarytenoideus muscle but not divided it into two parts. In donkeys, the laryngeal ventricle was a slightly deep evagination in lateral wall of vestibule which extended to form a bilateral pouches the laryngeal sacculae (Fig 4/7).

Recessus laryngis medianus

The median laryngeal recess (Fig 6/6) was a shallow depression located at the base of epiglottis. It was deeper in camels, while that of donkeys has two characteristic orifices on both sides that leading into small expanded pouches.

Plica vestibularis

The vestibular fold was present only in camels and donkeys (Fig 6/4), it was located rostral to the vocal fold and separated from it by the opening of the lateral laryngeal ventricle. In camels, it presents as a mucosal relief and not a true fold and enclosed the vestibular ligament and a part of the thy-

roarytenoideus muscle (without dividing it). In donkeys, it was enclosed the vestibular muscle and ligament. In camel, it was measured 5-6 cm in length, 1.5-2 cm in width and 1-1.40 mm in thickness. In donkey, it was 2.5-3 cm in length and 1-1.5 cm in width and 1-1.15 mm in thickness.

Plica vocalis

In buffaloes and camels, it enclosed the vocal ligament (Fig 6/3) and the caudal part of the thyroarytenoideus muscle, while in donkeys, it enclosed the vocal ligament and muscle. In camels, it measured 5.5-6 cm in length, 1-2 cm in width and 1-1.5 mm in thickness. In buffaloes it was measured 4-5 cm in length, 1-2 cm in width and 1-1.5 mm in thickness. In donkeys it measured 2-3 cm in length, 1-1.5 cm in width and 1-1.3 mm in thickness.

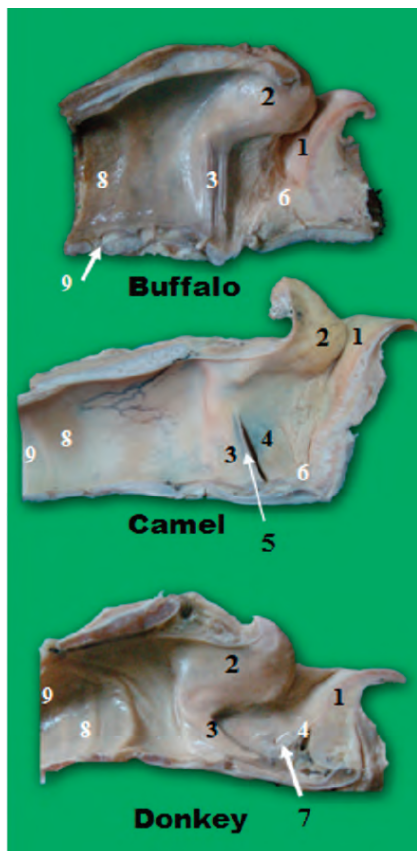


Fig. 6. A photograph of formalized specimens of median section of larynx in buffalo, camel and donkey showing: 1) *Cartilago epiglottica*. 2) *Cartilago arytenoidea*. 3) *Plica vocalis*. 4) *Plica vestibularis*. 5) *Ventriculus laryngis*. 6) *Recessus laryngis medianus*. 7) An orifice in recessus laryngis medianus. 8) *Lig. cricotracheale* 9) First tracheal ring.

Discussion

Results clarified that the three studied species have the same set of extrinsic muscles that described in other domestic animals, which include thyrohyoideus, sternohyoideus and hyoepiglotticus muscles in domestic animals (Hare, 1975 and Nickel *et al.*, 1979), in camels (Smuts and Bezuidenhout, 1987) and in the buffaloes (Attia and Moustafa, 1989), whereas, a different set of muscles were described in the Mongolian gazelle, which formed the omohyoid and the sternothyrohyoid muscles (Frey and Gebler, 2003).

In buffaloes and donkeys, the thyrohyoideus muscle was originated from the oblique line and extended until it reached the area for attachment of thyropharyngeous muscle, similar

findings were reported in buffaloes (Attia and Moustafa, 1989) and in ruminants and equine (Hare, 1975), however this differ with the observations of Georgi (1951), who reported that, it originated from the dorsal and posterior borders of the thyroid lamina at their junction.

The insertion of sternothyroideus muscle is controversial. In buffaloes, it was inserted on dorsal half of caudal border of thyroid lamina, but Attia and Moustafa (1989) provided another site in the same species, which was the rough line located on lateral aspect of thyroid lamina. Georgi (1951) observed that the insertion site in camels was into the posterior border and adjacent part of thyroid lamina, while results revealed that it was on the caudal part of oblique line. In donkeys, results were slightly similar to that described by Hare (1975), but the insertion did not reach the prominence of caudal border of lamina of thyroid at the ventral end of oblique line.

In the three species, the hyoepiglotticus muscle was a single but bifid muscle, as it arose by two limbs, which united together at a variable distance to end into the central part of lingual surface of epiglottis. These findings similar to that mentioned in swine and carnivores (El-Hagri, 1967), in equines (Hare, 1975) and in buffalo (Attia and Moustafa, 1989).

According to Hare (1975) and Nickel *et al.* (1979) in domestic animals and Abdel-Rahman (1990) in donkeys, the intrinsic muscles of the larynx are divided into two groups, the adductor group, which includes cricothyroideus, cricoarytenoideus lateralis, arytenoideus transversus and thyroarytenoideus muscles, and the abductor group, represented by the cricoarytenoideus dorsalis, and this comes in agreement with the results of the present study.

Results revealed that, *M. cricothyroideus* was originated from caudal border and lateral surfaces of cricoid arch, this similar to that reported in equine and ruminants by Hare (1975), While Smuts and Bezuidenhout (1987) in camels, restricted its origin to the lateral surface of cricoid arch.

In buffaloes and camels, *M. thyroarytenoideus* was undivided, as described by Nickel *et al.* (1979) in large ruminant and Attia and Moustafa (1989) in buffaloes. However, in donkeys, it was divided into two parts, a rostral part or *M. ventricularis* and a caudal part or *M. vocalis*. These findings were similar to that given by Nickel *et al.* (1979) and Kent (1992) in dogs and horses, and Thiemann and Bell (2000) and Badawy (2005) in donkeys. Accordingly, the vestibular fold was absent in buffaloes and present in camels and donkeys (El-Hagri, 1967; Nickel *et al.*, 1979) in ruminants and equines.

The aditus laryngis in buffaloes and donkeys was oval in shape; similar observations were recorded by Nickel *et al.* (1979) in domestic animals, Attia and Moustafa (1989) in buffaloes and Lindsay and Clayton (1986) in horses and donkeys. However, in camels, it did not take the usual oval outline, because of the large and movable epiglottis, but when grasped manually the aditus appeared triangular.

Only in donkeys, the tuberculum cuneiform was present as a mucosal elevation that covered the cuneiform processes and supported the aryepiglottic folds ventrally on both sides of base of epiglottis.

The study showed the presence of the ventriculus laryngis in camels and donkeys, and this confirmed the results of Smuts and Bezuidenhout (1987) in camels, Lindsay and Clayton (1986) Thiemann and Bell (2000) and Badawy (2005) in donkeys. However, it was absent in all buffaloes' specimens, and this also comes in agreement with the available literature, such as Frey and Gebler (2003) in bovine and ruminants. In donkeys, the laryngeal saccule, which was an extension of laryngeal ventricle was also present, this reported by Lindsay and Clayton (1986); Thiemann and Bell (2000) and Badawy (2005) in donkeys.

The median laryngeal recess was present in the three studied species. It was also recorded in horses and pigs (Hare, 1975; Nickel *et al.*, 1979), in camels (Smuts and Bezuidenhout, 1987) and in musk ox (Frey *et al.*, 2006). Only in donkeys, two orifices were present on both sides of median recess, when traced laterally, each one led to an expanded pouch, this confirms the previous observations in donkey (Lindsay and Clayton, 1986).

Conclusion

The basic anatomy of the laryngeal muscles and cavity in the buffaloes and donkeys were similar to those described in large ruminant and equine, respectively. However, camels were characteristic by the presence of a notably long hyoepiglotticus muscle, and a vast attachment between the thyroarytenoideus and the epiglottis cartilage, which may allow the epiglottis to move in various directions, changing the shape of the laryngeal cavity more than in the other species.

Acknowledgments

My utmost gratitude and acknowledgment are due to Prof. Dr. M.O.H. EL SHAIB, Professor and Previous Dean of Faculty of Veterinary Medicine, Benha University for his observations and his valuable continuous aid during this work.

References

- Abdel-Rahman, Y.A., 1990. Comparative macro-and-micromorphological studies on the larynx of different domestic animals (equidea, rumenanta and carnivore). Ph.D. Thesis. Assiut University. Egypt.
- Attia, M., Moustafa, I.A., 1989. Some morphological and histological studies on the larynx of buffalo (*Bos Bubalis*). Egyptian Society of Histology and Cytology. 13th Scientific Conference. Faculty of Medicine, Ain Shams University, Egypt
- Badawy, A.M., 2005. Experimental studies on laryngeal hemiplegia in equine with special reference to surgical affections of nearby structures. Ph.D., Zagazig University, Faculty of Veterinary Medicine, Egypt.
- El-Hagri, M.A.A., 1967. Splanchnology of the Domestic Animals. 1st edition. Cairo Univ. Press., Egypt.
- Frey, R., Gebler, A., 2003. The highly specialized vocal tract of the male Mongolian gazelle (*Procapra gutturosa* Pallas, 1777--Mammalia, Bovidae). *J. Anat.*, 203, 451-471.
- Frey, R., Gebler, A., Fritsch G., 2006. Arctic roars – laryngeal anatomy and vocalization of the muskox (*Ovibos moschatus* Zimmermann, 1780, Bovidae). *J. Zool.* 268, 433-448.
- Georgi, A.N., 1951. The respiratory system in the camel and its histology. M.V. Sc. Thesis, Faculty of Vet. Med. Cairo Univ. Egypt.
- Hare, W.C.D., 1975. Equine respiratory system and ruminant respiratory system. In: Sisson and Grossman. Anatomy of the domestic animals 5th ed. W.B. Saunders Company, Philadelphia. U.S.A. 1, 498-524 and 916-937.
- Kent, G.C., 1992. Comparative Anatomy of the Vertebrates. 9th ed. McGraw Hill-companies. U.S.A, pp. 293-313.
- Lindsay, F.E.F., Clayton, H.M., 1986. An anatomical and endoscopic study of the nasopharynx and larynx of the donkey (*Equus asinus*). *J. Anat.* 144, 123- 132.
- Moussa, E.A.M., 1998. Morphological studies on the prenatal development of the larynx in the one-humped camel. M.V. Sc., Suez Canal University. Faculty of Veterinary Medicine, Egypt
- Nickel, R., Shummer, A., Seiferle, E., 1979. The Viscera of the Domestic Animals. 2nd revised ed. Verlag Paul Parey. Berlin, Hamburg. pp. 211-281.
- Nomina Anatomica Veterinaria, 2006. Electronic edition. Published by the international committees on veterinary gross anatomical nomenclature under the finance responsibility of the world association of veterinary anatomists. Zurich and Ithaca, New York.
- Schaller, O., 1992. Illustrated veterinary anatomical nomenclature. 5th ed. Ferdinand Enke Verlag Stuttgart, Germany. pp. 174-194.
- Smuts, M.S., Bezuidenhout, A.J., 1987. Anatomy of the dromedary. 1st ed. Clarendon Press, Oxford. U.S.A. pp. 105-121.
- Thiemann, A.K., Bell, N.J., 2001. The peculiarities of donkey respiratory disease. International Veterinary Information Service, Ithaca, New York, U.S.A.