



Occurrence of Helminths in the Great Cormorants, *Phalacrocorax carbo*, in Qena, Egypt

Khaled Mohamed El-Dakhly^{1*}, Nermean M. Hussein², El-Shaymaa El-Nahass³

¹Department of Parasitology, Faculty of Veterinary Medicine, Beni-Suef University, Beni-Suef 62511, Egypt

²Department of Zoology, Faculty of Science, South Valley University, Qena, Egypt

³Department of Pathology, Faculty of Veterinary Medicine, Beni-Suef University, Beni-Suef 62511, Egypt

ARTICLE INFO

Original Research

Received:

18 December 2017

Accepted:

31 December 2017

Keywords:

Phalacrocorax carbo
Helminths
Contracaecum sp.
Qena, Egypt

ABSTRACT

Three adult female cormorants, *Phalacrocorax carbo*, were found dead in Qena province, Egypt in December 2016. They were immediately sent to the Laboratory in Faculty of Science, South Valley University, Egypt, for necropsy. Apparently, the birds had no gross lesions or suffered from injured or damaged tissue. Complete evisceration of internal organs was performed, and birds were subjected to a full parasitological examination for the detection of helminths. Helminthiasis was only detected in the gastrointestinal tracts. Among the recovered helminths, three trematodes, one tapeworm, and three nematode species were found. Digeneans were identified as *Clinostomum complanatum* (n=3; at the first part of the oesophagus), *Ribeiroia ondatrae* (n=2; at the middle part of the oesophagus), and *Paryphostomum radiatum* (n=3; in the small intestine). The revealed cestodes species (n=one; in the small intestine) were identified as *Paradilepsis scolecina*. Lastly, the recovered nematodes (n=3; in the stomach) were identified as *Contracaecum rudolphii*, *Contracaecum microcephalum*, and *Contracaecum chubutensis*. It was noted that mixed infection of all helminth species was found in a single bird. Moreover, another bird also presented with mixed infection of *Contracaecum* spp. and digeneans. Histopathological examination revealed leucocytic infiltration surrounding the embedded digeneans, hyperplasia of the proventricular wall, as well as necrosis with remnants of degenerated trematodes. To the best of the authors' knowledge, this is the first study revealing *Clinostomum complanatum*, *Ribeiroia ondatrae*, *Paryphostomum radiatum*, *Paradilepsis scolecina*, *Contracaecum rudolphii*, *Contracaecum microcephalum*, and *Contracaecum chubutensis* in the great cormorant, *Phalacrocorax carbo*, in Egypt.

J. Adv. Vet. Res. (2018), 8 (1),6-11

Introduction

The great cormorant, *Phalacrocorax carbo* (L. 1758) (Pelecaniformes: Phalacrocoracidae), is a common migratory ichthyophagous bird reared in colonies worldwide, and can be found in all continents aside from South America and Antarctica (Moravec and Scholz, 2016). Such birds can feed on various species of fish, predominantly cyprinids and percids, which constitute the majority of fresh water fish (Prejs, 1978; Martyniak *et al.*, 1997; Mellin and Krupa, 1997).

Previous studies have shown that increasing number of migratory birds harbor various parasites, as they travel across different topographical districts with the availability of appropriate intermediate hosts (Hoberg *et al.*, 2008; Koprivnikar and Leung, 2015; Amundson *et al.*, 2016). The presence of parasites in the ecosystems is encouraged by climatic changes, primarily high temperatures (Dziekonska-Rynko and Rokicki, 2008). Droppings from infected cormorants containing parasites at various developmental stages can therefore disseminate in water, where intermediate hosts are available to complete the life cycles of the helminths. Moreover, migratory birds, particularly great cormorants, have a negative impact on fish pro-

duction, as fish often serve as secondary intermediate hosts for helminths and they are considered the main diet for cormorants (Wheeb *et al.*, 2015).

Since no studies have previously examined the helminth community in the great cormorants and other pelecaniformes in Egypt, we aimed to investigate the presence of helminths in three great cormorants, *Phalacrocorax carbo*, that were found dead in Qena province, Upper Egypt. In Egypt, this is the first step attempting to determine the association between ecological conditions and the existence of parasites in cormorants, which can have a great impact on both naturally reared and cultured fish.

Materials and methods

Study area

Three adult female great cormorants, *Phalacrocorax carbo* (L. 1758), were found dead in an urban area near the Nile River in Qena province (coordinates: 26°10'12"N 32°43'38"E), Egypt. They were immediately sent to the Laboratory in the Faculty of Science, South Valley University, Egypt, for necropsy.

Parasitological investigations

Gross examination of birds revealed no visible abnormal-

*Corresponding author: Khaled Mohamed El-Dakhly

E-mail address: eldakley_s71@yahoo.com

ities. A complete necropsy of these birds was performed in order to determine the presence of helminths. The alimentary canal was dissected and separated into different parts; each section was placed in clean Petri dishes and examined under a dissecting microscope. The large trematodes were compressed between two slides; small trematodes and cestodes were compressed between two cover slips. The parasites were then fixed in 10% neutral buffered formalin, washed with distilled water, and stained with potassium alum carmine (5 min for small-sized helminths and up to 4 hours for large helminths). They were dehydrated in ascending grades of ethyl alcohol (70, 80, 90, 95, and 100%), cleared in xylene, and mounted with Canada balsam. Intact nematodes were cleared in lactophenol and mounted using a glycerol-jelly mixture onto clean glass slides (Abou Znada, 1993). Drawings were performed using a camera lucida, and available images are photographed using a digital microscope (Leica microsystems, CH-9435 Heebругg, Ec3, Singapore) (El-Dakhly et al., 2012).

Histopathological examination

Following the recovery of the parasites, exposed surfaces of oesophageal, gastric, and intestinal walls were processed according to the method outlined by Bancroft and Gamble (2008). Briefly, tissues from the oesophagus, stomach, and the small intestine were fixed in 10 % neutral buffered formalin and were routinely processed for paraffin embedding. Tissues were sectioned at 5 µm and stained with hematoxylin and eosin (HE) for microscopic examination.

Results

Necropsy of the three dead adult female great cormorants

revealed the presence of 3 digenean species; *Clinostomum complanatum* (Braun, 1899), *Ribeiroia ondatrae* (Beaver, 1939) and *Paryphostomum radiatum* (Dujardin, 1845) in the small intestine. Among them, *Paryphostomum radiatum* was found to be the most abundant, followed by *Clinostomum complanatum* and *Ribeiroia ondatrae* (Table 1).

Clinostomum complanatum (Digenea: Clinostomatidae) (Fig. 1)

The anterior portion of the oesophagi of three adult females *Phalacrocorax carbo* revealed a trematode with the following description: The body measured 2.4-3.0 x 0.58-0.69 cm, oral sucker (OS) 0.11-0.15 x 0.13-0.19 cm, ventral sucker (VS) 0.14-0.18 x 0.12-0.19 cm, oesophagus 0.29-0.36 mm, anterior testis (AT) 2.76-3.21 x 2.39-2.99 mm, posterior testis (PT) 1.89-2.32 x 2.11-2.73 mm, uterus 1.62-1.91 x 0.25-0.29 cm, ovary 1.02-1.22 x 0.39-0.51 mm, the distance between OS and VS was 0.14-0.18 cm, the distance between VS and uterus 0.021-0.031 cm, the distance between VS and AT 1.07-1.53 cm, the distance between AT and PT 1.49- 2.11 mm, the distance between the PT and the posterior body end 0.42-0.49 cm and the distance between the anterior body end and the anterior end of uterus 0.38-0.54 cm. The egg measured 0.91-0.12 x 0.05-0.069 mm. The recovered digenean was identified as *Clinostomum complanatum*.

Ribeiroia ondatrae (Digenea: Psilostomidae) (Fig. 2)

The median portion of esophagi of two adult females *Phalacrocorax carbo* had a digenean with the following measurements: The body measured 1.99-2.34 x 0.64-0.79 mm, OS 0.22-0.26 x 0.24-0.25 mm, VS 0.27-0.29 x 0.27-0.31 mm, phar-

Table 1. The intensity of both digenea and tapeworms recovered from necropsied great cormorants in Qena, Egypt

| Bird number | <i>Clinostomum Complanatum</i> | <i>Ribeiroia Ondatrae</i> | <i>Paryphostomum Radiatum</i> | <i>Paradilepsis scolecina</i> |
|--------------|--------------------------------|---------------------------|-------------------------------|-------------------------------|
| 1 | 10 | 8 | 42 | - |
| 2 | 13 | 11 | 35 | 44 |
| 3 | 9 | - | 51 | - |
| Total | 32 | 19 | 128 | 44 |

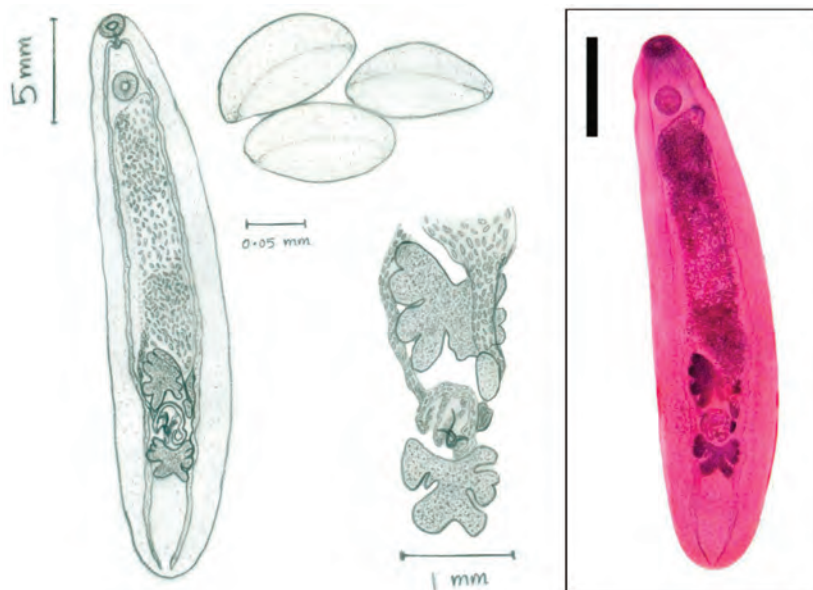


Fig. 1. Adult digenean, *Clinostomum complanatum*, recovered from necropsied cormorants, *Phalacrocorax carbo*. The right side showed a stained specimen with carmine (Scale bar = 5 mm). The left side revealed a diagrammatic view with camera lucida showing adult (Scale bar = 5 mm), gonads (Scale bar = 1 mm) and eggs (Scale bar = 0.05 mm).

ynx 0.20-0.23 mm, AT 0.19-0.22 x 0.26-0.30, PT 0.26-0.31 x 0.44-0.50 mm, ovary 0.19-0.2 x 0.11-0.12 mm, ootype 0.19-0.22 x 0.06-0.09 mm, the distance between OS and VS 0.63-0.69 mm, the distance between VS and AT 0.22-0.26 mm, the distance between AT and PT 0.022-0.031 mm, the distance between the PT and the posterior body end 0.21-0.27 mm. The egg measured 0.07-0.09 x 0.03-0.05 mm. The recovered digenean was identified as *Ribeiroia ondatrae*.

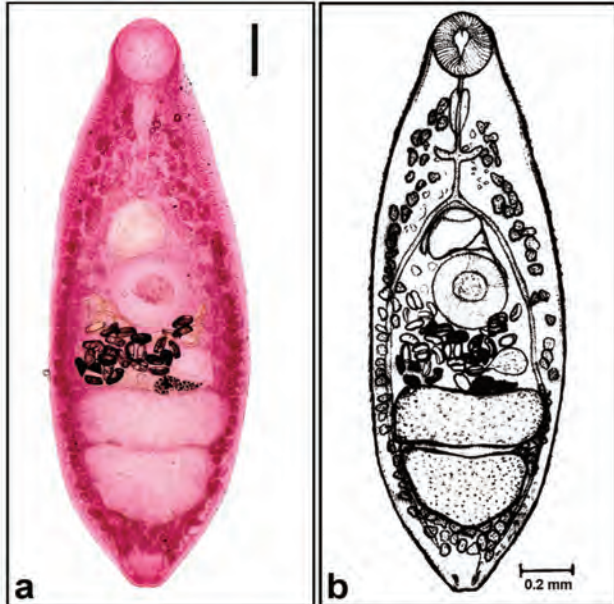


Fig. 2. Adult digenean, *Ribeiroia ondatrae*, recovered from necropsied cormorants, *Phalacrocorax carbo*. a) Carmine-stained specimen (Scale bar = 0.2 mm). b) A diagrammatic view of adult worm with camera lucida (Scale bar = 0.2 mm).

Paryphostomum radiatum (Digenea: Echinostomatidae) (Fig. 3)

The small intestine of three adult females *Phalacrocorax carbo* revealed a digenean trematode: The body measured 2.47-3.20 x 0.39-0.38 mm, OS 0.08-0.09 x 0.06-0.06 mm, oral cone 0.16-0.17 x 0.28-0.29 mm, head spine length 0.05-0.06 x 0.01-0.02 mm, VS length 0.32-0.35 x 0.29-0.32 mm, pharynx 0.29-0.32 mm in length, AT 0.19-0.21 x 0.19-0.21 mm, PT 0.21-0.27 x 0.17-0.20 mm, ovary 0.09-0.10 x 0.07-0.08 mm, ootype 0.15-0.17 x 0.11-0.13 mm, the distance between OS and VS 0.48-0.59 mm, the distance between VS and AT 0.60-0.64 mm, the distance between AT and PT 0.07-0.08 mm, and the distance between PT and the posterior body end 0.46-0.51 mm. The recovered digenean was identified as *Paryphostomum radiatum*.

The current study revealed that only one species of tapeworms, *Paradilepsis scolecina* (Rudolphi 1819) was found in the small intestine (Table 1).

Paradilepsis scolecina (Cestoda: Diplepididae) (Fig. 4)

The small intestine of an adult female *Phalacrocorax carbo*

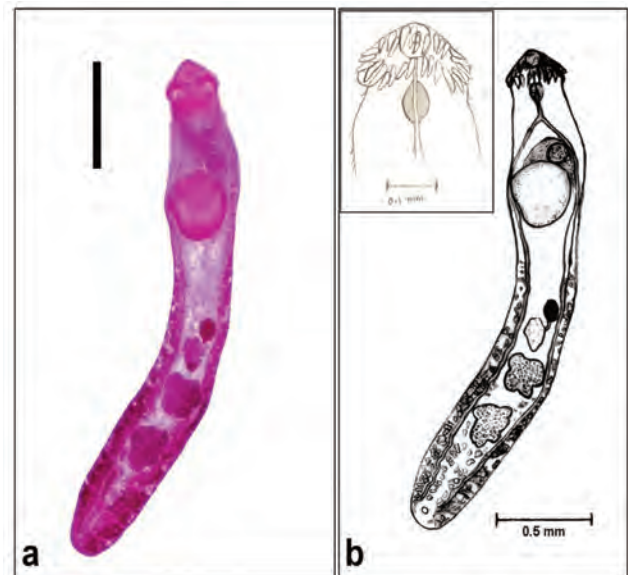

Fig. 3. Adult digenean, *Paryphostomum radiatum*, recovered from necropsied cormorants, *Phalacrocorax carbo*. a) Carmine-stained specimen (Scale bar = 0.5 mm). b) A diagrammatic view of adult worm with camera lucida (Scale bar = 0.5 mm). Inset: Spines of the head collar surrounding the oral sucker (Scale bar = 0.1 mm).

contained a tapeworm with the following dimensions: The body measured 1.2-1.4 x 0.17- 0.25 mm, scolex 0.35-0.36 x 0.31-0.36 mm, suckers 0.12-0.15 x 0.11-0.11 mm, the total length of a hook 0.10-0.12 mm, length of blade 0.06-0.06 and length of handle 0.04-0.05 mm.

Meanwhile, three nematode species belonging to genus *Contracaecum* (Railliet and Henry, 1912) were found in the stomachs of all necropsied birds; *Contracaecum rudolphii* (Hartwich, 1964), *Contracaecum microcephalum* (Yamaguti, 1961), *Contracaecum chubutensis* (Garbin, 2008) (Fig. 5). Among the recovered *Contracaecum* species, adult females were shown to be more abundant than males, except for *C. chubutensis* in the first bird (number of males exceeded that of females). *Contracaecum rudolphii* was determined to be the most predominant species, followed by *Contracaecum microcephalum* and *Contracaecum chubutensis* (Table 2).

Histopathologically, examination of different organs including the proventriculus, intestines, and the oesophagus was carried out. In the proventriculus, the presence of the digenean, *Ribeiroia ondatrae*, within the wall was associated with a moderate leucocytic infiltration and hyperplasia of the mucosal lining and proventricular glands could be detected (Fig. 6A). Moreover, the intestinal wall exhibited massive degenerative changes and necrosis of the intestinal mucosa. Severe mononuclear cell infiltration within the submucosa was possibly associated with embedded remnants of the parasite *Paryphostomum radiatum*. Furthermore, in some areas, incomplete fibrous connective tissue capsules surrounding the remnants of dead parasites were observed (Fig. 6B). No characteristic findings could be detected within the oesophageal wall.

Table 2. The intensity of recovered nematodes from necropsied great cormorants in Qena, Egypt.

| Bird number | <i>C. rudolphii</i> | | <i>C. microcephalum</i> | | <i>C. chubutensis</i> | |
|-------------|---------------------|----|-------------------------|----|-----------------------|---|
| | ♂ | ♀ | ♂ | ♀ | ♂ | ♀ |
| 1 | 5 | 11 | 4 | 13 | 6 | 3 |
| 2 | 8 | 12 | 5 | 13 | 7 | 8 |
| 3 | 9 | 18 | 4 | 9 | 5 | 5 |
| Total | 63 | | 48 | | 34 | |

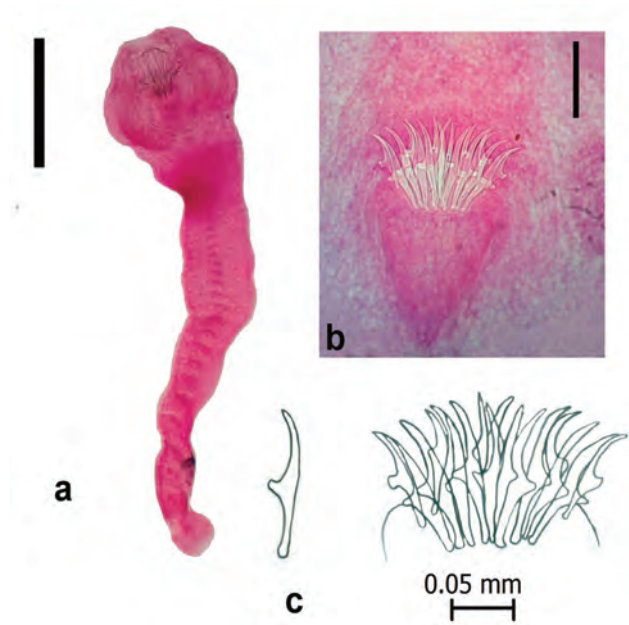


Fig. 4. Adult tapeworm, *Paradilepsis scolecina*, recovered from necropsied cormorants, *Phalacrocorax carbo*. a) Carmine-stained specimen (Scale bar = 250 µm). b) Magnified view of scolex (Scale bar = 0.1 mm). c) A diagrammatic view of hooks (Scale bar = 0.05 mm).

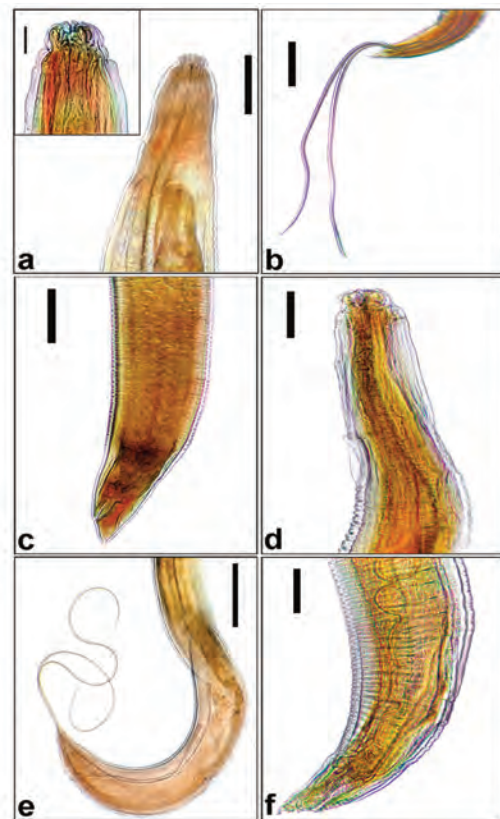


Fig. 5. Contracecum species recovered from necropsied cormorants, *Phalacrocorax carbo*. a) *Contracecum rudolphii* anterior end showing club-shaped oesophagus, intestinal caecum and ventricular appendix (Scale bar = 500 µm). Inset: Magnified view of lips showing distinct dorsal labium and subventral labia with their width is nearly similar to that of the collar area (Scale bar = 100 µm). b) *C. rudolphii* posterior end of male with spicules (Scale bar = 500 µm). c) *C. rudolphii* posterior end of female (Scale bar = 500 µm). d) *Contracecum microcephalum* anterior end (Scale bar = 200 µm). e) *C. microcephalum* posterior end of male (Scale bar = 1 mm). f) *Contracecum chubutensis* posterior end of male (Scale bar = 200 µm).

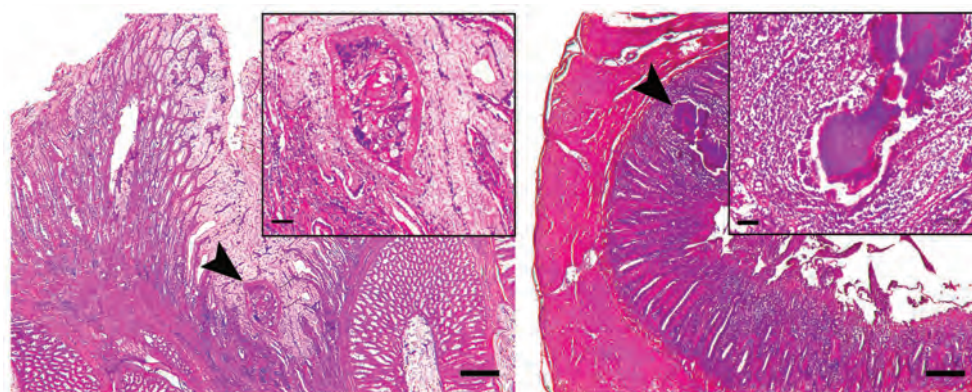


Fig. 6. Histopathology of the proventriculus and small intestine of the great cormorant, *Phalacrocorax carbo*, infected with trematodes. a) A cross section of the proventricular wall containing an adult digenean, *Ribeiroia ondatrae*, within the submucosal wall associated with leucocytic infiltration (Scale bar = 250 µm). Inset: Magnified part showing the adult trematode (Scale bar = 50 µm). b) A cross section of intestinal wall showing necrotic changes and severe mononuclear cell infiltration (Scale bar = 250 µm). Inset: Remnants of a digenean parasite, possibly, *Paryphostomum radiatum*, surrounded by incomplete fibrous connective tissues capsule (Scale bar = 50 µm).

Discussion

The great cormorant, *Phalacrocorax carbo*, is a common migratory bird species that feeds on various types of fish, particularly percids and cyprinids (Mellin and Krupa, 1997). Other fish species such as whitefish and pike are also included in the black cormorants' diet (Wziątek et al., 2007). *Phalacrocorax*

carbo has a significant impact on fresh water fish population, and consequently, the ecosystem, through the removal of parasite-infected individuals; the parasitic larvae found in these intermediate host fish develop in the gut of great cormorants (Barber, 2003; Dziekonska-Rynko et al., 2008).

In Egypt, scarce literature studied the helminth community in pelecyaniformes, particularly in cormorants. Among those,

Ibrahim (2006) investigated the presence of helminth in house sparrows, *Passer domesticus niloticus*, in Cairo; Wheeb et al. (2015) found helminth parasites infecting wild birds, cattle egrets (*Bubulcus ibis*), moorhens (*Gallinula chloropus*), migrant quail (*Coturnix coturnix*), king fisher (*Alcedo atthis*), and 8 house sparrow (*Passer domesticus*) in Edko District, Behira Province. None of helminth species recovered in the current study has been detected by these prior studies. Recently, Rzad and Busse (2015) revealed that the presence of the avian trematode, *Collyriclum faba* (Digenea: Collyriclidae), in migrant *Phylloscopus trochilus* (Aves: Sylviidae) for the first time in Egypt as well as on the African continent. Meanwhile, in nearby Asian countries such as Saudi Arabia, Mohamed et al. (2011) revealed that one nematode, *Heterakis gallinarum*, and two cestodes, *Choanotaenia infundibulum* and *Hymenolepis* sp. have infected the migratory quills, *Coturnix coturnix*. Al-Moussawi (2017) found 16 adult (8 males and 8 females) *Contraecaecum rudolphii* in the proventriculus of the great cormorant, *Phalacrocorax carbo*, in Baghdad, Iraq. The unique topography of Egypt, being situated at the center of the Africa, Asia, and Europe, allows for various migratory birds to travel through it between September-October, and again between March-April. In such circumstances, several migratory birds are exposed to parasitic helminths, as their main diet is fish, which are considered to be the predominant intermediate hosts (Wheeb et al., 2015).

Ribeiroia ondatrae has a complex life cycle, and the adults usually inhabit the gastrointestinal tract of both birds and mammals. Briefly, eggs are deposited within the feces of definitive hosts, which are then discharged to the environment. The larval growth occurs in planorbid snails (*Planorbella* and *Biomphalaria*), in which the digenean develops into large numbers of cercariae, which later encyst forming the next larval stage, the metacercariae, in amphibians such as frogs, tadpoles, salamanders, and fish. When the infected intermediate host is eaten by an appropriate definitive host, the metacercariae develop into adults (Taft et al., 1993; Schotthoefer et al., 2003). The presence of various water sources in Qena province encourages the inhabitation of different snails, frogs, lizards, and fish, which facilitates the completion of life cycle for *Ribeiroia ondatrae*. Similarly, *Clinostomum complanatum* is a widespread digenetic trematode found in piscivorous birds, with snails, frogs, fish, and snakes as intermediate hosts (Lemke et al., 2008; Abro et al., 2016). It was believed that the dead cormorants described in the current paper resided near fresh water sources in search of food, which allowed the parasites to complete their different developmental stages. Moreover, *Paryphostomum radiatum* is an intestinal digenean commonly found in great cormorants of Africa, Asia, Europe, and Australia; its intermediate hosts are snails and fish (Nasincova et al., 1993). Currently, there has been no report regarding *Ribeiroia ondatrae* and *Paryphostomum radiatum* in Egypt. The digenetic trematodes, *Clinostomum complanatum*, *Ribeiroia ondatrae*, and *Paryphostomum radiatum* were first described in the great cormorants, *Phalacrocorax carbo* (L. 1758), in Egypt.

Paradilepsis scolecina is a common tapeworm in fish-eating birds. The definitive hosts of this parasite are ichthyophagous birds, mostly the great cormorants (Scholz, 1989; Murai et al., 1996-97; Scholz et al., 2004). The main sources of infection by such cestodes are cyprinid fish which are preferable food sources for the great cormorants, although crustaceans serve as the first intermediate host (Dziekonska-Rynko and Dzika, 2011). In the present report, it has been found that infection occurs through the parasite larvae, plerocerci, in consumed cyprinid fish; parasitic infections are widespread along the Nile River and its associated lakes and ponds in Qena province.

In the present study, three adult female great cormorants were infected with three anisakid nematodes, *Contraecaecum rudolphii*, *C. microcephalum*, and *C. chubutensis*. The biology of *Contraecaecum* spp. in ichthyophagous birds is dependent on various environmental conditions as well as anthropogenic factors, which maximize the exposure of wildlife hosts to these environments (Friend, 1981; Pinto et al., 2004). *Contraecaecum rudolphii* is a common anisakid nematode worldwide, and is usually found in fish-eating birds (Huizinga, 1971; Kuiken et al., 1999; Nottenkämper et al., 1999; Abollo et al., 2001; Torres et al., 2005; Amato et al., 2006). Moreover, *Contraecaecum microcephalum* is cosmopolitan in the great cormorants, but is not as common as *C. rudolphii* (Anderson, 1992; El-Dakhly et al., 2012). This study discussed the incident where dead cormorants were found near the Nile River, Qena, strongly suggested that the various fresh water fish species consumed by these birds enabled *Contraecaecum* spp. to develop and complete their life cycles. The present study revealed no *C. multipapillatum*. This finding could be explained on the basis that in some anisakid infections, such as those by *C. multipapillatum*, adult nematodes are captured in tubular fibrous lesions due to contacting of the nematode with the gastric lumen. This hinders the oviposition, and so eggs could not be seen via coprological examination (Pinto et al., 2004). Malacalza et al. (1994) referred the variation in the mean intensity of *Contraecaecum* spp. in great cormorants is dependent on the regurgitation habit of those birds. This phenomenon might be a depuration mechanism, since a large number of high parasites were recovered in regurgitated pellets.

Histopathological examination of the great cormorants revealed leucocytic infiltration surrounding the embedded parasites in the proventricular wall, along with necrotic changes and mononuclear cells infiltration associated with degenerated trematodes in the intestinal wall. Moreover, the presence of *Contraecaecum* spp., either attached to the proventricular wall or free in the lumen, leads to destruction of the proventricular wall due to burrowing of anisakids, regardless of their parasitic stage. This occurs as the parasite fix itself against the abrasive movement of the bony structure of the ingested fish as it travels from the proventriculus to the intestine. As a result, most lesions and mucosal destruction occurs in the proventricular mucosa during *Contraecaecum* spp. infections (Huizinga, 1971; Fagerholm et al., 1996; Abollo et al., 2001). Progressively, in the absence of food, anisakid nematodes may invade the entire epithelial lining of the bird gut (Huizinga, 1971). Accordingly, a high mortality of cormorants might occur.

Conclusion

To the best of authors' knowledge, this is the first report studying helminthiasis in the great cormorants, *Phalacrocorax carbo* (L. 1758), in Upper Egypt. Description of three digenetic trematodes, *Clinostomum complanatum*, *Ribeiroia ondatrae*, *Paryphostomum radiatum*, was first mentioned in such birds in Egypt. Moreover, authors believed that the tapeworm, *Paradilepsis scolecina*, was first recorded in Egypt. Meanwhile, 3 anisakid nematodes, *Contraecaecum rudolphii*, *Contraecaecum microcephalum*, and *Contraecaecum chubutensis* were not yet recorded in the great cormorants in Egypt.

References

- Abollo, E., Gestal, C., Pascual, S. 2001. Anisakid infection in the European shag *Phalacrocorax aristotelis aristotelis*. *Journal of Helminthology* 75, 209-214.
- Abou Znada, N.Y., 1993. First record and prevalence of the caecal nematodes, *Heterakis gallinarum* and *Subulura suctorica* from the Guinea Fowl, *Numedia meliagraris*, in Saudi Arabia. *Journal of*

- King Saud University 5, 59-65.
- Abro, M.M., Dharejo, A.M., Khan, M.M., Birmani, N.A. 2016. First record of *Clinostomum complanatum* (Trematodes: Clinostomatidae) in Pakistan from *Phalacrocorax niger* (Aves: Phalacrocoracidae). *Biological Forum* 8, 479-483.
- Al-Moussawi, A.A., 2017. Insights at morphological features of *Contraeaecum rudolphii* Hartwich, 1964 (Nematoda: Anisakidae) as revealed by scanning electron microscope (SEM). *Journal of Entomology and Zoological Studies* 5, 116-119.
- Amato, J.F.S., Monteiro, C.M., Amato, S.B. 2006. *Contraeaecum rudolphii* Hartwich (Nematoda, Anisakidae) from the Neotropical cormorant, *Phalacrocorax brasilianus* (Gmelin) (Aves, Phalacrocoracidae) in southern Brazil. *Revista Brasileira de Zoologia* 23, 1284-1289.
- Amundson, C.L., Traub, N.J., Smith-Herron, A.J., Flint, P.L. 2016. Helminth community structure in two species of arctic-breeding waterfowl. *International Journal of Parasitology: Parasites and Wildlife* 5, 263-272.
- Anderson, R.C., 1992. Nematode parasites of vertebrates: their development and transmission. Oxford, CAB International.
- Bancroft, J.D., Gamble, M. 2008. *Theory and Practice of Histological Techniques*, 6th edn. Churchill Livingstone Elsevier, Philadelphia, PA.
- Barber, I., 2003. The role of parasites in fish-bird interactions: a behavioural ecological perspective. In: *Interactions between Fish and Birds: Implications for Management*, eds. Cowx I.G., Fishing News Books, Blackwell Science Ltd., Oxford, pp. 221-243.
- Beaver, P.C., 1939. The morphology and life history of *Psilostomum ondatrae* Price, 1931 (Trematoda: Psilostomidae). *Journal of Parasitology* 25, 383-393.
- Dziekonska-Rynko, J., Dzika, E., 2011. The tapeworm *Paradilepis scolecina* (Rudolphi, 1819) (Cestoda: Cyclophyllidae) invasion in Great Cormorant [*Phalacrocorax carbo sinensis* (Blumenbach, 1798)] from the breeding colony in Lake Selment Wielki (northern Poland). *Helminthologia* 48, 23-28.
- Dziekonska-Rynko, J., Rokicki, J., 2008. Infestation of the black cormorants (*Phalacrocorax carbo* L., 1758) from the colony on the Selment Wielki, with the nematode *Contraeaecum rudolphii* Hartwich, 1964 (Nematoda, Anisakidae). *Oceanological and Hydrobiological Studies* 37, 61-71.
- El-Dakhly, Kh. M., El-Nahass, E., Uni, S., Tuji, H., Sakai, H., Yanai, T., 2012. Levels of infection of gastric nematodes in a flock of great cormorants (*Phalacrocorax carbo*) from Lake Biwa, Japan. *Journal of Helminthology* 86, 54-63.
- Fagerholm, H.P., Overstreet, R.M., Humphrey-Smith, I., 1996. *Contraeaecum magnipapillatum* (Nematoda, Ascaroidoidea): Resurrection and pathogenic effect of a common parasite from the proventriculus of *Anous minutus* from the Great Barrier Reef, with a note on *C. variegatum*. *Helminthologia* 33, 195-207.
- Friend, M., 1981. Waterfowl management and waterfowl disease: independent or cause and effect relationships? *Transactions of the North American Wildlife Natural Resources Conference* 46, 94-103.
- Garbin, L.E., Diaz, J.I., Cremonte, F., Navone, G.T., 2008. New anisakid species parasitizing the imperial cormorant *Phalacrocorax atriceps* from the North Patagonian Coast, Argentina. *Journal of Parasitology* 94, 852-859.
- Hartwich, G., 1964. Revision der vogelparasitischen nematoden mitteleuropas, II. Di Gattung Contraeaecum Railliet and Henry, 1912. *Mitteilungen aus dem Zoologisches Museum Berlin* 40, 15-53.
- Hoberg, E.P., Polley, L., Jenkins, E.J., Kutz, S.J., Veitch, A., Elkin, B., 2008. Integrated approaches and empirical models for investigation of parasitic diseases in northern wildlife. *Emerging Infectious Diseases* 14, 10-17.
- Huizinga, H.W., 1971. Contraeaeciasis in pelicanform bird. *Journal of Wildlife Diseases* 7, 198-204.
- Ibrahim, O.A., 2006. Study on some parasites affecting sparrows, Passer domesticus niloticus, in Cairo Governorate, Egypt. *Assiut Veterinary Medical Journal* 52, 224-234.
- Koprivnikar, J., Leung, T.L.F., 2015. Flying with diverse passengers: greater richness of parasitic nematodes in migratory birds. *Oikos* 124, 399-405.
- Kuiken, T., Leighton, F.A., Wobeser, G., Wagner, B., 1999. Causes of morbidity and mortality and their effect on reproductive success in double-crested cormorants from Saskatchewan. *Journal of Wildlife Diseases* 35, 331-346.
- Lemke, L.B., Dronen, N., Fox, J.G., Nambiar, P.R., 2008. Infestation of wild caught American bullfrogs (*Rana catesbeiana*) by multiple species of metazoan parasites. *Journal of American Association for Laboratory Animal Science* 47, 42-46.
- Malacalza, V., Poretti, T.I., Bertelotti, M., 1994. La dieta de Phalacrocorax albiventer en Punta Leon (Chubut, Argentina) durante la temporada reproductiva. *Ornitologia Neotropical* 5, 91-97.
- Martyniak, A., Terlecki, J., Boroń, S., Hliwa, P., Szamańska, U., Gabryś, B., Romaniewicz, A. 1997. Diet composition of cormorants *Phalacrocorax carbo sinensis* from pellets collected at Katy Rybackie colony, northern Poland. *Ricerche di Biologia della Selvaggina Supplement* 26, 505-510.
- Mellin, M., Krupa, R., 1997. Diet of cormorant, based on the analysis of pellets from breeding colonies in NE Poland. *Ricerche di Biologia della Selvaggina Supplement* 26, 511-515.
- Mohamed, S.H., Ghobashy, M.A., Al-Zailae, H.A., 2011. Levels of helminthic infections in the quails *Coturnix coturnix* from Kingdom of Saudi Arabia. *Journal of Egyptian Society of Parasitology* 41, 397-407.
- Moravec, F., Scholz, T., 2016. Helminth parasites of the lesser great cormorant *Phalacrocorax carbo sinensis* from two nesting regions in the Czech Republic. *Folia Parasitologica* 63: 022. doi: 10.14411/fp.2016.022.
- Murai, E., Molnar, K., Gubanyi, A., 1996-97. Occurrence of the plerocercus forms of the *Paradilepis scolecina* (Rudolphi, 1819) (Cestoda: Dilepididae) in Lake Balaton, Hungary. *Parasitologia Hungarica* 29-30, 33-38.
- Nasincova, V., Scholz, T., Moravec, F., 1993. The life cycle of *Paryphostomum radiatum* (Dujardin 1845) (Trematoda: Echinostomidae), a parasite of cormorants. *Folia Parasitologica* 40, 193-201.
- Nottenkämper, D., Korbel, R., Kösters, J., 1999. The infection of great cormorants *Phalacrocorax carbo sinensis* L. 1758) with *Contraeaecum rudolphii* (Nematoda: Ascaridoidea) in the district of Upper Bavaria (Germany) and the canton St. Gallen (Switzerland). *Tierärztliche Praxis Kleintiere* 4, 27.
- Pinto, R.M., Barros, L.A., Tortelly, L., Teixeira, R.F., Gomes, D.C., 2004. Prevalence and pathology of ciconiiform birds from the Brazilian swamplands. *Journal of Helminthology* 78, 259-264.
- Prejs, A., 1978. Lakes eutrofisation and the ichtiofauna. *Wiadomosci Ekologiczne* 24, 201-208.
- Railliet, A., Henry, A., 1912. Quelques nematodes parasites des reptiles. *Bulletin de la Societe de Pathologie Exotique* 5: 251-259.
- Rzad, I., Busse, P., 2015. *Collyriclum faba* (Digenea: Collyriclidae) in migrant *Phylloscopus trochilus* (Aves: Sylviidae) in Egypt: the first record of the parasite on the African continent. *Turkish Journal of Zoology* 39, 359-364.
- Scholz, T., 1989. First record of the larvae of *Paradilepis scolecina* (Rudolphi, 1819) (Cyclophyllidae: Dilepididae) in fishes from Czechoslovakia. *Folia Parasitologica* 36, 65-66.
- Scholz, T., Bray, R.A., Kuchta, R., Řepova, R., 2004. Larvae of grypohynchid cestodes (Cyclophyllidae) from fish: a review. *Folia Parasitologica* 51, 131-152.
- Schotthoefer, A.M., Koehler, A.V., Meteyer, C.U., Cole, R.A., 2003. Influence of *Ribeiroia ondatrae* (Trematoda: Digenea) infection on limb development and survival of northern leopard frogs (*Rana pipiens*): effects of host stage and parasite-exposure level. *Canadian Journal of Zoology* 81, 1144-1153.
- Taft, S.J., Suchow, K., VanHorn, M., 1993. Helminths from some Minnesota and Wisconsin raptors. *Journal of Helminthological Society of Washington* 60, 260-263.
- Torres, P., Ortega, J., Schlatter, R., 2005. Nematode parasites of the digestive tract in Neotropical cormorant chicks (*Phalacrocorax brasilianus*) from the River Cruces Ramsar site in southern Chile. *Parasitology Research* 97, 103-107.
- Wheeb, H.S., Bazh, E.K., Aborwash, A., Ellakany, H., 2015. Some Helminthes Parasites Infecting Wild Birds at Edko, Behira Province, Egypt. *Alexandria Journal of Veterinary Science* 47, 65-70.
- Wziątek, B., Martyniak, A., Hliwa, P., Kozłowski, J., Krzywosz, T., Osowski, M., Sobocki, M., Szymanska, U., Gomulka, P., 2007. Great cormorant predation on coregonid fishes at sites in Poland. *Advances in Limnology* 60, 285-297.
- Yamaguti, S., 1961. *Systema Helminthum*. Vol. III. The nematodes of vertebrates. Part 1 N.Y. Interscience Publications.