

## Investigation of *Theileria camelensis* in camels infested by *Hyalomma dromedarii* ticks in Upper Egypt

Maha I. Hamed\*, Ahmed M.A. Zaitoun, Taha A.A. El-Allawy, Mourad I. Mourad

Department of Animal Medicine, Faculty of Veterinary Medicine, Assiut University, Assiut 71526, Egypt.

(Received 28 March 2011/ Accepted 5 April 2011)

### Abstract

In the present study, a total of 224 camels infested with *Hyalomma dromedarii* ticks were investigated for the presence of *Theileria camelensis* infection in Upper Egypt. The role of *Hyalomma dromedarii* ticks as the vector of this parasite was also investigated by haemolymph smear examination. Results revealed that 15 (6.75%) of 224 camels were harboring *Theileria camelensis* in erythrocytes. Furthermore, the theilerial schizont was also seen in lymphocytes. These 15 camels did not show any abnormal clinical signs except three cases that showed enlargement of superficial lymph node and fever. Examination of ticks showed various developmental stages of different shapes and forms of *Theileria* species.

**Keywords:** *Theileria camelensis*; *Hyalomma dromedarii*; Camels; Ticks; Upper Egypt

### Introduction

*Theileria camelensis* is an intra-erythrocytic protozoan parasite infecting camels, its presumed vector is *Hyalomma dromedarii*. The parasite forms in the erythrocytes were predominantly rod shaped and no schizonts were detected in the prescapular lymph node impression smears as reported by Nasser (1992). The predominant clinical findings of camels infected with theileria are fever, ocular watery discharge, severe emaciation, diarrhea in the form of intermittent bouts, in addition to the systemic signs, enlargement of superficial lymph nodes were also noticed (El-Fayoumy *et al.*, 2005). On the other hand, camels may be apparently healthy in spite of theilerial infection (Boyd *et al.*, 1985).

Yakimoff *et al.* (1917) gave the name *Theileria camelensis* provisionally to round erythrocytic organisms from three camels in Russia and Turkestan. *Hyalomma dromedarii* plays an important role in transmission of *Theileria camelensis* in vertebrates (Hoogstraal, 1956, Abd El-Baky, 2001).

Examination of *Hyalomma dromedarii* gut smears by El-Refaii *et al.* (1998), revealed the presence of various developmental stages of different

shapes and forms of *Theileria camelensis*. These developmental stages were in the form of ring form, slender spine-like form, an elongated structure or round form measuring 3.75  $\mu\text{m}$  in diameter, and enclosing centrally located nucleus surrounded by a cloud-like dispersed cytoplasm.

### Materials and methods

#### *Examination of camels*

Camels were clinically inspected for the presence of ticks according to Köhler-Rollefson *et al.* (2001) and the infested cases were subjected to detailed clinical examination and samples collection. Abnormal clinical findings were recorded. Blood samples were collected from 224 ticks infested camels into clean and dry sterile tubes containing Ethylene Diamine Tetra-acetic Acid (EDTA) as an anticoagulant. These samples were used for preparation of blood films. Thin blood films from each camel were prepared and stained with Giemsa stain and examined microscopically for presence of *Theileria camelensis*.

#### *Examination of ticks*

A total of 1967 ticks (452 engorged female, 1090 male and 425 nymph) were collected (with an av-

\*Corresponding author: Maha I. Hamed

Address: Department of Animal Medicine, Faculty of Veterinary Medicine, Assiut University, Assiut 71526, Egypt.

erage of 8.78 tick/case) from 224 infested camels. Identification was done according to standard keys (Hoogstraal et al., 1981). Haemolymph smears and midgut contents of each tick were examined for *Theileria camelensis*. Smears were air dried, fixed in methanol, stained with Giemsa (1:10), washed in tap water and upright air dried and then examined microscopically according to Burgdorfer (1970).

## Results

Camels infected with *Theileria camelensis* did not show any abnormal clinical signs except in three cases, that showed fever and enlargement of lymph nodes, especially superficial cervical lymph nodes (Fig. 1).

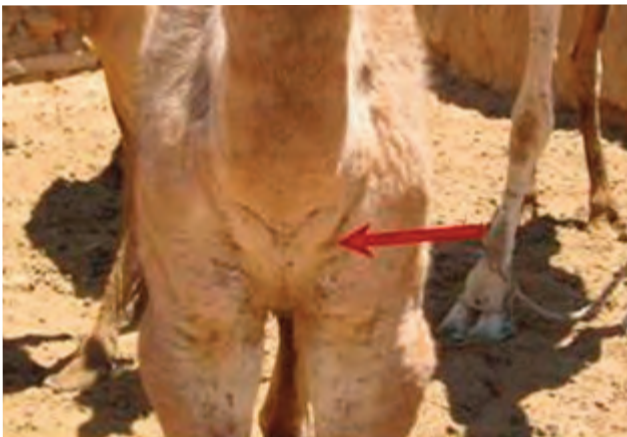

Fig. 1. Bilateral enlargement of superficial cervical lymph nodes in a camel-calve.

Of the 224 tick infested camels, 15 (6.75%) of them were positive for *Theileria camelensis* in their circulating red blood corpuscles. The erythrocytic form of *Theileria camelensis* were rod, rounded and ring shaped. The theilerial schizont was also seen in lymphocytes (Fig. 2).

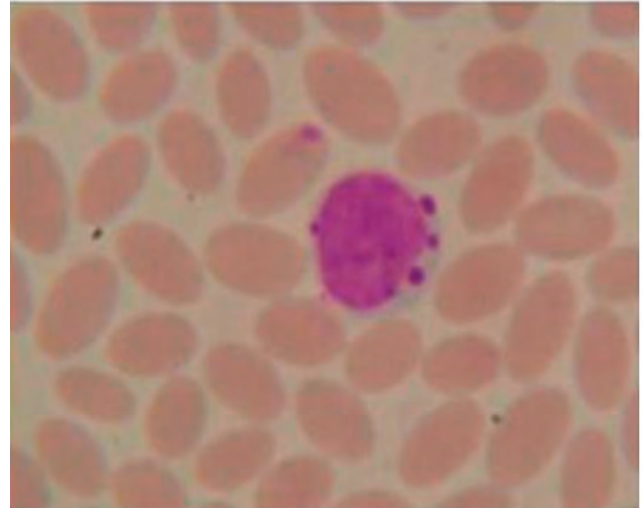


Fig. 2. Blood film from infested camels stained by Giemsa stain showing schizont of *Theileria camelensis* in lymphocytes. (X100)

Regarding hemolymph examination, it was noticed that 21 (9.38%) of 224 infested camels showed various developmental stages of different shapes and forms of *Theileria* species in their infesting ticks (Fig. 3).

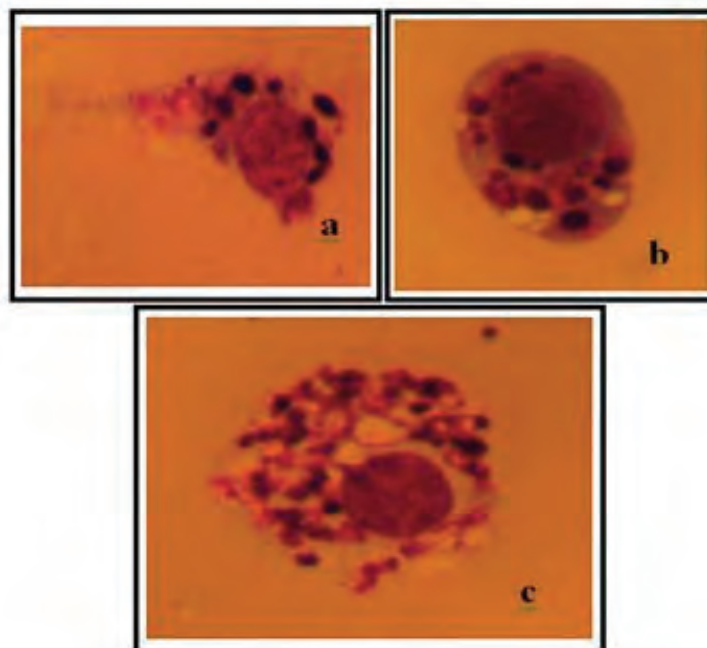


Fig. 3. Haemolymph smear from ticks showing various developmental stages of *Theileria* species. a) Slender spine-like form, b) Elongated or oval structure, c) Round form with centrally located nucleus surrounded by a cloud-like dispersed cytoplasm. (X100).

## Discussion

Pathogenic protozoa belonging to the order Piroplasmida include Babesia species and Theileria species are common pathogens transmitted by ticks and are of significant importance in many domestic animals, including camels (Wernery and Kaaden, 1995).

Theileriosis is considered to be the second most important hemoprotozoal disease following trypanosomiasis affecting dromedary camels in tropical and subtropical countries (Gatt-Rutter, 1967, Mishra et al., 1987, Nassar, 1992, El-Refaii et al., 1998, Mazyad and Khalaf, 2002) and there are different types of Theileria species implicated as etiologic agents of the disease. However, *Theileria camelensis* appears to be the principal cause of camel theileriosis particularly in Egypt (Gatt-Rutter, 1967, Barnett, 1977, Boid et al., 1985, Mishra et al., 1987, El-Fayoumy et al., 2005).

The current work indicated that 6.75 % (15 of 224) of the examined camels were harboring the erythrocytic forms of *Theileria camelensis* and most of the positive cases had no apparent characteristic clinical signs. This may be attributed to the chronic nature of Theileria infection and/or to the investigated *Theileria camelensis* was probably apathogenic (Boid et al., 1985). Nassar (1992) examined 200 apparently healthy camels under Egyptian field conditions and found that 30% of them were infected with *Theileria camelensis*. This may indicate that theileriosis in camels is symptomless infection. However, there were three (3 of 15, 20%) camels in the present study with characteristic enlargement of the lymph nodes, in particular, the superficial cervical nodes, in association with systemic reaction in the form of fever, polypnea and tachycardia. These infected cases were young (3-6 months of age) and might be under stresses because they were debilitated. Similar clinical signs of theilerial infection in one-humped camels were previously reported by El-Fayoumy et al. (2005).

The prevalence rate of Theileria infection in one-humped camel reported by Nassar (1992), El-Refaii et al. (1998), El-Fayoumy et al. (2005) were 30 % (60 of 200), 62.1 % (46 of 74) and 44.8 % (56 of 125) respectively, which are lower than that reported by the present study. Such variations may ascribe to several reasons, including different localities, population density of camels, environment and hygienic measures. Moreover, the ecological

and climatic factors of Upper Egypt, where the climatic condition is continental in nature, may play a pivotal role. Furthermore, the sharply pendulous changes in the desert environment have a strong effect on the prevalence of various hemoprotozoal infections of small ruminants and camels (Bahy et al., 2008).

*Hyalomma dromedarii* is the principal vector in transmission of *Theileria camelensis* in vertebrates (Hoogstraal, 1956). Theileria has various developmental stages of different shapes and forms inside the vector (ticks). These forms were observed in the haemolymph and gut smears as ring form, slender spine-like form, an elongated structure, round form, and enclosing centrally located nucleus surrounded by a cloud-like dispersed cytoplasm (Fig. 3), the same was reported by El-Refaii et al. (1998). On the current study, developmental stages of Theileria species were found in 9.38% (21 of 224) of the examined hemolymphs of ticks. These results further confirm the important role of tick (*Hyalomma dromedarii*) as a vector for Theileria infection among camel population in Upper Egypt.

## References

- Abd El-Baky, S.M.M., 2001. Prevalence of external parasites in the south eastern desert of Egypt. Journal of the Egyptian Society of Parasitology 31, 223-232.
- Bahy, M.M., Omer, O.H., Al-Sadrani, A.A., 2008. Temperature difference and parasitic infection at Qassim region, Saudi Arabia. Research Journal of Parasitology 3, 114-122.
- Barnett, S.F., 1977. Theileria. In: Kreier, J. P., ed. Parasitic Protozoa. Vol. 4. Academic Press, New York.
- Boid, R., Jones, T.W., Luckins, A.G., 1985. Protozoal Diseases of Camels. British Veterinary Journal 141, 87-105.
- Burgdorfer, W., 1970. Hemolymph test. A technique for detection of rickettsiae in ticks. American Journal of Tropical Medicine and Hygiene 19, 1010-4.
- El-Fayoumy, M.M., Abou Elnga, T.R., Abd El-Baky, S.M.M., Abdou, T.A., 2005. Prevalence and of camel theileriosis and its vector tick in North Coast of Egypt. Journal of the Egyptian Veterinary Medical Association 65, 291-302.
- El-Refaii, M.A.H., Wahba, A.A., Shehab, G.J., 1998. Studies of theileria infection among slaughtered camels in Egypt. The Egyptian Journal of Medical Science 19, 1-17.
- Gatt-Rutter, T.E., 1967. Protozoal diseases of camel. Veterinary Bulletin 37, 611-618.
- Hoogstraal, H., 1956. Notes on African Haemaphysalis ticks. III. The hyrax parasites, H. bequaerti sp. nov., H. orientalis N. and W., 1915 (new combination), and H. cooleyi Bedford, 1929 (Ixodoidea, Ixodidae). Jour-

- nal of Parasitology 42,156-172.
- Hoogstraal, H., Wassef, H.Y., Buttiker, W., 1981. (Acarina) of Saudi Arabia, Fam. Argasidae and Ixodidae. Fauna of Saudi Arabia 3, 25-110.
- Köhler–Rollefson, Paul Mundy, Evelyn Mathias, 2001. Skin Problems. In: A Field Manual of Camel Diseases. Traditional and modern health care for the dromedary. ITDG Publishing, pp. 69-98.
- Mazyad, S.A., Khalaf, S.A.A., 2002. Studies of theileria and babesia infecting live and slaughtered animals in Al Arish and El Hasanah, North Sinai Governorate, Egypt. Journal of the Egyptian Society of Parasitology 32, 601-610.
- Mishra, A.K., Sharma, N.N., Raghavendra Rao, J., 1987. Theileria dromedarii N.SP. from Indian camels (Camelus dromedarius). Rivista Di Parassitologia 4, 99-102.
- Nassar, A.M., 1992. Theileria infection in camels (*Camelus dromedarius*) in Egypt. Veterinary Parasitology 43, 147-149.
- Wernery, U., Kaaden, O.R., 1995. Infectious Diseases of Camelids. Blackwell Wissen-schafts-Verlag. Berlin.
- Yakimoff, W.L., Schokhor, N.I., Kosel-Kine, P.M., 1917. In Maladies animals du Turkestan russe a parasites endoglobulaires. Bulletin of the Exotic Pathology Society. 10, 303-305. Cited by Gatt-Rutter, T.E., 1967. Protozoal Diseases of Camel. Veterinary Bulletin 37, 611-618.