

Mammary Neoplasm in a Male Dog - A Case Report

Veena P., Kokila S.*, Sankar P., Suresh kumar R.V., Dhanalakshmi N., Ch. Srilatha

Department of Veterinary Surgery and Radiology, College of Veterinary Science, Sri Venkateswara Veterinary University, Tirupati-517 502 (AP), India

(Received 16 November 2011/ Accepted 20 April 2012)

Introduction

Mammary neoplasms represent an important health problem in companion animals. Mammary neoplasms occurred almost exclusively in female dogs. The risk in male dogs is 1% or less of that in bitches. Jabara (1960) listed 22 cases of mammary growths in male dogs. Moulton *et al.* (1970) based on a study of 1366 cases of canine mammary neoplasms, observed that approximately 2% of them were males.

Case history and observation

A 9 year old sexually intact male German Shephard dog was brought to the college clinics, Department of Veterinary Surgery and Radiology, College of Veterinary Science, Sri Venkateswara Veterinary University, Tirupati with a history of growth on left side 3rd and 5th mammary gland since 2 months (Fig. 1), inappetance, dullness, lethargy, polydipsia and weight loss since one week. Body temperature, pulse rate and heart rate were within normal range while examination. On physical examination the mass was about 2 cm diameter, soft on palpation and cystic. Fine needle aspiration cytology revealed malignant cells. Laboratory examination revealed leukocytosis characterized by neutrophilia. Radiography revealed no metastatic lesions in thorax.

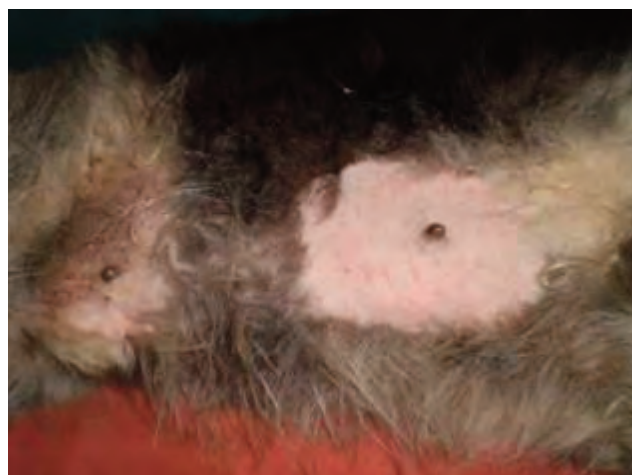


Fig.1. Growth on left 3rd and 5th mammary gland

Surgical treatment:

The animal was premedicated and sedated using Atropine and Xylazine at 0.04mg/kg and 1mg/kg b wt respectively by intramuscular route. General anaesthesia was induced and maintained with Ketamine and Diazepam at 10mg/kg and 0.5mg/ kg b wt respectively by intravenous route. Surgery was performed under standard techniques. Tumor mass was excised (Fig. 2) as per the standard procedure and the mass was subjected to histopathological examination.

Histopathological examination revealed numerous proliferating acini and ducts. Most of the acini and ducts were cystic and revealed papillary form processes lined by cuboidal or columnar epithelium. The tumor was diagnosed as papillary cyst adenoma (Fig. 3 and 4).

*Corresponding author: Kokila S.

E-mail address: gopika31@gmail.com

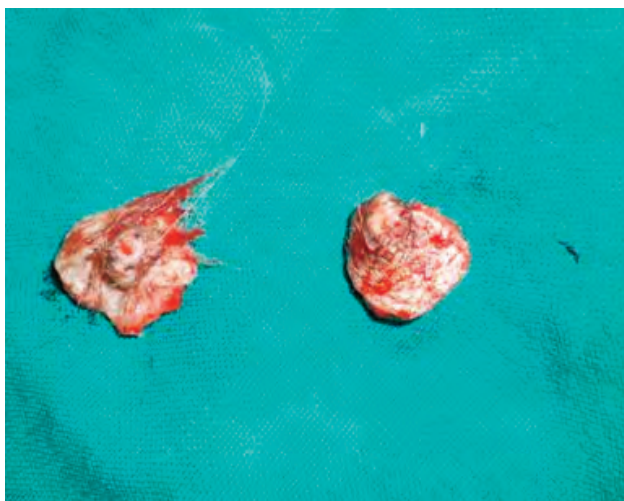


Fig. 2. Showing surgically resected mass)

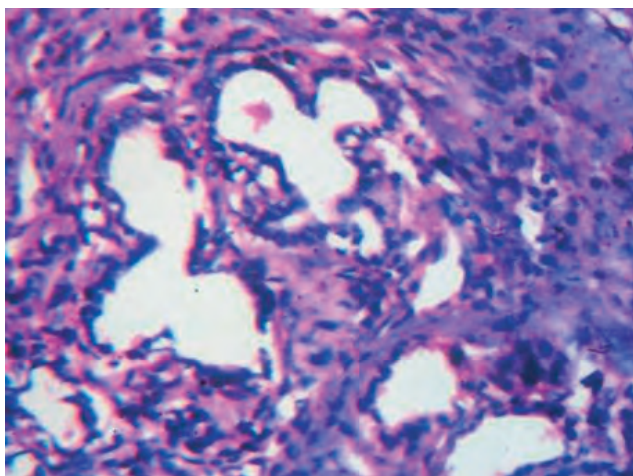


Fig. 3. Note irregular acinar structures with cystic dilatation and infiltration of neutrophils.

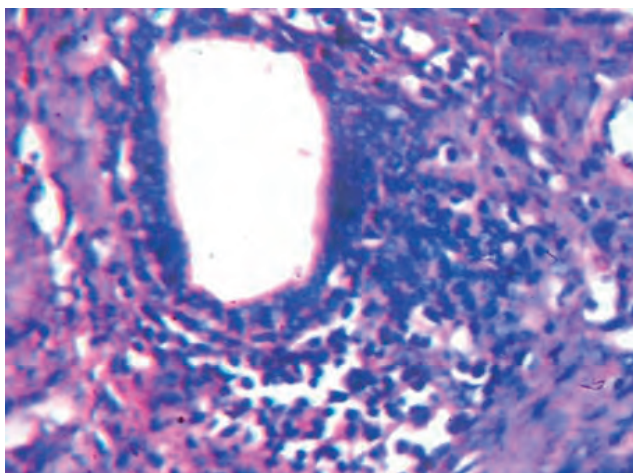


Fig. 4. Note dilated glandular structures and proliferated cells giving papillary projection and infiltration of neutrophils.

literature were associated with a feminizing testicular tumor (Jabara, 1960). Walker (1968) considered that the mammary growths were oestrogenically induced. In this case no symptom of feminization was noticed clinically. Saba (2007) stated that the mammary gland tumors in male dogs are rare, usually benign, and surgery alone can provide long-term control in most dogs. The animal was recovered uneventfully, and no recurrence was noticed upto 1 year.

References

- Jabara, A.G., 1960. Canine mixed tumours. *Australian Veterinary Journal* 36, 212.
- Moulton, J.E., DON Dorn, C.R., Anderson, A.C., 1970. Canine mammary tumor. *Veterinary Pathology* 7, 289-320.
- Walker, D., 1968. Mammary Adenomas in a Male Dog-Probable Oestrogenic Neoplasms. *Journal of Small Animal Practice* 9, 15.
- Saba, C.F., Rogers, K.S., Newman, S.J., Mauldin, G.E. Vail, D.M., 2007 Mammary gland tumors in male dogs. *Journal of Veterinary Internal Medicine* 21, 1056-1059.

Discussion

Jabara (1960) stated that there was no particular breed susceptibility for the development of mammary tumors in male dogs. Several cases of mammary neoplasms in male dogs reported in the