

**$\alpha$ -SMA and Ki-67 Immunohistochemistry as Indicators for the Fibrotic Remodeling Process in the Liver of Dogs**S. Neumann<sup>1\*</sup>, F.J. Kaup<sup>2</sup><sup>1</sup>Small Animal Clinic, Institute of Veterinary Medicine, University of Gottingen, Burckhardtweg 2, D-37077 Gottingen<sup>2</sup>German Primate Center, Pathology Unit, Kellnerweg 4, D-37077 Gottingen

(Received 11 August 2011/ Accepted 18 December 2011)

**Abstract**

Liver cirrhosis is a fatal end-stage of various chronic liver diseases. It develops from persistent liver cell necrosis with resulting fibrosis. Because liver cirrhosis is an irreversible process it is important to recognize the reversible fibrotic stages of the disease. Different markers and staining are currently used to detect fibrosis. Besides plasma markers, some tissue markers are currently being used for this purpose. In this study, we investigated the expression of two immunohistochemical markers (Ki-67,  $\alpha$ -SMA) in liver diseases with and without fibrosis in dogs and compared their expression with the degree of tissue fibrosis, assessed by Masson trichrome staining. In all the stages of fibrosis, Ki-67 and  $\alpha$ -SMA was expressed in the liver tissue. There was no significant difference between Masson trichrome staining which is "gold standard" and expression of Ki-67 or  $\alpha$ -smooth muscle actin (SMA). We concluded that Ki-67 and  $\alpha$ -SMA can be potentially used as markers for the fibrotic remodeling of the liver.

**Keywords:** Dog; Ki-67; Liver fibrosis; Smooth muscle actin.

**Introduction**

Hepatic fibrosis is indicated by an accumulation of connective tissue molecules, mainly collagen, in the extracellular matrix. The etiology of fibrosis includes chronic injuries of various types. Advanced fibrosis develops into hepatic cirrhosis, which is an irreversible process with profound changes in the organ architecture (Wasmuth and Weiskirchen, 2010). Since liver fibrosis is potentially reversible, markers for its detection are essential to identify any early alterations in the liver tissue. Besides connective tissue staining like Masson trichrome stain, immunohistochemistry markers could also be of interest as they are useful in detecting molecular changes and cell activation during the fibrotic process. This may make an early diagnosis possible.

In order to establish novel immunohistochemistry markers for liver fibrosis it is important to consider the pathogenesis of liver fibrosis. Hepatic fibrosis is induced by chronic stimuli, which activate Ito cells in the peri-sinusoidal space. Under

physiological conditions Ito cells serve as storage cells for fat and vitamin A and are found in the sub-sinusoidal space along the sinusoid. The activation occurs mainly due to necrobiotic hepatocytes and activated Kupffer cells. After cytokine induced activation, Ito cells proliferate to transform from resting cells to contractile myofibroblasts (Gressner, 1991, Bachem *et al.*, 1992), which are then involved in the onset of fibrosis. Various cytokines, including transforming growth factor (TGF) that are produced in the hepatocytes and Kupffer cells induce proliferated Ito cells to synthesize extracellular matrix (Houglum *et al.*, 1994). It is known that, during the fibrotic process, TGF- $\beta$ 1 serum concentration is markedly increased (Neumann *et al.*, 2008). A further change during the activation of Ito cells is their metamorphosis to myofibroblasts (Rockey *et al.*, 1993). Myofibroblasts can cause a reduction in the sinusoidal blood flow leading to portal hypertension and contraction of the liver parenchyma (Pinzani *et al.*, 1992, Marra *et al.*, 1993). Both of these are typical pathophysiological features of the end-stage liver cirrhosis. Owing to their role in the fibrotic and cirrhotic liver diseases, activated Ito cells are vital cellular structures for these processes. To characterize the remodeling

\*Corresponding author: S. Neumann  
Address: Burckhardtweg 2, D-37077 Gottingen  
E-mail address: [sneuman@gwdg.de](mailto:sneuman@gwdg.de)

process in the liver, markers associated with the proliferation and metamorphosis of Ito cells could be of interest. Two such potential markers are Ki-67 and  $\alpha$ -smooth muscle actin ( $\alpha$ -SMA).

Ki-67 is a protein that is expressed during cell proliferation and can be found during all the stages of cell cycle except the G0 phase. It is described to be present in cells of different organs during cell proliferation (Scholzen and Gerdes, 2000). In liver, it is also found in the hepatocytes during neoplastic proliferation (Neumann and Kaup, 2005).  $\alpha$ -smooth muscle actin ( $\alpha$ -SMA) is an important protein, which is synthesized during Ito cell activation and transformation into myofibroblasts and is used as a marker for this process in humans (Akpola *et al.*, 2005).

In order to confirm the use of  $\alpha$ -SMA in dogs and investigate further markers for Ito cell activation we analyzed the expression of both  $\alpha$ -SMA and Ki-67 in fibrotic liver tissue of dogs. The aim of this study was to investigate the expression of a metamorphic marker ( $\alpha$ -SMA) and a proliferation marker (Ki-67), to further elucidate the tissue alteration process during the fibrotic process and to establish new markers for fibrosis.

## Materials and methods

### Animals

Twenty-two dogs who were patients at the Clinic for Small Animals, University of Gottingen, Germany, were included in this study. The diagnosis of liver disease was based on histopathological examination of the biopsies. Liver biopsies were performed under the ultrasound guidance or by laparotomy. Three to four biopsy specimens were taken. During laparotomy, biopsy specimens were taken from the macroscopically altered tissue. In the case of ultrasound guidance, the samples were taken from ultrasonographically altered tissue. We used a True-Cut biopsy needle (Surgi-Vet) for taking the biopsy specimens under ultrasound guidance. Each specimen was approximately 2 mm in thickness and 2 cm in length.

### Histology and Immunohistochemistry

#### Specimens

For diagnosis, the biopsies were fixed in 10% for-

malin solution stained with hematoxylin-eosin and Masson trichrome stain and were investigated by an experienced pathologist. One part of the biopsy was prepared for immunohistochemistry with Ki-67 and  $\alpha$ -SMA antibodies. On the other, Masson trichrome staining was performed using standard protocol ([www.medilexicon.com](http://www.medilexicon.com)). Briefly, the tissue samples were stained with Mayer's hematoxylin, Biebrich scarlet-acid fuchsin and light green solution.

### Immunohistochemistry

#### Ki-67

For immunohistochemical detection of Ki-67 expression the histological sections were placed in a pressure cooker, which contained 1 l of boiling 10 mM sodium citrate buffer (pH 6.0). After acquiring maximum pressure, slides were boiled for 1 minute. Pressure equalization was achieved by cooling with water and slides were replaced after 20 minutes of incubation. Immunohistochemistry was performed using the automated NexES®-IHC-staining system (Ventana Medical Systems, Tucson). This system applied a streptavidin-biotin-peroxidase complex technique using the primary antibody CONFIRMTM Anti-Ki67 (Clone K-2) (Cat. 790-2910, Ventana Medical Systems), available in a ready-to-use dilution. iView™ detection system (Ventana Medical Systems), which is an integral part of the NexES®-IHC-staining system, was used for the visualization of the primary antibody.

The automated staining procedure was carried out according to the following steps. First, the slides were heated to 37°C. Then the I-VIEW Inhibitor™ containing 3% hydrogen peroxidase was applied for 4 minutes to inhibit the endogenous peroxidase followed by 10 minutes of Option 1™ (goat serum 1:5, diluted with phosphate buffered saline) to block unspecific binding sites. The slides were incubated in CONFIRMTM Anti-Ki67 (Clone K2) for 32 minutes followed by Fixative 1™ (20  $\mu$ l Glutardialdehyde in 10 ml 0.9% NaCl) for 2 minutes.

The slides were subsequently incubated for 8 min with a biotin-labelled multi-link secondary antibody (I-VIEW Biotin Ig), which could detect both mouse and rabbit immunoglobulins. The streptavidin-peroxidase complex (I-VIEW SA-HRP) and

the chromogenic substrate solution (I-VIEW DAB, I-VIEW H<sub>2</sub>O<sub>2</sub>) were each applied for 8 minutes. Subsequent to incubation with copper sulphate solution (5g/l, 4 minutes), the slides were counterstained with hematoxylin and bluing reagent for 4 minutes each. All steps were followed by incubation with 10XAPK Wash Solution (Ventana Medical Systems, Cat. 250-042). The slides were mounted manually and viewed under a Zeiss Axioptot microscope using 10X to 40X magnification. Confirmed positive histological sections were used as positive controls. For negative controls, the primary antibody incubation was omitted from the staining protocol.

#### $\alpha$ -SMA

For anti-SMA staining the slides were treated in a similar way as described above. The primary antibody, Anti-SMA (Dako Cytomation, monoclonal

mouse anti-human, Clone 1A4, Code No. M 0851) was used at a 1:200 dilution. Ventana's iView<sup>TM</sup> detection system was applied for the visualization of the primary antibody using methods identical to detection of Ki-67 as described in the previous section.

The immunoreactivity was assessed semi-quantitatively. Further, we divided the 22 patients into four groups depending on the degree of fibrosis assessed by Masson trichrome staining. The degree of  $\alpha$ -SMA and Ki-67 expression was compared to the degree of fibrosis within each group.

## Results

The results of this study are summarized in Table 1. Three cases were histopathologically diagnosed with neoplastic liver disease, four with the degenerative process and 15 cases with hepatitis. The de-

Table 1. Histopathology of dogs in this study. Beside the diagnosis, the expression of  $\alpha$ -SMA and Ki-67 was assessed semiquantitatively. 0 = no expression; 1 = mild expression; 2 = moderate expression; 3 = severe expression. The degree of fibrosis was observed using Masson trichrome stain. 0 = no fibrosis; 1 = mild fibrosis; 2 = moderate fibrosis; 3 = severe fibrosis or cirrhosis.

No	Histopathological diagnosis	$\alpha$ -SMA	Ki-67	Masson Trichrome stain
1	Hepatitis with cirrhosis	2	1	3
2	Cholangiocarcinoma with severe fibrosis	3	3	3
3	Cirrhosis	3	3	3
4	Moderate chronic hepatitis with moderate fibrosis	2	1	2
5	Mild hepatitis with moderate fibrosis	1	2	2
6	Reactive hepatitis with moderate fibrosis	1	1	2
7	Hemangithelioma with moderate fibrosis	2	2	2
8	Lymphoma with mild fibrosis	2	3	1
9	Severe lipidosis with mild fibrosis	1	1	1
10	Hydropic degeneration with mild fibrosis	1	1	1
11	Moderate chronic hepatitis with mild fibrosis	2	2	1
12	Mild hepatitis without fibrosis	1	1	1
13	Moderate chronic hepatitis with mild fibrosis	3	2	1
14	Mild hepatitis with mild fibrosis	1	1	1
15	Severe lipidosis with mild fibrosis	3	2	1
16	Mild hepatitis with mild fibrosis	2	1	1
17	Reactive hepatitis with mild fibrosis	1	2	1
18	Reactive hepatitis with mild fibrosis	1	1	1
19	Mild hepatitis without fibrosis	1	0	0
20	Hepatitis without fibrosis	2	2	0
21	Reactive hepatitis without fibrosis	2	0	0
22	Reactive hepatitis without fibrosis	1	1	0



gree of fibrosis was assessed using Masson trichrome staining. Four dogs in this study showed no signs of fibrotic process. Eleven dogs had mild focal interstitial fibrosis and four had moderate fibrosis. Finally, three dogs had severe fibrosis or cirrhosis. In each dog, Ki-67 and  $\alpha$ -SMA immunohistochemistry were performed. Out of

three cases of severe fibrosis two showed high severe expression of Ki-67 and  $\alpha$ -SMA. In one case mild expression of Ki-67 and moderate expression of  $\alpha$ -SMA was seen. Out of four cases with moderate fibrosis, two cases showed moderate expression of Ki-67 or  $\alpha$ -SMA (Fig. 1-3) whereas two other cases showed mild expression of Ki-67 or  $\alpha$ -

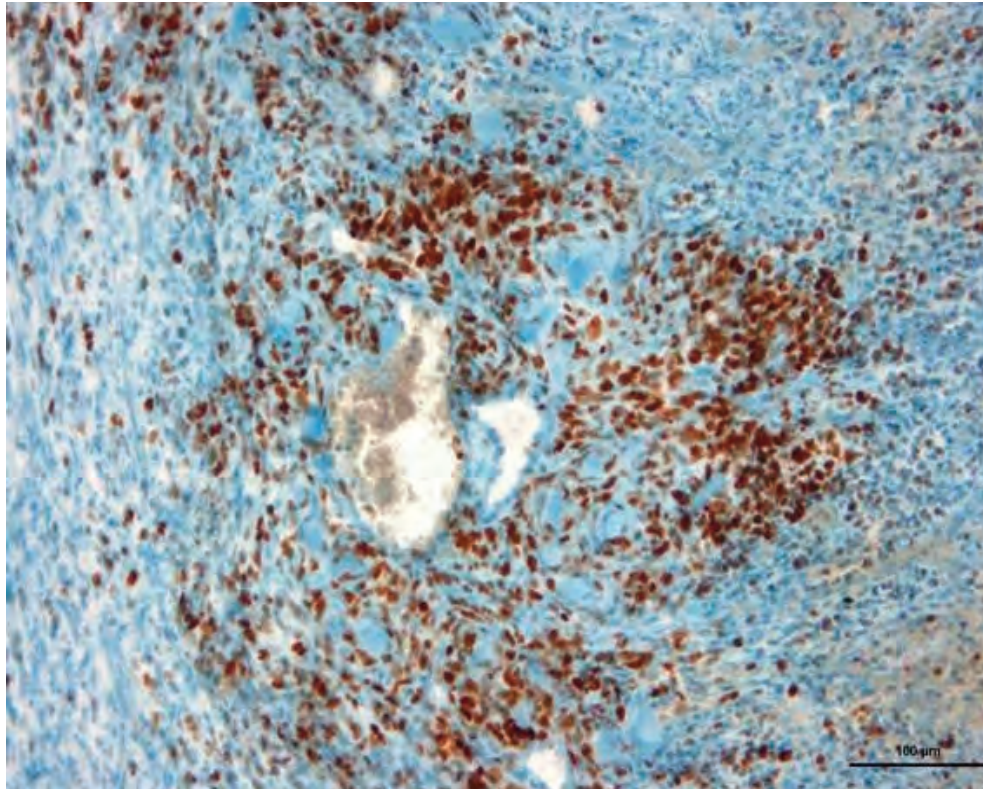


Fig. 1. Ki-67 positive cells in a case of liver tumor with focal fibrosis

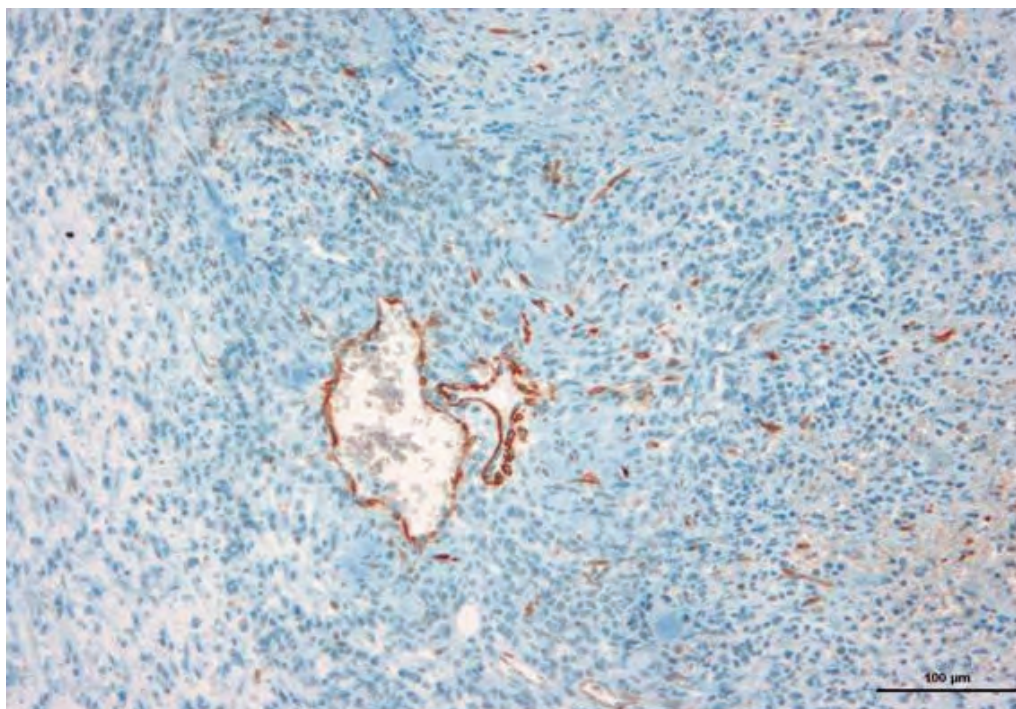


Fig. 2. A-SMA positive cells in the same case as Fig. 1.



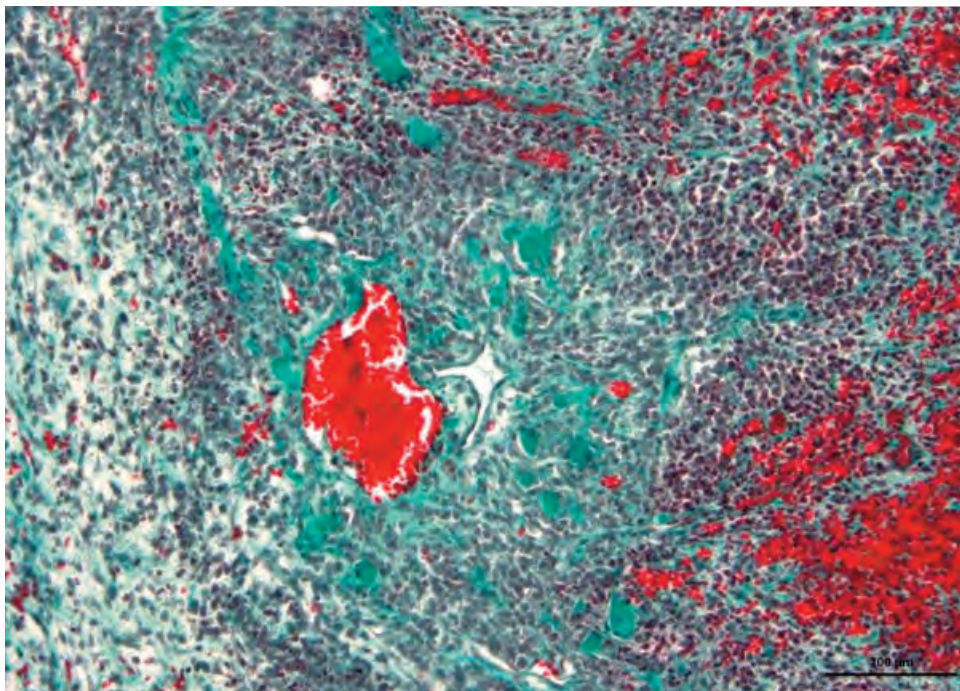


Fig. 3. Masson trichrome stain in the same case as Fig. 1 and 2.

SMA. Among the dogs with mild fibrosis, expression of Ki-67 and  $\alpha$ -SMA was variable ranging from high to mild levels (Table 1).

Finally, the cases with no fibrosis also showed variation in the expression of Ki-67 and  $\alpha$ -SMA, with none to moderate levels of the proteins. The comparison between Ki-67 and  $\alpha$ -SMA showed complete concordance between the degree of Ki-67 and  $\alpha$ -SMA expression in 12 dogs. In nine dogs, the difference between the levels of Ki-67 and  $\alpha$ -SMA expression was one degree. In three dogs the degree of Ki-67 expression was observed to be one degree more than  $\alpha$ -SMA and in six cases the  $\alpha$ -SMA was found to be one degree more than Ki-67. In one case the difference between the two markers was two degrees. The degree of fibrosis and the expression of  $\alpha$ -SMA and Ki-67 were compared using the Mann-Whitney U-Test. No significant difference was observed between the degree of fibrosis and the expression of  $\alpha$ -SMA and Ki-67 ( $P > 0.05$ ). Unfortunately it was impossible to detect activated Ito cells with Ki-67 or  $\alpha$ -SMA clearly. So the positive Ki-67 tissue reaction we observed could be a consequence of activated Kupffer cells or hepatocytes.

## Discussion

Liver fibrosis is a crucial consequence of chronic liver diseases with different etiology. Epidemiolog-

ical studies have shown that liver fibrosis and end-stage liver cirrhosis is a common pathological feature in dogs (Favier, 2009). Due to its reversible character, it is important to recognize liver fibrosis since at the stage of fibrosis, therapy can be successfully performed (Honeckman, 2003, Povero *et al.*, 2010). Different investigators have shown that the characteristics of liver fibrosis change during disease progression (Gressner, 1991, Thornburg, 1998). Thus, at the beginning, there are only a few deposits of extracellular matrix, which make a specific diagnosis difficult. However, by the end-stage, organ architecture has undergone irreversible changes and a mixture of fibrotic deposits and regenerative nodules are present. Markers defining the fibrotic process are important for assessing the progression of the disease, to establish a prognosis and to gain important information that may have therapeutic implications. The fibrotic process begins with increased deposits of different types of collagen and proteoglycans (Gressner and Bachem, 1990, Gressner, 1991). Therefore, identification of these proteins is useful for delineating liver fibrosis. Unfortunately, at this time, irreversible fibrotic changes already begin. Therefore, it is useful to find a marker that can predict extracellular matrix production. The pathophysiological process of liver fibrosis shows that activation of Ito cells is an important step in the disease progression (Pinzani, 1992). Thus, identification of activated Ito cells

could be a good marker for the onset of liver fibrosis. One marker that is already known is  $\alpha$ -SMA (Otogawa *et al.*, 2009). In this study, we investigated  $\alpha$ -SMA and Ki-67 expression in hepatic tissue as potential markers for defining the start of hepatic fibrosis in dogs. Ki-67 is a nuclear marker for cellular activation. In our previous study of liver tumors in dogs, we showed that activation of hepatocytes in neoplastic transformation is identifiable with Ki-67 (Neumann and Kaup, 2005). In the present study, we show that liver tissue express Ki-67 during the activation process of fibrosis. The same is true for  $\alpha$ -SMA, which was also expressed in the liver tissue. It was impossible to detect activated Ito cells clearly, but tissue expression of  $\alpha$ -SMA and Ki-67 correlates with the degree of fibrosis in this study. Therefore, we conclude that,  $\alpha$ -SMA and Ki-67 expression are reliable markers of fibrotic transformation of the liver tissue. It is useful to detect early stages of the disease and can support diagnosis obtained by standard methods like Masson trichrome staining.

## References

- Akpolat N., Yahsi, S., Godekmerdan, A., Yalniz, M., Demirbag, K., 2005. The value of alpha-SMA in the evaluation of hepatic fibrosis severity in hepatitis B infection and cirrhosis development: a histopathological and immunohistochemical study. *Histopathology* 47, 276-280.
- Bachem, M.G., Meyer, D., Melchior, R., Sell, K.M., Gressner, A.M., 1992. Activation of rat liver perisinusoidal lipocytes by transforming growth factors derived from myofibroblast like cells. A potential mechanism of self perpetuation in liver fibrogenesis. *Journal of Clinical Investigation* 89, 19-27.
- Favier, R.P., 2009. Idiopathic hepatitis and cirrhosis in dogs. *Veterinary Clinics of North America Small Animal Practice* 39, 481-488.
- Gressner, A.M., 1919: Liver fibrosis. Perspectives in pathobiochemical research and clinical outlook. *Journal of Clinical Chemistry and Clinical Biochemistry* 29, 293-311.
- Gressner, A.M., Bachem, A.M., 1990. Cellular sources of non collagenous matrix proteins: Role of fat-storing cells in fibrogenesis. *Seminars in Liver Diseases* 10, 30-46.
- Honeckman, A., 2003. Current concepts in the treatment of canine chronic hepatitis. *Small Animal Practice* 18, 239-244.
- Houglum, K., Bedossa, P., Chojkier, M., 1994: TGF-beta and collagen alpha 1 (I) gene expression are increased in hepatic acinar zone 1 of rats with iron overload. *American Journal of Physiology* 267, 908-913.
- Marra, F., Valente, A.J., Pinzani, M., Abboud, H.E., 1993. Cultured human liver fat-storing cells produce monocyte chemotactic protein-1. Regulation by proinflammatory cytokines. *Journal of Clinical Investigation* 92, 1674-1680.
- Neumann, S., Kaup, F.J., 2005. Usefulness of Ki-67 proliferation marker in the cytologic identification of liver tumors in dogs. *Veterinary Clinical Pathology* 34, 132-136.
- Neumann, S., Kaup, F.J., Beardi, B., 2008. Plasma concentration of transforming growth factor-beta1 and hepatic fibrosis in dogs. *Canadian Journal of Veterinary Research* 72, 428-431.
- Otogawa, K., Ogawa, T., Shiga, R., Ikeda, K., Kawada, N., 2009. Induction of tropomyosin during hepatic stellate cell activation and the progression of liver fibrosis. *Hepatology International* 3, 378-383.
- Pinzani, M., Abboud, H.E., Gesualdo, L., Abboud, S.L., 1992. Regulation of macrophage colony-stimulating factor in liver fat-storing cells by peptide growth factors. *American Journal of Physiology* 262, 876-881.
- Povero, D., Busletta, C., Novo, E., di Bonzo, L.V., Cannito, S., Paternostro, C., Parola, M., 2010. Liver fibrosis: a dynamic and potentially reversible process. *Histology Histopathology* 25, 1075-1091.
- Rockey, D.C., Houssetand, C.N., Friedman, S.L., 1993. Activation-dependent contractility of rat hepatic lipocytes in culture and in vivo. *Journal of Clinical Investigation* 92, 1795-1804.
- Scholzen, T., Gerdes, J., 2000. The Ki-67 Protein: From the known and the unknown. *Journal of Cell Physiology* 182, 311-322.
- Thornburg, L.P., 1998. Histomorphological and immunohistochemical studies of chronic active hepatitis in Doberman Pinschers. *Veterinary Pathology* 35, 380-385.
- Wasmuth, H.E., Weiskirchen, R., 2010. Pathogenesis of liver fibrosis: modulation of stellate cells by chemokines. *Zentralblatt Gastroenterologie* 48, 38-45.