

## Radiography of Manus and Pes in Hard Working Donkeys

M.A. Semieka, Magda M. Ali\*

Department of Animal Surgery, Faculty of Veterinary Medicine, Assiut University 71526, Assiut, Egypt.

(Received 20 November 2011/ Accepted 30 December 2011)

### Abstract

The present study aimed to highlight on the radiographic appearance of extensive new bone formation in equine limbs, which resulted from recurrent mild traumas to the limbs in hard working donkeys. The study was carried out on 36 hard working donkeys admitted to the Veterinary Teaching Hospital, Assiut University suffering from different types and forms of lameness (new bone growth). Based on history, clinical signs and radiographic examinations, various types of osteophytes were diagnosed and recorded including: ringbone (20 animals), splints (6 animals), osselets (4 animals), sesamoiditis (4 animals) extensive foot osteophytes (one animal) and splints with accidental absence of digit (one animal).

**Keywords:** Digits; Donkey; Hard working; Osteophytes; Radiography

### Introduction

Donkeys play an important role as an inexpensive means of transportation. The usefulness of these animals depends upon the condition of their feet. The feet are subjected to variable degrees of trauma, especially in those animals working on asphalt and stony roads, leading to different abnormalities (Misk and Nigam, 1985).

The digit and metacarpophalangeal region are clinically important areas that are frequently examined radiographically (Smallwood and Holladay, 1987). Radiography has permitted more precise diagnosis of certain disorders of the skull, esophagus, thoracic cavity, joints and foot (Nigam *et al.*, 1982). Radiography is the most used imaging tool for the diagnosis of the bony disorders (Vanderperren and Saunders, 2009). The present study highlighted on the radiographic features of osteophytes (new bone growth) affecting feet of hard working donkeys.

### Materials and methods

The present study was carried out on 36 mature hard working donkeys of both sexes. They were se-

lected from the clinical cases admitted to the Veterinary Teaching Hospital – Assiut University. These animals were suffering from osteoperiostitis complicated by osteophytes (new bone growth) of their feet. Diagnosis of the cases based on case history, clinical signs and radiography. Radiographic examination of the foot was performed using dorsopalmar (dorsoplantar) and mediolateral views. High definition screens and appropriate film were used and exposure factors ranged from 56 KV, 10 mAs to 60 KV, 12 mAs.

### Results

Based on history, clinical signs and radiographic description, various types of osteophytes (new bone growth = bony exostosis) affecting the feet of hard working donkeys were diagnosed and recorded.

History of all affected cases indicated that, the animals were working hardly on a solid ground, exposed to constant feet trauma during work and showed variable degrees of lameness.

#### *Ringbone (phalangeal exostosis):*

Twenty donkeys were diagnosed in this study suffering from phalangeal exostosis. Ringbones were diagnosed affecting the fore feet in 16 animals and

\*Corresponding author: Magda M. Ali

Address: Department of Surgery- Faculty of Veterinary Medicine- Assiut University 71526, Assiut, Egypt.

E-mail address: magdaali70@yahoo.com

affecting the hind feet in 4 animals. Clinical examination showed different degrees of lameness during gait with presence of hard painful swelling over the phalangeal region. Passive movements of the phalangeal joints revealed severe pain. Radiographic examination revealed presence of osteophytes (new bone growth) at the shaft of the phalanges in 4 cases, at the articular surfaces of the pastern and coffin joints in 4 cases (articular ringbone), at the phalanges around the joints in 3 cases (periarticular ringbone) and at both articular surfaces and phalanges around the joints in 9 cases (articular and periarticular ringbone at the same digit) (Fig. 1, 2, 3, 5 & 6).

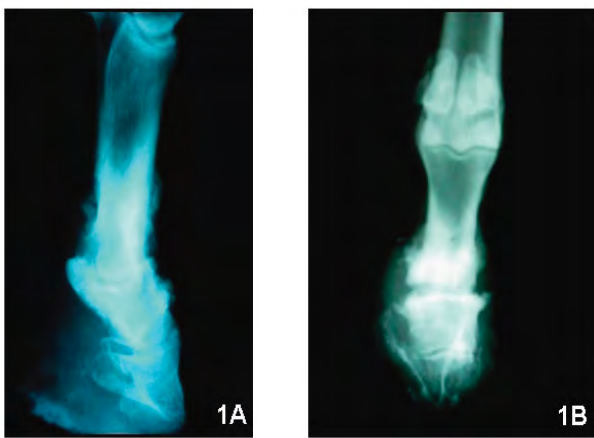


Fig. 1. Mediolateral (A) and dorsopalmar (B) radiographs of the phalangeal region revealed the presence of a new bone growth (osteophytes) at the shaft of the proximal phalanx (high ringbone), shaft of the middle phalanx (low ringbone), at the edge of the pastern joint (periarticular ringbone) and at the joint surfaces (articular ringbone) were involved.

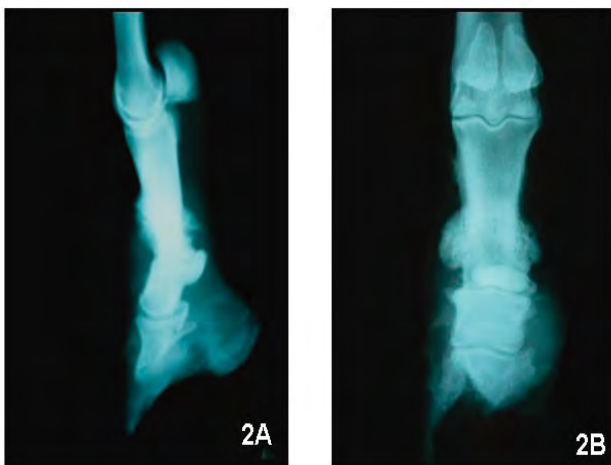


Fig. 2. Mediolateral (A) and dorsopalmar (B) radiographs of the phalangeal region revealed the presence of a new bone growth (osteophytes) at the shaft of the proximal phalanx (high ringbone), shaft of the middle phalanx (low ringbone) and around the pastern joint (periarticular ringbone).

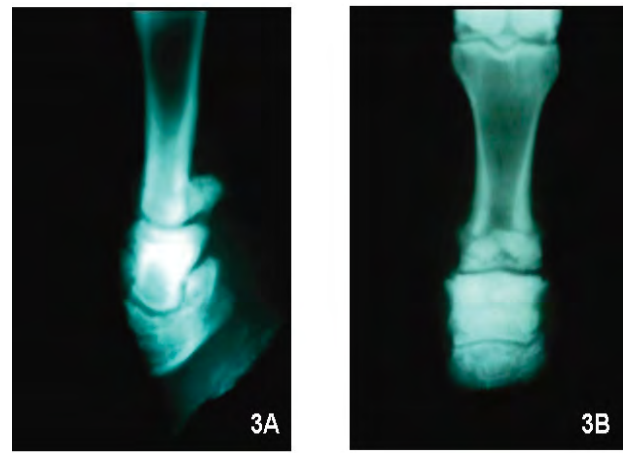


Fig. 3. Mediolateral (A) and dorsopalmar (B) radiographs of the phalangeal region revealed the presence of a new bone growth (osteophytes) at the shaft of the proximal phalanx (high ringbone) and at the shaft of the middle phalanx (low ringbone).

#### Splints:

Six donkeys were suffered from splints (new bone growth of the metacarpal or metatarsal bones) were recorded in this study. Splints were diagnosed affecting thoracic limbs in 4 cases and pelvic limbs in 2 cases. Clinically, the animals showed lameness which increase with exercise on hard ground. By palpation, there is hard swelling attached to the metacarpal or metatarsal bones. Radiographic examination revealed presence of osteophytes connected either with the proximal or distal part of the third metacarpal (metatarsal) bone. In other cases the osteophytes were originating from the posterior aspect of the splint bones. Also splints were observed between the third metacarpal and splint bones (Fig. 4 & 5).

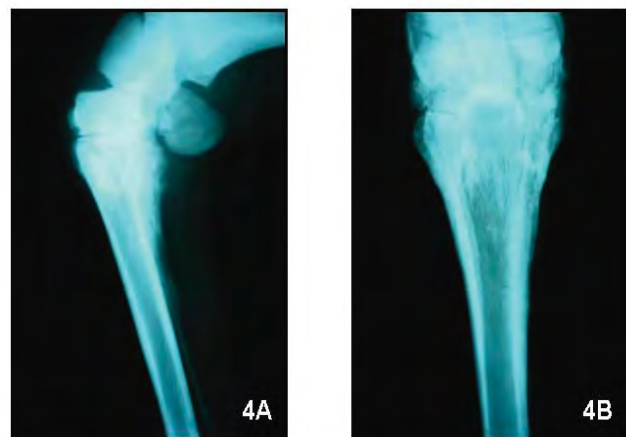


Fig. 4. Mediolateral (A) and dorsopalmar (B) radiographs of the metacarpal region revealed the presence of a new bone growth (osteophytes) at the proximal part of the third metacarpal bone (Knee splints), between the third metacarpal and splint bones (intermetacarpal splints) and at the posterior aspect of the splint bone (postmetacarpal splints).

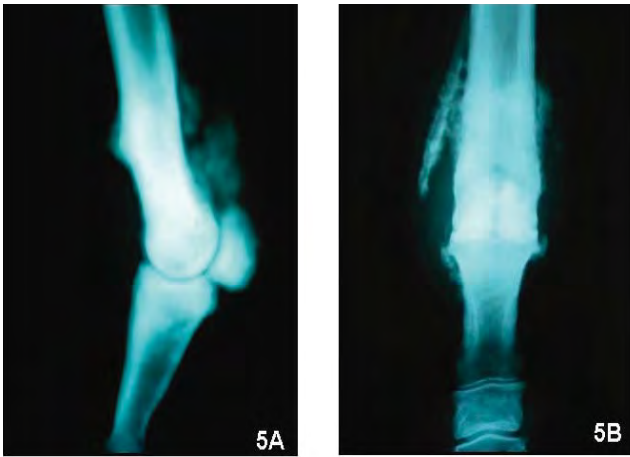


Fig. 5. Mediolateral (A) and dorsopalmar (B) radiographs of the metacarpophalangeal region revealed the presence of a new bone growth (osteophytes) at the distal part of the splint and third metacarpal bones (splints), at the proximal sesamoid bones (Sesamoiditis) and at the proximal part of the proximal phalanx (high ringbone).

*Osselets:*

Osselets were recorded in four cases in this study. In three cases the osselets were affecting both fetlock joints of the thoracic limbs. In the fourth case, the osselets were diagnosed affecting the fetlock joint of the left pelvic limb. Clinical examination showed obvious lameness with presence of hard swelling varies in size around the affected fetlock joints. Pressure over the involved areas revealed severe pain. Radiography revealed presence of newly formed bony growths around the affected fetlock joint and encroaching on the joint surfaces (Fig. 6 & 9).

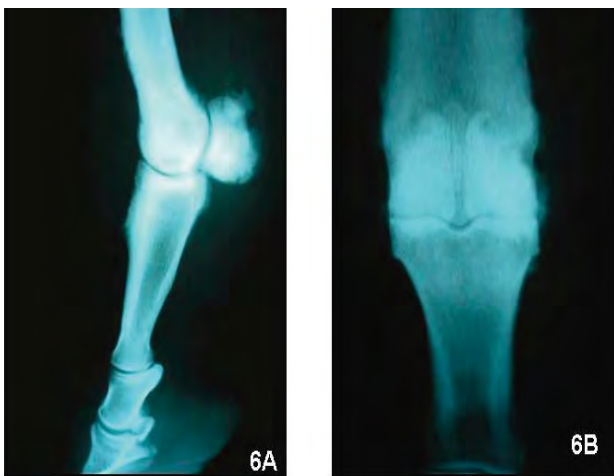

Fig. 6. Mediolateral (A) and dorsopalmar (B) radiographs of the metacarpophalangeal region revealed the presence of a new bone growth (osteophytes) at the proximal sesamoid bones (sesamoiditis), around the fetlock joint (osselets) and at the shaft of the proximal phalanx (high ringbone).

*Sesamoiditis:*

Four donkeys were recorded suffering from osteophytes at the proximal sesamoid bones in this study. This affection was diagnosed in both thoracic limbs in three cases and in the right pelvic limb in one case. The animals were hard working on hard ground. One animal was exposed to severe trauma at the planter aspect of the right fetlock joint. Clinical examination revealed lameness, pain and swelling of the affected fetlock joint especially at the palmar (plantar) aspect. Pressure over the sesamoid bones results in the animal to flinch. During motion, the animal not allows the fetlock joint to descend to normal level. Radiography revealed new bone growth on the convex surface of the sesamoid bones. In case of the animal which exposed to trauma, radiography revealed presence of old fracture of the sesamoid bones in addition to osteophytes. In addition to sesamoiditis, other types of osteophytes (splints, ringbone, osselets) were observed radiographically at the same foot in two cases (Fig. 6, 7 & 8).

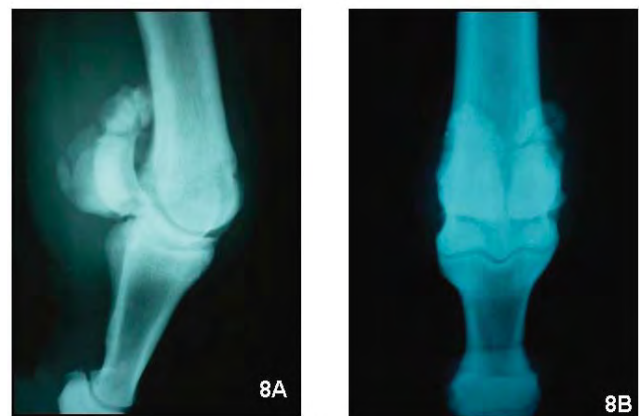
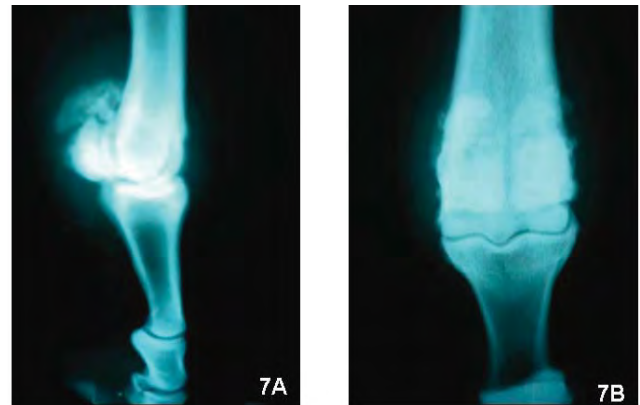


Fig. 7 & 8. Mediolateral (A) and dorsoplantar (B) radiographs of the fetlock region revealed the presence of old fractures complicated by new bone growth (osteophytes) of the proximal sesamoid bones.



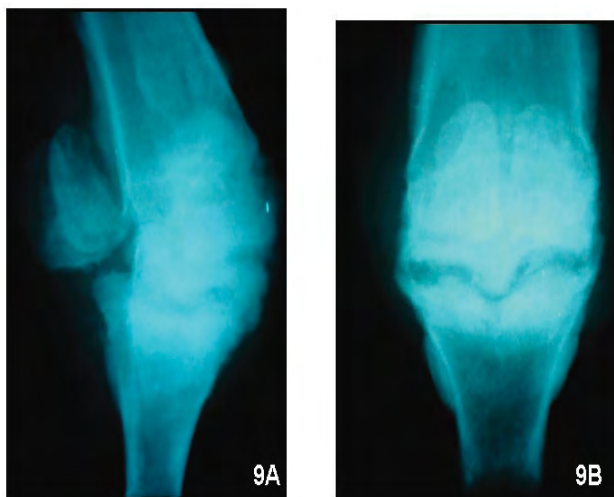


Fig. 9. Mediolateral (A) and dorsopalmar (B) radiographs of the fetlock joint revealed the presence of a new bone growth (osteophytes) around the joint and involves the joint surfaces (osselets).

*Extensive foot osteophytes (ringbone, osselets and splints):*

One donkey was presented with history that the animal hard working and exposed to trauma at the level of the distal third of the right metacarpal bone. Clinical examination revealed presence of extensive hard swelling at the distal part of the metacarpal bone, fetlock joint and at the phalangeal region. The animal cannot bear weight on the affected limb with presence of fracture signs at the distal part of the metacarpal bone. Radiographically, the affected area showed presence of complete, single, transverse, diaphyseal fracture of the third metacarpal bone in addition to presence of extensive osteophytes at the distal part of the third metacarpal bone (splints), around the fetlock joint (osselets) and at the phalangeal region (ringbone) (Fig. 10).

*Splints with absence of digit:*

One donkey was presented with accidental absence of the digit of the right thoracic limb. Clinical examination revealed presence of a hard swelling at the distal third of the metacarpal bone of the affected foot. Radiography showed absence of the digit with presence of extensive osteophytes attached to the distal part of the third metacarpal bone, posterior aspect of the splint bones and between the third metacarpal and splint bones (Fig. 11).

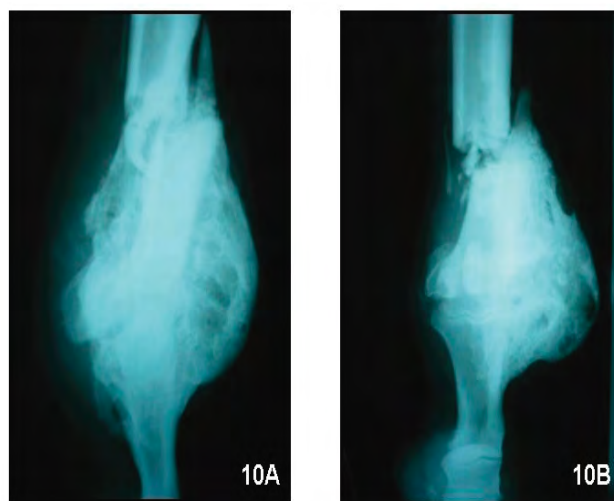


Fig.10. Mediolateral (A) and dorsopalmar (B) radiographs of the metacarpophalangeal region revealed the presence of extensive new bone growth (osteophytes) at the distal part of the third metacarpal bone (splints), at the fetlock joint (osselets) and at the shaft of the proximal phalanx (high ringbone). Note the presence of complete, single, transverse fracture of the third metacarpal bone proximal to the level of the osteophytes.

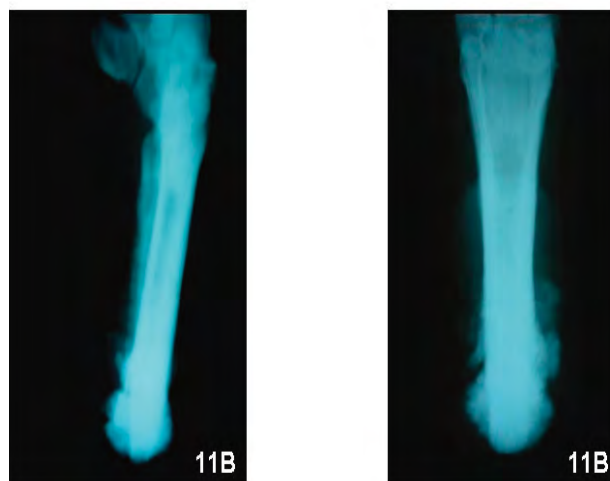


Fig. 11. Mediolateral (A) and dorsopalmar (B) radiographs of the metacarpal region revealed the presence of extensive new bone growth (osteophytes) at the third metacarpal bone (traumatic splints), between the third metacarpal and splint bones (intermetacarpal splints) and at the posterior aspect of the splint bones (postmetacarpal splints). Note absence of the digit.

**Discussion**

The foot represents an important structure to the sound movement of the donkey limb during both support and swing phases of the stride. Any affliction that causes pain or reduction in the range of motion may seriously affect performance. Radiography is still the most accessible and most com-

monly used imaging modality for the diagnosis of bone lesions (Vanderperren *et al.*, 2009). In the present study several types of osteophytes (new bone growth) were diagnosed and recorded affecting feet of hard working donkeys including ringbone, splints, osselets and sesamoiditis. Ringbone is new bone growth that occurs on the first, second or third phalanx. It is the result of a periostitis and may lead to an osteoarthritis or ankylosis of the pastern or coffin joints. A periostitis produced by pulling of the collateral ligaments of the joint involved, pulling of the joint capsule attachments to the bone, pulling of the attachments of the common extensor tendon to the first, second or third phalanx and direct blows to the phalanges are the most common causes of ringbone (Adams, 1974). New bone seen in localized on the diaphysis of the proximal and middle phalanges, is probably due to periostitis as a result of trauma. While forming, this may be associated with lameness, particularly when the horse is worked on hard surfaces (Butler *et al.*, 1993). In the present study ringbone was considered to be the most common osteophytes affecting foot of hard working donkeys. It recorded more common in the thoracic limbs (16 animals) than in pelvic limbs (4 animals). These animals were exposed to constant trauma and pulling of the soft tissues attached to the phalangeal region during their work leading to periostitis complicated by formation of new bone growth. In describing of ringbone, the following terminology is used, periarticular high ringbone; articular high ringbone; periarticular low ringbone or articular low ringbone (Stashak, 1987). In this study, all types of ringbone were observed in the same digit in most cases. This may be due to constant hard work in a hard ground leading to severe periostitis and extensive osteophytes affecting phalanges and interphalangeal joints. Lameness associated with the metacarpal region may be due to a number of causes including periostitis of the second or fourth metacarpal bones (Dyson, 1991). Splints is new bone growth that occurs between the second and third or between the fourth and third metacarpal bones. The condition may also occur, but is less common in the pelvic limb (Adams, 1974). In the present study the splints were recorded affecting the metacarpal bones in 4 cases and affecting the metatarsal bones in 2 cases of hard working donkeys. There are four types of splints in donkeys represented by postmetacarpal splints; intermetacarpal splints; knee splints and

deep splints. The most common type of splints encountered in donkeys was the postmetacarpal splint (Misk and Hifny, 1982). Postmetacarpal, intermetacarpal and knee splints were diagnosed in this study, in addition to osteophytes at the distal part of the third metacarpal bone (traumatic splints). Direct trauma to any of the metacarpal bones may result in inflammation of the periosteum and/or a subperiosteal haematoma and subsequent periosteal new bone. Periostitis between the second and the third or fourth and third metacarpal bones develops secondary to damage of the interosseous ligament (Butler *et al.*, 1993, Thrall, 2002). In the present study, the donkeys were hard working and usually exposed to irritation of the interosseous ligament and trauma to the third metacarpal bone causes periostitis and new bone growth. Osselet is traumatic arthritis of the fetlock joint. The metacarpophalangeal and metatarsophalangeal joints (fetlock joints) are the joints most frequently affected with degenerative and traumatic lesions in the horse, and are therefore commonly subjected to radiographic and ultrasonographic examination (Pool and Meagher, 1990, Denoix *et al.*, 1996, Ueltschi *et al.*, 1996 and Brommer *et al.*, 2003). New bone growth is caused by periostitis that results from pulling of the joint capsule attachments or from pulling of the periosteum at the attachment of the lateral digital extensor tendon. Osselets are most common in young Thoroughbreds and Standardbreds in early training (Adams, 1974). In the present study osselets were diagnosed in 4 hard working donkeys. Based on history these animals were act on hard ground and exposed to constant irritation and pulling of the tissues attached to joint structures leading to periostitis complicated by osteophytes. Sesamoiditis means inflammation of the proximal sesamoid bones accompanied by periostitis, osteitis and new bone production. The new bone on the abaxial and distal surfaces of the sesamoid bone is often associated with strain of the suspensory ligament and distal sesamoidean ligaments. Most common in race horses, hunters, and jumpers (Adams, 1974, Butler *et al.*, 1993). Sesamoiditis is indicated radiographically by bony proliferation on non articular surfaces of the proximal sesamoids (Thrall, 2002). Four donkeys were recorded in this study suffering from new bone growth of the proximal sesamoid bones. These osteophytes may be due to periostitis and osteitis of the bones as a result of hard work (three cases) or

due to fracture of the sesamoid bones (one case). In conclusion, osteophytes or bony exostosis is considered to be a common affection of the foot of hard working donkeys. Ringbone was the most common osteophytes recorded in this study. More than one type of osteophytes (ringbone, splints, osselets, sesamoiditis) were radiographically diagnosed affecting the same foot. Hard work on hard ground for a long period may be the cause of constant irritation, trauma and pulling of the soft tissues attached to the foot bone leading to periostitis and osteitis which complicated by bony exostosis. Radiography is the most accessible and best imaging modality for the diagnosis and description of new bone growth (osteophytes).

## References

- Adams, OR., 1974. Lameness in horses. 3rd Edition; Lea and Febiger; Philadelphia. pp. 207-240.
- Brommer, H., Van weeren, RR., Brama, PAJ., Barneveld, A., 2003. Quantification and age-related distribution of articular cartilage degeneration in the equine fetlock joint. *Equine Veterinary Journal* 35, 697-701.
- Butler, SE., Colles, CM., Dyson, SJ., Kold, SE., Poulos, P., 1993. *Clinical radiology of the horse*. Blackwell Scientific Publications; London Paris Vienna; pp.79, 94, 117, 121.
- Denoix, JM., Jacot, S., Bousseau, B., Perrot, P., 1996. Ultrasonographic anatomy of the dorsal and abaxial aspects of the equine fetlock. *Equine Veterinary Journal* 28, 54-62.
- Dyson, S., 1991. Proximal suspensory desmitis: Clinical, ultrasonographic and radiographic features. *Equine Veterinary Journal* 23, 25-31.
- Misk, NA., Hifny, A., 1982. Thoracic limb splint in donkeys. *Assiut Veterinary Medical Journal* 10, 183-185.
- Misk, NA., Nigam, JM., 1985. Unusual traumatic foot abnormalities in Egyptian Donkeys. *Equine Practice* 7, 15-20.
- Nigam, JM., Chandna, IS., Singh, AP., 1982. Radiography of laryngopharyngeal foreign bodies. *Modern Veterinary Practice*; February pp. 166-168.
- Pool, RR., Meagher, DM., 1990. Pathological findings and pathogenesis of racetrack injuries. *Veterinary Clinics of North America- Equine Practice* 6, 1-30.
- Smallwood, JE., Holladay, SD., 1987. Xeroradiographic anatomy of the equine digit and metacarpophalangeal region. *Veterinary Radiology* 28, 166-173.
- Stashak, T., 1991. *Adams lameness in horses*, fourth ed. 1987; Lea & Febiger. pp. 552-558.
- Thrall, DE., 2002. *Textbook of veterinary diagnostic radiology*. Fourth Edition. W.B. Saunders Company Philadelphia London Toronto. pp 249, 267.
- Ueltschi, G., Voswinkel, K., Lauk, HD., 1996. Scintigraphical and radiological examination of fetlock joints in clinically sound and lame horses. *Pferdeheilkunde* 12, 25-32.
- Vanderperren, K., Saunders, JH., 2009. Diagnostic imaging of the equine fetlock region using radiography and ultrasonography. Part 2; bony disorders. *The Veterinary Journal* 181, 123-136.
- Vanderperren, K., Raes, E., Bree, HV., Saunders, JH., 2009. Diagnostic imaging of the equine tarsal region using radiography and ultrasonography. Part 2; Bony disorders. *The Veterinary Journal* 179, 188-196.