



## A Successful Surgical Approach for Treatment of the Spastic Paresis in two Calves

Mohammed A. H. Abdel-Hakim\*, Haroun A. Youssef

Department of Animal Surgery, Faculty of Veterinary Medicine, Assiut University, Assiut, 71526, Egypt

(Accepted 10 May 2013)

Spastic paresis or Elso-heel is a progressive neuromuscular disease which affects the hind limb in young cattle (Baird *et al.*, 1974; Harper, 1993). It is recorded in Holstein, Freisian and other breeds (Baird *et al.*, 1974; Harper, 1993). This disease resulted from the contraction of the gastrocnemius and superficial flexor digital muscles and in some cases, the biceps femoris, semitendinosus, semi-membranosus, quadriceps and abductor muscles (Windsor and Agerholm, 2009). The involvement of the quadriceps in this disease is not confirmed (Caroline *et al.*, 2013). The contraction of the aforementioned muscles resulted in extension of the stifle and hock joints. It is considered a heritable disease. Inheritance may be a result of multiple recessive genes (Ducharme, 2004).

There are several surgical methods for treatment of the spastic paresis. The partial tibial neurectomy is one of them but this technique is invasive, somewhat difficult at its implementation and needs electrostimulation to verify the denervation of the gastrocnemius muscles. A slight chance of recurrence occurs due to missing of some branches during surgery or due to reinnervation occurred. Complications after the procedure are rare but may lead to dropped hock and ruptured gastrocnemius tendon (Ducharme, 2004).

In the period from January, 2007 to December, 2012, only two calves (1 male, 4 months of age and 1 female, 2 months of age) were admitted to the surgery department at the Veterinary Teaching Hospital (VTH), Assiut University, Assiut, Egypt. The calves had unilateral left hind limb lameness. This

lameness was characterized by lifting up of the affected limb above the ground (Figs. 1 and 2). The affected limb appeared shorter and with backward movement resembling the pendulum, in addition to the hyperextension of its stifle, hock and fetlock joints. The angle of the tarsal joint increased explicitly than normal.



Fig. 1. Hyperextension of the stifle, hock and fetlock joints of the left hind limb of 4 months old age male calf.




Fig. 2. Hyperextension of the stifle, hock and fetlock joints of the left hind limb of 2 months old age female calf.

\*Corresponding author: M. A. H. Abdel-Hakim

E-mail address: hamdsurgery@yahoo.com

The two calves had lameness at the left hind limbs. This lameness appeared about forty days after their birth. They received nerve tonics, calcium therapy and non steroidal anti-inflammatory drugs by the veterinarians before their admission to the hospital.

The calves were examined clinically and had normal physiological parameters (Heart rate, respiratory rate and rectal temperature). The calves showed hyperextension of the hock joint, severe spasmodic contraction of the gastrocnemius muscles and the consistency of common calcanean tendon resembled the bone. The animal could not stand on the affected limb which was lifted up over the ground and staggered as a pendulum.

Radiographic examination of the affected limb was performed using fixed X ray machine. The exposure factors used were 40 mA/s and 50 Kv and the focal film distance (FFD) was about 90 cm.

A square area above the hock joint at the lateral aspect of the affected limb was prepared aseptically for surgery (Fig. 3). The animal was positioned on the lateral recumbency with affected limb upwards. A transverse line of infiltration analgesia above the line of the incision was performed (Fig. 3) using 1 % Lidocaine Hcl.

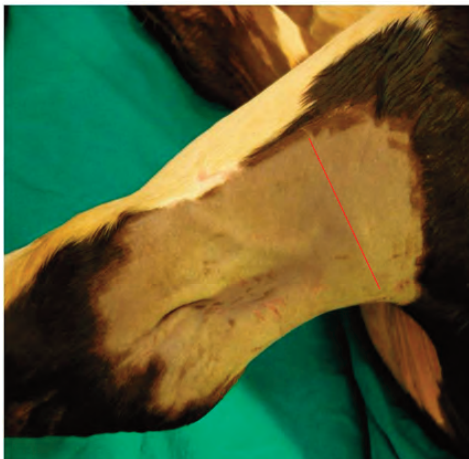


Fig. 3. A square area at the lateral aspect of the affected limb and above the point of hock joint was prepared for surgery. Red line represented the line of infiltration analgesia.

Vertical incision (6- 8 cm above the point of the hock joint and at the lateral aspect of the limb) was performed. The incision passed through the skin and the subcutaneous tissue. Curved scissors were introduced under the common calcanean tendon (Fig. 4). The tendons of the gluteobiceps, gastrocnemius and semitendinous muscles were severed

by a scalpel. The tendon of SDFM, tibial nerve and lateral saphenous vein were preserved intact (Fig. 5). The wound was closed by simple interrupted suture pattern using braided silk no 2 (Figs. 6).

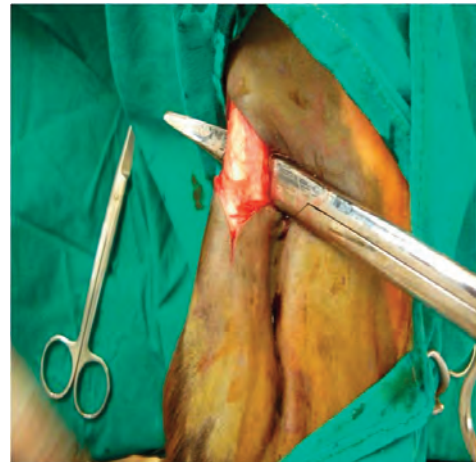

Fig. 4. A Curved scissors were introduced under the common calcanean tendon.

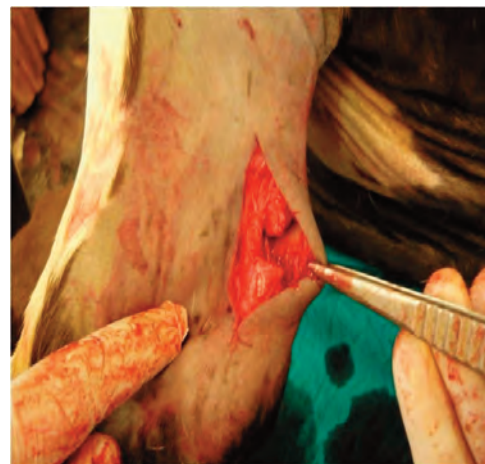

Fig. 5. Partial transection of the common calcanean tendon with preservation of the SFT.

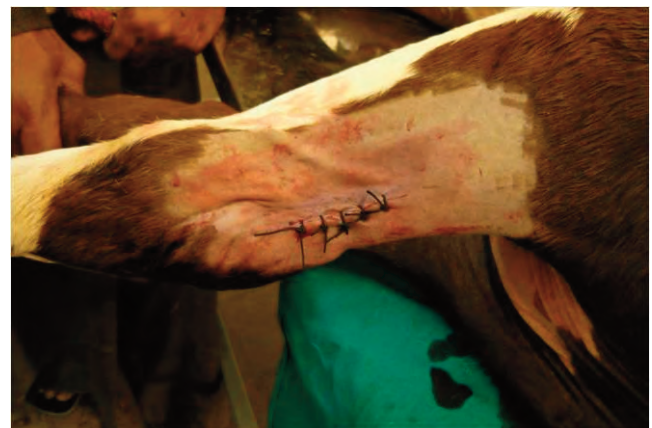

Fig. 6. Closure of the skin using the simple interrupted suture pattern by silk no 2.



The animals received only broad spectrum antibiotics for 5 days (Ampicillin trihydrate 10 mg/Kg. B.W.) post- operation.

The results of the surgical management of spastic paresis appeared directly after the operation and were satisfactory. The animals did not bear the weight on the affected limb in the first few steps after the operation, but their gaits were improved gradually (Figs. 7, 8 and 9). It was noticed clearly that the operated limb showed full bearing weight within few minutes post-operatively. The cases were followed up for 4 weeks after the operation by the phone. The animals resumed the normal function of the hind limbs.

One of the 2 calves readmitted after 18 days post operation suffering the spastic paresis in the opposite hind limb (right hind limb). The animal was subjected to the surgical management as mentioned previously. The animal received broad spectrum antibiotics for 5 days post operation (Figs. 8

and 9).

The radiographic examination of the affected limb displayed increase in the angle of hock joint, moreover there were no changes detected in the joints (hock and fetlock) (Fig. 10).

The spastic paresis disease is considered a rare condition affects the calves (Ledoux, 2001). Although Arnault (1983a and b) stated that the disease mainly affect the male calves, the 2 cases admitted to VTH were of both sex.

It is considered a disease of young cattle not affect other species (Baird *et al.*, 1974; Harper, 1993)., and there is no a definite period of susceptibility in calves. Ducharme (2004) stated that no clinical signs were observed until 1- 2 years of age, while Windsor and Agerholm (2009) noted the signs at 3-6 months, but in this short study the signs were recorded at 30 days old age.

Appearance of the spastic paresis signs several weeks after birth indicates that the disease is not a



Fig. 7. The calf bore weight on the operated limb.



Fig. 8. The readmitted calf after 18 days from the surgical treatment of the left hind limb bore weight on the recently operated limb (right limb). The red arrow refers to the previous wound after healing.



Fig. 9. The calf walked normally and bore weight on the both hind limbs.

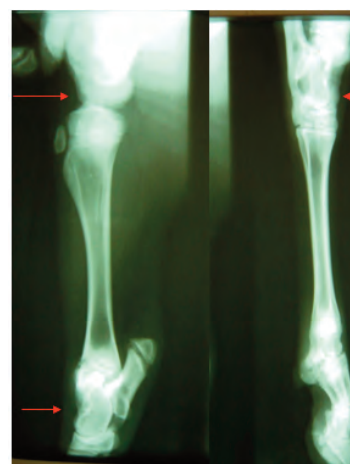


Fig. 10. Radiograph of the affected limb showed the increase angles of the stifle and hock. Red arrows.

congenital one but it is considered a hereditary disease. The appearance of signs on the affected animals in different time after birth may be attributed to other contributing factors (Vlaminck *et al.*, 2000; Ledoux, 2001). Recent studies reported that the disorder of dopamine metabolism may be the possible cause of spastic paresis in calves (Andrews, 2004). The nutritional deficiency may play an important role in the appearance of the signs this is due to the decrease of Ca and P in CSF of the affected calves (Weaver, 2004). So the combination of inheritance and effect of the environmental factors control the onset of the spastic paresis.

The medical treatment was useless, so the surgical management of the disease is the best approach to increase the chance for improvement of the animal and to avoid the disuse atrophy of the affected limb. The two surgical techniques used for the treatment of this disease are the partial neurectomy of the tibial nerve or the partial transection of the common calcanean tendon (Ducharme, 2004).

The easily implemented technique was carried out for treatment of the 2 admitted calves is the partial severing of the common calcanean tendon above its point of insertion to the calcaneal bone. This method is non invasive and time sparing method relative to the partial tibial neurectomy (Ducharme, 2004) in addition to; it is easier to be applied by the veterinarians in the field.

Cutting the tendon of gastrocnemius muscle is considered one of the most important steps in the surgical management of the spastic paresis. This is due to the electromyogram studies that indicate the increase of electrical activity in gastrocnemius muscle and to lesser extent in other muscles (Weaver *et al.*, 2005). Moreover, the preservation of the SDFT intact prevent the over flexion of the hock joint and in addition may counteract the effect of extensor tendons on the distal joints (Fetlock and pastern).

The positive satisfactory results which appeared directly post operation indicate that the spasmodic contraction of the muscles was the main cause of the signs of the spastic paresis (Windsor and Agerholm, 2009).

It could be concluded from this short report that the spastic paresis is not a congenital disease but it is considered a hereditary one, which may show its signs on the young calves beginning from 1 month to 1 year after birth. It is easily managed surgically by the partial transection of the common calcanean

tendon. The treated animals should not be used for breeding to decrease the chance of inheritance. Although the animals may be admitted with unilateral limb affection, however, it can be vulnerable for the affection in the contra lateral limb so the owner should be informed.

## Acknowledgements

The authors are grateful to the Director of Veterinary Teaching Hospital and the members of Department of Animal Surgery, Faculty of Veterinary Medicine, Assiut University, Assiut, Egypt for their kind support.

## References

- Andrews, A.H., 2004. Congenital Conditions. In: Bovine Medicine Diseases and Husbandry of Cattle. 2nd ed. Wiley-Blackwell. pp. 172-184.
- Arnault, G., 1983a. Bovine spastic paresis. Proceedings, XIIth World Congress of diseases of cattle, Amsterdam, 1982; II: 853-858. Reprinted in Bovine Practitioner 18, 236-237.
- Arnault, G., 1983b. Bovine spastic paresis. Effect of lithium therapy. Proceedings, Spurenelement Symposium, Iena, Germany; 4: 306-311.
- Baird, J.D., Johnston, K.G., Hartley, W.J., 1974. Spastic paresis in Friesian calves. Australian Veterinary Journal 50, 239-245.
- Caroline, D., Vlaminck, L., Hauspie, S., Saunders, J., Gasthuys, F., 2013. Ultrasound-guided femoral nerve block as a diagnostic aid in demonstrating quadriceps involvement in bovine spastic paresis. Veterinary Journal 196, 451-455.
- Ducharme, N.G., 2004. Surgery of the calf musculoskeletal system (chapter 15). In: Farm Animal Surgery. 1st ed. Saunders, Philadelphia. pp. 283-504.
- Harper, P.A.W., 1993. Spastic paresis in Brahman crossbred cattle. Australian Veterinary Journal 70, 456-457.
- Ledoux, J.M., 2001. Bovine spastic paresis: etiological hypotheses. Medical Hypotheses 57(5), 573-579.
- Vlaminck, L., De Moor, A., Martens, A., Steenhaut, M., Gasthuys, F., Desmet, P., Van Branteghem, L., 2000. Partial tibial neurectomy in 113 Belgian blue calves with spastic paresis. Veterinary Record 147: 16-19.
- Weaver, A.D., 2004. Lameness above the Foot. In: Bovine Medicine Diseases and Husbandry of Cattle. 2nd ed. Blackwell Publishing Company. pp. 435-467.
- Weaver, A.D., St Jean, G., Steiner, A., 2005. Lameness. In: Bovine Surgery and Lameness. 2nd ed. Black well publishing. pp. 198-258.
- Windsor, P.A., Agerholm, J.S., 2009. Inherited diseases of Australian Holstein-Friesian cattle. Australian Veterinary Journal 87, 193-199.