

**Effectiveness of Tetrachlorodecaoxide Compounds in the Healing of Mandibular Fracture**Arslan Tariq<sup>\*1</sup>, Asim Shahzad<sup>2</sup>, Misbah Ijaz<sup>3</sup>, Zeeshan Akbar<sup>1</sup><sup>1</sup>*Faculty of Veterinary Sciences (FVS),* <sup>2</sup>*Department of Veterinary Pathology,* <sup>3</sup>*Department of Clinical Medicine and Surgery (CMS), University of Agriculture, Faisalabad (UAF)-38040, Punjab, Pakistan*

Accepted 17 March 2014

**Abstract**

Fractures of mandible are more common in fighting dogs or can be occur due to accidents. A dog with similar fracture was presented at Department of Clinical Medicine and Surgery (CMS) with dropped jaw, drawling of bloody saliva. Animal was reluctant to eat and was depressed. After critical physical examination, the condition was confirmed as bilateral fracture of the mandibular body. After performing the necessary pre-operative test like complete blood count (CBC), Serum biochemistry and urinalysis, fracture was surgically reduced by using inter-dental wiring technique. Tetrachlorodecaoxide drops (TCDO) (Oxoferin®; Brookes Pharmaceutical Laboratories, Pakistan) were applied on fracture site three to four times /day until recovery. Animal was kept on liquid diet (chicken soup and milk) throughout and semi-solid food after 25 days. The fracture healed uneventfully in just 37 days.

*Keywords: Dog; Inter-dental wiring; Mandibular fracture; Oxoferin*

**Introduction**

Mandibular fractures are common in dogs, as they are more prone to get fractured at premolar region. Out of total mandible fractures, 31% of mandibular body was reported due to accidents, but may also be occurring due to fighting or any disease (Glyde and Lidbetter., 2003; Tiwari *et al.*, 2012). Approximately, 34% of open or contaminated fractures become complicated, but rapidly healed without large callus formation (Tiwari *et al.*, 2012). Inter-dental wire and acrylic bonding (IWAB) is the best treatment to reduce mandibular body fractures (Glyde and Lidbetter., 2003). In a respected report, the technique is successfully applied without using acrylics along with Tetrachlorodecaoxide compounds showed earlier recovery than normal.

**Case description**

An indigenous domesticated dog of approximately 2.5 year old brought to the Veterinary Teaching

Hospital at CMS (University of Agriculture, Faisalabad), with chief complaint of mandibular fracture. Animal showed drawling of bloody saliva, dropped jaw, and pain in chewing. Physical manipulation revealed, complete bilateral open fracture of the mandibular body (Fig. 1). Clinical parameters e.g. temperature, respiration and pulse were noted within normal ranges as 102.2 OF, 20 resp./min and 92 bpm respectively.

As animal was already anorexic from last night and it was better to operate as early as possible so decided to operate in 2 hour by Interdental wire and acrylic bonding (IWAB) technique. Necessary pre-operative tests like CBC, serum biochemistry and urinalysis were performed to check any change in profile, and found to be normal.

**Treatment protocol**

After making necessary preparation, surgical site was prepared aseptically. Atropine sulfate at 0.04 mg/kg b.w and Ketamine hydrochloride at 4 mg/kg b.w were used intramuscularly as anti-sialagogic and to reduce the anesthesia dose respectively. For general anesthesia, Pentothal sodium at 20 mg/kg b.w was injected intravenously. At fracture site in-

\*Corresponding author: Arslan Tariq

E-mail address: [dr.arslantariq3418@live.com](mailto:dr.arslantariq3418@live.com)



Fig.1. Photograph showing complete fracture of mandibular body.

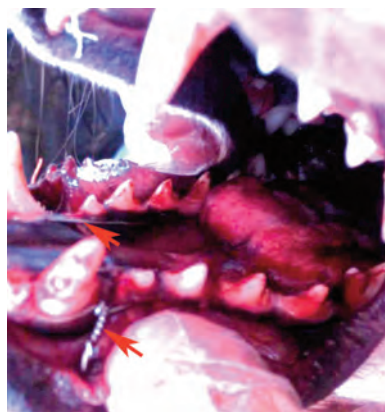


Fig. 2. Photograph showing inter-dental wiring.

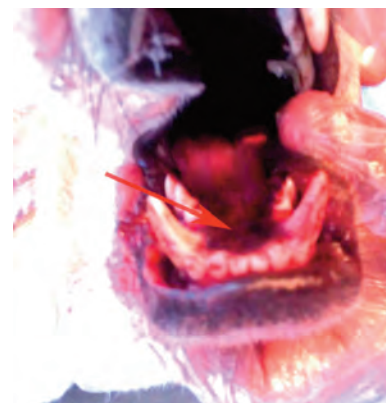

Fig.3. Photograph showing complete recovery mandibular fracture after 37 days.

cision on mucous membrane was given to clear the site for drilling. Two holes, behind the canine teeth and in-between 1st and 2nd premolars were made laterally to horizontal ramus. A 4" piece of stainless steel wire of 20 gauge laterally inserted to first hole (in between the 1st and 2nd premolars), which ejects outside from other hole (behind the canine teeth) after passing from the medial side (oral cavity). Three twists were given to wire and piped after cutting the extra wire (Fig. 2). After stabilization, a simple interrupted suture was given to close the incision site. The same protocol was applied on the opposite side mandible.

Postoperative therapy was done with ceftriaxone sodium at 25 mg/kg b.w and Ketoprofen at 2 mg/kg b.w for 10 days. Three to four drops of TCDO (Oxoferin®; Brookes Pharmaceutical Laboratories, Pakistan) were recommended after washing of mouth after every meal until recovery. As TCDO is an oxidizing in nature, so perform a bactericidal activity and supposed to be enhancing the healing process. The animal was kept in liquid feed including chicken soup and milk as an active ingredient for whole period of recovery. After 25 days, wires were removed and animal was brought to semi-solid feed along with liquid feed. Complete recovery seen in 37 days without any complication (Fig. 3).

## Discussion

Always the targeted goals of surgery are restoration of normal functioning and stabilization to accelerate healing process. Interdental wire and acrylic bonding (IWAB) technique was used to reduce the fracture. Wire was placed on lateral side of

mandible to provide good stability. Following surgery an anti-biotic and anti-pyretic cover was given for 10 days to avoid complications as also described by Glyde and Lidbetter. (2003). Complications such as osteomyelitis, mal or non-union may lead to partial mandibulectomy but with fibrous union, animal may remain functionally active (Olmstead, 2010).

Tetrachlorodecaoxide drops after every meal were found to be helpful in rapid healing. TCDO actually enhance healing process by attracting macrophages derived growth factor, which deposit fibroblast and synthesize collagen fibers and wound angiogenesis factor increasing capillaries bed at fracture site (Tiwari *et al.*, 2012; Glyde and Lidbetter., 2003). Normally fractures of the mandibular body heal earlier than symphyseal usually within 6 weeks (Gonul *et al.*, 2009; Glyde and Lidbetter, 2003). But here in the studied case complete recovery was recorded in just 37 days explaining the effectiveness of TCDO and IWAB in the treatment of fracture of the mandibular body (Fig. 3).

## References

- Glyde, M., Lidbetter, D., 2003. Management of fractures of the mandible in small animals. In Practice 25, 570-585.
- Gonul, R., Kayar, A., Koenhemi, L., Ozkan, B., Erman, M., 2009. Management of Mandibular Fractures in dogs. Indian Veterinary Journal 86(3), 301-302.
- Olmstead, M.L., 2010. Small Animal Orthopedics, 3rd ed., Mosby, St.Louis, Missouri, pp: 180.
- Tiwari, S.K., Kaushal, G.D., Sharda, R., Singh, H., Choudhary, Y., 2012. Successful repair of mandibular symphyseal fracture in a Dog. Veterinary World 5(12), 762-763.