



Approach for Diagnosis of Complicated Traumatic Reticuloperitonitis in Cattle using Ultrasonography

Arafat Abdellah Khalphallah, Ali Hussein El-Sebaie, Mohamed F. Raghib

Department of Animal Medicine, Faculty of Veterinary Medicine, Assiut University, 71526 Assiut, Egypt

ARTICLE INFO

Original Research

Accepted:

25 September 2015

Keywords:

Cattle
Diaphragmatic hernia
Reticuloperitonitis
Ultrasonography

ABSTRACT

The current study indicated that the complicated sequellae of traumatic reticuloperitonitis (TRP) in cattle could be efficiently diagnosed by using of ultrasonography and some other diagnostic tools. The affections in these cases included reticulum and spleen with extension to one or more of the other organs such as rumen and abomasum. This study included two groups of animals; one of them kept as a control one (n.=16) and the other was a diseased group (n.= 12). All animals were subjected to clinical examination, whole blood profiling, blood serum biochemical assay, radiography and ultrasonographic examination. Rumenotomy was carried out in some cases. The reticulum was mostly displaced in cases of complicated TRP by a distance of 3-6 cm. Sometimes, the reticulum was not displaced such as in case of diaphragmatic hernia. The reticular contractions in the complicated traumatic cows were either reduced to 2 or 1/3mins, or completely reduced to 0/3mins. Reticular abscess and peritoneal effusions were imaged in all these diseased cases. Here, Vagus indigestion syndrome and diaphragmatic hernia were successfully diagnosed by using of ultrasonography with the aid of radiography and rumenotomy. Ultrasonography was useful in imaging non metal objects (Ropes and plastic tubes) within the rumen especially in cases of severe ruminal distension.

Introduction

Bovine practitioners face daily three challenges; they must reach the correct diagnosis, select the clinical management and keep up to date with useful advances in veterinary medicine (Sackett *et al.*, 1991).

The cause of ruminant stomach diseases and the rumenotomy operation indicated the usual and common finding of foreign bodies collected with nails, wire, ropes, plastic bags and rugs. Unfortunately the problem of ingestion of sharp or blunt bodies is still the major problem facing the bovine producers all over Egypt and constitutes the major part in economic losses to the farmers and their

farms which reflected on national economy (El-Sebaie, 2008).

Preliminary diagnosis of digestive disorders in ruminants could be achieved by ordinary diagnostic procedures such as visual inspection, palpation, percussion and auscultation, still as usual as basic methods (Rosenberger, 1979; Kelly, 1984; Rados-tits *et al.*, 1994).

During the recent years, some progress has been made in understanding clinical reasons and clinical interference. Special attention has been paid to principles of diagnostic thinking process and diagnostic methods. The ultrasonound applications in cattle included diagnosis of cardiac (Schweizer *et al.*, 2003), abdominal (Braun *et al.*, 1993a,b; Hassel *et al.*, 1995; Kim *et al.*, 1996; Pusterla and Braun, 1997; Braun *et al.*, 1997a,b; Braun *et al.*, 1998a,b)

*Corresponding author: Arafat A, Khalphallah
E-mail address: arafatvet2003@yahoo.com

and musculoskeletal disorders (Kofler, 1996).

Radiography is an efficient technique for identifying metal foreign bodies, whereas ultrasonography rarely identifies metallic objects, including magnets. Radiography is best suited for the detection of metallic foreign bodies inside and outside the reticulum, and the position of the foreign body is the most reliable indicator for diagnosing traumatic reticuloperitonitis (TRP) by radiography. In contrast, ultrasonography is the method of choice for detecting fibrinous deposits and abscesses that cannot be detected by using radiography. Although neither radiography nor ultrasonography alone achieve a complete definitive diagnosis of TRP, the two tools supported each other (Braun *et al.*, 1994; Kaske *et al.*, 1994).

This study described the most common ultrasonographic findings associated with complicated problems of TRP in cattle and aimed to establish cooperation between the traditional diagnostic techniques such as clinical examination, laboratory analysis and radiography, and ultrasonography in bovine medicine.

Materials and methods

This study was carried out on twenty-eight cows that were classified into two groups; one of them was kept as a control group and included sixteen animals while the other included twelve animals and was kept as complicated TRP diseased cows. The control group was selected from healthy non-pregnant female cattle that belonged to the Veterinary Teaching Hospital. The diseased cows were submitted to the Veterinary Teaching Hospital, Faculty of Veterinary Medicine, Assiut University, Egypt.

All animals were treated in accordance with guidelines established by faculty of veterinary medicine, Assiut University Committee on Animal Care, Egypt. Clinical examination of all animals was done according to Rosenberger (1990). Whole blood samples were collected on EDTA and stored at 4 °C until analysis, while blood serum samples were collected on plain vacutainer tubes, serum samples were separated and stored at -20°C until analysis according to Coles (1986).

Hematological pictures included red blood cells (RBCs) count, packed cell volume (PCV), haemoglobin concentration (Hb) and total white blood cells (T.WBCs) count were determined by using

electronic cell counter (ABBOTT Cell Dyne 1700). Differential leucocytic count (DLC) was determined using four field meander method (Kelly, 1984).

Determination of blood serum levels that included; liver enzymes according to Sherwin (1984) for aspartate aminotransferase (AST), according to Shaw *et al.* (1983) for γ -glutamyl transferase (GGT) and according to Moss (1982) for alkaline phosphatase (AP), Serum total protein according to Tietz (1994), Serum albumin according to Tietz (1990), serum globulin by subtraction of albumin from total protein, albumin/globulin ratio, cholesterol according to Ellefson and Caraway (1976) and triglycerides (TG) according to Stein (1987) by using digital ultraviolet spectrophotometer (Digital ultraviolet spectrophotometer, CE 292, series 2, Cecil instruments, Cambridge England) and commercial kits (Spectrum Diagnostic, Egypt).

Radiographic examination was carried out for all animals according to the method of Nägeli (1991); Braun *et al.* (1993a). Diseased and healthy cattle were examined ultrasonographically according to Braun (1990); Braun and Gotez (1994); Wild (1995); Braun *et al.* (2001) by using a 3.5 MHz Sector transducer of apparatus (FF Sonic, Model UF-4000, Tokyo, Japan) to detect either the normal organs in the control animals or the affected organs in the diseased cows.

Rumenotomy was performed after radiography and ultrasonography in some TRP diseased animals to remove the metal objects or the other foreign materials inside the rumen.

Statistical analysis

Statistical analysis for the obtained data was done through analysis of variance and by using software computer program (Spsswin, 1997). Significance was declared at $P < 0.05$. The significance of differences between the means at control group and diseased group were evaluated by Dunnett's test. Means and standard deviation shown in Tables were calculated from the original data.

Results

History and clinical findings

History and clinical signs of the complicated TRP cases indicated that cows showed reduced ap-

petite to off food, sometimes were associated with recurrent tympany and showed bilateral symmetrical distension of the flank regions. They showed tucked up appearance, pain sensation on palpation with gait ranged between normal, reluctant to move and recumbency. Rectal examination showed empty rectum with distended rumen and failure of palpating any loops of small intestine or large intestine. Mucous membranes and conjunctiva were congested and episcleral capillaries were usually engorged. Mine detector was either positive or negative. In cases of intestinal involvement, the animals suffered from no defecation or even difficult defecation associated with straining. Body temperature, heart rate and respiration were elevated with reduced to absent ruminal motility. Abnormal heart sounds (machinery murmurs or muffling sound) were heard in some cases with tachycardia or bradycardia.

Blood picture and serum biochemical analysis

Blood picture indices (Table 1) in case of complicated TRP cases indicated leucocytosis with neutrophilia, shift to the left with insignificant decrease in T.RBCs and PCV, when compared with those of control cattle.

Serum biochemical analysis (Table 2) revealed significant ($P < 0.05$) increase in serum activities of GGT, AST and AP in diseased cattle when compared with those of control group. Diseased cattle

had insignificant increase in serum levels of total protein and globulin ($P < 0.05$) with decreased albumin. Serum level of cholesterol was significantly ($P < 0.05$) increased while serum level of triglycerides was decreased in complicated TRP cows when compared with those of healthy cattle.

Radiographic findings

Radiographic findings of reticulum in control cows showed that the reticulum was free from any metal objects. The diaphragm was imaged as a clear black well-identified line between two radio-opaque structures; reticulum and heart. The heart that appeared as radio-opaque with clear margins, normal size and a characteristic shape (Fig. 1). Radiography was helpful in the diagnosis of traumatic reticuloperitonitis and pericarditis in cases of complicated TRP cases. It showed enlargement of the heart, diaphragm margins were easily identified; reticulum and rumen were free from any metal objects (Fig. 2). Radiography sometimes showed heart of normal size with presence of diaphragmatic hernia (Fig. 3).

Rumenotomy

Rumenotomy that was performed in a case of the diseased group indicated severe ruminal distension and diaphragmatic hernia with removal of plastic tubes, rugs, ropes, wires and stones.

Table 1. Mean values for parameters of the blood picture in control and diseased cattle

	T.RBCs (T/L)	PCV (%)	Hb (g/L)	T.WBCs (G/L)	Neutrophiles (%)	Lymphocytes (%)	Monocytes (%)	Eosinophiles (%)	Band cells (%)
Control (n= 16)	8.3±2.06	38.25±1.15	129.9±3.60	7.11±1.24	26.56±4.13	62.38±3.23	6.75±2.63	3.31±0.07	1.40±0.52
Complicated TRP Cases (n=12)	5.06±1.80	25.59±2.02	121.8±8.56	20.58±3.56*	46.33±5.01*	40.08±6.24*	6.42±1.06	2.42±0.86	4.75±0.42*

Values with asterisks (*) within the same column are significantly different ($P < 0.05$). TRP: traumatic reticuloperitonitis. T.RBCs: total red blood corpuscles. PCV: packed cell volume. Hb: haemoglobin concentration. T.WBCs: total white blood cells count.

Table 2. Mean values of blood serum biochemical parameters in control and diseased cattle

	Total proteins (g/L)	Albumin (g/L)	Globulin (g/L)	A/G ratio	GGT (U/L)	AP (U/L)	AST (U/L)	Cholesterol (mmol/L)	TG (mmol/L)
Control (n= 16)	103.0±8.16	61.0±4.56	42.3±4.36	1.86±0.59	17.03±2.26	36.36±5.26	36.04±4.02	112.5±9.14	3.77±0.6
Complicated TRP Cases (n=12)	107.1±6.4	38.6±5.36*	68.5±7.02*	0.56±0.24*	25.28±3.14*	57.68±4.36*	57.6±6.84*	145.1±11.61*	2.44±0.68

Values with asterisks (*) within the same column are significantly different ($P < 0.05$). TRP: traumatic reticuloperitonitis. A/G ratio: albumin/Globulin ratio. AST: aspartate aminotransferase. AP: alkaline phosphatase. GGT: γ -glutamyl transferase. TG: triglycerides.

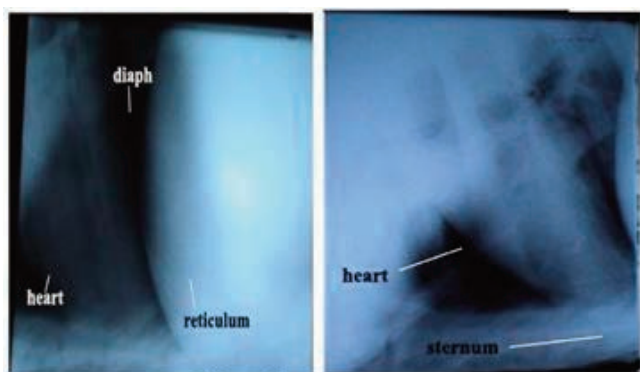


Fig. 1. Normal radiography of reticulum and heart in cattle. Lateral radiographic views of the cranial abdomen and the thorax of 4 years non-pregnant cattle showed normal radiographic appearance of reticulum, heart and diaphragm.

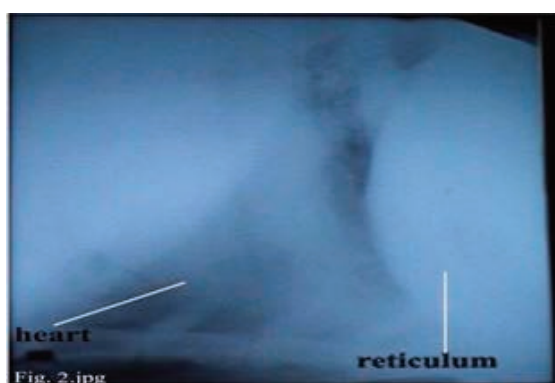

Fig. 2. Radiography in a heifer with traumatic reticulo-pericarditis. Lateral radiographic view of the thorax showed evidences of adhesions between the heart and both of the diaphragm and reticulum. Diaphragm margins were ill-defined. Reticulum and rumen were free from any metal foreign bodies.

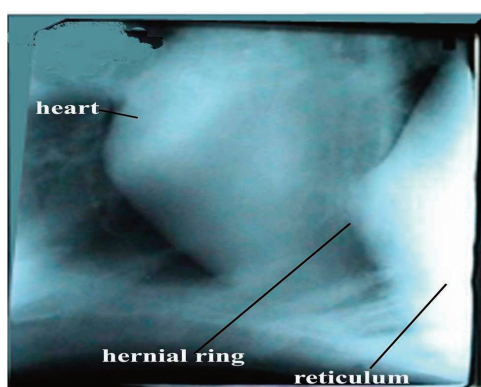


Fig. 3. Radiography in a heifer with traumatic reticulitis and diaphragmatic hernia. Lateral radiographic view of the thorax showed diaphragmatic hernia. The diaphragm is well-identified. The heart was radiopaque and with clear margins.

Ultrasonographic findings

TRP was imaged as echogenic fibrinous deposits interspersed with hypoechoic pockets of fluids (Fig. 4), while the reticular abscess was imaged as an echogenic capsule with anechoic contents caudoventral to the reticulum (Fig. 5). Peritoneal

effusions visualized as fibrinous echogenic deposits restricted to reticular area and surrounded by hypoechoic exudates (Fig. 6).

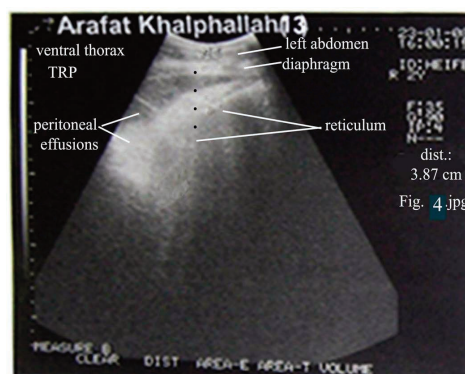


Fig. 4. Ultrasonogram in a heifer with traumatic reticuloperitonitis showed deformity in the reticular serosa and its contour with accumulation of echogenic fibrinous deposits cavitated by hypoechoic exudates.

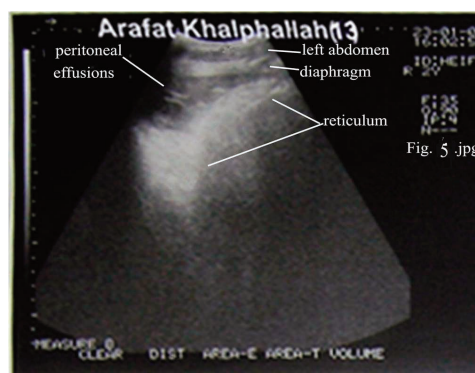


Fig. 5. Ultrasonogram of a cow with traumatic reticuloperitonitis showed peritoneal effusion caudoventral and cranioventral to reticulum and restricted to reticular area appeared as echogenic fibrinous deposits surrounded by anechoic, hypoechoic or moderately echogenic contents.

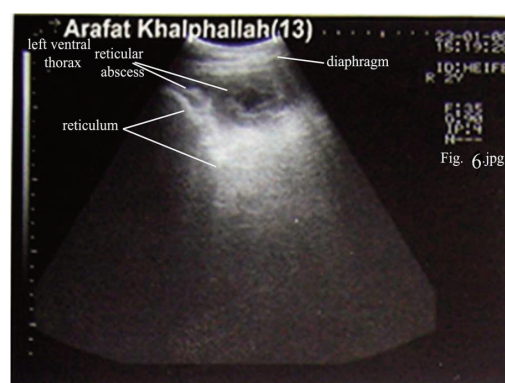


Fig. 6. Ultrasonogram in a cow with traumatic reticuloperitonitis showed reticular abscess imaged with its echogenic capsule and its hypoechoic contents and anechoic center causing distal acoustic shadowing.

The reticulum was mostly displaced in cases of complicated TRP by a distance of 3-6 cm. Sometimes, the reticulum was not displaced such as in case of diaphragmatic hernia. The reticular contrac-

tions in the complicated traumatic cows were either reduced to 2 or 1/3 minutes (In which the heart was not affected as in case of Diaphragmatic hernia), or completely reduced to 0/3 minutes (In which the heart and spleen were affected).

Suppurative pericarditis in some of these diseased cases was imaged as accumulation of hypoechoic to anechoic exudates and gases around the heart (In the pericardium) with increasing in echogenicity of the heart and deposition of echogenic fibrinous deposits on cardiac valves with cardiomegally. Severe, strong and rapid contraction of the myocardium or reduction of the heart contractility was observed as in M-mode (Fig. 7).

Spleen that was involved in traumatic reticuloperitonitis appeared surrounded by echogenic deposits and hypoechoic fluids between spleen and reticulum and/or craniodorsal blind sac of the rumen and between spleen & abdominal wall (Fig. 8).

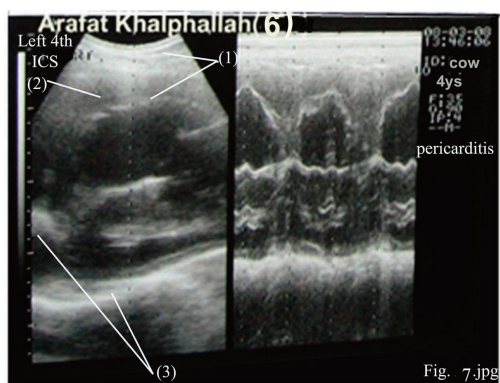


Fig. 7. Ultrasonogram of a cow with traumatic pericarditis showed cardiomegally, thickening in the wall of the heart with increasing of its echogenicity. Imaging of hypoechoic exudates in the pericardium and echogenic threads within the myocardium. 1- Hypoechoic to anechoic exudates in the pericardium. 2- Thickening of the heart wall. 3- Deposition of echogenic fibrinous deposits within the heart and on its wall with cardiomegally.

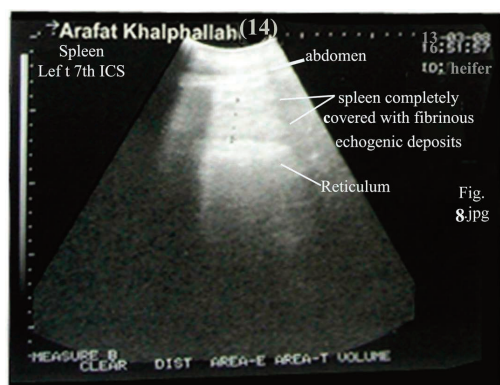


Fig. 8. Ultrasonogram in a heifer with Spleen involved in traumatic reticuloperitonitis. It was surrounded by echogenic deposits and hypoechoic fluids between spleen and reticulum and/or craniodorsal blind sac of the rumen and between spleen & abdominal wall.

Vagus indigestion (Functional stenosis) either in anterior form or posterior form was diagnosed as a sequellae to complicated TRP. Vagus indigestion syndrome that included TRP, frothy ruminal tympany (Sever ruminal distension) and diaphragmatic hernia in anterior form; and TRP, ileus of intestine and abomasal dilatation in posterior form was successfully diagnosed in the current study by using of ultrasonography and the aid of radiography and rumenotomy.

Severe ruminal distension was imaged from the left and right last three intercostals spaces (ICSs) and from the left and right flank regions dorsally and ventrally. It showed echogenic elongated thin structures (The ropes and plastic tubes in the rumen) (Fig. 9). In case of diaphragmatic hernia, the reticulum was imaged immediately adjacent to the diaphragm and appeared as an echogenic line imaged adjacent to the distinct heart margins and ventral to the heart (Fig. 10).

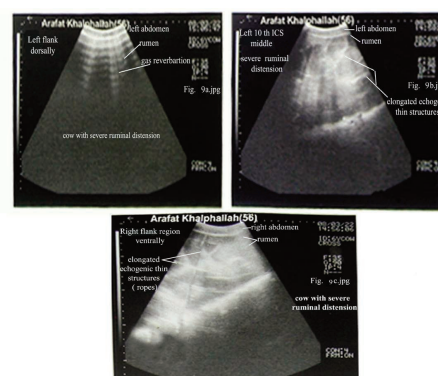

Fig. 9. Ultrasonogram in cow with severe ruminal distension, mild traumatic reticulitis showed distended rumen that filled the right abdominal region and the right last three intercostals spaces dorsally (Fig. 9a) that prevent imaging of the liver, and ventrally (Fig. 9b, c) that prevent visualization of the small and large intestine.

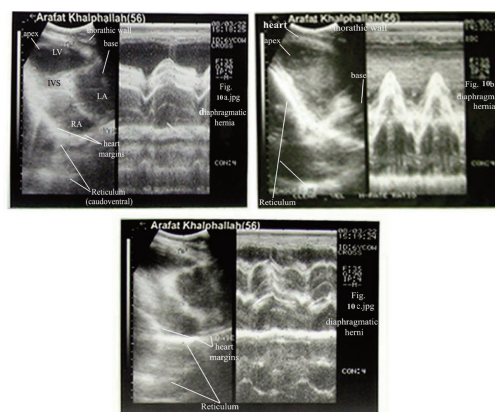


Fig. 10a, b, c. Ultrasonogram in cow with diaphragmatic hernia. The reticulum was imaged immediately adjacent to the diaphragm and appeared as an echogenic line imaged adjacent to the distinct heart margins and ventrally to the heart. This echogenic line contracted with the heart. The heart was strongly and regularly contracted, and of clear margins.

Abomasal dilatation as a sequellae to TRP and vagus indigestion was diagnosed by using ultrasonography. The abomasal dilatation was either due to ileus of small intestine or pyloric stenosis i.e. Visualization of dilated abomasum with narrowing of the pylorus (Fig. 11a). The dilated abomasum was visualized from the distal part of the last three ICSs and to the right from the ventral midline or caudal to the last rib and to the right from the ventral midline where the abomasum was not torsed or displaced. It lost its heterogenic nature and its contents were imaged as hypoechoic contents with visualization of its abomasal folds as thin elongated sickle shaped structures (Fig. 11b).

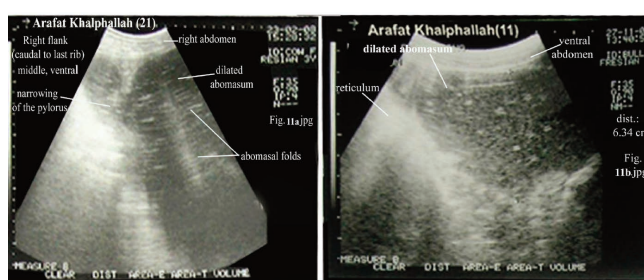


Fig. 11. Ultrasonogram in a heifer showed abomasal dilatation. It was imaged from distal part of the last three ICSs and to the right from the ventral midline or caudal to the last rib and to the right from the ventral midline. Visualization of dilated abomasum with narrowing of the pylorus (Fig. 11a). It lost its heterogenic nature and its contents were imaged as hypoechoic contents with visualization of its abomasal folds as thin elongated sickle shaped structures (Fig. 11b).

Discussion

History and clinical findings of the complicated cases matched with Smith and Slenning (2000); Hawkins (2002). Blood picture indices in case of complicated group indicated leucocytosis with neutrophilia associated with shift to the left with decreased T.RBCs count and PCV %, which agreed with Blood and Radostits (1989); Braun *et al.* (1998b); Smith and Slenning (2000).

Serum biochemical analysis of the complicated cases showed an increase ($P < 0.05$) in serum activities of GGT, AST and AP. They also showed increased serum levels of total protein, and globulin ($P < 0.05$) with decreased albumin. The serum levels of cholesterol increased ($P < 0.05$) while serum levels of triglycerides decreased. The previous results agreed with those of Smith (1993); Smith and Slenning (2000) that stated that there is an increase in total plasma protein and plasma fibrinogen lev-

els among cattle with TRP and those with other gastrointestinal diseases. Meanwhile, Benjamin (1985) reported that the changes in haemological values and biochemical parameters such as elevation of fibrinogen, aspartate aminotransferase and alkaline phosphatase were suggestive of inflammatory changes in the body not only TRP/TP.

Ultrasonography could diagnose these complicated cases that include TRP, TRP-TP, reticular abscess, peritoneal effusions, splenic abscess and sometimes associated with frothy ruminal tympany, abomasal dilatation and/or diaphragmatic hernia. Spleen was involved in traumatic reticuloperitonitis that appeared surrounded by echogenic deposits and hypoechoic fluids between spleen and reticulum and/or craniodorsal blind sac of the rumen and between spleen and abdominal wall. These results agreed with Braun *et al.* (1993b); Braun and Götz (1994). The reticular abscess was imaged as an echogenic capsule with anechoic contents caudoventral to the reticulum producing distal acoustic shadowing. These findings agreed with Braun *et al.* (1993b). Peritoneal effusions visualized as fibrinous echogenic deposits restricted to reticular area and surrounded by hypoechoic exudates caudoventral and cranioventral to it that agreed with Braun *et al.* (1993b). The reticulum was either displaced in cases of complicated TRP cases by a distance of 3-6 cm or not displaced as in case of the diaphragmatic hernia. The reticular contractions in the complicated traumatic cows were either reduced to 2 or 1/3mins (In which the heart was not affected such as in case of Diaphragmatic hernia) or completely reduced to 0/3mins (In which the heart and spleen were affected). Suppurative pericarditis was imaged as accumulation of exudates and gases around the heart with increase in echogenicity of the heart and deposition of echogenic fibrinous deposits on cardiac valves with cardiomegally. Sever strong rapid contraction of the myocardium or reduction of the heart contractility was observed as in M-mode. These results agreed with Schweizer *et al.* (2003).

Vagus indigestion (Functional stenosis) either in anterior form or posterior form was diagnosed as sequellae to complicated TRP. Vagus indigestion syndrome that included TRP, frothy ruminal tympany (Sever ruminal distension) and diaphragmatic hernia in anterior form; and TRP, ileus of intestine and abomasal dilatation in posterior form was successfully diagnosed in this current study by using

of ultrasonography with the aids of radiography and rumenotomy.

Ultrasonography was helpful in diagnosis of sever ruminal distension (Frothy ruminal tympany) associated with diaphragmatic hernia and mild traumatic reticulitis with the aid of radiography and rumenotomy. This case was of healthy heart and no peritonitis. The severely distended rumen was imaged from the left and right last three ICSs and from the left and right flank regions dorsally and ventrally showed echogenic elongated thin structures (Ropes and plastic tubes in the rumen). Visualization of these foreign materials (Ropes and plastic tubes in the rumen) within the rumen either ultrasonographically, radiographically or even by using mine detectors, was not reported before. In case of diaphragmatic hernia, the reticulum was imaged immediately adjacent to the diaphragm and appeared as an echogenic line imaged directly closely adjacent to the distinct heart margins and ventral to the heart. This echogenic line which represented the reticular serosa was moving separately and simultaneously with the contractions of the heart. It was diagnosed as recently occurred diaphragmatic hernia (Of six fingers width) and the echogenic line was the reticular serosa which passed through the diaphragmatic hernial ring.

Abomasal dilatation was diagnosed using ultrasonography. It was either due to ileus of small intestine or pyloric stenosis (Visualization of dilatation of the abomasum with narrowing of the pylorus). In case of abomasal dilatation due to ileus of small intestine, dilated loops of the small intestine were imaged while in case of abomasal dilation due to pyloric stenosis (Either mechanical or functional pyloric stenosis); empty loops of small intestine were visualized. The dilated abomasum was visualized from the distal part of the last three ICSs, and to the right from the ventral midline or caudal to the last rib, and to the right from the ventral midline as the abomasum was not torsed or displaced while the abomasum lost its heterogenic nature and imaged as hypoic echoic contents with visualization of its abomasal folds as thin elongated sickle shaped structures and that agreed with Braun *et al.* (1995); Braun *et al.* (1997b).

Ultrasonography could be used in some cases of complicated TRP, with cooperation of x-ray films for the diagnosis of TRP and TP. Radiography in case of TRP showed that the presence of foreign objects e.g. nails, needles and other metal materials

could give indication about the nature of the traumatic cause. Radiography failed to identify inflammatory changes that occurred on the reticular serosa or reticular abscesses. Radiography in some traumatic cases failed to show any abnormalities in the heart or reticulum; however ultrasonography in these cases was diagnostic and showed fibrinous inflammatory changes on the reticular serosa. At the same time, Ultrasonography failed to visualize metal objects inside or outside the reticulum. These results agreed with Braun *et al.* (1993a); Braun *et al.* (1994); Braun *et al.* (2002).

Conclusion

Ultrasonography is considered an important diagnostic tool in disease of digestive system in cattle with the aids of other diagnostic tool such as clinical findings, laboratory analysis and radiography. The present work could diagnose complicated TRP cases and their squellae and abomasal dilatation. Vagus indigestion syndrome and diaphragmatic hernia were successfully diagnosed by using of ultrasonography with the aid of radiography and rumenotomy. Ultrasonography is useful in imaging non metal objects (Ropes and plastic tubes) within the rumen especially in cases of severe ruminal distension.

Acknowledgement

Great thanks to Department of Animal Surgery, and Department of Theriogenology, Faculty of Veterinary Medicine, Assiut University, Egypt, for their help and great cooperation in this study.

References

- Benjamin, M.M., 1985. Outline of Veterinary Clinical Pathology. 3rd ed. Kalyan publishers, New Delhi. pp. 291.
- Blood, D.C., Radostits, O.M., 1989. Veterinary Medicine. 7th ed. Baillière Tindall, London. pp. 254.
- Braun, U., 1990. Ultrasonographic examination of the liver in cows. American Journal of Veterinary Research 51, 1522-1526.
- Braun, U., 1997. Atlas und Lehrbuch der Ultraschalldiagnostik beim Rind. Parey Buchverlag, Berlin.
- Braun, U., Götz, M., 1994. Ultrasonography of the reticulum in cows. American Journal of Veterinary Research 55, 325-332.
- Braun, U., Flückiger, M., Nägeli, F., 1993a. Radiography as an aid in the diagnosis of traumatic reticuloperitonitis in cattle. The Veterinary Record 132, 103-109.

- Braun, U., Götz, M., Marmier, O., 1993b. Ultrasonographic findings in cows with traumatic reticuloperitonitis. *The Veterinary Record* 133, 416–422.
- Braun, U., Flückiger, M., Götz, M., 1994. Comparison of ultrasonographic and radiographic findings in cows with traumatic reticuloperitonitis. *The Veterinary Record* 135, 470–478.
- Braun, U., Marmier, O., Pusterla, N., 1995. Ultrasonographic examination of the small intestine of cows with ileus of the duodenum, jejunum or ileum. *The Veterinary Record* 137, 209–215.
- Braun, U., Wild, K., Guscetti, F., 1997a. Ultrasonographic examination of the abomasum of 50 cows. *The Veterinary Record* 140, 93–98.
- Braun, U., Pusterla, N., Schönmann, M., 1997b. Ultrasonographic findings in cows with left displacement of the abomasum. *The Veterinary Record* 141, 331–335.
- Braun, U., Iselin, U., Lischer, C., Fluri, E., 1998a. Ultrasonographic findings in five cows before and after treatment of reticular abscesses. *The Veterinary Record* 142, 184–189.
- Braun, U., Pusterla, N., Anliker, H., 1998b. Ultrasonographic findings in three cows with peritonitis in the left flank region. *The Veterinary Record* 142, 338–340.
- Braun, U., Schweizer, T., Pusterla, N., 2001. Echocardiography of the normal bovine heart: technique and ultrasonographic appearance. *The Veterinary Record* 148, 47–51.
- Braun, U., Schweizer, G., Flückiger, M., 2002. Radiographic and ultrasonographic findings in three cows with reticulo-omasal obstruction due to a foreign body. *The Veterinary Record* 150, 580–581.
- Coles, E.H., 1986. *Veterinary Clinical Pathology*. 4th ed. Saunders Company, Philadelphia, USA.
- Ellefson, R.D., Caraway, W.T., 1976. *Fundamentals of Clinical Chemistry*. Ed Tietz NW. pp. 506.
- El-Sebaie, A.H., 2008. Impact of environmental pollution on animal health and its reflection on the national economy in Egypt. In: *Proceeding of Alexander von Humboldt colleagues meeting in Khartoum, Sudan*.
- Hassel, D., Tyler, J.W., Tucker, R.L., Sondhof, A.F., 1995. Urachal abscess and cystitis in a calf, *Journal of Veterinary Internal Medicine* 9, 286–288.
- Hawkins, L.L., 2002. Bovine Digestive Diseases In: *Large Animal Digestive Diseases notes*. LAMS 5350, 22–24.
- Kaske, M., Midasch, A., Rehage, J., 1994. Sonographic investigation of reticular contractions in healthy sheep, cows, and goats and in cows with traumatic reticuloperitonitis. *Journal of Veterinary Medicine, Series A* 41, 748–756.
- Kay, R.N.B., 1983. Rumen function and physiology. *The Veterinary Record* 113, 6–9.
- Kelly, W.G., 1984. *Veterinary Clinical Diagnosis*. 3rd ed. Bailliere Tindall, London.
- Kim, M., Hwang, K., Byun, H., Park, K., Lee, K., Han, Y., Shin, S., 1996. Ultrasonographic appearance of the urinary organs in native Korean cattle. *Korean Journal of Veterinary Clinical Medicine* 13, 103–107.
- Kofler, J., 1996. Arthrosonography: the use of diagnostic ultrasound in septic and traumatic arthritis in cattle—a retrospective study of 25 patients. *British Veterinary Journal* 152, 683–698.
- Moss, D.w., 1982. Alkaline phosphatase isoenzymes. *Clinical Chemistry* 28, 2007–2016.
- Nägeli, F., 1991. *Disseration, Veterinär-Medizinische Fakultät der Universität Zürich*.
- Pusterla, N., Braun, U., 1997. Ultrasonic Examination of The pancrease in healthy cows, *Veterinary Radiology & Ultrasound* 38, 1, 63–67.
- Radostits, O.M., Blood, D.C., Gay, C.C., 1994. *Veterinary Medicine. A text book of the diseases of cattle, sheep, pigs, goats and horses*, 8th ed. Baillière Tindall, London. pp. 323.
- Rosenberger, G., 1979. *Clinical examination of cattle*. Verlag Paul Parey, Berlin and Hamburg.
- Rosenberger, G., 1990. *Die Klinische Untersuchung des Rindes: 3. Auflage herausgegeben von Dirksen, G., GrÜnder H.-D and Stöber M. S. 670–677: Verlag Paul Parey, Berlin and Hamburg*.
- Sackett, D.L., Haynes, R.B., Guyatt, G.H., Tugwell, 1991. *Clinical Epidemiology; A basic Science for clinical medicine*. 2nd ed. Little, Brown amd Co., Boston.
- Schweizer, T., Sydler, T., Braun, U., 2003. Kardiomyopathie, Endokarditis valvularis und Perikarditis traumatica beim Rind – Klinische und echokardiographische Befunde an drei Fallberichten. *Schweiz Arch Tierheilk* 145, 425–430.
- Shaw, M., Stromme, J.H., London, J.L., Theodorsen, L., 1983. IFCC method for g-glutamyl transferase {(g₂ glutamyl)–peptide: amino acid g-glutamyl tranerase, EC 2.3.2.2}. *Clinica Chimica Acta* 135, 315–338.
- Sherwin, J.E., 1984. Liver function. In: *Clinical Chemistry, Theory Analysis, and Correlation (L.A., PESCE, A.J., eds)*. Mosby Company, St. Louis, Philadelphia, USA. pp. 420–438.
- Smith, B.P., 1993. *Text book of Large Animal Internal Medicine*. 1st ed. St. Louis. C.V. Mosby Company, Philadelphia. pp. 348–367.
- Smith, R.D., Slenning, B.D., 2000. Decision analysis: dealing with uncertainty in diagnostic testing. *Preventive Veterinary Medicine* 45, 139–162.
- Spsswin, 1997. *Software program for statistical analysis under Windows, USA*.
- Stein, E.A., 1987. Lipids, lipoproteins, and apolipoproteins. In: *NW Tietz, ed. Fundamentals of Clinical Chemistry, 3rd ed. WB Saunders, Philadelphia, USA. pp. 448*.
- Tietz, N.W., 1990. *Clinical Guide to Laboratory Tests*. 2nd ed. WB Saunders, Philadelphia, USA. pp. 26–29.
- Tietz, N.W., 1994. *Fundamentals of Clinical Chemistry*. 2nd ed. NW Tietz, editor. pp. 692.
- Wild, K., 1995. *Sonographische Untersuchungen am Labmagen des Rindes*. Thesis, Dr Med Vet, Faculty of Veterinary Medicine, University of Zurich.