



## Comparison of Three Techniques for Arthrocentesis of the Carpal Joint in Dromedary Camels: A Prospective Study

Adel M. Badawy<sup>1</sup>, Eman A. Eshra<sup>2\*</sup>

<sup>1</sup>Department of Veterinary Surgery, Anesthesiology and Radiology, Faculty of Veterinary Medicine, Benha University, 13736, Egypt.

<sup>2</sup>Department of Anatomy and Embryology, Faculty of Veterinary Medicine, Benha University, 13736, Egypt.

### ARTICLE INFO

#### Original Research

#### Received

19 February 2016

#### Accepted:

27 March 2016

#### Keywords:

Arthrocentesis  
Camel  
Dromedary  
Carpus  
Joint capsule

### ABSTRACT

The aim of this prospective study was to determine the appropriate approaches for arthrocentesis of the carpal joint in dromedary camels and to compare between these approaches with regard to their success rate, feasibility, accuracy and ease of performance. Twenty-two cadaveric camel forelimbs obtained from 11 camel cadavers, and 4 living camels (6 joints) underwent arthrocentesis for therapeutic and diagnostic purposes, were used in this study. For studying gross anatomy of the suggested approaches, 4 forelimbs were used. For CT anatomy 3 forelimbs (one/each technique) were scanned before and after injection of iodinated contrast medium. For *in-vitro* evaluation of the techniques 15 forelimbs were used (5/each technique). To test the ease of performance in the living camels, arthrocentesis of 6 joints in 4 camels was performed by a single operator while the animal sited in kneeling position (3 camels) and standing position (one camel). Based on the results, there were three feasible approaches for arthrocentesis of carpal joint in camel, the dorso-medial, dorso-lateral, and the lateral approaches. The dorso-medial approach was easily performed and more accurate than the other approaches. The dorso-medial approach was successful with accuracy index of 100% after the first attempts, whilst the dorso-lateral and the lateral approaches have lower rates of success. The procedure was well tolerated in all camels.

*J. Adv. Vet. Res.* (2016), 6 (2), 53-59

## Introduction

Camels (*Camelus dromedarius*) not only serve as a source of high quality meat, milk and leather, but also as riding or pack animals (Khan *et al.*, 2003). Camels have unique locomotor apparatus, enables them to be an excellent racing animals, well adapted to travel fast on sandy soil (Smuts and Bezuidenhout, 1987; Janis *et al.*, 2002; Khan *et al.*, 2003; Badawy, 2011).

Carpal joint of camel is a complex joint, which consists of three joints, radiocarpal, intercarpal, and carpometacarpal joints. It has three joint capsules,

the proximal and middle sacs are capacious and each forms a dorsal recess. The intercarpal and carpometacarpal joints communicate, whilst the radio-carpal joint has a separate sac (Smuts and Bezuidenhout, 1987; Kassab, 2008; Alsobayil *et al.*, 2015).

Camel carpus is able to extension and flexion (Roony, 1977; Smuts and Bezuidenhout, 1987; Kassab, 2008). The carpus extends during stance, allows the forelimb to act as a rigid strut as the body mass is propelled forward, and flexes in the swing phase to raise the foot clear of the ground (Roony, 1977). Camel carpus also flexes during recumbent or kneeling position, as the carpal joints are the first points touch the ground (Kassab, 2008). Carpal affections are common in camels be-

\*Corresponding author: Eman A. Eshra  
E-mail address: mevet213@gmail.com

cause of the prolonged pressure on the dorsal aspect of the joint when camels sit down or standing (Ramadan *et al.*, 1986; Kassab, 2008). The reported affections are mostly carpalitis and ulcerative dermatitis with high incidences in calves (Ramadan *et al.*, 1986; Khan *et al.*, 2003).

Arthrocentesis is a very useful procedure for both the diagnosis and treatment of carpalitis (Alsobayil *et al.*, 2015). In addition, it was commonly used for administration of the intra-articular medication (McIlwraith, 2010; Alsobayil *et al.*, 2015) and intra-articular anesthesia (Drevemo *et al.*, 1999; Tnibar *et al.*, 2015) as well as contrast medium used in diagnostic imaging (Gray *et al.*, 2013). Little is known about techniques of arthrocentesis in camels, as the published works are few (Smuts and Bezuidenhout, 1987; Alsobayil *et al.*, 2015), and did not provide detailed instructions important for accurate and safe arthrocentesis in this species. Despite the anatomical similarities of camel and ruminants carpus (Kassab, 2008), the sites used for joint puncturing in cattle are not suitable for camels (Nuss *et al.*, 2002; Alsobayil *et al.*, 2015). Anatomical peculiarities such as the carpal pad and the presence of two large tendon sheaths at the dorsal aspect of the camel carpus (Ramadan *et al.*, 1986; Smuts and Bezuidenhout, 1987), and the little anatomical information about the articular and periarticular anatomy of the carpal joint as well as the camel nervous temperament, make performance of arthrocentesis procedure challenging in this species.

This study was aimed to determine the appropriate sites for arthrocentesis of carpal joint in dromedary camels, with regard to their peculiar periarticular and articular anatomy. It also aimed to compare between these sites on basis of their success rate, feasibility, accuracy and ease of performance.

## Materials and methods

### Animals

All the study procedures were approved by the Animal Care Committee of Benha University, Egypt and in accordance with Egyptian ethical code for studies on experimental animals.

Twenty-two forelimbs were used for determination and for *in-vitro* evaluation of the arthrocentesis techniques; the limbs were harvested 10 cm above

the carpal joint from 11 apparently healthy camels (*Camelus dromedarius*), 6 males and 5 females, aged, 3-5 years. All limbs were obtained from Shebien-Elkanater and Toukh abattoirs, Qaliobia, Egypt.

For *in-vivo* evaluation, arthrocentesis were performed in 6 joints of 4 camels (3 calves, one female) for diagnosis and treatment of carpalitis.

### Gross and CT anatomy

Seven of the cadaveric forelimbs were used, 4 for gross anatomy and 3 for Computed tomography (CT).

For CT examination, one limb for each technique was scanned before and after injection of iodinated contrast medium (150 mg of I/ml), (Ioversol, Optiray<sup>TM</sup> 300, NDC, 0019-1332-06, 12550612, Mallinckrodt Inc. Hazelwood, MO 63042, USA). The CT was performed by using a 64 detector row CT scanner (Somatom Sensation, Siemens Medical Solutions, Forchheim, Germany), at 130 kVp and 160 mAs. For the dorsal techniques, the limb was flexed, and tied by ropes as if it was in the kneeling position (2 limbs), but for the lateral approach it was kept extended (1 limb), then  $66.6 \pm 2.10$  ml of the contrast medium was injected into the radiocarpal joint, and  $40.0 \pm 1.05$  ml into the intercarpal joint using a 22-gauge, 1.5 inch hypodermic needle. All CT images were reformatted in dorsal and saggittal planes by use of software (Syngo CT 2006G, ICS VB28B, Siemens, Munich, Germany).

### Evaluation of arthrocentesis approaches

Fifteen forelimbs were injected to evaluate the techniques with regard to the ease of performance and the accuracy (5 limbs /each technique). For the dorsal suggested techniques, each forelimb was held by the assistant as if the camel was in kneeling position (flexed), and for the lateral technique one limb hold in standing position (extended), 22 gauges, and 1.5 inch needle was used. As each technique was performed, the number of attempts needed to reach the capsular recesses with the needle was recorded. The needle was judged to be within the capsular recess, then injection of  $66.6 \pm 2.10$  ml,  $40.0 \pm 1.05$  ml saline (0.9 % Na Cl) was done into the radiocarpal, the intercarpal joint respectively, which resulted in visible distension of

the joint and fluid could be retrieved following injection. In case that the aspiration was not successful, the position of the needle was slightly corrected in proximal or distal directions, then the injection trial repeated.

For *in-vivo* evaluation of the techniques, arthrocentesis was performed in 6 joints of 4 camels. All camels were undergoing arthrocentesis for therapeutic or diagnostic purposes. For each technique, all camels except one was restrained in kneeling position, no sedation was used, and the site of injection was clipped and aseptically prepared. A 22 gauges, and 1.5 inch needle was used for injection of 8 ml of Xylocaine 2%, or 4 ml of Gentamycin (50 mg/ml) into the joint. Camel tolerance to procedure, distension of joint before and after injection, number of attempts, and retrieval of synovial fluid were recorded.

#### Accuracy assessment

On basis of success rate and number of attempts, accuracy and ease of performance of each technique were assessed. The accuracy of each technique was confirmed using CT when the contrast medium was demonstrated within the palmar recesses. Accuracy percentage was calculated using the formula [(number of corrected attempts/ Total number of attempts)\*100].

## Results

#### Gross anatomy

Grossly, the carpal joints were capped externally by hard keratinized pads of skin, the carpal callosities (carpal pad). The subcutaneous tissue and the extensor retinaculum, were rich in fat, and surrounded externally by a fibrous joint capsule. The fibrous layer of the joint capsule was common for the three parts of the carpal joint and grooved dorsally for the following tendons: the extensor carpi radialis (medial), common digital extensor (middle) and the lateral digital extensor (lateral) (Figs. 1a-b). The synovial membrane formed three sacs corresponding to the three compartments of the carpal joint. The radiocarpal sac was the most voluminous, the intercarpal sac communicated between the bones of the two rows and the carpometacarpal sac was very limited (Fig. 1b).

The radiocarpal and intercarpal sacs formed a

dorsal recesses underneath the extensor retinaculum and in between the extensor tendons (Fig. 1b). Additionally, each joint formed a small palmar pouch which embedded underneath the flexor tendons (Fig. 2).

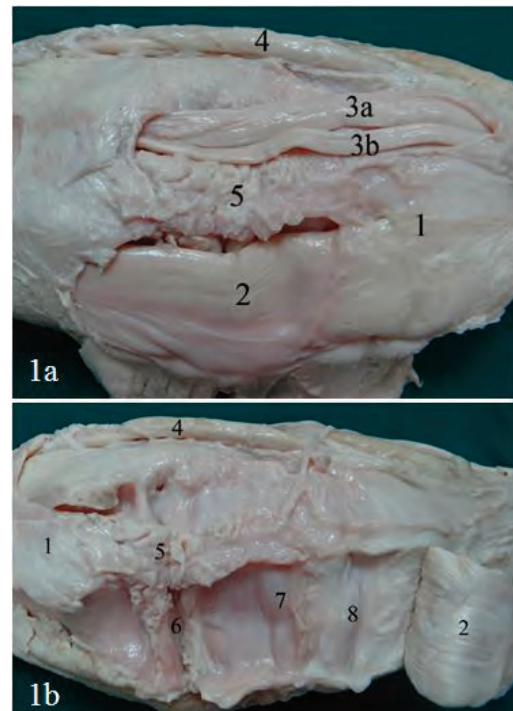


Fig. 1. A photograph of the extensor aspect of the carpal joint in camel. a) after removal of the skin and carpal pad, b) after reflection of two of the extensor tendons, identifying, extensor retinaculum (1), extensor carpi-radialis tendon (2), medial and lateral parts of common digital extensor tendon (3a, 3b), lateral digital extensor tendon (4), fat filling (5), dorsal recess of radio-carpal sac (6), dorsal recess of intercarpal joint sac (7), Carpo-metacarpal sac (8).

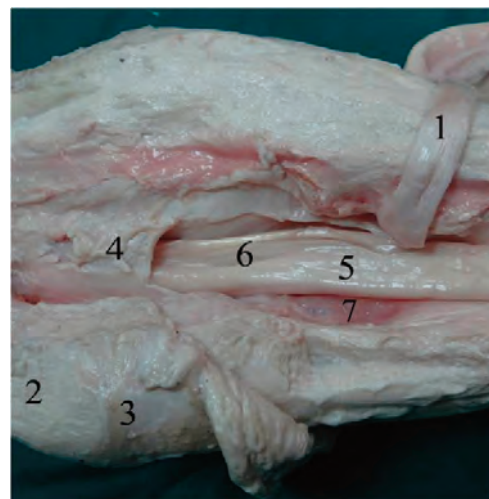


Fig. 2. A photograph of the flexor aspect of the carpal joint, the tendon of insertion of the flexor carpi radialis was reflected and the flexor retinaculum opened, identifying, tendon of insertion of M. flexor carpi radialis (1), tendon of insertion of M. ulnaris lateralis (2), tuberosity of accessory carpal bone (3), flexor retinaculum (4), superficial digital flexor tendon (5), deep digital flexor tendon (6), palmar recess of intercarpal sac (7).

*CT anatomy of the joint capsule*

CT findings were confirmed the aforementioned gross anatomical description of the joint capsule. Postcontrast CT images showed that, the intercarpal and carpometacarpal sacs are communicated, whilst the radiocarpal formed a separate sac (Figs. 3 and 4). The CT images also revealed the presence of a large pouch of the radiocarpal sac,

extended latero-palmarly at the level of the accessory carpal bone (Fig. 5). This pouch was bound by the contents of the carpal canal including, the median artery and nerve.

*Arthrocentesis approaches and techniques*

On basis of the anatomical and CT findings, dorso-medial, dorso-lateral and lateral approaches

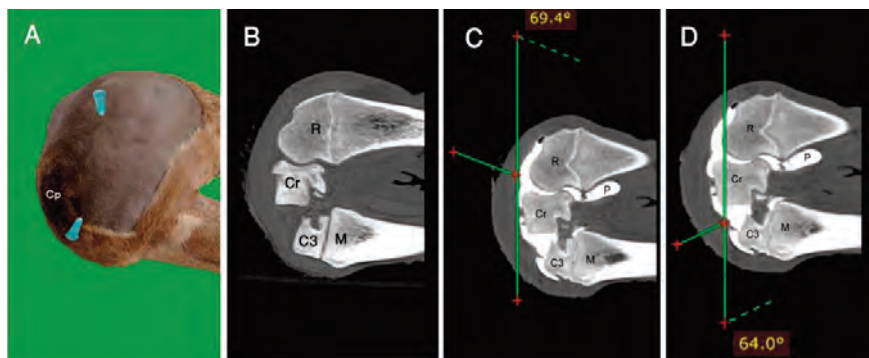


Fig. 3. Sites of needle placement for the dorsomedial approach of arthrocentesis of the carpal joint in camel (A). Pre-contrast reformatted parasagittal CT image of the medial side of the flexed camel carpal joint (B). Post-contrast reformatted parasagittal CT image of the flexed medial side of the carpal joint in camel after successful injection of the radiocarpal (C) and intercarpal (D) joints, identifying, carpal pad (Cp), radius (R), radial carpal bone (Cr), Third carpal bone (C3), Metacarpal (M), Palmar recess (P).

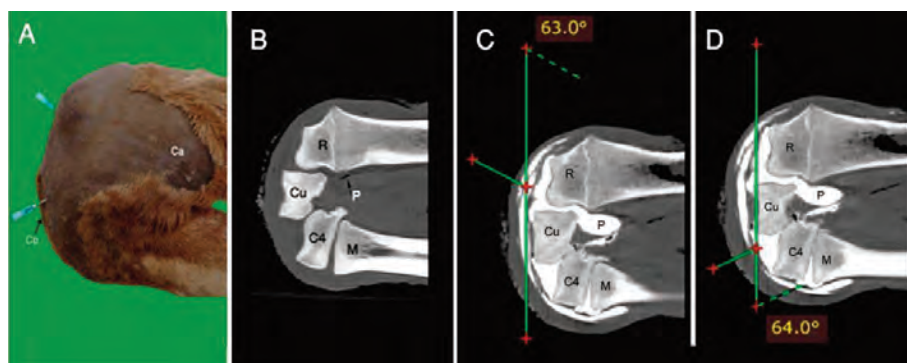


Fig. 4. Sites of needle placement for the dorsolateral approach of arthrocentesis of the carpal joint in camel (A). Pre-contrast reformatted parasagittal CT image of the lateral side of the flexed camel carpal joint (B). Post contrast reformatted parasagittal CT image of the lateral side of the flexed carpal joint in camel after successful injection of the radiocarpal (C) and intercarpal (D) joints, identifying, accessory carpal bone (Ca), carpal pad (Cp), radius (R), ulnar carpal bone (Cr), fourth carpal bone (C4), Metacarpal (M), Palmar recess (P).

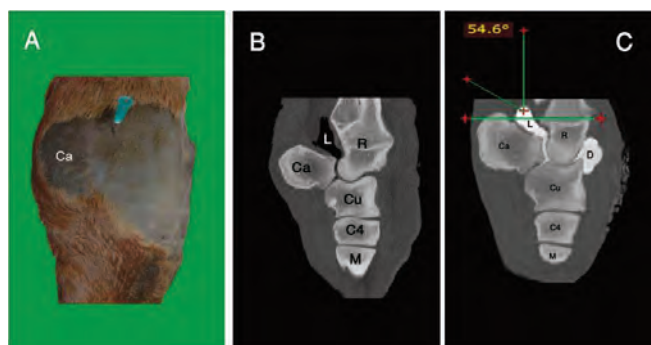


Fig. 5. Sites of needle placement for the lateral approach of arthrocentesis of the carpal joint in camel (A). Pre-contrast reformatted parasagittal CT image of the extended lateral side of the camel carpal joint (B). Post contrast reformatted parasagittal CT image of the extended lateral side of the carpal joint in camel, after successful lateral arthrocentesis, identifying, the latero-palmar recess of the radiocarpal sac (L), dorsal recess (D), accessory carpal bone (Ca), fourth carpal bone (C4), metacarpal (M).

Table 1. Success rate for radiocarpal and intercarpal arthrocentesis of 15 adult camel cadaveric forelimbs (5 limbs /technique).

Techniques	Success rate %			
	number of corrected attempts / Total number of attempts*100			
	Success after 1 <sup>st</sup> attempt		Success after 2 <sup>nd</sup> attempt	
	Radiocarpalsac	Intercarpalsac	Radiocarpalsac	Intercarpalsac
Dorsomedial	100 (5/5)	100 (5/5)	0	0
Dorsolateral	80 (4/5)	60 (3/5)	20 (1/5)	40 (2/5)
Lateral	60 (3/5)	Not accessible	40 (2/5)	Not accessible

were feasible for carpal puncturing in camel (Figs. 1-5). Whilst, palmar approaches could not be feasible, because of the small size of the palmar pouches, their deep location underneath the multiple layers formed by the flexor tendons, and the presence of the carpal canal and its contents (median artery and nerve).

Topographic landmarks for medio-lateral orientation of dorso-medial and dorso-lateral arthrocentesis of the radiocarpal and intercarpal joints were the tendons of extensor muscles. The optimum location for needle placement that was identified from examination of anatomic preparations and CT images was directly lateral to the tendon of the extensor carpi radialis and the common digital extensor tendon, for the dorso-medial and dorso-lateral approaches respectively (Figs. 3-4). In these locations, wide depressions without relevant blood vessels were identified in all examined forelimbs. From these locations, the needle was inserted at an angle 60-70 degree from the sagittal plane of the joint to a depth of 1.5-2.0 cm (Figs. 3-4).

When arthrocentesis of radiocarpal and intercarpal joints was successful, contrast medium was seen within the palmar recesses (Figs. 3-4). Evaluation of CT images revealed that, in the two examined limbs, the contrast medium was detectable in the radiocarpal and intercarpal joints as well as their recesses, but when using the dorso-lateral approach, the radiocarpal joint was filled better than the intercarpal joint. In the two limbs, inadvertent centesis of common digital extensor and extensor carpi-radialis tendon sheaths was occurred.

In contrast to the dorsal approach (Fig. 3), which can be applied in standing or kneeling position, the lateral approach (Fig. 5) could only be performed in standing position, when the carpus was fully extended. In such a position, a shallow depression between the lateral extensor and the ulnar carpal extensor tendons could be located. From this

location, the needle was then inserted at an angle of 50-60 degree from the sagittal plane of the joint to a depth of 1- 1.5 cm (Fig. 5), then the procedures of needle injection and aspiration were repeated. This approach targeted the lateral pouch of the radiocarpal sac, which has no communications with other compartments. Consequently, when arthrocentesis with lateral approach was successful, contrast medium was only seen within the lateral and the other recesses of radiocarpal sac (Fig. 5). Evaluation of CT images revealed that contrast medium was detectable in the radiocarpal sac, as well as their palmar and lateral recesses (Fig. 5).

The operator found that it easier to reach the joint capsule using the dorsomedial approach (Fig. 3), with accuracy index of 100% and was obtained on the first attempts for the radiocarpal and intercarpal joints respectively, whilst the dorso-lateral (Fig. 4) and the lateral approach (Fig. 5) had lower success rate as shown in Table 1.

In the six procedures that performed for intra-articular medication and diagnosis, all approaches were successful, but the dorso-medial approach was the easier one. The arthrocentesis was performed while three of the camels were restrained in kneeling position, and only one calf restrained in standing position for lateral approach. In-order to ensure good diffusion of medication throughout all the joint compartments, dorso-medial approach for intercarpal joint was performed in-combination with the lateral approach. No sedation was used, and the procedure was well tolerated in all camels.

## Discussion

Joint puncturing is the only route for intra-articular medication for treatment of carpalitis in camel. Despite the high incidence of carpalitis in camel (Khan *et al.*, 2003), literatures concerning carpal arthrocentesis are very few (Alsobayil *et al.*, 2015).

The available literatures described briefly the anatomy of the dorsal approaches for carpal injection in camel, and not taken in consideration other approaches or the comparison between different techniques with regard to their feasibility, accuracy and ease of performance.

There are practical and clinical needs for feasible and safe carpal arthrocentesis techniques in camel. Therefore, the authors designed this study to describe in detail the different approaches, and compared between them on basis of the feasibility, accuracy, and ease of performance.

Authors also had taken in consideration the camel nervous temperament while performing the procedure, so all camels but one were restrained in kneeling position. In this position, camels were quite and well secured, additionally it provided extreme flexion needed for revealing the depressions (injection sites) of dorsal approaches.

For accuracy test, the use of routine radiography was highly recommended, (Miller *et al.*, 1996; Drevemo *et al.*, 1999; Tnibar *et al.*, 2015), but little is known about the very complex structure of the camel carpal joint as well as, its topographic and capsular anatomy, for these the authors preferred to use CT scanning instead of X-ray imaging. As, CT scans was superior to conventional radiography for the simultaneous imaging of bone and soft tissue, the absence of superimposition, and ability of providing a panoramic view of joint pouches, their communications and relations using 3d reformatted CT images (Tietje, 1997; Tucker and Sande, 2001).

The examination of anatomic preparations and application of imaging techniques are useful to assess synovial joint cavities and their relationship to the periarticular structures (Miller *et al.*, 1996). The anatomical and CT findings of these studies suggested three feasible approaches of carpal arthrocentesis, which including, dorso-medial, dorsolateral and lateral approaches. These approaches were different from that used for other ruminants (Nuss *et al.*, 2002; Alsobayil *et al.*, 2015). Nevertheless, the similarities between the periarticular (Constantinescu *et al.*, 2008) and articular anatomy (Gallotta and Gallotta, 1988; Adro and Benavente, 1990) of the dromedary carpal joint and that of the llama and guanaco may open the door to test the suitability of the approaches, described in this study for other camelides.

From the anatomical point of view, the selected sites of injection were accurate and safe, as they

did not include or related to any blood vessels or nerves. No safe or accurate palmar approach could be determined in this study, because the deep location of the palmar pouches, the presence of flexor tendons, carpal canal and their contents (median artery and veins).

The dorsal techniques could be performed either in the kneeling or standing- position, but the limb should be flexed properly to obtain the injection sites. The authors decided to secure camels in the kneeling position as it was not only safe for the operators, but also provided proper flexion of the joint, additionally, in this position the carpal callosities touched the ground and could not impair the injection.

In this study, the tendons of the extensor carpi radialis and common digital extensor muscles were used as landmarks for the dorsomedial and lateral approaches respectively, these slightly similar to that described by Alsobayil *et al.* (2015) for the dorso-medial approach. These tendons were easily palpated and facilitate identification of the site of needle insertion which located directly lateral to these tendons.

Results of *in-vitro* evaluation indicated that dorso-medial approach for arthrocentesis of radio-carpal and intercarpal joints was easier in performance than the dorso-lateral and the lateral approaches. It has a success rate with the first attempt 100% compared with 80% for the dorso-lateral and 60% for the lateral approach. Arthrocentesis via the dorso-medial approach was technically easy to perform because of the site for needle placement was wider and easily located, compared with that required for the lateral approaches.

Although inadvertent centesis is common during carpal injection in camel (Alsobayil *et al.*, 2015), it did not occur while performing the lateral technique. To avoid the inadvertent centesis of the tendon sheaths, which occurred during the dorsal approaches, arthrocentesis should be performed approximately 2 to 3 mm lateral to the extensor tendons.

The lateral technique performed in this study was accurate and safe, but has several limitations, which could be summarized as follows: it could not be applicable in the kneeling position, as the site of injection was obtained only while the carpus fully extended during the standing position, only the radiocarpal sac could be reached with this approach,

so it will not be used for intercarpal injection, and it has lower success rate comparing to other techniques. However, the lateral approach as an alternative site of arthrocentesis is advantageous if a superficial wound or dermatitis is present at the sites of the dorso-medial or dorso-lateral approaches and vice versa, as in such instances, arthrocentesis should not perform in the affected area.

In the present study, *in-vivo* arthrocentesis of the carpal joint in one female camel and three calves via three approaches were feasible without sedation and secured either in kneeling or standing position. Because females and calves have a quite attitude in contrast to male camels which almost nervous and entrusted; sedation is highly recommended when dealing with male camels, especially in rutting season. In the four camels, the dorsomedial approach was slightly easier than the dorsolateral and the lateral one.

## Conclusion

Studying the feasibility, accuracy and safety of different techniques for arthrocentesis of the carpal joint will help clinicians for deciding the suitable approach for treatment or diagnosis of carpalitis. Camels are sensitive animals with nervous temperament, so the selected techniques described in this study regarding the peculiarities of camel anatomy, safety of operator, ease of performance and accuracy of procedure is very important for clinical practice.

## References

- Adro, A.L., Benavente, A.M.A., 1990. Identification of bone patterns of south American camelids. *Avances en Ciencias Ve* 5, 79-86.
- Alsobayil, F.A., Allouch, J.A., Ahmed, A.F., 2015. Articular puncture techniques and contrast arthrography of the forelimb in dromedary camels (*Camelus dromedarius*). *Pakistan Veterinary Journal* 35, 28-32.
- Badawy, A.M., 2011. Computed tomographic anatomy of the fore-foot of the one humped camel (*Camelus dromedarius*). *Global Veterinaria* 6, 417-423.
- Constantinescu, G.M., Reed, S.K., Constantinescu, I.A., 2008. The suspensory apparatus and digital flexor muscles of the llama (*Lama glama*) 1. The thoracic limb. *International Journal of Morphology* 26, 543-550.
- Drevemo, S., Johnston, C., Roepstorff, L., Gustas, P., 1999. Nerve block and intra-articular anaesthesia of the forelimb in the sound horse. *Equine Veterinary Journal Suppl* 30, 266-269.
- Gallotta, D.R., Gallotta, J.M., 1988. (Osteology of the llama) *Osteologia del llama (lama glama guanicoe f.d. glamma linnaeus; 1758)*. *Rev Cienc Agrar Tecnologia alimentos* 9, 19-61.
- Gray, S.N., Puchalski, S.M., Galuppo, L.D., 2013. Computed tomographic arthrography of the intercarpal ligaments of the equine carpus. *Veterinary Radiology and Ultrasound* 54, 245-252.
- Janis, C.M., Theodor, J.M., Biosvert, B., 2002. Locomotor evaluation in camels revisited: A quantitative analysis of pedal anatomy and the acquisition of the pacing gait. *The Journal of Vertebrate Paleontology* 22, 110-121.
- Kassab, A., 2008. The normal anatomical, radiographical and ultrasonographic appearance of the carpal region of one-humped camel (*Camelus dromedarius*). *Anatomia, Histologia, Embryologia* 37, 24-29.
- Khan, B.B., Iqbal, A., Riaz, M., 2003. Production and management of camels. Part III, University of agriculture, Faisalabad. pp. 1-20.
- Mellwraith, C.W., 2010. Review of the scientific basis for use of intra-articular corticosteroids in the horse. *Proceedings, 56<sup>th</sup> Annual Meeting of the American Association of Equine Practitioners* 56, 19-23.
- Miller, S.M., Stover, S.M., Taylor, K.T., 1996. Palmaroproximal approach for arthrocentesis of the proximal interphalangeal joint in horses. *Equine Veterinary Journal* 28, 376-380.
- Nuss, K., Hecht, S., Maierl, J., Matis, U., 2002. Arthrocentesis in cattle. Part 1: Thoracic limb. *Tierarztl Prax*, 30, 226-232.
- Ramadan, R.O., Kock, R.A., Higgins, A.J., 1986. Observations on the diagnosis and treatment of surgical conditions in the camel. *British Veterinary Journal* 142, 75-89.
- Roony, J., 1977. *Biomechanics of lameness in horses*. 2<sup>nd</sup> ed, R.E. Krieger publishing Co, Huntington, NY, pp. 71-139.
- Smuts, M.M.S., Bezuidenhout, A.J., 1987. *Anatomy of the dromedary*. Clarendon, Oxford.
- Tietje, S., 1997. The value of computed tomography in horses (243 cases). 2. Diseases of the limbs. *Parktt Tierarzt* 78, 35-43.
- Tnibar, A., Schougaard, H., Camitz, L., *et al.*, 2015. An international multi-centre prospective study on the efficacy of an intraarticular polyacrylamide hydrogel in horses with osteoarthritis: a 24 months follow-up. *Acta Veterinaria Scandinavica* 57, 20.
- Tucker, R.L., Sande, R.D., 2001. Computed tomography and magnetic resonance imaging of equine musculoskeletal conditions. *Veterinary Clinics of North America: Equine Practice* 17, 145-157.