

2020

## Ruptured Splenic Hemangioma Presenting As Small Bowel Obstruction: A Case Report

Haya S. Raef

*Tufts School of Medicine and Maine Medical Center*

Karin L. Cole MD

*Northern Light Mercy Surgery and Tufts School of Medicine*

Follow this and additional works at: <https://knowledgeconnection.mainehealth.org/jmmc>



Part of the [Gastroenterology Commons](#), and the [Surgery Commons](#)

### Recommended Citation

Raef, Haya S. and Cole, Karin L. MD (2020) "Ruptured Splenic Hemangioma Presenting As Small Bowel Obstruction: A Case Report," *Journal of Maine Medical Center*. Vol. 2 : Iss. 2 , Article 9.

Available at: <https://knowledgeconnection.mainehealth.org/jmmc/vol2/iss2/9> <https://doi.org/10.46804/2641-2225.1041>

The views and thoughts expressed in this manuscript belong solely to the author[s] and do not reflect the opinions of the Journal of Maine Medical Center or MaineHealth.

This Case Report is brought to you for free and open access by Maine Medical Center Department of Medical Education. It has been accepted for inclusion in the Journal of Maine Medical Center by an authorized editor of the MaineHealth Knowledge Connection. For more information, please contact Dina McKelvy [mckeld1@mmc.org](mailto:mckeld1@mmc.org).

## CASE REPORT

# Ruptured splenic hemangioma presenting as small bowel obstruction: a case report

Haya S. Raef,<sup>1</sup> Karin L. Cole MD<sup>2</sup>

<sup>1</sup>Tufts University School of Medicine, Boston, MA, <sup>2</sup>Northern Light Mercy Surgery, Portland, ME

---

**Introduction:** Splenic hemangioma is a rare vascular tumor of the spleen. These lesions are typically asymptomatic and can present with rupture and hemoperitoneum.

**Clinical findings:** We report the case of a patient who had no history of abdominal surgery before presenting with symptoms and imaging consistent with small bowel obstruction. The patient also had a splenic lesion.

**Diagnoses, Interventions, and Outcomes:** A diagnostic laparoscopy revealed a ruptured splenic hemangioma with obstructive ileus due to hemoperitoneum. The patient then underwent splenectomy to prevent recurrent bleeding.

**Conclusions:** Splenic hemangiomas are rare vascular neoplasms of the spleen that can be complicated by rupture. While obstructive ileus is a common post-operative phenomenon, it is rarely seen in association with vascular anomalies. This case represents a rare presentation of small bowel obstruction, highlighting the importance of using diagnostic laparoscopy in patients with no previous abdominal surgery.

**Keywords:** ruptured splenic hemangioma, small bowel obstruction, obstructive ileus, diagnostic laparoscopy

---

## CASE PRESENTATION

An otherwise healthy 78-year-old male with no history of abdominal surgery presented to the emergency room after two days of nausea and bilious vomiting, constipation, and colicky abdominal pain radiating to his back.

The patient was tachycardic and in mild distress. He did not have significant hypotension. His abdominal exam demonstrated distention and tenderness in the lower quadrants. CT (computed tomography) imaging showed dilated bowel loops throughout the upper abdomen, with collapsed distal bowel loops and scattered air-fluid levels, consistent with obstruction. An incidental finding noted a 3-cm hypodense, contrast-enhancing lesion in the spleen, likely hemangioma, with some adjacent free fluid (Figure 1). Lab tests showed

mild anemia (hemoglobin 11.1 g/dL) after hydration. A nasogastric tube was placed, and the patient was brought to the operating room the next day to determine the etiology of his obstruction.

Diagnostic laparoscopy showed dilated proximal small bowel with no clear transition point, along with some bloody fluid (250 cc) in the lower abdomen and left-upper quadrant. Findings were consistent with small bowel ileus due to hemoperitoneum. There was no active bleeding, but the splenic hemangioma was noted to distort the capsule of the spleen and believed to be the most likely source of the hemoperitoneum.

The patient's ileus resolved without further intervention, and he was discharged on post-operative day 2. One month later, after being given prophylactic vaccinations, he underwent elective laparoscopic splenectomy to prevent future hemorrhagic episodes. He recovered uneventfully. Pathology from the operative specimen confirmed the diagnosis of splenic cavernous hemangioma.

---

Correspondence: Karin L. Cole, MD  
Northern Light Mercy Surgery  
195 Fore River Parkway, suite 210  
Portland, ME 04102 email: coleka@emhs.org

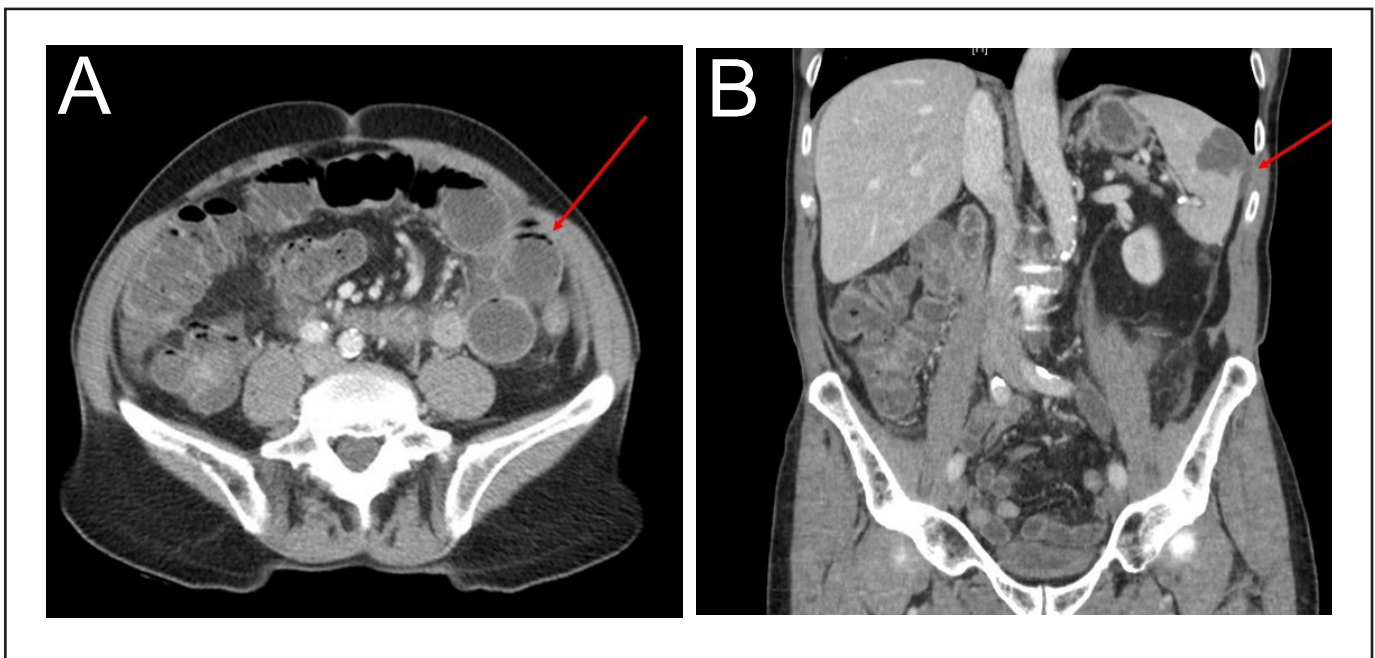
## DISCUSSION

Splenic hemangiomas are the most common benign tumor of the spleen and are composed of blood vessels that proliferate to form an unencapsulated mass.<sup>1</sup> The vascular channels can range from capillary to cavernous in size, with cavernous being the most common type. They are thought to be congenital, with an incidence rate between 0.03% and 14%, based on an autopsy study.<sup>2</sup> The channels are typically detected in middle-aged, predominately female, adults.<sup>3</sup> With ultrasound, hemangiomas are usually well-defined, echogenic lesions. With CT, they are hypodense lesions that show persistent contrast enhancement.<sup>4</sup> Splenic hemangiomas are often asymptomatic and discovered incidentally.

At larger sizes ( $\geq 4$  cm), the lesions can lead to non-specific symptoms, such as abdominal pain or a palpable mass in the left-upper quadrant.<sup>3</sup> Complications may be seen in larger splenic hemangiomas, including anemia, thrombocytopenia, and consumptive coagulopathy (Kasabach-Meritt syndrome) due to sequestration of blood components within the neoplasm.<sup>5,6</sup> Larger hemangiomas also have a higher risk of malignant transformation, portal hypertension, and spontaneous rupture.<sup>2,7,8</sup> Spontaneous rupture

occurs in up to 25% of patients, especially with lesions  $>4$  cm, and is due to increased pressure within the spleen secondary to congestion, Valsalva maneuver with straining, abdominal muscle spasm, infarction, or trauma.<sup>2</sup> Additionally, several cases have reported spontaneous rupture of splenic hemangiomas after thrombolysis.<sup>9,10</sup>

In this case, the patient presented with a ruptured splenic hemangioma, which led to an obstructive ileus due to hemoperitoneum. Obstructive ileus is characterized by impaired intestinal motility caused by non-mechanical factors.<sup>11</sup> This post-operative phenomenon is common and may be secondary to anesthesia, inflammation, or exposure of the peritoneum to irritants, such as blood from intraoperative damage to small vessels. It rarely occurs spontaneously as a result of vascular tumors. More common causes of small bowel obstruction in patients with no history of abdominal surgery include hernia, neoplasms, inflammatory bowel disease, congenital abnormalities, intussusception, and foreign bodies.<sup>12</sup> CT is helpful in diagnosing underlying pathology. Although the splenic lesion was noted on CT, the cause of intestinal obstruction in this patient was not definitively determined until laparoscopy.



**Figure 1.** Contrast-enhanced CT of the abdomen/pelvis at presentation. A) Axial view of dilated small bowel loops in the left abdomen. B) Coronal view of splenic lesion and adjacent free fluid. CT, computed tomography.

To prevent further episodes of hemorrhage and possible hypovolemic shock, the treatment of choice for splenic hemangioma rupture is total or partial splenectomy.<sup>2</sup> Although a partial splenectomy allows the spleen to retain some immune function, the procedure is generally indicated for younger patients (<60) with small tumors.<sup>13</sup> Other treatment options for splenic hemangioma include splenic artery embolization and antiangiogenic therapy; however, these approaches are typically reserved for stable hemangiomas.<sup>14,15</sup> There are no randomized trials that compare splenectomy versus splenic embolization for splenic hemangioma treatment. Patients with splenectomy have an increased risk of infections and, therefore, should be vaccinated against encapsulated microorganisms as soon as possible.

This report illustrates a unique case of splenic hemangioma rupture presenting as small bowel obstruction, highlighting the need to consider a broad differential diagnosis in patients presenting with obstruction but without prior abdominal surgery. In these cases, a diagnostic laparoscopy can be useful for ruling out rare and unexpected pathologies. Regardless of how it presents, ruptured splenic hemangioma can be safely treated with splenectomy.

**Conflicts of Interest:** None

## REFERENCES

1. Disler DG, Chew FS. Splenic hemangioma. *AJR Am J Roentgenol*. 1991;157(1):44. doi:10.2214/ajr.157.1.2048536.
2. Husni EA. The clinical course of splenic hemangioma with emphasis on spontaneous rupture. *Arch Surg*. 1961;83(5):681-688. doi:10.1001/archsurg.1961.01300170037008.
3. Willcox TM, Speer RW, Schlinkert RT, Sarr MG. Hemangioma of the spleen: presentation, diagnosis, and management. *J Gastrointest Surg*. 2000;4(6):611-613. doi:10.1016/s1091-255x(00)80110-9.
4. Ros PR, Moser RP Jr, Dachman AH, Murari PJ, Olmsted WW. Hemangioma of the spleen: radiologic-pathologic correlation in ten cases. *Radiology*. 1987;162(1 Pt 1):73-77. doi:10.1148/radiology.162.1.3538155.
5. Shanberge JN, Tanaka K, Gruhl MC. Chronic consumption coagulopathy due to hemangiomatous transformation of the spleen. *Am J Clin Pathol*. 1971;56(6):723-729. doi:10.1093/ajcp/56.6.723.
6. Dufau JP, le Tourneau A, Audouin J, Delmer A, Diebold J. Isolated diffuse hemangiomatosis of the spleen with Kasabach-Merritt-like syndrome. *Histopathology*. 1999;35(4):337-344. doi:10.1046/j.1365-2559.1999.00726.x.
7. Hoge M. Angioma cavernosum of the spleen. *Medical Record (1866-1922)*. 1895;48(12):418.
8. Pitlik S, Cohen L, Hadar H, Srujijes C, Rosenfeld JB. Portal hypertension and esophageal varices in hemangiomatosis of the spleen. *Gastroenterology*. 1977;72(5 Pt 1):937-940.
9. Norris PM, Hughes SCA, Strachan CJL. Spontaneous rupture of a benign cavernous haemangioma of the spleen following thrombolysis. *Eur J Vasc Endovasc Surg*. 2003;25(5):476-477. doi:10.1053/ejvs.2002.1839.
10. Balineni P, Kamal S, Pathivada S, Shivaji K. Spontaneous rupture of splenic hemangioma: a case report. *Int Surg*. 2019;6(5):1780-1782. doi:10.18203/2349-2902.isj20191907.
11. Mattei P, Rombeau JL. Review of the pathophysiology and management of postoperative ileus. *World J Surg*. 2006;30(8):1382-1391. doi:10.1007/s00268-005-0613-9.
12. Whang E. Small Intestine. In: Last FM, ed. *Schwartz's Principles of Surgery*. 11th ed. New York, NY: McGraw-Hill Professional; 2019:1051-1052.
13. Han X-L, Zhao Y-P, Chen G, Wu W-M, Dai M-H. Laparoscopic partial splenectomy for splenic hemangioma: experience of a single center in six cases. *Chin Med J (Engl)*. 2015;128(5):694-697. doi:10.4103/0366-6999.151680.
14. Islam S, Newman EA, Strouse PJ, Geiger JD. Antiangiogenic therapy for a large splenic hemangioma. *Pediatr Surg Int*. 2005;21(12):1007-1010. doi:10.1007/s00383-005-1533-3.
15. Choi W, Choi YB. Splenic embolization for a giant splenic hemangioma in a child: a case report. *BMC pediatr*. 2018;18(1):354. doi:10.1186/s12887-018-1331-4.