

Philadelphia College of Osteopathic Medicine

DigitalCommons@PCOM

---

Neurosurgery Resident Research

Graduate Medical Education Research

---

7-1-2020

## Endovascular treatment of cervical myelopathy from brachiocephalic venous stenosis.

Craig Schreiber

*Philadelphia College of Osteopathic Medicine*

Alex Anavim

Mark Kotapka

Paul Brady

Follow this and additional works at: [https://digitalcommons.pcom.edu/neurosurgery\\_residents](https://digitalcommons.pcom.edu/neurosurgery_residents)



Part of the [Neurosurgery Commons](#)

---

### Recommended Citation

Schreiber, Craig; Anavim, Alex; Kotapka, Mark; and Brady, Paul, "Endovascular treatment of cervical myelopathy from brachiocephalic venous stenosis." (2020). *Neurosurgery Resident Research*. 5. [https://digitalcommons.pcom.edu/neurosurgery\\_residents/5](https://digitalcommons.pcom.edu/neurosurgery_residents/5)

This Article is brought to you for free and open access by the Graduate Medical Education Research at DigitalCommons@PCOM. It has been accepted for inclusion in Neurosurgery Resident Research by an authorized administrator of DigitalCommons@PCOM. For more information, please contact [library@pcom.edu](mailto:library@pcom.edu).

Available online at [www.sciencedirect.com](http://www.sciencedirect.com)

ScienceDirect

journal homepage: [www.elsevier.com/locate/radcr](http://www.elsevier.com/locate/radcr)

## Case Report

# Endovascular treatment of cervical myelopathy from brachiocephalic venous stenosis

Craig Schreiber, DO<sup>a,b,\*</sup>, Alex Anavim, MD<sup>c</sup>, Mark Kotapka, MD<sup>a</sup>, Paul Brady, MD<sup>c</sup>

<sup>a</sup>Department of Neurosurgery, Einstein Medical Center, Philadelphia, PA, USA

<sup>b</sup>Department of Neuroscience, Philadelphia College of Osteopathic Medicine, Philadelphia, PA, USA

<sup>c</sup>Department of Radiology, Einstein Medical Center, Philadelphia, PA, USA

## ARTICLE INFO

## Article history:

Received 22 March 2020

Revised 17 April 2020

Accepted 17 April 2020

Available online 1 May 2020

## Keywords:

Cervical myelopathy

Venous stenosis

Brachiocephalic vein

Epidural venous

Engorgement

Endovascular treatment

## ABSTRACT

Central venous stenosis is a rare cause of neurologic pathology. Here we present a case of brachiocephalic vein stenosis causing cervical myelopathy through venous engorgement. Our patient was a 51-y/o male who presented with ambulatory dysfunction so he was evaluated for cervical myelopathy. Imaging revealed cord compression from venous engorgement and brachiocephalic vein stenosis. He was treated with angioplasty and vessel stenting which significantly improved flow on postintervention imaging. In conclusion, preoperative vascular imaging should be considered in myelopathic patients as it can detect this rare but dangerous etiology.

© 2020 The Authors. Published by Elsevier Inc. on behalf of University of Washington.

This is an open access article under the CC BY-NC-ND license.

(<http://creativecommons.org/licenses/by-nc-nd/4.0/>)

## Case 1

Our case is a 51-year-old male who presented after being found down in his basement. He has been having progressive ambulatory dysfunction over the past few months and has been falling frequently. Patient has a history significant for a severe traumatic brain injury in the 1980s. His brain injury eventually required a ventriculoperitoneal shunt for post traumatic hydrocephalus. Shunt has never been revised. Also of note, the patient was admitted 3 months prior for left sided weakness and had a stroke work up which was negative. CT head was performed in the emergency department and showed an appropriately positioned VP shunt

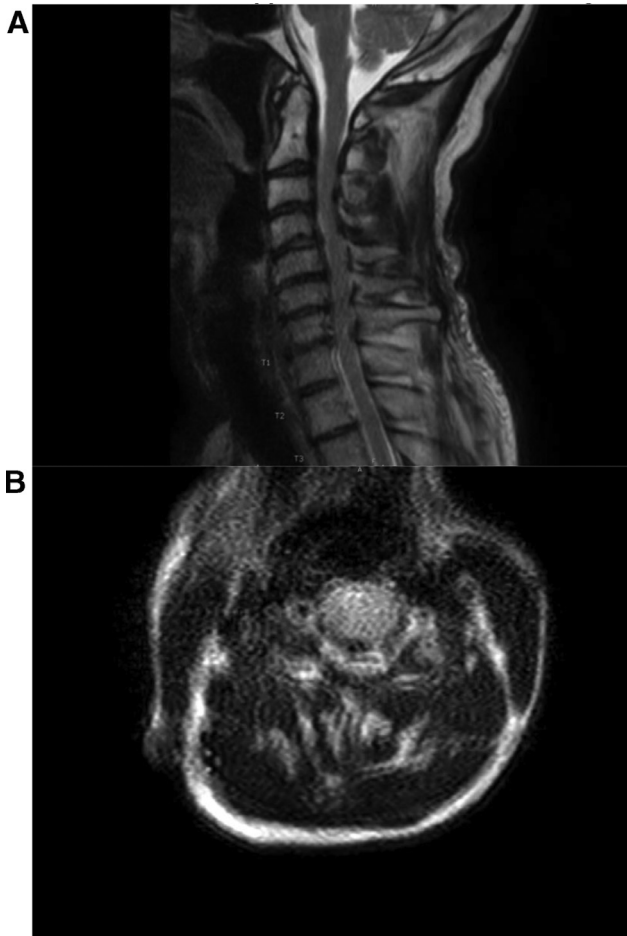
without evidence for acute intracranial hemorrhage or hydrocephalus. On exam, patient had a normal level of consciousness. He had normal strength on the motor exam except he was 4/5 in the hand intrinsics and hand grip. Some wasting of the hands was present bilaterally. Patient was hyper-reflexive throughout with some spasticity on passive motion. Hoffman's reflex was present on the left. No clonus was appreciated. Patient was admitted to the neurology service for myelopathy workup. An MRI of the cervical spine (**Image 1**) was obtained showing canal stenosis from C3 to C7 and initial plans were made for posterior decompression and fusion. The patient had a computed tomography angiogram (CTA) (**Image 2**) from his previous admission which was reviewed for surgical planning. On the CTA it was noted that the patient had a very prominent epidural venous

\* Corresponding author.

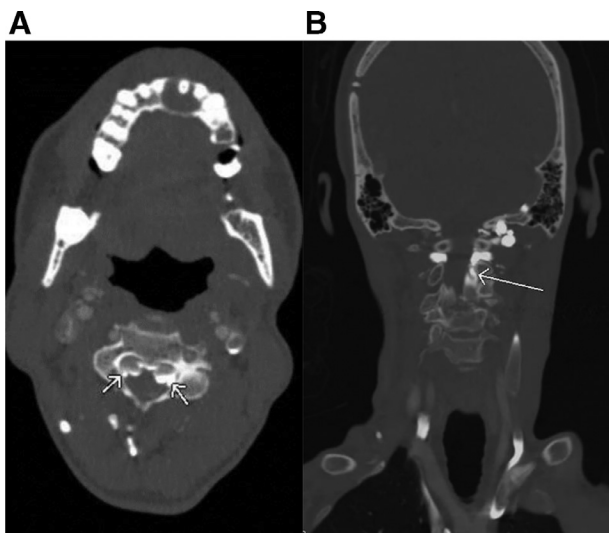
E-mail address: [craigsc@pcom.edu](mailto:craigsc@pcom.edu) (C. Schreiber).

<https://doi.org/10.1016/j.radcr.2020.04.041>

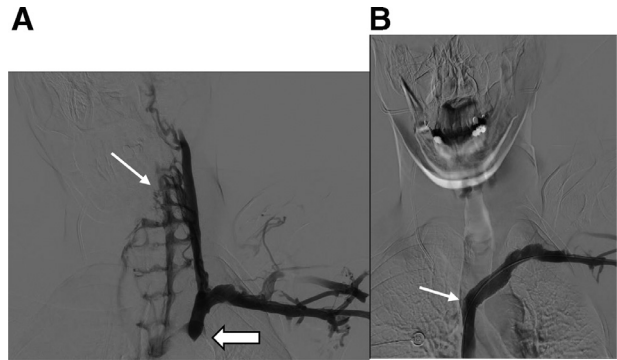
1930-0433/© 2020 The Authors. Published by Elsevier Inc. on behalf of University of Washington. This is an open access article under the CC BY-NC-ND license. (<http://creativecommons.org/licenses/by-nc-nd/4.0/>)



**Image 1A – (sagittal) and 1B (axial) are the T2 MRI images of the patient’s cervical spine at admission. Here it appears to be stenotic from degenerative changes from C3 to C7.**



**Image 2A – (Coronal) and 2B (Axial) CT Angiogram showing early filling of prominent epidural veins (white arrows) on CT Angiogram**



**Image 3A – showing venogram prior to intervention. Brachiocephalic stenosis is seen (thick white arrow) with retrograde filling of prominent epidural veins (thin white arrow). Image 3B shows venogram after stent placement, with brisk opacification of the superior vena cava (white arrow) without visualization of the cervical epidural veins.**

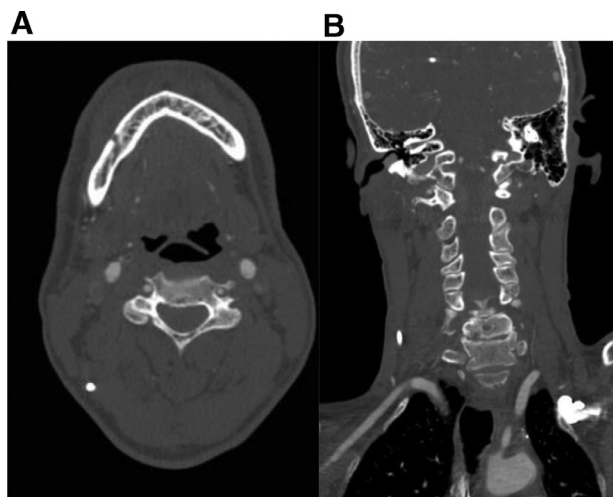
plexus, and the plexus itself was contributing to the canal stenosis.

The decision was made to undergo a spinal angiogram/venogram prior to any surgical intervention to evaluate for a vascular lesion. A venogram was performed using a micropuncture access in the left brachial vein. The brachial and subclavian veins were unremarkable. The left brachiocephalic vein was noted to have severe stenosis with retrograde filling of the left internal jugular vein and enlarged epidural veins (Image 3A). Decision was made to treat the lesion. A stiff guidewire was threaded through the stenosis. Then the vessel underwent balloon angioplasty which improved flow, but there was still retrograde filling of the left internal jugular vein. A self-expanding stent was then placed across the lesion. After intervention, contrast was seen emptying into the superior vena cava without retrograde filling of the internal jugular vein or prominent epidural veins (Image 3B).

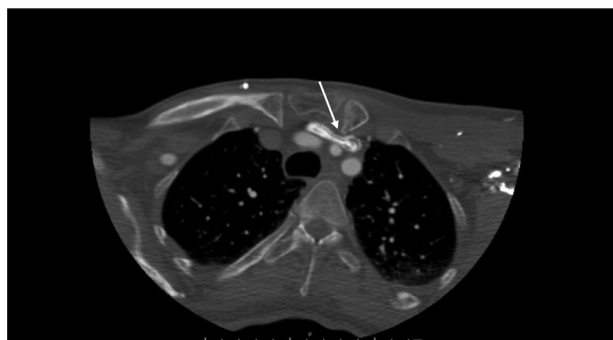At time of discharge, the patient denied headache, sensorimotor deficits, arm numbness/pain, or acute changes in mobility. Follow-up MRI of the cervical spine at 4 weeks showed persistent prominent epidural veins. However, concurrent CTA of the neck showed a patent stent in the left brachiocephalic vein, without reflux of contrast into the previously described prominent epidural veins (Image 4). Of note, in the CTA you can see the stent in the brachiocephalic vein being compressed by the left clavicle and left common carotid, which supports an anatomic compression syndrome (Image 5).

## Discussion

Central venous stenosis (CVS) is a finding seen commonly in patients on long term hemodialysis. True epidemiology is unclear because patients are typically only screened when symptomatic. Estimates range from 20% to 50% [1]. One study screened hemodialysis patients, who were previously dialyzed



**Image 4A – (Coronal) and 4B (axial) CT Angiogram 4 weeks after initial venogram shows stent patency without visualization of the previously seen prominent epidural veins.**



**Image 5 – This is a view of the chest on the postintervention CTA. Here you can see the brachiocephalic venous stent (white arrow). It is being compressed by the left clavicle and left common carotid artery.**

through subclavian catheters and found a rate of 34% [2]. History of central venous catheterization and cardiac pacing devices has also been indicated as high risk factors for CVS. Uncommon causes of CVS include tumor compression, arterial compression syndromes, radiation treatment, and idiopathic sources. Typical symptoms of CVS include extremity and facial edema, pleural effusions, and inefficient dialysis/recurrent hyperkalemia [1,8]. Some of the more well-known syndromes of venous hypertension include Superior Vena Cave Syndrome, Budd-Chiari Syndrome, and esophageal varices. Once detected, CVS usually requires treatment. Endovascular intervention remains treatment of choice and involves angioplasty and stenting. Refractory disease can be treated with open surgical repair of the vessel [8].

Neurologic sequelae are rarely seen from CVS however there has been a small but growing body of literature showing neurologic compromise. Some of the earlier literature focused on shunted patients, and how over shunting caused

venous engorgement. This resulted in cord compression and myelopathy. Revision of the shunting resolved the issue in reported cases [7,11]. CVS has been shown to cause intracranial venous hypertension with severe sequelae such as hemorrhage, stroke, optic atrophy, and provocation of seizures [4,5,9]. Here we present a case of cervical myelopathy, a common syndrome in the general population, but the etiology is from the rare occurrence of epidural engorgement secondary to stenosis of the brachiocephalic vein. Myelopathy from epidural engorgement has been described in only a few cases previously. One case has a patient who had a chronic thrombus of epidural veins causing cervico-thoracic junction compression [3]. Another published case is a patient with Budd-Chiari syndrome who presented with thoracic myelopathy [6]. A third case had a woman present with cauda equina secondary to venous congestion from May-Turner Syndrome [10]. It is important to note, that in all of these case reports, the neurologic function improved after treatment of the CVS.

In our patient, the epidural engorgement did improve significantly after the brachiocephalic vein was stented open. Our patient did not have a history of hemodialysis or kidney disease. However, with his history of severe brain trauma, it is reasonable to assume he had a central catheter at some point in his hospitalization, however we have no record of this. It is interesting to note on the post intervention CT, the stent is being compressed between that patient's clavicle and left common carotid, which supports an anatomic compression syndrome. Unfortunately, our patient has not had long term followed up and was last seen in the office at his 4 week post op visit, so long term neurologic outcome has not been obtained yet. The long-term outcome of our patient will be critical because he also has a ventriculoperitoneal shunt and therefore has two unorthodox reasons to be myelopathic outside of spondylosis. If his myelopathy does not improve, he may be a candidate for a shunt revision to correct overshunting [7,11].

Central vein stenosis is a rare cause of myelopathy. Brachiocephalic stenosis is an even rarer cause. Brachiocephalic stenosis has been implicated in intracranial venous hypertension previously, but it has not been reported as a source of compressive myelopathy [4]. CVS is not a common source of myelopathy, and it is inappropriate to screen for in the general population without a history/physical supporting a vascular lesion. However, in patients with history of hemodialysis, central venous catheterization, and cardiac pacing devices, CVS would be reasonable to consider as an atypical cause. In our case, there was no suspicion until the CT angiogram was reviewed for operative planning. A vascular study such as a CT angiogram is a valuable tool in preoperative planning for cervical myelopathy and can detect this rare but potentially dangerous etiology of myelopathy. Vascular imaging should be considered in all patients who are considered for operative management.

#### REFERENCES

- [1] Agarwal AK. MD: Central vein stenosis. *Am J Kidney Dis* 2013;61:1001–15.

- [2] Al-Salman MM, Rabee H, Abu-Aisha H, Trengganu N, Al-Damegh S, Al-Smeyer S, et al. Central vein stenosis in patients with prior subclavian vein catheterization for maintenance dialysis. *Saudi J Kidney Dis Transpl* 1997;8:119.
- [3] Dickman CA, Zabramski JM, Sonntag VKH, Coons S. Myelopathy due to epidural varicose veins of the cervicothoracic junction. *J Neurosurg* 1988;69:940–1.
- [4] Herzig DW, Stemer AB, Bell RS, Liu A, Armonda RA, Bank WO. Neurological sequelae from brachiocephalic vein stenosis. *J Neurosurg* 2013;118:1058–62.
- [5] Kim CH, Kang J, Choi DS, Park J. Intracranial venous reflux caused by occlusion of the brachiocephalic vein mimicking dural arteriovenous fistula. *World Neurosurg* 2018;120:438–41.
- [6] Lee J, Song W, Kang K. Myelopathy-mimicking symptoms of epidural venous engorgement and syringomyelia due to inferior vena cava stenosis at the thoracolumbar junction in a patient with budd-chiari syndrome. *J Neurosurg Spine* 2015;23:467–70.
- [7] Liu JK, Gottfried ON, Brockmeyer DL. Epidural venous engorgement resulting in progressive cervical myelopathy from shunt-related intracranial hypotension. Case report and review of the literature. *J Neurosurg* 2006;105:499.
- [8] Park HS, Choi J, Baik JH. Central venous disease in hemodialysis patients. *Kidney Res Clin Pract* 2019;38:309–17.
- [9] Rinat C, Ben-Shalom E, Becker-Cohen R, Feinstein S, Frishberg Y. Complications of central venous stenosis due to permanent central venous catheters in children on hemodialysis. *Pediatr Nephrol* 2014;29:2235–9.
- [10] Tello Díaz C, Allegue Allegue N, Gil Sala D, Gonçalves Martins G, Boqué Torremorell M, Bellmunt Montoya S. Cauda equina syndrome caused by epidural venous plexus engorgement in a patient with may-thurner syndrome. *Ann Vasc Surg* 2019;60:480.e7–480.e11.
- [11] Wolfe SQ, Bhatia S, Green B, Ragheb J. Engorged epidural venous plexus and cervical myelopathy due to cerebrospinal fluid overdrainage: a rare complication of ventricular shunts. case report. *J Neurosurg* 2007;106:227.